

implants

international magazine of oral implantology

3 2017

case report

Natural preservation
of the emergence profile

industry

Dynamic navigation in fully edentulous maxilla

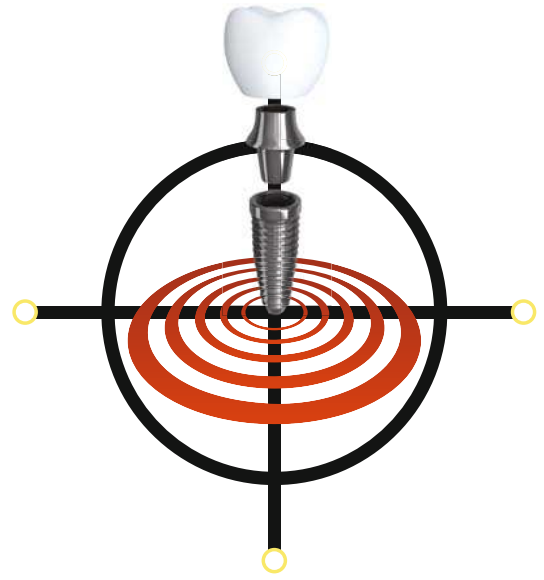
events

Joint meeting of the EAO and SEPES



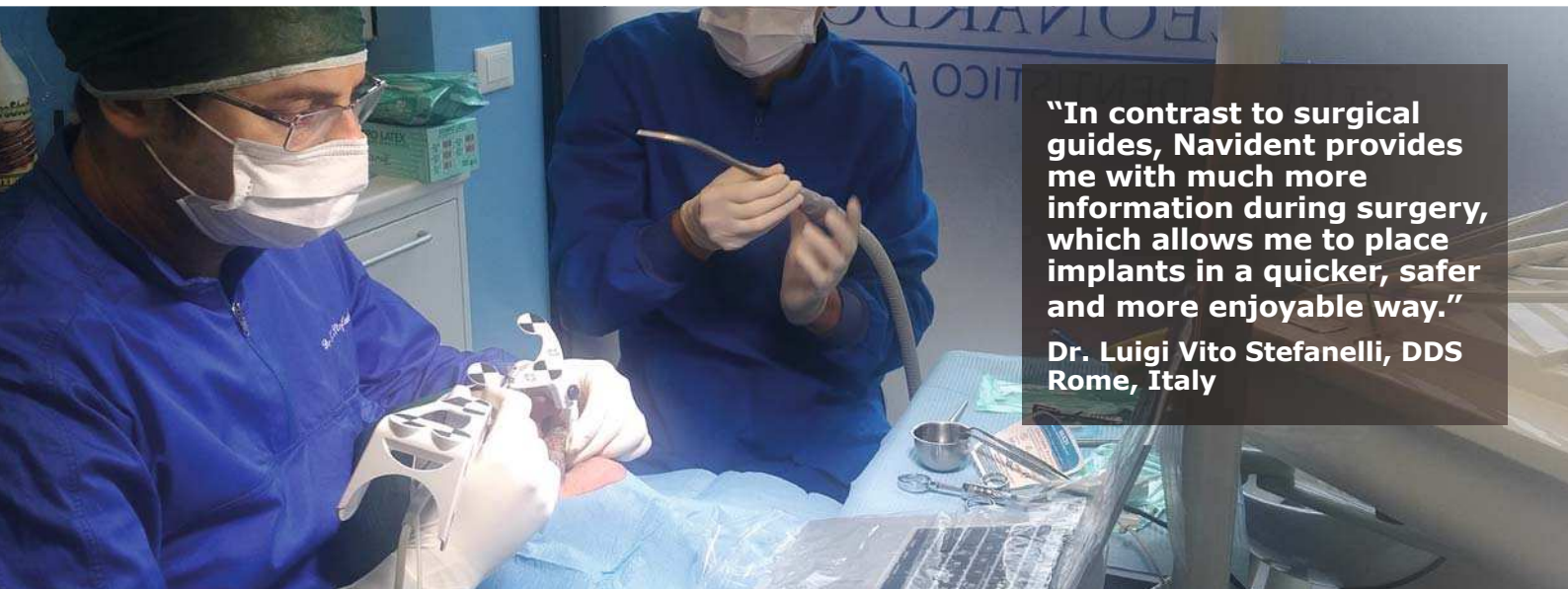Navident

Targeting Perfection



Dynamic navigation for freehanded dental implant placement

See for yourself how freehanded guided surgery aids more accurate implant placement. Navident tracks the drill and the patient's jaw, providing real-time tactile guidance and visual feedback.



"In contrast to surgical guides, Navident provides me with much more information during surgery, which allows me to place implants in a quicker, safer and more enjoyable way."

**Dr. Luigi Vito Stefanelli, DDS
Rome, Italy**

Compatible with any implant type, drill system and all CBCTs currently on the market

- Precision guidance for increased accuracy within 0.5mm of treatment plan*
- Provides even greater value from your CBCT data
- Easy to use, reducing time and expense with a simplified workflow
- Enables minimally invasive flapless drilling without a physical guide



Try Navident's precision guidance for yourself.

Call +32.475.75.52.26 or email info@claronav.com

Visit us at Booth n° S31 at EAO-SEPES joint meeting 2017

ClaroNav
www.claronav.com

*Average error of 0.4mm in internal bench tests with a range of operating conditions.

Does **biology** **still** matter?



Prof. (CAI) Dr Roland Hille

On 29 and 30 September 2017, the German Association of Dental Implantology (DGZI) and dental implant professionals will meet for the 47th International Annual Congress in Berlin, Germany. At the heart of the two day congress stands the question of "Does biology still matter?". Our thoughts and actions today are increasingly defined by "higher, faster, further". But is this really the best and safest treatment strategy for our patients or would it not be more effective to combine implantology and biology in order to reach a successful treatment outcome? Various treatment strategies have already been tried and proven in practice and are science-based and largely foreseeable. Practitioners should follow and strive for those examples, particularly when entering implantology for the very first time. Because the challenges in this field are far from small. Our patients' wishes and expectations are often impossible to meet from a biological, physiological and hence aesthetic point of view.

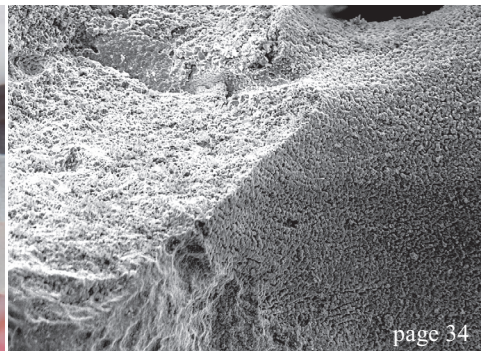
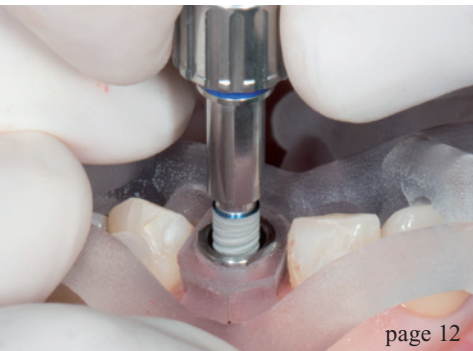
In addition, this year's update comprises the field of implantological prosthetics. Intensive discussions will focus here on the question of to what extent the conventionally practiced workflow is still contemporary. Or has the digital workflow already taken over the lead? In this light, it is crucial to examine the qualitative output and the preconditions that are required in order to ensure an adequate and standardised implementation. Furthermore, another important point of discussion will be the multi-morbidity of our patients with regards to extensive medication prescriptions. In this context, dentists are required to look outside their respective treatment areas and recognise the complexity of their patients' full clinical pictures. This, in turn, enables practitioners to fully assess possible risks involved in performing extensive surgical interventions. However, equally important for the implant success are the implant's biomechanics and the implant material, whether titan or ceramic is used. Which indication requires which implant, and what foreseeable difficulties might arise for the practitioner, based on those decisions, has also to be taken into account. Failure discussions, including identifying possible causes of the problem, will determine the future story of success.

Please come and join our panel discussion "DGZI kontrovers". Two experienced university professors will be talking about current scientific evidence and their practical experiences in using short implants while pursuing the question "Are shorties the all-purpose weapon in implantology?". High-quality training and celebrating are hallmarks of the DGZI! Therefore, on Friday we will celebrate as part of the legendary live show "Stars in Concert" and plunge into the sparkling world of show business. Excitement guaranteed!

And last but not least, Berlin is calling. The capital is always worth a visit and so are the practice-oriented international congresses of the DGZI!

Warm regards

Prof. (CAI) Dr Roland Hille
Vice President of the DGZI



| editorial

- 03 Does **biology still** matter?
Prof. (CAI) Dr Roland Hille

| research

- 06 **Immediate** restoration in the **digital** workflow
José Eduardo Maté Sánchez de Val &
José Luis Calvo Guirado

| case report

- 12 Natural **preservation** of the **emergence** profile
Dr Umut Baysal & Dr Arzu Tuna
- 18 Immediate **temporisation** using **tapered** implants
Dr Mohamad El Moheb

| industry

- 22 Overcoming a **difficult aesthetic** situation
Prof. Dr Dr M. Kemal Unsal
- 28 From **granules** to **foam**
Prof. Dr Dr Stefan Schermer

- 34 **Xenogeneic** bone **grafting** materials
Dr Mike Barbeck, Dr Ronald Unger,
Prof. Dr Frank Witte, Prof. Dr Sabine Wenisch &
Prof. Dr Dr Reiner Schnettler

- 38 **Dynamic** navigation in **fully** edentulous **maxilla**
Prof. Dr Hakan Uysal & Dr Noyan Başal

| events

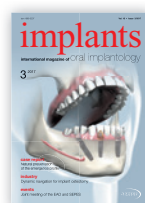- 52 **Arabian flair** and **French** charm
Dr Rolf Vollmer
- 54 Joint **meeting** of the **EAO** and **SEPES**

| news

- 42 **manufacturer news**
- 56 **news**

| about the publisher

- 58 **imprint**



Cover image courtesy of bredent medical GmbH & Co. KG
www.bredent-medical.com

a perfect fit™

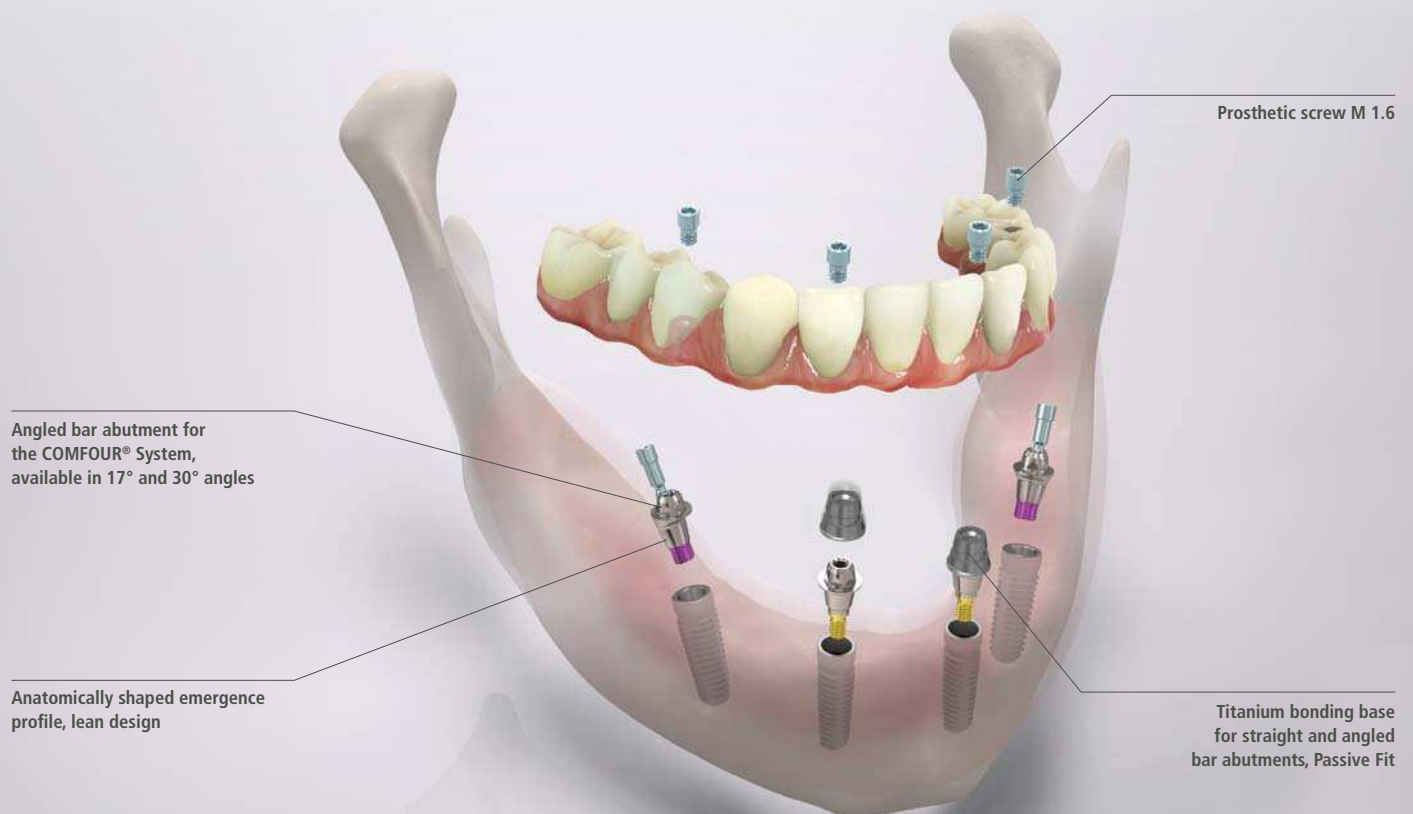camlog

THE NEW COMFORT CLASS.

The COMFOUR® Abutment System for occlusal screw-retained restorations is an ideal addition to the CAMLOG® and the CONELOG® Implant System. With the COMFOUR® System, you can offer your edentulous patients the option of an immediate, comfortable and permanent denture on four or six implants – and thus a considerable gain in quality of life. www.camlog.com

CAMLOG®
SYSTEM

CONELOG®
SYSTEM



Aligning tool



Scanning cap



Titanium cap



Flexible handle

COMFOUR® offers you a range of options to overcome the challenges you face in your implant practice, making them easier while saving time.

Immediate restoration in the digital workflow

Part II: Results and discussion

Authors: José Eduardo Maté Sánchez de Val & José Luis Calvo Guirado, Spain



The success of immediately placed implants has been investigated in various studies with encouraging results already. But what is rather simple in the anterior mandible needs more attention when it comes to the anterior maxilla. Here, clinicians are oftentimes concerned not only about achieving adequate implant stability, but also about fulfilling patients' desires for aesthetic results that resemble the natural dentition. To shorten procedures and eliminate intermediate prosthetic steps, digital technologies were developed that allow the intraoral scanning of models and attachments with a high degree of precision and reproducibility.

The article demonstrates the reliability of the single-session protocol using digital methods for scanning and producing crowns complemented with platform switching and evaluates the peri-implant soft-tissue seal. In part I of the article (published in *implants 2/17*), the authors described materials and methods used in an experiment with animals and in the treatment of humans. In part II of the article, the results are presented and discussed.

Rationale for immediate restoration

Research has shown that, for two-stage implants, marginal bone loss occurs primarily during the first year following placement and that this has mainly been attributed to the establishment of biologic width adjacent to the implant.¹⁹ Some studies have shown that bone remodelling can be biologically ascribed to bacterial colonisation of the micro-leakage present in a two-stage implant system and subsequent inflammation.²⁰ The crestal bone loss around implants has both horizontal and vertical components. Following abutment connection, crestal bone has been shown to recede from the implant/abutment junction microgap by 1.3 to 1.4 mm, measured horizontally.²¹

Animal study

Immediate implant placement and restoration minimise the harmful contamination of the peri-implant biological space and the resultant bone resorption. Immediate loading requires that certain prerequisites are met. The best way to objectively quantify the feasibility of immediate loading clinically is to analyse implant stability either by measuring the insertion torque, recommended at above 30 Ncm, or using the Osstell Mentor ultrasonic stability measuring device that returns ISQ values, which if above 65–70 allow us to load immediately with some confidence (Tab. 1).

Changes in the peri-implant tissue can be quantified by histomorphometry and histological evaluation in experimental studies (Tabs. 2 & 3). The radiological results of the animal experiments are documented in Figures 1a & b and Table 4. The histological connection between the soft tissue and the SKY elegance abutment is tight. In combination with platform switching, this produces a high level of bone stability at the implant collar (Figs. 2a & b).

Tab. 1: Friedman test of ISQ analysis and measurements at initial day. Results as mean and medians.

No significant differences with $p < 0.05$ were found.

Tab. 2: Friedman test of BIC values. Comparison between titanium and hybrid PEEK-Ti abutments. Follow-up eight weeks after implant placement. Data shows mean, Sd and medians.

No significant differences with $p < 0.05$ were found.

ISQ value	Insertion		p value
	Mean ± Sd	Median	
BioHPP abutment	74.46 ± 4.55	74.46	0.16
Titanium abutment	74.19 ± 4.29	74.19	0.23

Table 1

BIC (%)	Titanium	PEEK	p value
Mean ± Sd	61.29 ± 1.45	62.52 ± 4.63	0.32
Median	61.29	62.52	

Table 2

		Titanium	PEEK	p value
PM-BC	Mean ± Sd	2.74 ± 0.41	3.11 ± 0.26 *	0.032
	Median	2.74	3.11	
PM-LC	Mean ± Sd	2.91 ± 0.03	3.71 ± 0.18 *	0.008
	Median	2.91	3.71	
PM buccal-IS	Mean ± Sd	2.35 ± 0.87	2.95 ± 0.53 *	0.015
	Median	2.35	2.95	
PM lingual-IS	Mean ± Sd	2.65 ± 0.43	3.57 ± 0.38 *	0.003
	Median	2.65	3.57	
IS-BC	Mean ± Sd	2.04 ± 0.11 *	1.53 ± 0.21	0.011
	Median	2.04	1.53	
IS-LC	Mean ± Sd	1.93 ± 0.14 *	1.41 ± 0.19	0.029
	Median	1.93	1.41	

Table 3

Linear measurements in millimetre: PM-BC: distance from the peri-implant mucosa to the buccal bone crest; PM-LC: distance from the peri-implant mucosa to the lingual bone crest; PM buccal-IS: distance from peri-implant mucosa to the implant shoulder in the buccal aspect; PM lingual-IS: distance from peri-implant mucosa to the implant shoulder in the lingual aspect; IS-BC: distance from the top of the implant shoulder to the first bone-to-implant contact in the buccal aspect; IS-LC: distance from the top of the implant shoulder to the lingual bone crest. Values as mean ± Sd and median.

Tab. 3: Non-parametric Friedman test to related samples. (*) Significant differences with $p < 0.05$.

Rationale for platform switching

The switch in implant platform diameter prevents apical migration of the epithelial attachment and soft-tissue ingrowth at the top of the platform by reducing bacterial migration and, consequently, of soft-tissue ingrowth and peri-implant bone loss. Marginal bone loss is drastically reduced and the objective criteria for peri-implant inflammation are greatly improved.²²

Human study

Table 5 lists clinical parameters from human studies at one, three and five months. Figures 3a to h show radiological findings at one, three and five months. Figures 4a and b show the customisation of a SKY elegance abutment.

Rationale for single-stage treatments

Successive insertions and reconnections when restoring an implant accord-

ing to conventional protocols provoke bacterial invasion and colonisation of the biological space and mark the onset of marginal bone loss. Offering treatment in a single session provides the biological benefits described and saves time and money, increasing patient satisfaction.²³

Intraoral scanning

Fabricating a CEREC crown requires a step prior to intraoral scanning, namely the adaptation of the prosthetic support. The SKY elegance abutment can be cut and customised in the mouth, more or less like dentin, which means a reduction in time and cost. Also required are a delicate surface polish and preparation of the profiles to be recognised by the intraoral scanner. The restoration margins should be well-defined and prepared to the gingival or subgingival level.^{24,25} The SKY elegance abutment anatomy allows to create a proper emergency profile that can be customised for



Shortest Implants – Longest History.

Think Short!

For more than 30 years Bicon® short implants are unchanged in clinical use.

According to the 11th European Consensus Conference (EuCC) 2016 in Cologne, provided the specific treatment parameters are observed, the use of short, angulated or diameter-reduced implants in sites with reduced bone volume can be a reliable treatment option, given the risks associated with the use of standard-dimension implants in combination with augmentation procedures.

For more information:

Bicon Europe Ltd.

Hauptstr. 1

55491 Buechenbeuren

Germany

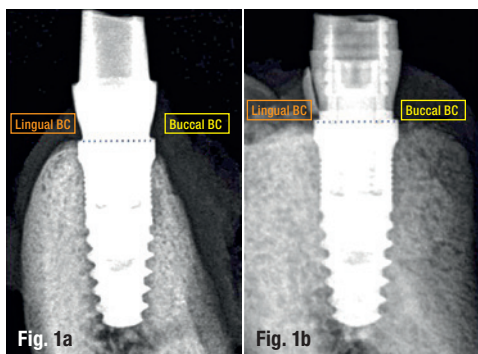
Phone +49 (0)6543 818200

germany@bicon.com

www.bicon.de.com



bicon
DENTAL IMPLANTS



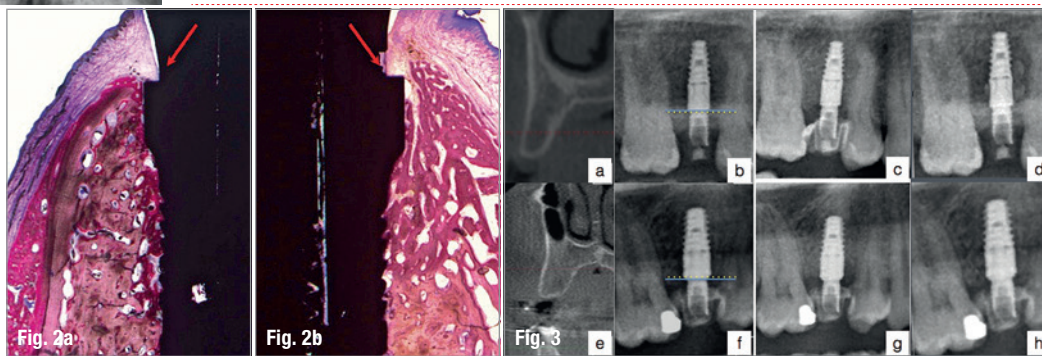
		Titanium	PEEK	p value
Buccal bone	Mean ± Sd	1.96 ± 0.21 *	1.43 ± 0.11	0.013
	Median	1.96	1.43	
Lingual bone	Mean ± Sd	1.78 ± 0.33 *	1.28 ± 0.43	0.031
	Median	1.78	1.28	

Table 4

Figs. 1a & b: Radiological analysis. Comparison between a titanium abutment (a) and a SKY elegance abutment (b).

Tab. 4: Radiological analysis of bone first contact distance to the implant shoulder. Values as mean ± Sd and median. Non-parametric Friedman test analysis. (*) Significant differences with $p < 0.05$.

Figs. 2a & b: Histological analysis of the SKY elegance abutment. Detail of platform switching and connective-tissue insertion over platform. Connective tissue at four weeks (a). Connective tissue at eight weeks (b).



Figs. 3a-h: Radiological analysis. Preoperative (a, e), at one month (b, f), at three months (c, g), and at five months (d, h).

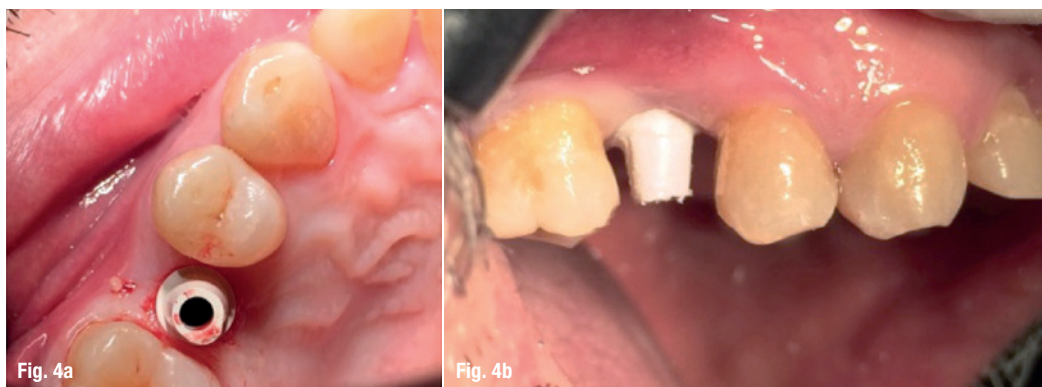
each patient (Fig. 5). The next step is to obtain relative relative isolation, with any hint of moisture removed, to ensure a good intraoral impression. The savings in terms of time and money are evident, as is the increase in patient comfort.

Fabricating a CEREC crown

The choice of restorative material to use on an implant requires familiarity with the way masticatory forces are transmitted via the crown and abutment

to the bone-to-implant contact area. Biomimetics is the study of the materials that allow us to adapt prosthetic elements to their intended proper function, based on similarity to the receiving environment.²⁶ Knowing how forces are transmitted is essential to avoid loads that can lead to bone loss or implant failure.

The SKY elegance is a hybrid abutment with a titanium base and a ceramically reinforced PEEK body, so the transmission of forces from the crown to the



Figs. 4a & b: Customisation of a SKY elegance abutment.

Tab. 5: Human study, values as mean ± Sd. Non-parametric Friedman test. Values of bleeding on probing (0 = no bleeding on probing and 1 = bleeding on probing).


		1 month	3 months	5 months	p value
First bone contact to platform (mm)	Mean ± Sd	0.50 ± 0.41	1.07 ± 1.12	1.17 ± 0.87	0.044
		68.10 ± 4.93	69.34 ± 1.22	71.43 ± 3.01	
	ISQ value (%)	0.21 ± 0.01	0.16 ± 0.05	0.06 ± 0.02	
Bleeding on probing (0–1)		3.64 ± 1.02	4.19 ± 1.05	4.11 ± 1.02	0.029
Insertion length (mm)					

Table 5



MIS GLOBAL
CONFERENCE 2018

360° IMPLANTOLOGY NASSAU PARADISE ISLAND, BAHAMAS, 8-11.02, 2018



LEARN THE EASY WAY. MAKE IT SIMPLE

MIS is pleased and honored to invite you to the 4th MIS Global Conference: 360 IMPLANTOLOGY, in beautiful Nassau Paradise Island, Bahamas. This Global Conference will deliver an intense and unforgettable experience in every aspect: scientific, professional and personal. [For registration, please contact your local MIS Representative.](#)

mis[®]

