



**Patient financing**  
Wouldn't you rather have 95 percent of a fee than zero?

▶Page 17



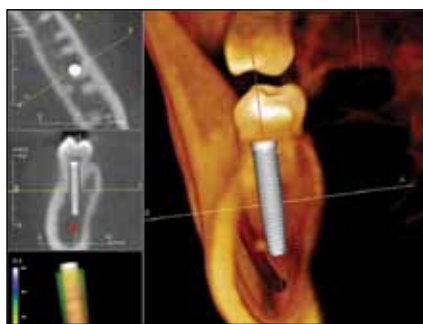**Materialise at the EAO**  
Dr. Norton will showcase SurgiGuide in Glasgow, U.K.

▶Page 19



**The new Legacy**  
Implant Direct's new angled overdenture abutments

▶Page 22



(Photo/Provided by Dr. Steven A. Guttenberg)

## CBCT and implants: a career-altering experience

By Steven A. Guttenberg, DDS, MD

With all the technology available to dental practitioners today, very few can be described as "career altering." One of my original reasons for investing in a cone-beam computed tomography (CBCT) scanner was to assist with the complete evaluation of dental implant sites.

A major concern during implant placement is the possibility of placing an implant too close to or penetrating the inferior alveolar nerve canal, likely resulting in injuries such as paresthesia, anesthesia or dysesthesia. In preparation for the insertion of fixtures, I wanted to be able to appropriately visualize important anatomic landmarks

→ **IT** page 14

## Esthetic management of adjacent maxillary central incisors

*Extraction, immediate placement and immediate provisionalization*

By Michael Sonick DMD

**Periodontist:** Dr. Michael Sonick

**Restorative Dentist:** Dr. Patrice Foudy

### Patient history

A medically and periodontally stable 50-year old woman presented with failing #8 and #9 teeth that exhibit asymmetry, lack of interdental papilla and a history of failing root-canal therapy and apicoectomy (Fig. 1).

### Treatment plan

1. Extraction of teeth #8 and #9, immediate implantation of #8 and #9 and immediate non-functional provisionalization of #8 and #9.
2. Three-month healing period.
3. Gingivectomy to create mucosal symmetry.
4. Six-month healing period, during which contour adjustments to interim restoration will be made to manipulate papillary regeneration.
5. Placement of final single PFM crowns on implants #8 and #9.

### Treatment plan rationale

Implant rehabilitation for sites #8 and #9 boosts long-term pros-



Fig. 1a: Initial facial view. (Photos/Provided by Dr. Michael Sonick)

thetic success, which diminishes future costs and permits more future restorability options.

The patient is an ideal candidate for immediate implant placement and temporization because of her

### Extraction of teeth #8 and #9, immediate placement of implants #8 and #9 and immediate non-functional provisionalization of #8 and #9

After oral sedation with 0.25 mg triazolam and local anesthetic induction using 2 percent lidocaine with 1:100,000 epinephrine and 0.5 percent bupivacaine with 1:200,000 epinephrine, sulcular incisions were made circumferentially around teeth #8 and #9.

To create room for extraction instructions, the crowns on teeth #8 and #9 were reduced (Fig. 2a). Teeth #8 and #9 were extracted atraumatically using a piezosurgical insert and serrated universal maxillary forceps

→ **IT** page 2

AD

**FREE**

**NuOss™**

See page 3 and [www.acesurgical.com](http://www.acesurgical.com) for details

PRSRT STD  
U.S. Postage  
PAID  
Permit # 306  
Mechanicsburg, PA

Dental Tribune America  
213 West 35th Street  
Suite #801  
New York, NY 10001



← **m** page 1

(Figs. 2b-2c). Degranulation of the sockets was performed using a carbide finishing bur and Neumeyer bur.

A surgical guide was used to prepare the implant osteotomies, and proper positioning was attained (Fig. 3). After finalization of the osteotomy sites, rough-surfaced, internal hex 4 mm (diameter) x 15 mm (length) implants were placed into the #8 and #9 sites (NanoTite® Tapered Certain® Implant, BIOMET 3i, Palm Beach Gardens, Fla.) (Fig. 4).

Healing abutments were placed on the implants to prevent soft-tissue and bony collapse during the period that extraoral fabrication of the temporary prostheses occurred (Fig. 5a).

The orientation of the implants was ideal, and the fixtures exited from the sockets at the cingulum posi-

tions (Fig. 5a). Primary stability was achieved. Radiographic review of the implants revealed a peak of bone between the fixtures, an inter-implant distance of greater than 4 mm and an implant-tooth distance of 2 mm (Fig. 5b). To bridge the circumferential gap between the socket walls and the implant surfaces, freeze-dried bone allograft (FDBA) was used as graft material (LifeNet Health, Virginia Beach, Va.).

Temporary cylinders (Pre-Formance® Temporary Cylinder, Certain Internal Connection, 4.1 mm platform, hexed) were placed on the implants to check the restorative position (Fig. 6). These were removed, and an implant-level pick-up impression was taken.

After chairside creation of a cast

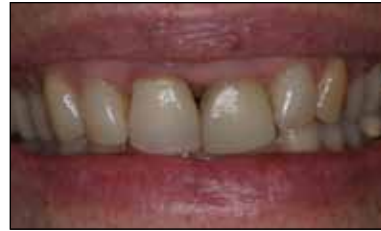

Fig. 1b: Smile view. Lack of papillae between #8 and #9 is evident. Patient also reveals gingival asymmetry, inflammation and excess gingiva around #8 and #9.

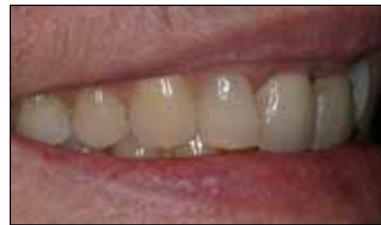

Fig. 1c: Right lateral initial smile view.

→ **m** page 4

AD

# Las Vegas

**Bellagio Hotel  
Las Vegas, Nevada**

**February 10-12, 2011**

Pre-Symposium Courses:  
Thursday, February 10, 2011

## ICOI Winter Symposium

For more information please contact the ICOI Central Office  
at (973) 783-6300 or visit our website at [www.icoi.org](http://www.icoi.org)

Sponsored by:

ADA CERP® | Continuing Education Recognition Program

AGD - Accepted Program Provider  
FAGD/MAGD Credit, 5/1/09 - 6/30/12

ICOI is an ADA CERP® Recognized Provider. ADA CERP® is a service of the American Dental Association to assist dental professionals in identifying quality providers of continuing dental education. ADA CERP does not approve or endorse individual courses or instructors, nor does it imply acceptance of credit hours by boards of dentistry.

Photo courtesy of The Las Vegas Convention and Visitors Authority

## IMPLANT TRIBUNE

The World's Newspaper of Implantology · U.S. Edition

### Publisher & Chairman

Torsten Oemus  
t.oemus@dental-tribune.com

### Vice President Global Sales

Peter Witteczek  
p.witteczek@dental-tribune.com

### Chief Operating Officer

Eric Seid  
e.seid@dental-tribune.com

### Group Editor & Designer

Robin Goodman  
r.goodman@dental-tribune.com

### Editor in Chief

Sascha A. Jovanovic, DDS, MS  
sascha@jovanoviconline.com

### Managing Editor/Designer

Implant & Endo Tribunes  
Sierra Rendon  
s.rendon@dental-tribune.com

### Managing Editor/Designer

Ortho Tribune & Show Dailies  
Kristine Colker  
k.colker@dental-tribune.com

### Online Editor

Fred Michmershuizen  
f.michmershuizen@dental-tribune.com

### Account Manager

Humberto Estrada  
h.estrada@dental-tribune.com

### Marketing Manager

Anna Wlodarczyk  
a.wlodarczyk@dental-tribune.com

### Marketing & Sales Assistant

Lorrie Young  
l.young@dental-tribune.com

### C.E. Manager

Julia Wehkamp  
j.wehkamp@dental-tribune.com

Dental Tribune America, LLC  
213 West 35th Street, Suite 801  
New York, NY 10001  
Phone: (212) 244-7181, Fax: (212) 244-7185



Published by  
Dental Tribune America

© 2010, Dental Tribune America, LLC  
All rights reserved.

Dental Tribune makes every effort to report clinical information and manufacturer's product news accurately, but cannot assume responsibility for the validity of product claims, or for typographical errors. The publishers also do not assume responsibility for product names or claims, or statements made by advertisers. Opinions expressed by authors are their own and may not reflect those of Dental Tribune International.

### Editorial Advisory Board

Dr. Sascha Jovanovic, Editor in Chief

Dr. Bernard Touati

Dr. Jack T. Krauser

Dr. Andre Saadoun

Dr. Gary Henkel

Dr. Doug Deporter

Dr. Michael Norton

Dr. Ken Serota

Dr. Axel Zoellner

Dr. Glen Liddelow

Dr. Marius Steigmann



Stop by the ACE booth  
AAOMS • Chicago



BOOTH #1012

SURGICAL SUPPLY CO., INC.

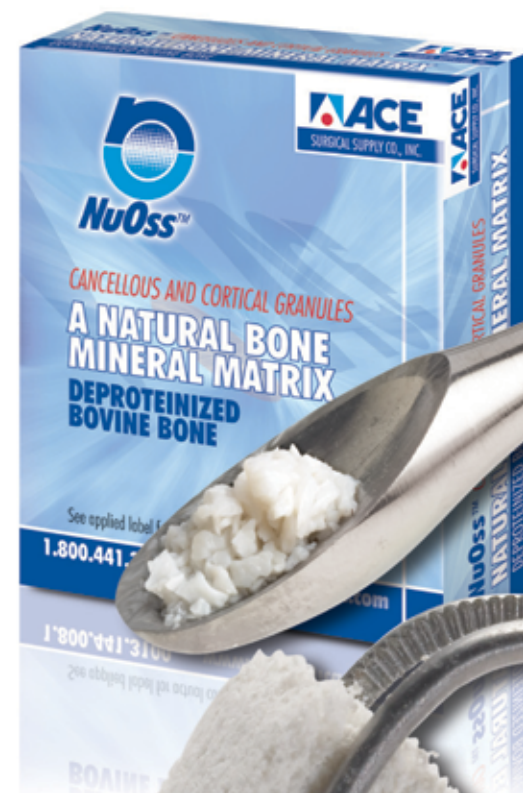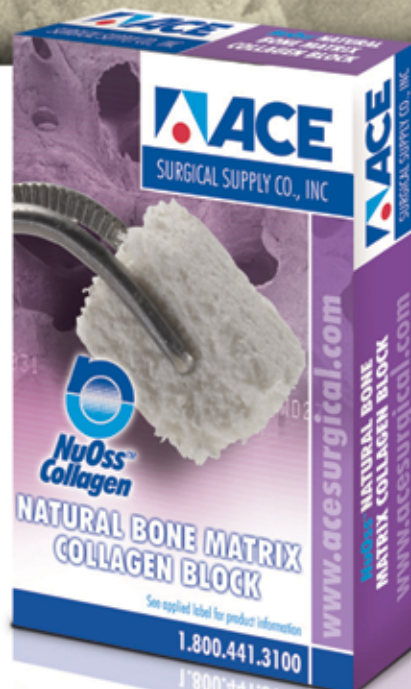# NuOss™

## The NU CHOICE IN BONE REGENERATION

### A NATURAL, POROUS BONE MINERAL MATRIX

**BUY ANY 5 NuOss  
VIALS or BLOCKS &  
GET 1 FREE\***

Offer good through October 2010.



### NuOss™ DEPROTEINIZED BOVINE BONE

**NuOss™** — A natural porous bone mineral matrix produced by the removal of all organic components from bovine bone. Due to its natural structure, NuOss™ is physically and chemically comparable to the mineralized matrix of human bone.

**NuOss™ Collagen** — A natural bone substitute that promotes bone growth in both periodontal and maxillofacial defects. NuOss™ Collagen is made up of cancellous granules mixed with approximately 5% of bovine collagen. Once moistened the NuOss Collagen is moldable and can be placed in most defects.

#### Typical Uses:

- Ridge Augmentation
- Filling of infrabony periodontal defects
- Filling of extraction sockets
- Elevating the maxillary sinus floor
- Filling of peri-implant defects

ACE Surgical Supply Company, Inc. • 1034 Pearl Street, Brockton, MA 02301 • \*Mix and match, lowest priced item is FREE. All items must be on the same order.

Offer valid through October 31st, 2010. Call 1.800.441.3100 or order online @ [www.acesurgical.com](http://www.acesurgical.com)

800.441.3100

[www.acesurgical.com](http://www.acesurgical.com)



← **ii** page 2

with implant analogs, the hexed temporary cylinders were connected to the analogs and acrylic resin interim crowns were fabricated using a vacuum-formed template made over ideally shaped central incisors.

The resin interim crowns were seated and screwed onto the implants using hexed titanium screws with 20 Ncm torque. Cotton pellets were placed over the screw heads, and the access holes were sealed with composite resin.

Occlusal adjustment prevented functional contact upon excursions. The interim restorations did not fill the papillary space between #8 and #9 (Fig. 7). A radiograph taken following completion of provisionalization demonstrated satisfactory positioning and seating (Fig. 8).

**Gingivectomy over implants #8 and #9**

Healing of the implant sites proceeded without incident. At one week post-surgery, the buccal marginal tissue remained coronally-oriented and encroachment of the papilla into the unfilled interdental space began (Fig. 9). Three months after initial surgery, further coronal displacement and papilla fill occurred

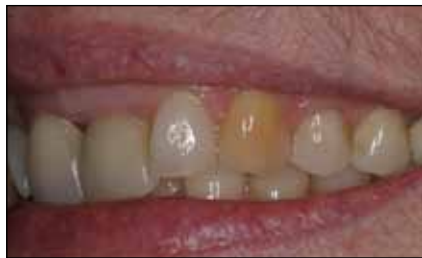

Fig. 1d: Left lateral initial smile view. Teeth #8 and #9 appear to be on a different occlusal plane. Attention is drawn to them.

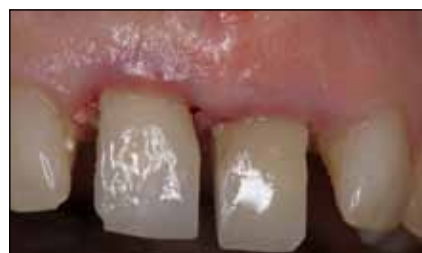

Fig. 2a: Contact points are broken and the crowns are removed. Trauma to the bone and adjacent teeth is to be avoided.

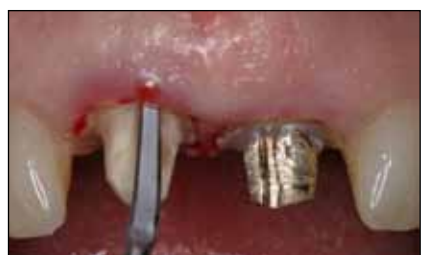

Fig. 2b: Following a sulcular incision, piezosurgery is used to atraumatically remove the teeth.

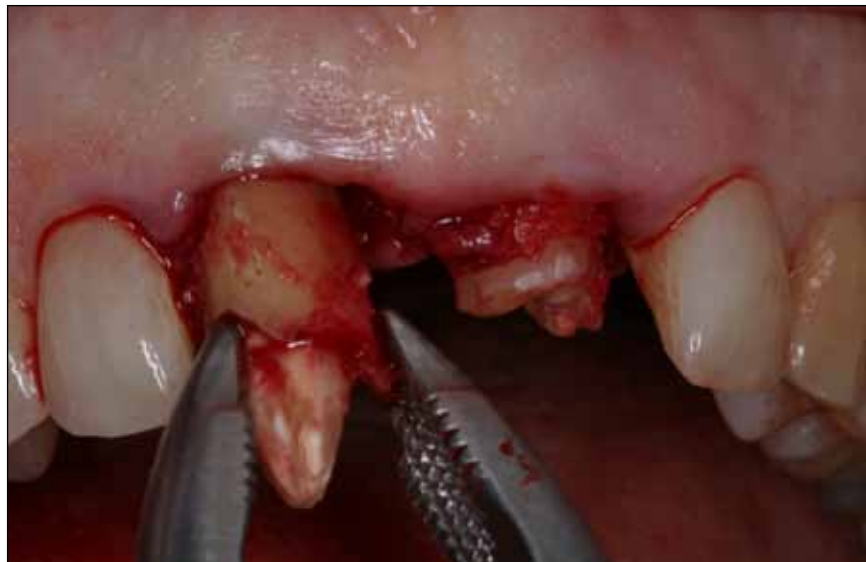

Fig. 2c: Utilizing beaked serrated forceps and rotational apical pressure, tooth #8 is removed without any destruction to the alveolar plate.

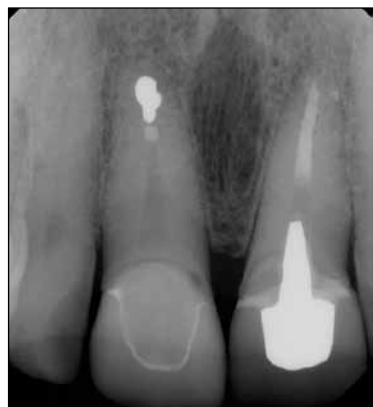

Fig. 1e: Initial radiograph. Teeth #8 and #9 are failing endodontically.

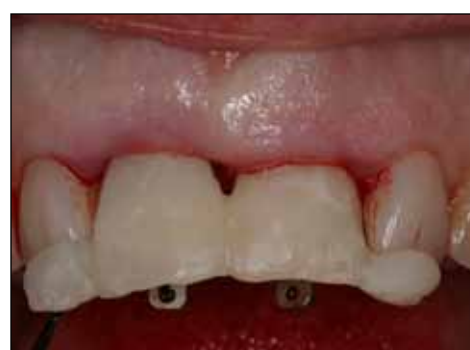

Fig. 3a: A surgical guide is used to ensure correct orientation during osteotomy preparation. Buccal view of the guide in place with orientation pins is shown.

→ **ii** page 6

AD



ANNUAL DENTAL TRIBUNE STUDY CLUB  
**SYMPOSIA AT THE GNYDM**  
NOVEMBER 28 – DECEMBER 1, 2010, 10:00 AM DAILY



For the third year in a row, the DTSC hosts its annual CE Symposia at the GNYDM, offering four days of focused lectures in various areas of dentistry.

**REGISTER NOW: WWW.GNYDM.COM**

**FREE ENTRANCE**  
EARN 20 C.E. CREDITS  
**20h CE**

**28 NOV**

10:00 - 11:00 Dr. Howard Glazer, DDS, FAGD  
**BEAUTIFIL: GO WITH THE FLOW**

11:20 - 12:20 Dr. John Flucke, DDS  
**LIGHT CURED ADHESIVE DENTISTRY - SCIENCE AND SUBSTANCE**

1:20 - 2:20 Dr. Martin Goldstein, DMD  
**A SIMPLIFIED APPROACH TO MULTI-LAYER DIRECT COMPOSITE BONDING**

2:40 - 3:40 Dr. Marius Steigmann, DMD  
**MY FIRST ESTHETIC IMPLANT CASE - WHY, HOW, & WHEN?**

4:00 - 5:00 Dr. Louis Malcmacher, DDS, MAGD  
**TOTAL FACIAL ESTHETICS FOR EVERY DENTAL PRACTICE**

**29 NOV**

10:00 - 11:00 Mrs. Noel Brandon-Kelsch  
**ECO-FRIENDLY INFECTION CONTROL-UNDERSTANDING THE BALANCE**

11:20 - 12:20 Dr. Derek Fine, DMD  
**CONE BEAM - AWARENESS IN THREE DIMENSIONS**

1:20 - 2:20 Various Speakers  
**OPTIMIZING YOUR PRACTICE WITH 3D CONE-BEAM TECHNOLOGY**

2:40 - 3:40 Dr. Daniel McEwen, DDS  
**HIGH RESOLUTION CONE BEAM WITH PREXION 3D**

4:00 - 5:00 Dr. Maria Ryan, DDS, PhD  
**DETECTING CORONARY HEART THROUGH PERIODONTITIS AND PERIIMPLANTITIS**

**30 NOV**

10:00 - 11:00 Dr. Fotinos Panagakos  
**DENTIN HYPERSENSITIVITY - NEW MANAGEMENT APPROACHES**

11:20 - 12:20 Dr. Jay Reznick, DMD, MD  
**3D IMAGING AND CT-GUIDED DENTAL IMPLANT SURGERY**

1:20 - 2:20 Dr. Dov Almog, DMD  
**INTRODUCTION TO CONE BEAM CT (CBCT), ESPECIALLY AS IT PERTAINS TO PREVENTION OF FAILURES IN ORAL IMPLANTOLOGY**

2:30 - 3:30 Dr. Maria Ryan, DDS, PhD  
**DETECTING CORONARY HEART THROUGH PERIODONTITIS AND PERIIMPLANTITIS**

4:00 - 5:00 Dr. Dwayne Karateew, DDS  
**CONTEMPORARY CONCEPTS IN TOOTH RELACEMENT: PARADIGM SHIFT**

**1 DEC**

10:00 - 11:00 Mr. Al Dube  
**MERCURY AMALGAM WASTE AND OSHA AND REGULATORY ISSUES AFFECTING DENTISTS**

11:20 - 12:20 Dr. Glenn van As  
**AN INTRODUCTION TO DIODE LASERS: TOP 10 PROCEDURES YOU CAN DO WITH YOUR DIODE LASER**

1:00 - 4:30 Various Speakers  
**REVOLUTIONARY IMPLANT DESIGN UNVEILED**

PLEASE SEE FURTHER PROGRAM AND SPEAKER DETAILS UNDER [WWW.DTSTUDYCLUB.COM/GNYDM](http://WWW.DTSTUDYCLUB.COM/GNYDM)





APPROACH DENTURES FROM A UNIQUE ANGLE



## ERA Mini™ Dental Implant System

*Zimmer Dental – the worldwide exclusive distributor of the ERA Mini Dental Implant System and related products.*

*The ERA Mini Dental Implant System offers the life-improving benefits of denture stabilization with the capability to correct implant misangulation.*



### EASY TO USE

- Enables uncomplicated, minimally invasive, chair-side procedures in as little as one visit



### RESILIENT

- Provides vertical resiliency, helping to reduce load transmission to implants<sup>1</sup>



### AFFORDABLE

- Low-cost denture stabilization

To learn more about the **ERA Mini Dental Implant System** please visit us online at [www.zimmerdental.com](http://www.zimmerdental.com) or to speak to a sales representative call **1 (800) 854-7019**.

To receive our eNews visit us at [www.zimmerdental.com/news\\_eNewsLetterSignUp.aspx](http://www.zimmerdental.com/news_eNewsLetterSignUp.aspx)



[www.zimmerdental.com](http://www.zimmerdental.com)



← **T** page 4

(Fig. 10).

Minor gingivectomy was performed to create mucosal symmetry between the maxillary central incisors. The contact point and contour of the interim crowns were also adjusted to create a fuller papilla.

**Final restoration of implants #8 and #9**

Six months after gingivectomy and provisional contour modification, the implants were ready for final prostheses (Fig. 11). Single final PFM crowns were placed on implants #8 and #9. Clinical analysis demonstrated resolution of inflammation,

→ **T** page 9

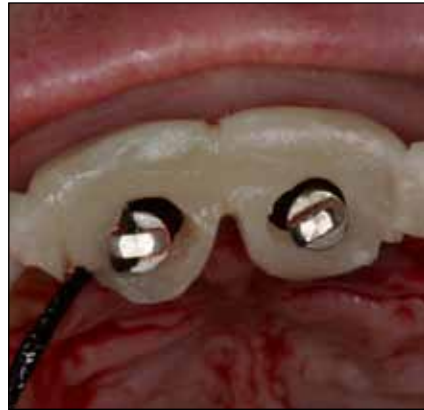

Fig. 3b: Occlusal view of the surgical guide in place. Note that the osteotomy is located at the cingulum position, the preferred site for a screw-retained restoration. Notice too the occlusal wings on the guide that stabilize its position on adjacent teeth during surgical preparation.

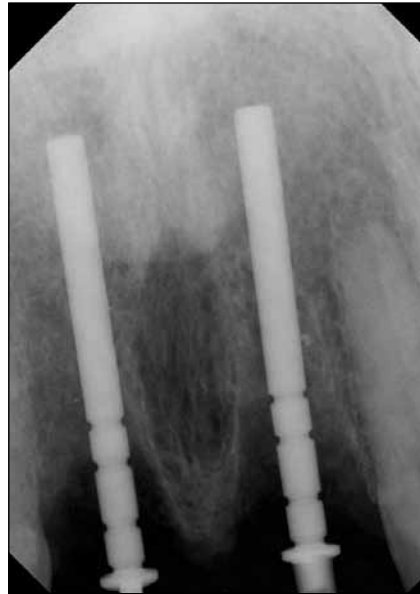

Fig. 3c: Initial osteotomy orientation confirmed by radiograph.

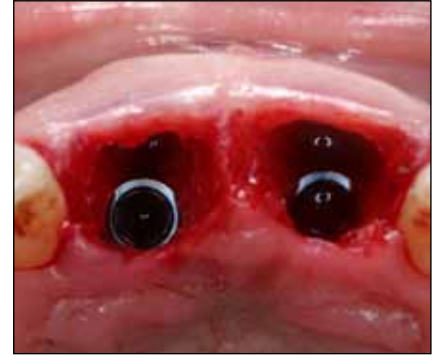


Fig. 4: Occlusal view following placement of two 4 mm-diameter dental implants. Note the palatal position and the thickness of the buccal plate. A gap is present between the labial aspect of the implant and the facial plate. This will be grafted.

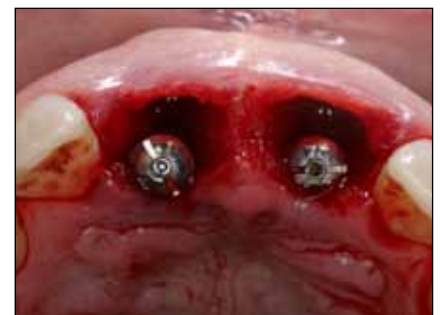

Fig. 5a: Temporary healing abutments in place. They prevent soft-tissue and bony collapse while the provisional restoration is being fabricated extra-orally.

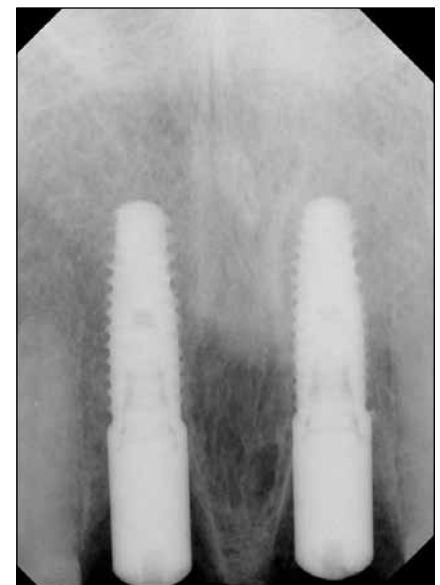


Fig. 5b: Radiograph of implants in place with temporary healing abutments. Note peak of bone between the implants.

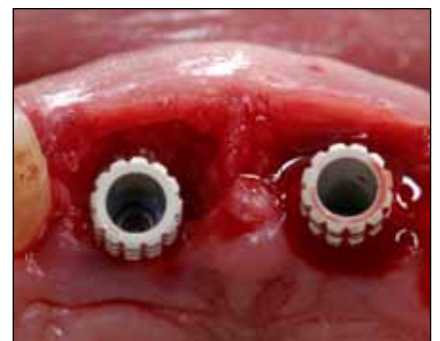
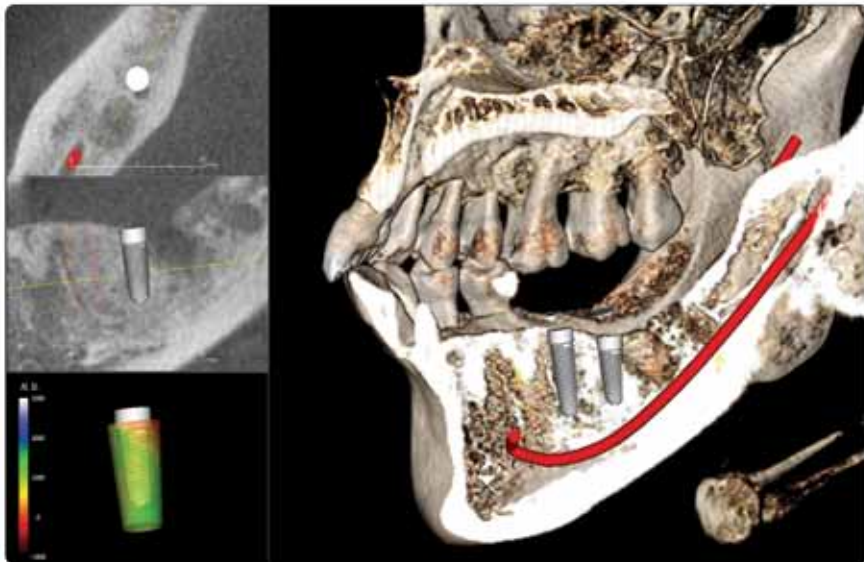


Fig. 6a: Occlusal view of temporary cylinders. Note ideal positioning for both function and esthetics. Occlusal forces are directed along the long axis of the implants. Implants are also positioned palatally, which will allow for ideal sculpting of the tissue with the provisional.

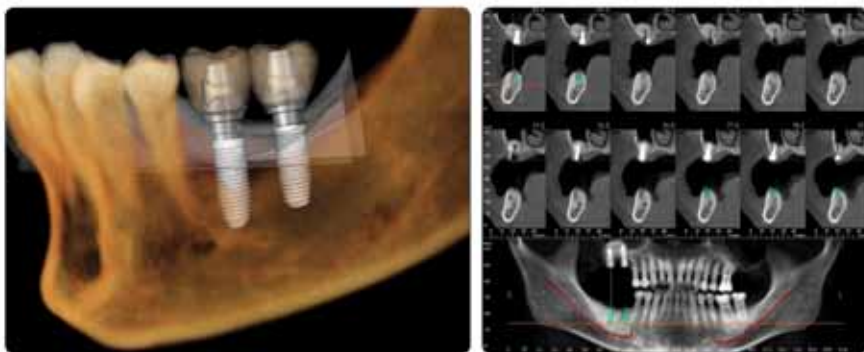
AD

**Implant Planning in 20 Seconds**  
with **Invivo5**



**High quality 3D Implant planning system from CA, USA.**

- Extremely fast and easy
- High quality and accurate visualizations
- No conversion, pre-processing, or preparation
- Software developed from Silicon Valley, California
- Surgical Guide made from California
- Expert support provided from California



Find out why so many doctors choose Invivo5. Call for a demonstration today!



www.anatomage.com Tel. 408-885-1474 Fax 408-295-9786 111 N. Market St. #800 San Jose, CA 95113

*Anatomage*

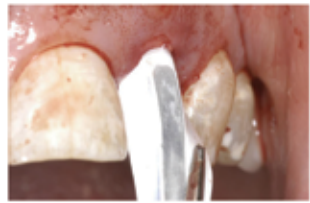

# PRESERVE BONY ARCHITECTURE IN COMPROMISED EXTRACTION SITES

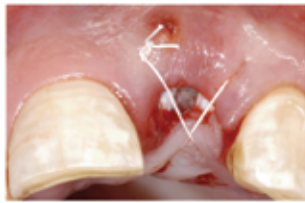Visit Osteogenics Biomedical at AAOMS Booth #1132 to learn more and receive special show pricing.

Extraction sites with deficient structural support (ex. buccal defects) often require **tenting membranes to prevent collapse into the defect**. In these cases, titanium-reinforced membranes help reshape the site to the original dimensions of the ridge. Although primary closure may be obtained, Cytoplast® titanium-reinforced membranes are designed to withstand exposure and prevent bacterial penetration<sup>1, 2, 3</sup>, making them especially well-suited for extraction site reconstruction.

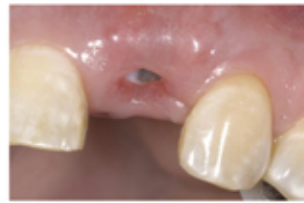1. Fotek PD, Neiva RF, Wang HL. Comparison of dermal matrix and Polytetrafluoroethylene membrane for socket bone augmentation. J Periodontol 2009;80:776-785 2. Hoffman O, Bartee BK, Beaumont C, Kasaj A, Deli G, Zafiroopoulos GG. Alveolar bone preservation in extraction sockets using non-resorbable dPTFE membranes: A retrospective non-randomized study. J Periodontol 2008;79:1355-1369 3. Barber HD, Lingnelli J, Smith BM, Bartee BK. Using a dense PTFE membrane without primary closure to achieve bone and tissue regeneration. J Oral Maxillofac Surg 2007;65:748-752



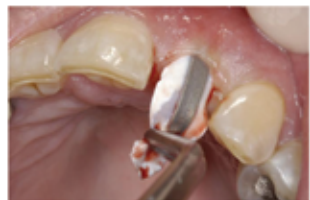Due to a vertical root fracture, the entire buccal plate is missing. The titanium-reinforcement of the Cytoplast® Ti-250 Anterior Narrow allows easy placement and maintenance of space.



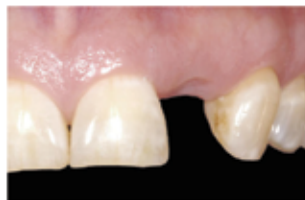The dense PTFE membrane has a pore size of <math><0.3\mu\text{m}</math>, making it occlusive to both soft tissue cells AND bacteria. Primary closure is not necessary.



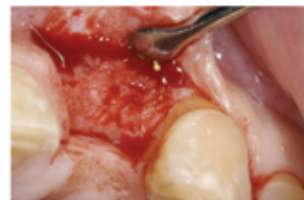At two weeks, healing over the membrane is excellent – no inflammatory response and infection-free.



Because the membrane is left exposed, a non-surgical removal requires only topical anesthetic after 4 weeks of healing.



Two weeks after removal of the membrane, soft tissue has re-epithelialized over the socket. Soft tissue contours are preserved.



Re-entry at 4 months shows regeneration of the ridge to its original dimensions. Implants may now be placed in an optimal location.

## Extraction Site Grafting Configurations

Shown actual size.



12 mm x 20 mm

### Cytoplast® Ti-250 Anterior Narrow

Ideal for narrow single-tooth extraction sites, especially where one or more bony walls are missing.



14 mm x 24 mm

### Cytoplast® Ti-250 Anterior Singles

Ideal for single-tooth extraction sites, especially where one or more bony walls are missing.



17 mm x 25 mm

### Cytoplast® Ti-250 Buccal

For grafting large buccal defects.



20 mm x 25 mm

### Cytoplast® Ti-250 Posterior Singles

For grafting posterior extraction sites and limited ridge augmentation.

## DISCOVER WHY SO MANY SPECIALISTS RELY ON CYTOPLAST® TI-250 TITANIUM-REINFORCED MEMBRANES

“This membrane exhibits the least amount of post operative inflammatory tissue response, if any, and is easy to keep clean...even if a large portion is exposed. They almost maintain themselves, and if they don't self exfoliate, they are easy to slide out. Best of all, the bone forms where you want it to be!”  
*Robert Gorzelnik, DDS, Oral & Maxillofacial*

“I have had excellent results in reconstruction of labial and buccal wall defects with the Cytoplast® titanium-reinforced membrane. No other procedure gives me the same predictable results.”  
*John Sisto, DDS, Oral & Maxillofacial Surgeon*

“This is a very high quality product that consistently produces predictable results in my practice. It is a product any implant surgeon should consider in their armamentarium.”  
*David H. Gilbert, DDS, MS, Oral & Maxillofacial Surgeon*

“I use your membrane for all of my immediate extraction/immediate placement implants. I am getting predictable results. The time saved is another bonus.”  
*Charles C. Chen, DDS, Periodontist*

“In my experience, this membrane may be the best on the market currently for treatment of the severely resorbed extraction socket. It provides predictable space maintenance, excellent bone regeneration potential, and all while extremely tolerant to exposure.”  
*Matt Heaton, DDS, MS, Periodontist*



# REGISTER FOR

## The Future of Dentistry

*What's In, What's Out: Materials and Methods to Keep You on the Cutting Edge*

**EXIT 1A**

**Complacency**  
This Lane  
**Achievers**  
Merge Right



**MOTIVATION  
SOLUTIONS  
SUCCESS**

This EXIT   
10 Miles  
25 Miles

Just because the economy is unstable does not mean that your practice has to be.

**LVI will steer you in the right direction!**

Now is the time to take the driver's seat and invest in yourself and your future.

Recession-proof your practice with an education from LVI.

Bring a new enthusiasm to yourself, your practice, your team, and your patients!

You can have the practice of your dreams, and we can show you how.

Rohnert Part, CA	September 24-25	Toronto, ON	October 15-16	Carlsbad, CA	November 12-13
Calgary, AB	September 24-25	Palo Alto, CA	October 15-16	Pittsburgh, PA	November 19-20
Lincolnshire, IL	September 24-25	San Diego, CA	October 15-16	Seattle, WA	November 19-20
Portland, OR	September 24-25	Stockton, CA	October 22-23	Kitchener, ON	November 26-27
Hilton Head, SC	September 24-25	Moncton, NB	October 22-23	<b>2011 Events</b>	
Sudbury, ON	October 1-2	Littleton, CO	October 22-23	Houston, TX	February 4-5
Edmonton, AB	October 1-2	Madison, WI	October 22-23	Park City, UT	February 11-12
Omaha, NE	October 1-2	Kansas City, MO	October 29-30	Lubbock, TX	March 4-5
Sioux Falls, SD	October 8-9	Minneapolis, MN	November 5-6	Shreveport, LA	April 1-2

LVI is bringing 11 CE credits TO YOU with  
The Future of Dentistry in your area!

For complete details visit [www.LVIRegionalEvents.com](http://www.LVIRegionalEvents.com)

No Interest Tuition Financing Available Through  | CHASE 

If paid in full within the promotion period of 12 months. Interest will be charged to your account from the purchase if the balance is not paid in full within the promotional period 12 months, if you make a late payment, or if you are otherwise in default.


**ADA CERP**® | Continuing Education  
Recognition Program

LVI Global is an ADA CERP Recognized Provider. ADA CERP is a service of the American Dental Association to assist dental professionals in identifying quality providers of continuing dental education. ADA CERP does not approve or endorse individual courses or instructors, nor does it imply acceptance of credit hours by boards of dentistry. LVI Global designates this activity for 11 continuing education credits.



CHANGING DENTISTRY. CHANGING LIVES.

Sponsored by



Academy of General Dentistry  
Approved PACE Program Provider  
FAGD/MAGD Credit  
6/1/2007 to 5/31/2011

Check with your provider to see which plans are available. Available for purchases of \$1,000.00 or more. Interest will accrue during the promotional period at an APR of 24.75% to 27.99% (depending on creditworthiness). Your actual APR will be stated at the time of purchase. A Penalty Rate of 29.99% will be applicable if your minimum payment is not received within 60 days of the due date if stated at the time of purchase. Due Date Change Fee \$15. Minimum finance charge \$5.00. See your Purchase Acknowledgement and ChaseHealthAdvance Revolving Account Agreement for more information about this Promotion. Please read that material carefully.



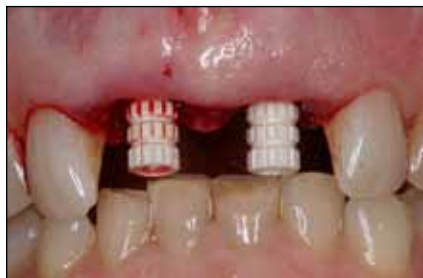

Fig. 6b: Facial view of temporary cylinders.

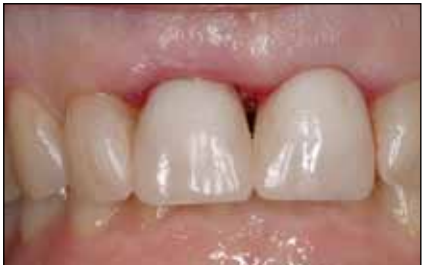

Fig. 7: Provisional restoration immediately following reline and placement. Papilla is not present.

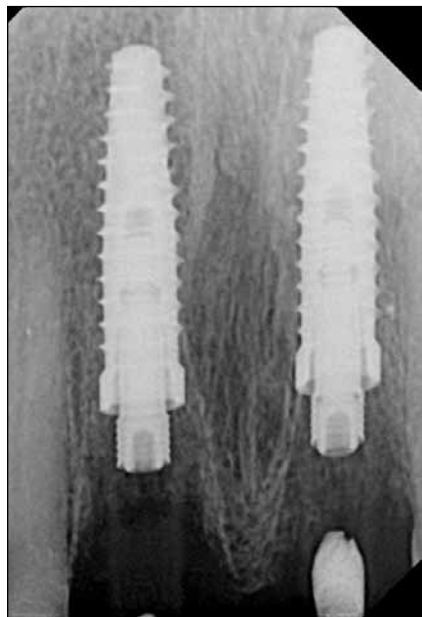


Fig. 8: Radiograph the day of implant placement.

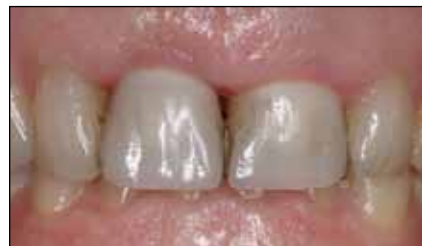

Fig. 9: Provisional restoration one week post-implantation. Very good soft-tissue healing and minimal recession.

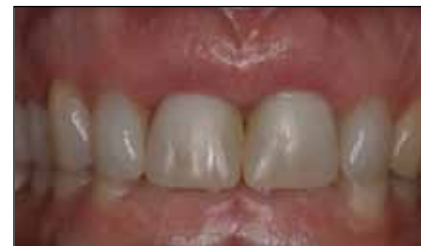

Fig. 11: Provisional restoration at six months after gingivectomy and adjustment of interim crown contours.

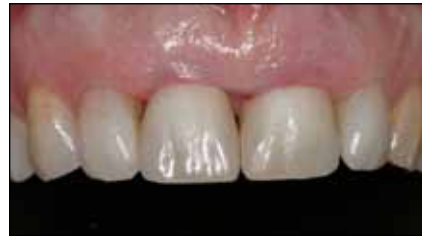

Fig. 10: Provisional restoration three months post-implantation.

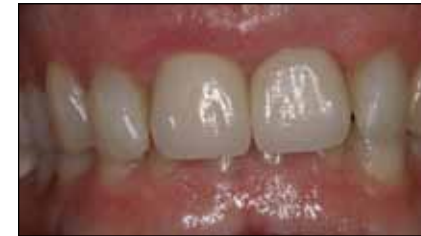

Fig. 12a: Final #8 and #9 implant restorations.

← [page 6](#)

idealization of the soft-tissue drape and papillary regeneration (Fig. 12).

A radiograph illustrated preservation of interproximal and peri-implant bone (Fig. 13). The patient was satisfied with the functional and esthetic results (Fig. 14).

**Post-operative instructions**

After each surgical procedure, the patient was instructed to take ibuprofen 600 mg q4-6 hours, hydrocodone 7.5 mg/acetaminophen 750 mg q4-6 hours prn pain and doxycycline

→ [page 10](#)

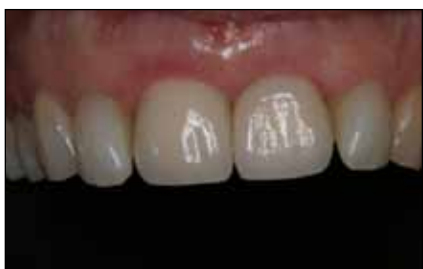

Fig. 12b: Close-up view of final restoration.

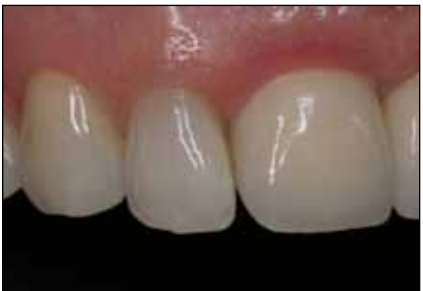

Fig. 12c: Right lateral final view.

AD

# SurgiGuide®

Now there's a solution for every implant case

From **\$275!**  
\*\$250 per implant

**What I'm thinking about?**

- Computer guided surgery at an economic price
- Precision support for anatomically restricted cases
- Drill and implant guidance with depth control
- Flexibility – to continue using my preferred implant brands
- Natural looking top esthetic results
- My patient leaving surgery with a new smile

Email us today to receive your free brochure! [simplant@materialise.be](mailto:simplant@materialise.be)

Your SimPlant® 3D treatment plan turned reality

\* Sales tax will apply where applicable

simple    compatible    unique

[www.materialisedental.com](http://www.materialisedental.com)

Looking for more dental news?

See [www.dental-tribune.com](http://www.dental-tribune.com) for dental news and much more