

cosmetic dentistry

_ beauty & science

1²⁰¹¹

| **clinical technique**

Reattachment and build-up of fractured maxillary central incisors

| **case report**

Laser-assisted cosmetic dentistry

| **industry report**

CLEARFIL SA CEMENT—
Easy to remove, hard to forget!

kuraray

0277113

Strength *of a Hybrid ...*

... Deliver *like a flow*

BEAUTIFIL Flow Plus

Yet another milestone in the Giomer family of restoratives, **BEAUTIFIL Flow Plus** is an injectable hybrid aesthetic restorative that exhibits superior strength, durability and aesthetics for enhanced applications in direct cosmetic dentistry.

The Plus benefits for you ■■■

- Ideal density and stackability for effortless sculpting
- Remarkable mechanical properties
- Easy injectable delivery
- Extensive application capabilities including load-bearing surfaces
- Simulates life-like aesthetics with excellent shade match
- Benefits of fluoride with anti-plaque effect

Official Partner



Minimally Invasive
Cosmetic Dentistry

*For further information, contact your Shofu dealer
TODAY!*



SHOFU INC.

Singapore Branch 10 Science Park Road, #03-12 The Alpha, Science Park II, Singapore 117684
Tel: 65-6377 2722 Fax: 65-6377 1121 eMail: mailbx@shofu.com.sg www.shofu.com.sg

Dear Reader,

_Welcome to this year's first edition of **cosmetic dentistry**!

As we all know, the American Dental Association (ADA) has played an important role in dentistry not only in America, but also worldwide. On 13 October 2010, Dr Raymond Gist was installed as the 147th President of the ADA. Dr Gist made ADA history as the first African-American President to serve in this role. In a recent interview, Dr Gist stated: "I am looking forward to continuing to create a history that will be embraced [...] I see nothing but positives for the future of dentistry."

Likewise, I see many positives for the future of aesthetic/cosmetic dentistry. For the past two decades, aesthetic dentistry has been well led by the International Federation of Esthetic Dentistry (IFED). IFED's ultimate purpose has been to contribute to the progress and development of worldwide aesthetics and oral health and to enhance communication between all member academies. Amongst IFED members are the Asian Academy of Aesthetic Dentistry, Japan Academy of Esthetic Dentistry, Korean Academy of Esthetic Dentistry, Taiwan Academy of Aesthetic Dentistry, and Indian Academy of Aesthetic and Cosmetic Dentistry. Personally, I hope more Asia-Pacific countries such as China, Singapore, Thailand, Nepal, Sri Lanka, Australia and New Zealand will join the Federation to contribute to dentistry and enhance communication worldwide.

In February, Dr Dan Nathanson (USA) passed the IFED Presidency to Dr José Moura (Brazil) with a new executive committee of nine members. Amongst the current executive committee members, Dr Akira Senda (Japan) and Dr Sushil Koirala (Nepal) will be representing Asia.

I am sure that this edition of **cosmetic dentistry** will meet your expectations in seeking critical clinical tips to improve on your everyday clinical work especially in the area of bonding in the aesthetic zone. Please send your invaluable feedback and participate in improving our journal's quality to the highest level of excellence.

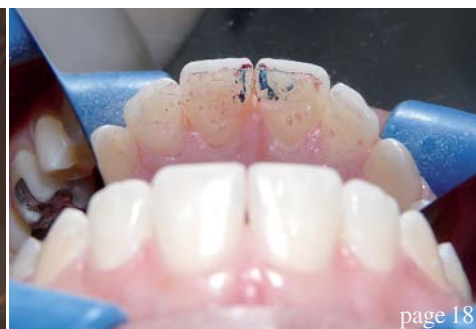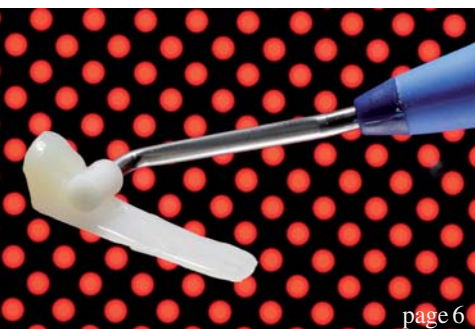
Yours faithfully,



Dr So-Ran Kwon
Co-Editor-in-Chief
President, Korean Bleaching Society
Seoul, Korea



Dr So-Ran Kwon
Co-Editor-in-Chief



| editorial

- 03 **Dear Reader**
| Dr So-Ran Kwon, Co-Editor-in-Chief

| clinical technique

- 06 **Reattachment and build-up** of fractured maxillary central incisors
| Dr Irfan Ahmad

| case report

- 14 **Laser-assisted** cosmetic dentistry—A case report
| Dr Hugh Flax
- 18 **Integration of aesthetics and function** with composite resins
| Dr Rony Hidalgo Lostanau *et al.*
- 20 **Restoring missing mandibular incisors with implants**—What makes you hesitate?
| Dr Chonghwa Kim & Sangwoo Lee

| feature

- 26 **An interview with Dr José Roberto Moura, IFED President**
- 28 **An interview with Olaf Sauerbier, CEO of VOCO GmbH**

| MICD

- 30 **The Inman Aligner**—Alignment, bleaching, bonding: **A progressive approach to smile design** (Part II)
| Dr Tif Qureshi

| industry report

- 36 **CLEARFIL SA CEMENT**—Easy to remove, hard to forget!
| Dr Jürgen Garlachs
- 42 **Aesthetic restoration** created with composite
| Dr Anna Salat Vendrell
- 44 **Class II fillings** in everyday clinical work
| Dr Sylvain Mareschi

| industry news

- 46 **Lithium disilicate** meets **zirconium oxide**
| Ivoclar Vivadent

| meetings

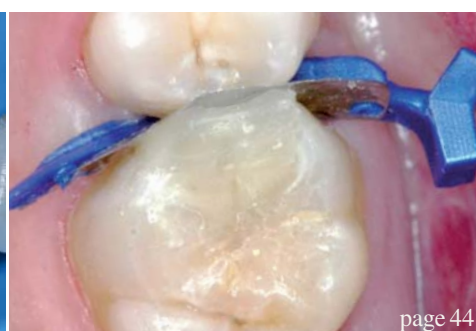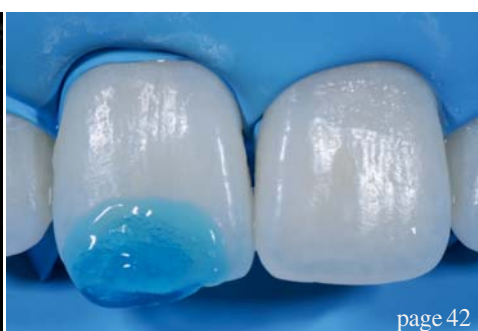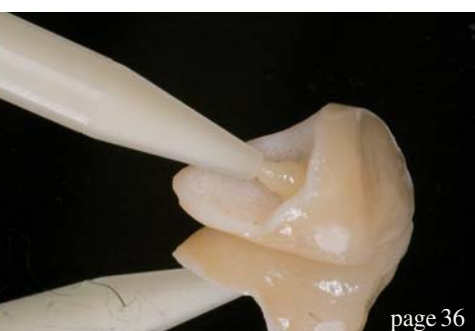- 48 **International Events**

| about the publisher

- 49 | submission guidelines
- 50 | imprint



Cover image courtesy of Kuraray Europe GmbH, www.kuraray-dental.eu.

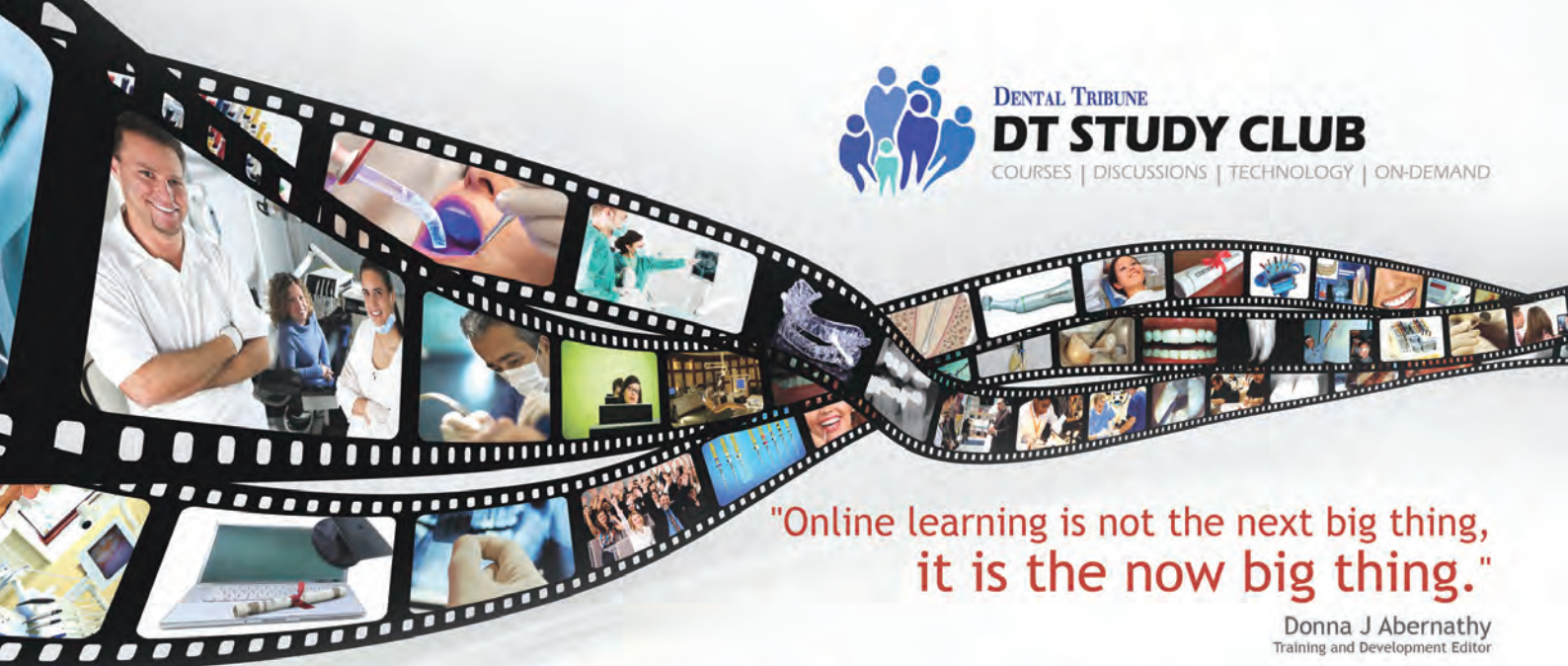



DENTAL TRIBUNE

DT STUDY CLUB

COURSES | DISCUSSIONS | TECHNOLOGY | ON-DEMAND



**"Online learning is not the next big thing,
it is the now big thing."**

Donna J Abernathy
Training and Development Editor

DTSC - COURSES, COMMUNITY, TECHNOLOGY, ON-DEMAND

The DT Study Club makes all of this possible from the comfort of your own computer and without travel expenses. In other words, welcome to the community!

The purpose of this study club is to provide practitioners like yourself an opportunity to learn and network with like-minded colleagues in a friendly, non-threatening environment. We encourage you to take advantage of Dental Tribune's global outreach to access a variety of fresh perspectives and cultures, enhancing your educational mix.

24/7 LIVE AND INTERACTIVE ONLINE COURSES

Fulfill your yearly CE requirements with our growing list of archived ADA CERP approved courses.



DISCUSSION FORUMS

focused on helping today's practitioners to stay up to date. Networking possibilities that go beyond borders to create a truly Global Dental Village



VIDEO REVIEWS OF PRODUCTS

Our opinion leaders unveil new products, services, and give you their first impressions of the industry's hottest topics.



PEER REVIEWED CASE STUDIES

Upload, comment, participate. We encourage you to share your cases for review with like-minded practitioners.



 REGISTER FOR FREE ON WWW.DTSTUDYCLUB.COM

CONTESTS WITH CHANCES TO WIN FREE TUITION FOR ADA/CERP C.E. ACCREDITED WEBINARS

SPONSORSHIP AND SPEAKING INQUIRIES:
JULIA WEHKAMP, J.WEHKAMP@DTSTUDYCLUB.COM, (416) 907-9836.

ADACERP
CONTINUING EDUCATION RECOGNITION PROGRAM



PRACTICE MANAGEMENT



GENERAL DENTISTRY



COSMETICS



ENDODONTICS



IMPLANTOLOGY



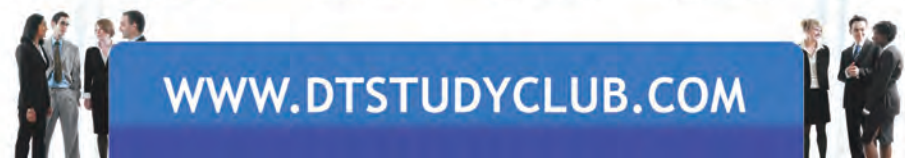PERIODONTICS



ORTHODONTICS



DENTAL HYGIENE



WWW.DTSTUDYCLUB.COM

Reattachment and build-up of fractured maxillary central incisors

Author_ Dr Irfan Ahmad, UK

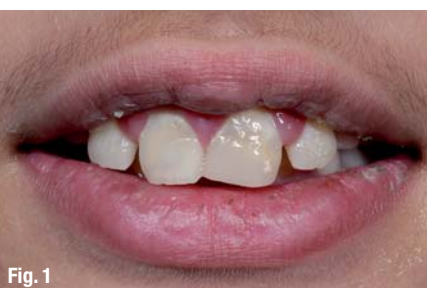

Fig. 1

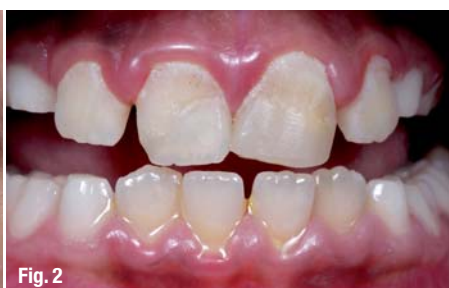

Fig. 2

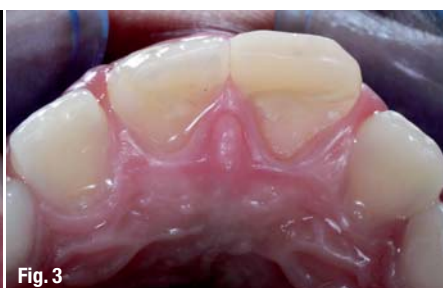

Fig. 3

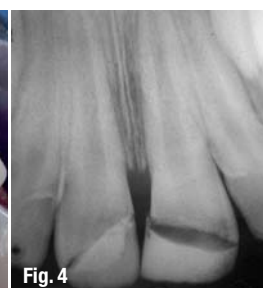


Fig. 4

Fig. 1 _Dentofacial view, showing immediate treatment of the two maxillary central incisors, following a sporting accident.

Fig. 2 _Pre-op status, showing extensive plaque deposits, acute gingivitis, reattachment of the coronal fragment on the right central incisor and a defective composite build-up on the left central incisor.

Fig. 3 _Incisal pre-op view, showing the reattached right fragment on the right central incisor and an over-contoured composite build-up on the left central incisor.

Fig. 4 _Peri-apical radiograph, showing large defects between the composite resin fillings and remaining tooth substrate, with large pulp chambers and immature, open apices.

Figs. 5-7 _Post-scaling and polishing, showing improvement of gingival

_Acute dental trauma of anterior teeth is a common occurrence in children under the age of 12. The most frequently fractured teeth are the maxillary incisors, involving solely enamel, enamel and dentine or, in extreme cases, pulpal exposure, very often without root fractures. Unlike the relatively slow tooth loss due to dental caries or tooth wear, acute dental trauma is an immediate, often painful loss of natural tooth substrate. Furthermore, involvement of the pulp complicates initial and long-term treatment, placing the affected teeth in jeopardy and requiring periodic monitoring.

The sequential treatment strategy for acute dental trauma is restoring health (H), followed by function (F) and lastly, achieving acceptable aesthetics (A); the HFA triad. Contemporary dental composites and direct adhesive techniques allow replication of the tooth morphology, as well as optical (colour, translucency, opalescence, fluorescence) and mechanical properties.

The advantage of a direct approach is that it is minimally invasive, not requiring additional removal of tooth substrate; however, it is technique sensitive, requiring patience and meticulous execution.

_Clinical case

A ten-year-old boy was involved in a sporting accident that resulted in acute dental trauma to the maxillary central incisors. The fractured fragment of the left central incisor was lost, while that on the right central incisor was located. The patient was treated at the accident and emergency department of a local hospital, where tetanus inoculation was verified and composite resin used to reattach the right central incisor fragment and to build-up the left central incisor (Figs. 1-3).

The patient presented to my practice a few weeks later, complaining of poor aesthetics and

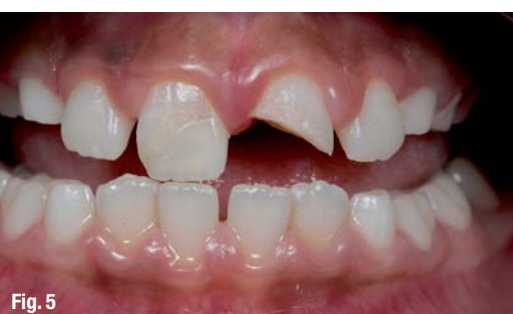

Fig. 5

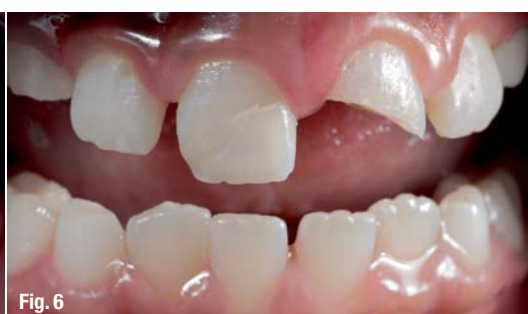

Fig. 6

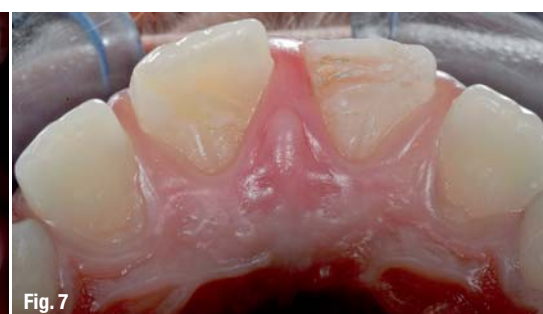

Fig. 7

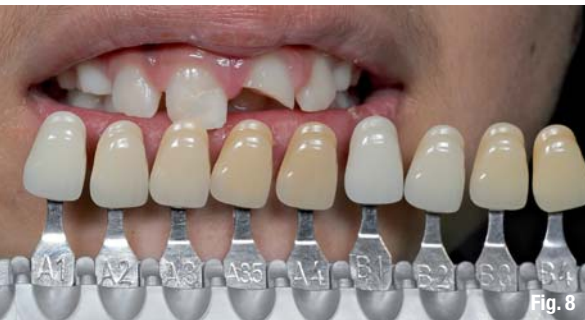

Fig. 8

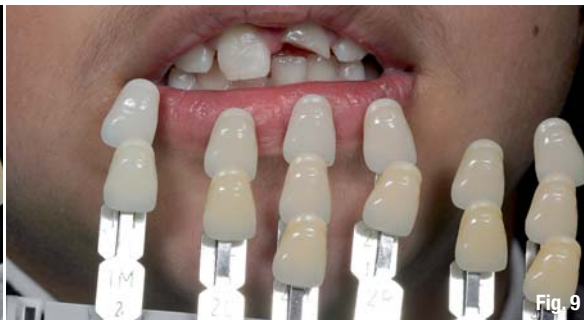

Fig. 9



Fig. 10

a dull ache in the buccal sulcus above the left central incisor. Intra-oral examination revealed poor contours of the composite fillings, with incorrect colour and texture. In addition, the patient's oral hygiene was unsatisfactory, with extensive plaque and calculus deposits causing acute gingivitis. The left central incisor was sensitive to gentle percussion, as well as to hot and cold stimuli.

Radiographs showed substantial defects between the composite filling and remaining tooth substrate, allowing ingress of oral pathogens (Fig. 4). The periodontal ligament was intact, no root fractures were evident and a typical solid cortical bone appearance, consistent with an acute dental trauma, was apparent.

Initial therapy

Before considering definitive treatment, the initial items requiring attention are the periodontal and endodontic status. Assessing the endodontic condition following acute trauma is essential for treatment planning. Following an accident, the patient is distressed, anxious and mentally traumatised. In addition, the shock of the physical trauma often results in a transient anaesthesia or paraesthesia of the pulpal neural fibres.

For these reasons, assessing pulp vitality with thermal or electrical stimuli, which are highly subjective, yields unreliable results. In addition, a false-negative result is often obtained with traumatised teeth owing to the transient

paraesthesia of nerve fibres. Conversely, a false-positive result is elicited when necrosis of the pulpal vascular tissues has occurred, leaving vital nerve fibres, which are more resilient. This may delay diagnosis and treatment of the affected tooth, often leading to root absorption.

A reliable and objective method for determining pulp vitality is pulse oximetry. Pulse oximetry measures the blood oxygen saturation levels or circulation within the pulp. The pulse oximeter consists of light-emitting diodes (LED) of two wavelengths (red light – 640 nm and infrared light – 940 nm) and a receptor for recording the spectral absorbance of the oxygenated and deoxygenated haemoglobin in the tooth pulp. A computer calculates the percentage of oxygen saturation levels, which is approximately 75 to 80 % for vital teeth, compared to values at the fingers or ear lobes of 98 %. The tooth oxygen saturation levels are lower than soft tissues of the body owing to the dentine and enamel, which scatters the LED light. A reading of 78 % was obtained for this patient, indicating that there was adequate vascularity for eventual regeneration of the pulp. At this stage, root-canal therapy was not necessary.

In order to resolve the acute gingivitis, the teeth were scaled and polished, and the patient counselled about home oral-hygiene procedures. Impressions for the diagnostic wax-up were delayed until gingival health had improved.

health and detachment of the defective composite build-up on the left central incisor. Notice the clearly visible dentine mamelons and incisal edge lobes of the reattached fragment on the right central incisor.

Fig. 8_Dento-facial view with VITA Classic shade guide.

Fig. 9_Dento-facial view with VITA 3D Shade Guide.

Fig. 10_Photograph of patient before the sporting injury. Notice the blatant maxillary midline diastema.

Fig. 11_A large overjet of 7 mm, making the maxillary incisors vulnerable to external trauma.

Fig. 12_Facial view of pre-op plaster model.

Fig. 13_Incisal view of pre-op plaster model.




Fig. 11

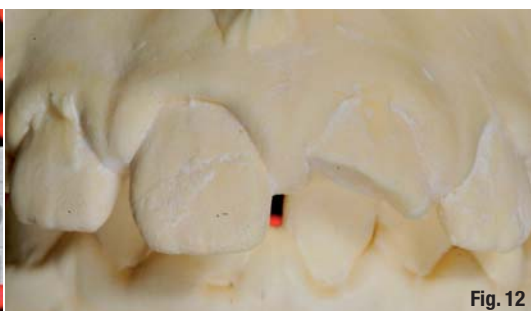

Fig. 12



Fig. 13

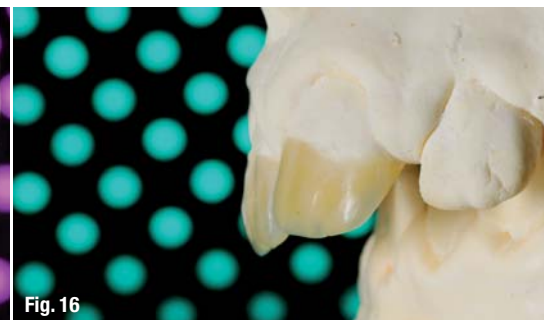
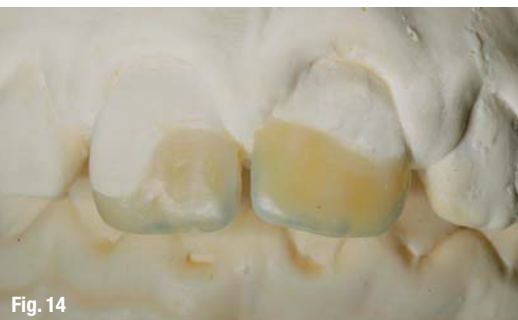
Fig. 14 _Facial view of diagnostic wax-up.

Fig. 15 _Right lateral view of diagnostic wax-up.

Fig. 16 _Left lateral view of diagnostic wax-up.

_Diagnostic wax-up and silicone index

At the next appointment the following week, the gingivitis had resolved but the composite build-up on the left central incisor had detached from the remaining tooth substrate (Figs. 5–7). In order to prevent sensitivity and bacterial invasion, the exposed dentine on the left central incisor was etched with 37% phosphoric acid for 20 seconds and immediately sealed with a dentine-bonding agent (OptiBond Solo Plus, Kerr). The gingival condition had improved following prophylaxis and oral-hygiene instruction, and upper and lower impressions were taken using an accurate, soft, distortion-free material (AlgiNot FS, Kerr). Concurrently, reference photographs were taken with VITA Classic and VITA 3D Shade Guides (VITA) for shade analysis (Figs. 8 & 9).

The impressions were cast with hard plaster for the diagnostic wax-up. The patient was asked to supply photographs of his teeth prior to the accident (Fig. 10), which are an invaluable guide for assessing tooth anatomy and for guiding the dental technician during the wax-up process. The patient displayed a large overjet of 7 mm, which obviously places the central incisors in a precarious situation, highly susceptible to traumatic injury (Fig. 11).

In the dental laboratory, the preoperative models of the fractured incisors were waxed-up to the proposed facial and palatal morphology (Figs. 12–17). An index was fabricated, using a heavy body, addition silicone impression ma-

terial and sectioned at the incisal edge, ensuring that a ledge was present at the incisal edge to support the intra-oral composite build-up (Figs. 18 & 19).

_Composite build-up on the left central incisor

Choice of composite

The two basic criteria for selecting an appropriate composite filling material are satisfaction of function (resilience, mechanical and thermal properties) and aesthetics (replicating enamel, dentine and characteristics such as translucency, opalescence and fluorescence). In this instance, the new Herculite XRV Ultra (Kerr) was chosen for its superior mechanical and optical properties. Herculite XRV Ultra is a nano-hybrid composite, updated from its predecessor Herculite XRV, which was introduced over two decades ago.

The endearing feature of nano-composites is the very small particle size of the filler, 25 to 75 nm smaller than in micro-hybrids. The reduced filler size particles confers superior aesthetics by allowing excellent surface gloss after polishing, as well as advantageous optical properties, such as opalescence and fluorescence. In addition, Herculite XRV Ultra offers favourable wear resistance, compressive strength, fracture toughness and flexural strength with good adaptability, sculptability and thixotropic properties. Furthermore, it is available in a large range of enamel, dentine and incisal shades for

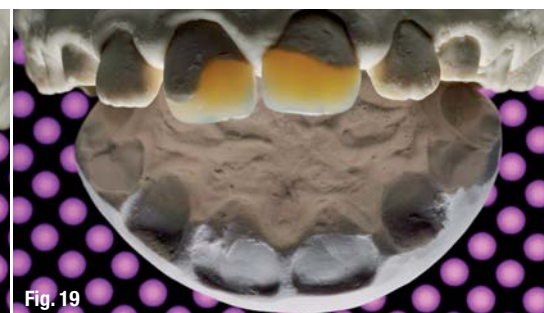
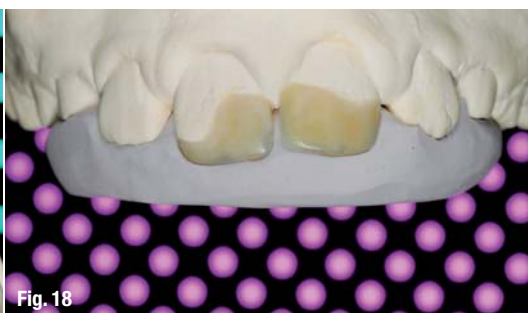
Fig. 17 _Incisal view of diagnostic wax-up.

Fig. 18 _Facial view of diagnostic wax-up with silicone index *in situ*.

Fig. 19 _Facial view of diagnostic wax-up and palatal aspect of silicone index, showing the palatal anatomy with incisal ledge to support the intra-oral composite build-up.

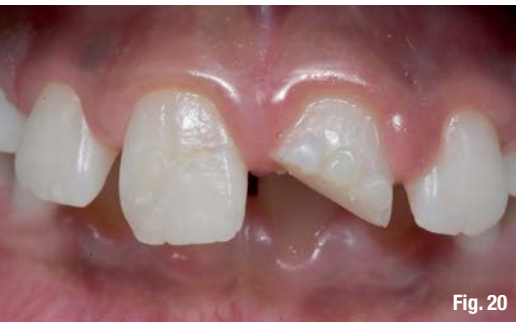

Fig. 20

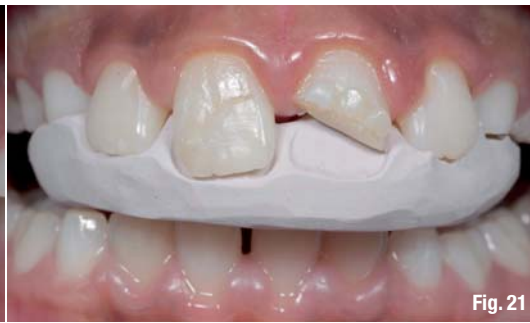

Fig. 21

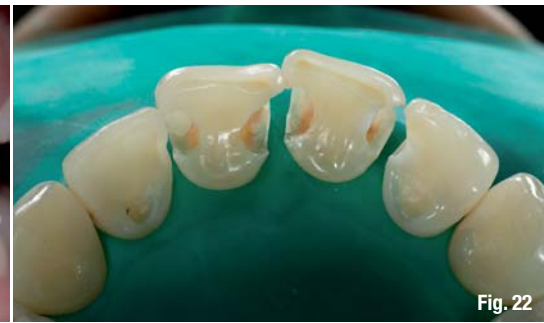


Fig. 22

incremental layering or stratification placement. The latter techniques are commonly utilised to reduce polymerisation stresses by lowering the C-factor and for emulating the shade nuances and characterisations within natural teeth, for example incisal halos, mamelons and translucencies.

Clinical technique

After two weeks, the symptoms associated with the left central incisor had subsided (that is, sensitivity and buccal tenderness), and no response was elicited with gentle percussion.

In addition to the preoperative colour analysis with shade tabs carried out earlier, small beads of Herculite XRV Ultra shades Incisal, Enamel A1, and Dentine A2 were directly placed on the tooth and light-cured to ensure a precise shade match (Fig. 20). This method allows a direct comparison of set composite on the natural tooth substrate and is an excellent method for selecting the correct enamel and dentine shades of composite. Next, the silicone index was placed against the teeth to confirm correct location and exact seating (Fig. 21).

Isolation is essential for composite resin fillings to accomplish a moisture-free environment. Various methods are available, including gingival retraction cords, cotton wool rolls, aspiration and a rubber dam. Several techniques are advocated for rubber dam use, including complete isolation of individual teeth (Fig. 22) and the split-dam technique for isolating a

number of teeth (Fig. 23). However, when building-up anterior teeth, for which aesthetics is of paramount concern, using a rubber dam can be disadvantageous owing to excessive dehydration of teeth, making accurate shade assessment challenging. Therefore, for this patient, a dry retraction cord was carefully eased into the gingival sulcus to absorb the crevicular fluid, together with cotton wool rolls in the sulci and continuous aspiration to maintain a dry field. This protocol prevented desiccation of the teeth, allowing a precise shade assessment during the layering placement of the composite build-up.

After composite shade selection, silicone index verification and tooth isolation, the tooth was prepared for resin build-up. The reattached fragment on the right central incisor was left untouched and served as a guide to mimic shape, colour and characterisations of the build-up on the left central incisor (Fig. 20). Several designs are suggested for preparing the tooth substrate, including no preparation, simple chamfer or the stair-step chamfer. In this instance, a simple 1 mm chamfer was created on the buccal and lingual surfaces using a tapered round-ended diamond bur (Fig. 24). The prepared tooth was etched with phosphoric acid and dried (not desiccated), and OptiBond Solo Plus was applied according to the manufacturer's instructions (Figs. 25 & 26). The stages for the layered composite build-up are as follows:

Step 1: Using the CompoRoller (KerrHawe SA), a thin layer (1 to 1.5 mm) of Herculite XRV Ultra

Fig. 20 Beads of different shades of Herculite XRV Ultra (Kerr) placed and set directly onto the left central incisor (from left: Incisal, Enamel A1, Dentine A2 shades).

Fig. 21 Silicone index placed onto placed surfaces of incisors to ensure correct seating.

Fig. 22 Complete isolation of each tooth with a rubber dam.

Fig. 23 Split-dam technique used to isolate the anterior maxillary sextant.

Fig. 24 A 1 mm chamfer being prepared around the circumference edge of the fracture. Notice the visible gingival retraction cord on the mesial aspect.

Fig. 25 Enchant is applied for 20 seconds using the total etch technique.

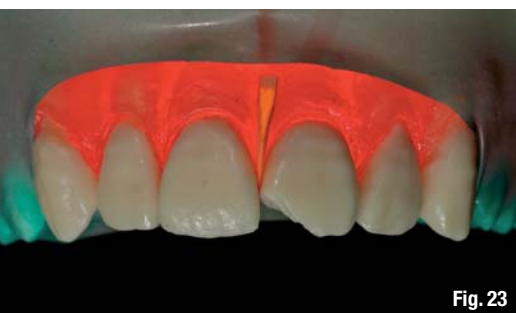

Fig. 23

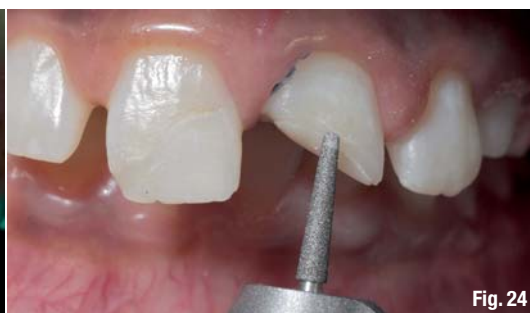

Fig. 24

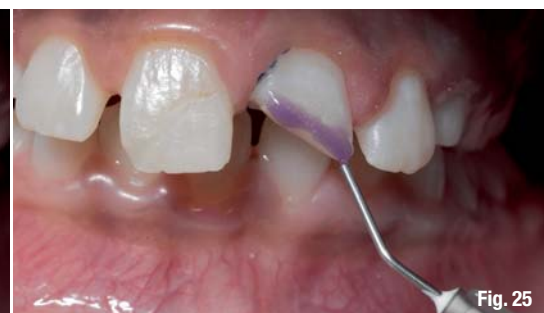

Fig. 25