

# cosmetic dentistry \_ beauty & science

4<sup>2013</sup>

| **special**

Bio-aesthetics: giving a new face to smile enhancements

| **case report**

Interdisciplinary treatment:  
A biomimetic approach

| **feature**

“Aesthetic dentistry in itself means nothing”  
An interview with Pascal Magne





# *Adopt the trend...*



**SHOFU** recognizes the development of new clinical techniques in minimally invasive cosmetic dentistry (MiCD) procedures and is fully committed to support the MiCD movement through the contribution in developing and providing dental professionals with newer aesthetic biocompatible materials to achieve their goals.



For more information, simply contact your nearest **SHOFU** dealer.



**SHOFU DENTAL ASIA-PACIFIC PTE. LTD.**

Tel (65) 6377 2722 Fax (65) 6377 1121 eMail [mailbx@shofu.com.sg](mailto:mailbx@shofu.com.sg) website [www.shofu.com.sg](http://www.shofu.com.sg)

# Dear Reader,


Modern science and technology are making tremendous advances and changes in all aspects of dentistry. The rapid integration of technology has dramatically improved the way we collect and acquire information, and has greatly facilitated successful diagnosis and treatment planning.

Since beauty is subjective, successful cosmetic dentistry requires skills beyond the ability to diagnose and treat functional or pathological irregularities. Besides entailing attention to function and pathology, cosmetic treatment requires mastery of the art of understanding different types of personalities with different expectations for treatment. Proper communication appropriate to each type will not only enhance the doctor-patient relationship, but also provide greater acceptance of treatment planning.


According to Chu and colleagues, patient expectations fall into three categories: Hollywood, "Alfred E. Neuman" and the naturalist. The first type desires very white and straight restorations, and is generally very concerned and vocal. The second type tends to rely on the clinician's expertise and follow his or her recommendations. The naturalist is often the most difficult to treat because of the expectation that all the restorations should look natural and blend in perfectly with rest of the dentition.

In this issue of **cosmetic dentistry**, we have included beautifully illustrated and documented articles that provide the solutions to improving aesthetics in CAD/CAM dentistry and present the concept of bio-aesthetics, giving a new face to smile enhancement. Emphasis has also been placed on interdisciplinary treatment planning using a biomimetic approach. I hope you will enjoy this edition and apply your new knowledge to your daily practice successfully.

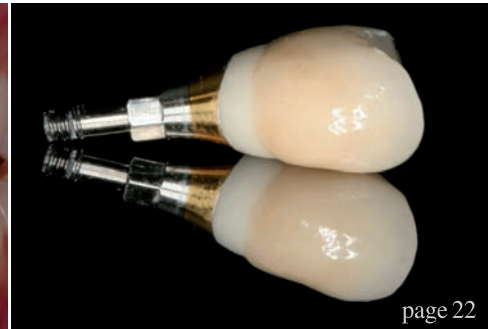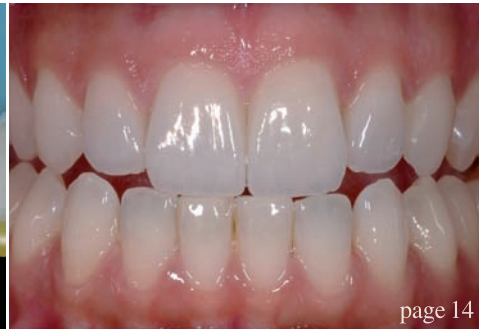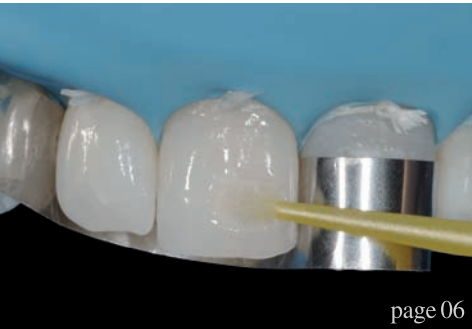
Yours faithfully,



Dr So Ran Kwon  
Co-Editor-in-Chief  
President, Korean Bleaching Society  
Seoul, Korea



Dr So Ran Kwon  
Co-Editor-in-Chief



## editorial

### 03 Dear Reader

| Dr So Ran Kwon, Co-Editor-in-Chief

## special

### 06 Bio-aesthetics: giving a new face to smile enhancements

| Dr Didier Dietschi, Switzerland

## feature

### 14 “Aesthetic dentistry in itself means nothing”

| An interview with Dr Pascal Magne, USA

## technique

### 18 Improving aesthetics in CAD/CAM dentistry – anatomic shell technique (AST)

| Dr Paulo Kano, Brazil, Dr Eric Van Dooren, Belgium,  
Dr Cristiano Xavier, Brazil, Dr Jonathan L. Ferencz, USA,  
Emerson Lacerda, Brazil & Dr Nelson RFA Silva, Brazil

## case report

### 22 Interdisciplinary treatment of a patient with 11 missing permanent teeth: A biomimetic approach

| Drs Magdalena Jaszczak-Malkowska, Joanna Witanowska &  
Małgorzata Zadurska, Poland

### 30 Reconstruction of a horizontal ridge defect using the bone lamina technique

| Dr Arndt Happe, Germany

## research

### 32 Stem cells in implant dentistry

| Dr André Antonio Pelegrine, Brazil

## meetings

### 36 Dublin conference discussed future concepts in dental implant rehabilitation

### 40 International Events

## industry news

### 38 KATANA Zirconia ML Disc High-performance zirconia with integrated colour shift

| Kuraray

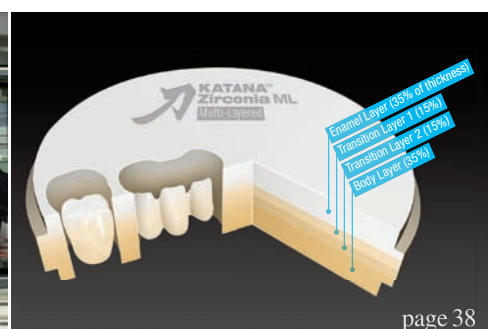
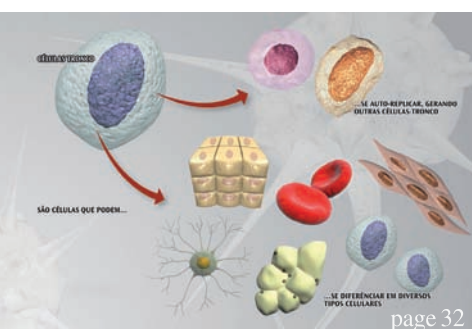
## about the publisher

### 41 | submission guidelines

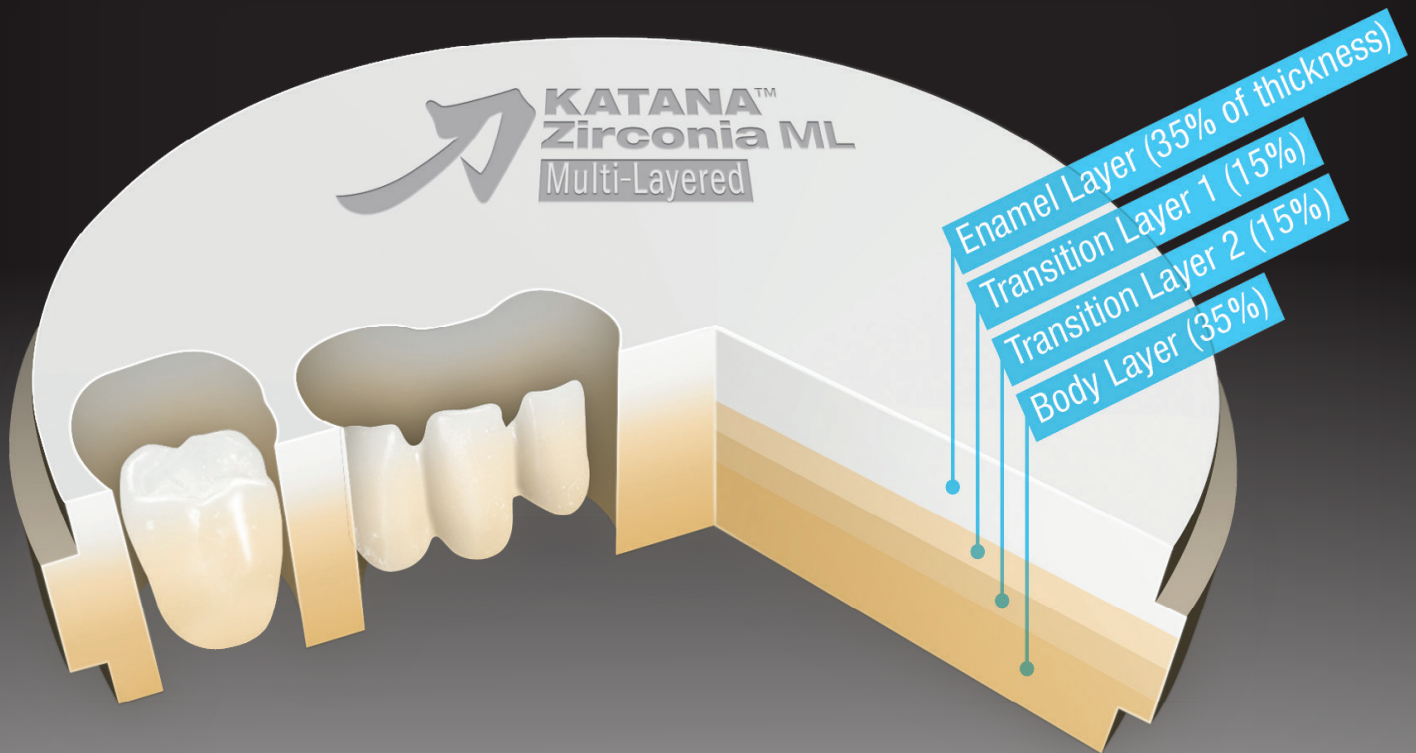
### 42 | imprint



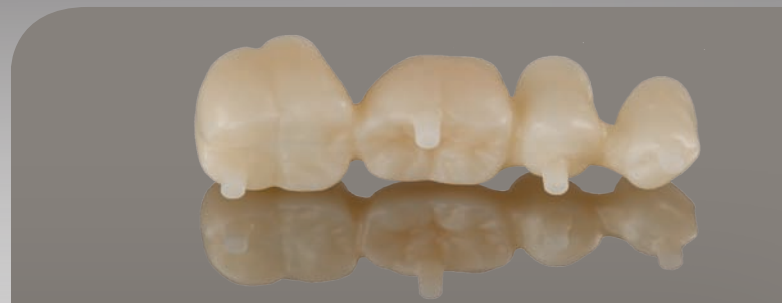Cover image courtesy of luminaimages







## IMPRESSIVE ESTHETICS IN ONE STEP!



## KATANA™ ZIRCONIA ML

### Innovative zirconia with integrated color shift!

This zirconia disc consists of four pre-colored layers. They represent the natural tooth colors and make you achieve a natural tooth-like restoration. Now you can create impressive restorations with zirconia!

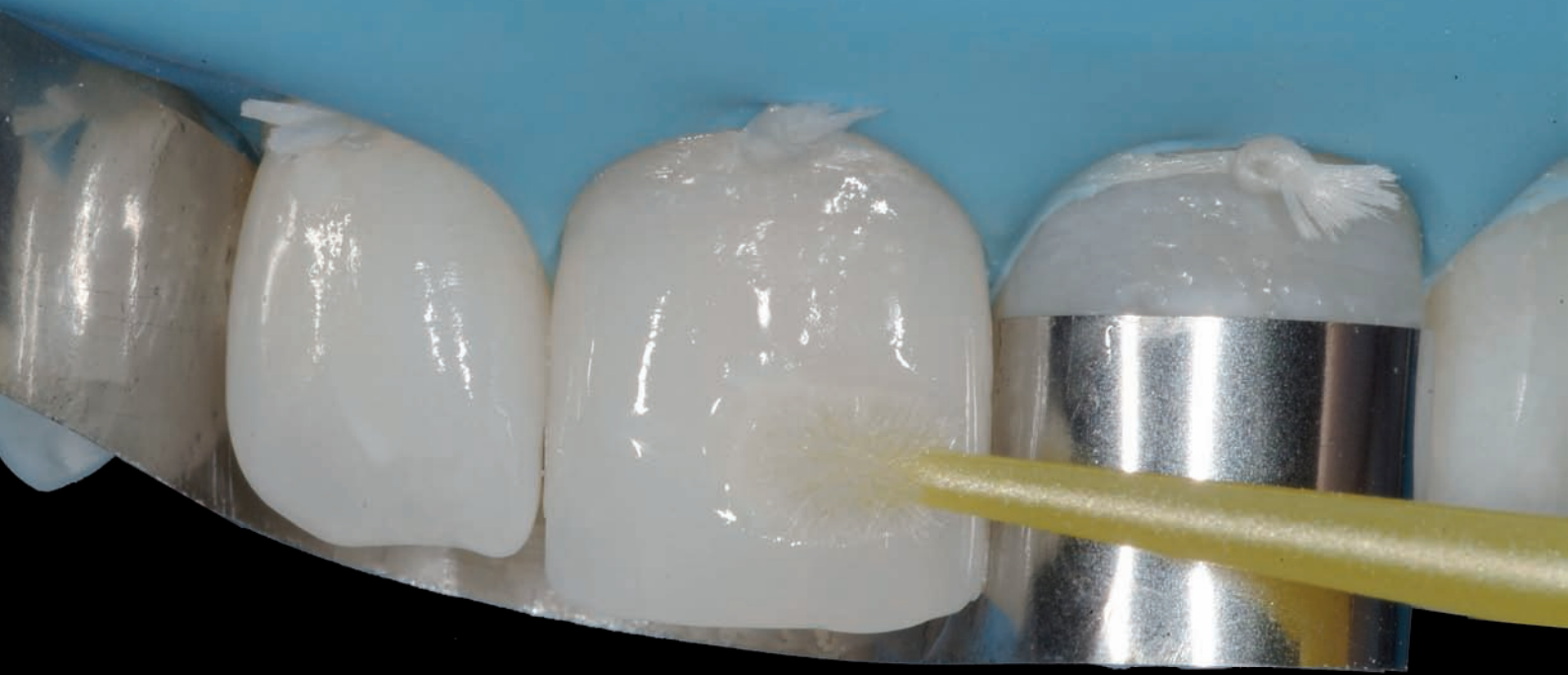### Create impressive results - immediately!

Without typical working steps like dipping or painting and drying - the sintering process can be started. After polishing or glazing you can achieve remarkable restorations under standardized conditions! The production process is significantly minimized to fewer steps!

### Reproducibility of colors for crowns, bridges and frames by integrated color gradation!

Reproducibility has been further developed and with KATANA™ ZIRCONIA ML we succeeded in offering predictable and esthetic results as easy as possible.

The KATANA™ portfolio also includes the white KATANA™ ZIRCONIA HT (High-Translucent) Disc, which gives you additional opportunities for individual staining and veneering.



# Bio-aesthetics:

## giving a new face to smile enhancements

**Author \_** Dr Didier Dietschi, Switzerland

---

Bio-aesthetics is the quintessence of biology, biomechanics and aesthetics and aims to more conservative, ethical solutions to a myriad of aesthetic deficiencies.

---

### Introduction

A more attractive smile, improved dental aesthetics and durable results have been for long intimately linked to ceramic restorations such as veneers and crowns and remain strongly anchored in patients and dental professional minds. Modern composite resin technology has however challenged this assumption because they offer excellent aesthetic potential and acceptable longevity, with a much lower cost than equivalent ceramic restorations for the treatment of both anterior and posterior teeth.<sup>1-3</sup> Moreover, composite restorations allow for minimally invasive preparations or no preparation at all when mo-

difying existing tooth anatomy or assuming the replacement of decayed tissues; this constitutes an unparalleled advantage of "free-hand bonding" also due to its relative simplicity. This rationale has been the foundation of a new concept named "bio-aesthetics", giving priority to additive, minimally or microinvasive procedures to preserve tooth biology and biomechanics.

While resin composites are universally considered the "standard of care" material for the filling of small to medium class III, IV and V cavities, they can be used today in many more indications such as the correction of small to moderate aesthetic and functional deficiencies.<sup>2,3...+</sup> Recent developments in composite optical properties and physical properties have also significantly contributed to simplifying their application and improving treatment outcome and predictability.<sup>4-6</sup> The aim of this short article is then to demonstrate the potential and multiple applications of composite as a modern aesthetic restorative material in the context of bio-aesthetic treatment approach.

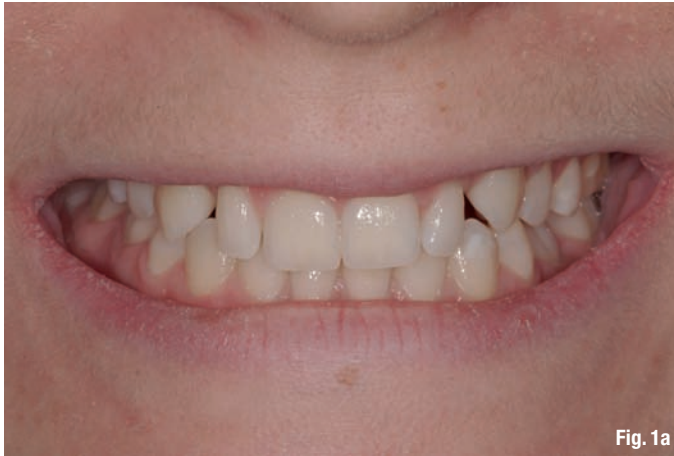

Fig. 1a

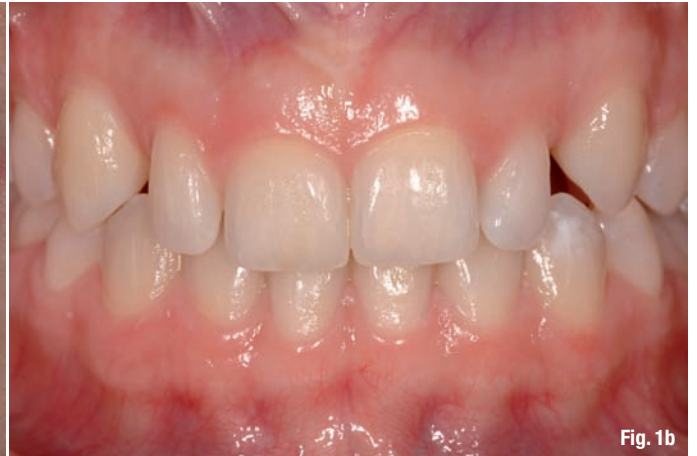

Fig. 1b

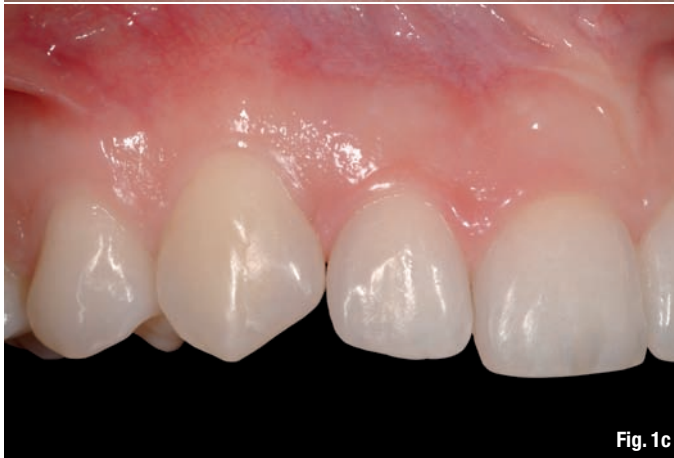

Fig. 1c

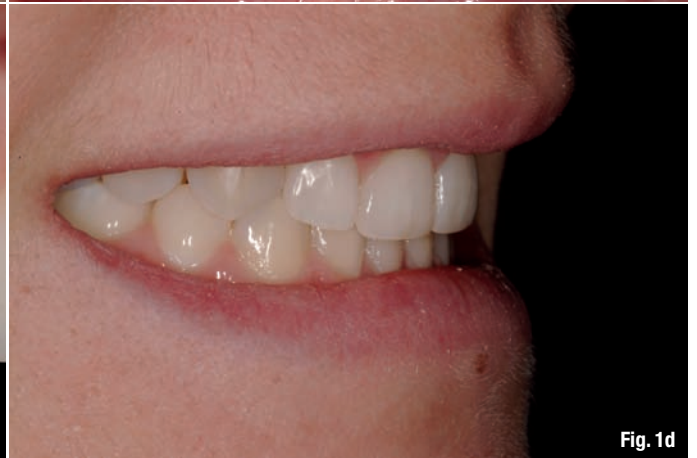

Fig. 1d

### Revisiting smile rehabilitation concepts: Bio-aesthetics

Choosing the right restorative approach (direct or indirect, composite or ceramics) has been debated over decades and finally, the decision largely depends on the practitioner's own education background and experience with each of the aforementioned options. Only "extreme"

This rationale has been the foundation of a new concept named "bio-aesthetics", giving priority to additive, minimally or microinvasive procedures to preserve tooth biology and biomechanics.

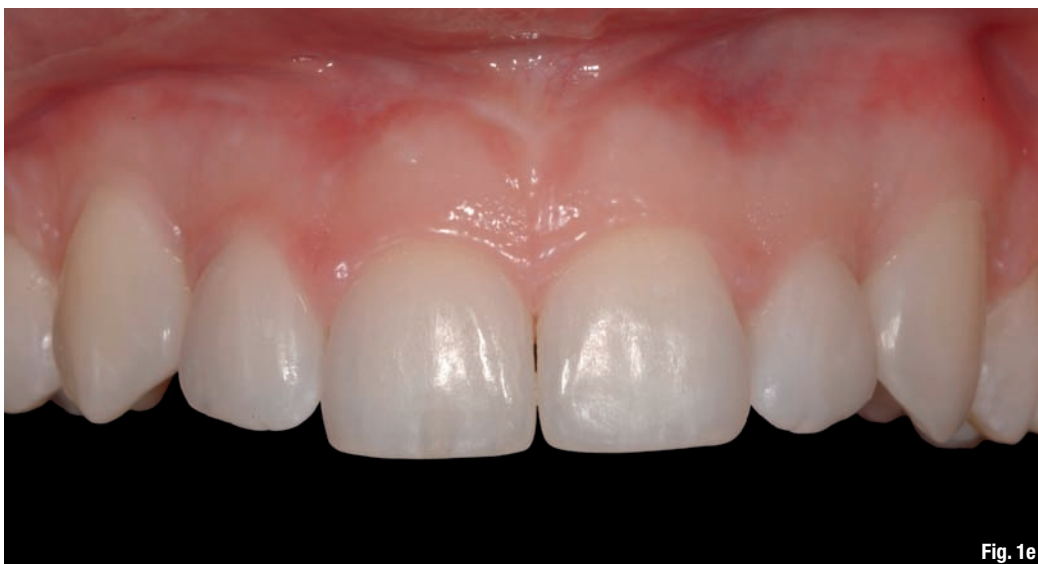
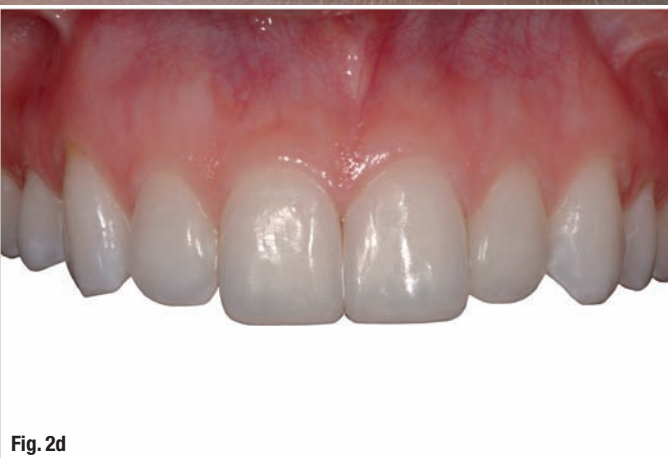
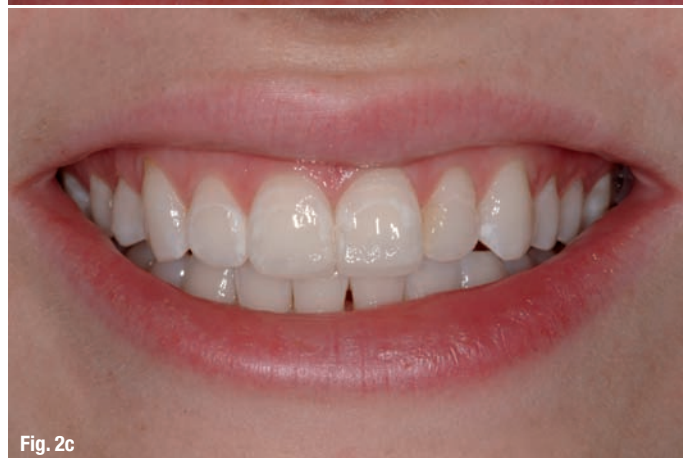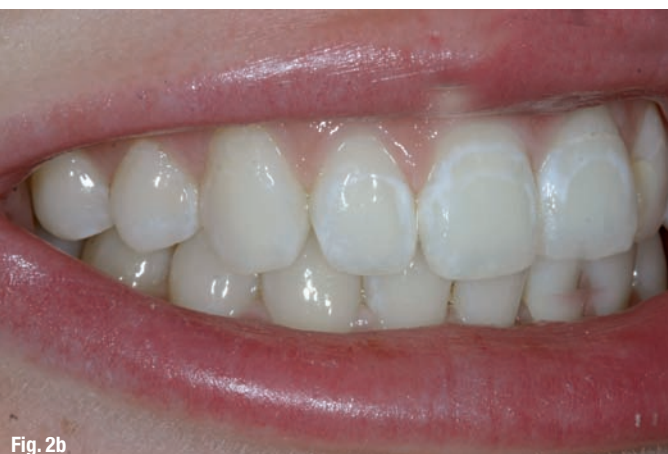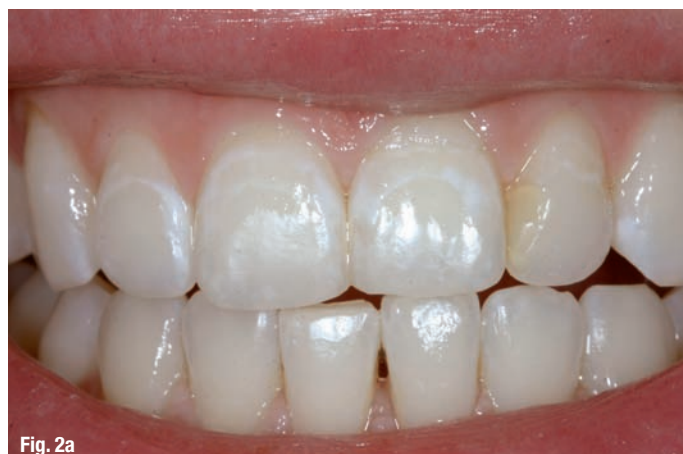Fig. 1e

**Figs. 1a & b**\_Pre-operative views of a young patient presenting relatively large diastemas distally to lateral incisors. The case is complicated by improper occlusal relationship with lower canines which reduce the space available for restorations.

**Figs. 1c–e**\_Post-operative views showing an improved smile configuration using "no-prep" direct composite restoration (inspiro, Edelweiss DR). This treatment illustrates the "bio-aesthetic" philosophy which truly represents a breakthrough in modern restorative dentistry.





**Figs. 2a & b** Pre-operative smile of a young patient presenting post-orthodontic enamel hypocalcifications and asymmetrical shorter incisors.

**Fig. 2c** A free-hand mock-up was made to assess the ideal length for an optimal smile configuration.

**Fig. 2d** Post-treatment view showing better smile balance and harmony, following micro-abrasion (to remove white spots) and direct bonding (inspire).

| Parameters            | Direct option | Indirect option veneer to crown |
|-----------------------|---------------|---------------------------------|
| age of the patient    | younger       | older                           |
| size of the decay     | smaller       | larger                          |
| tooth vitality        | vital         | non-vital                       |
| tooth colour          | normal        | non-treatable discolouration*   |
| facial anatomy        | normal        | altered                         |
| number of restoration | unrelated     | unrelated                       |

\*using chemical treatments (vital & non-vital bleaching or microabrasion)

Tab. I

| Types of procedures | Typical procedures  |
|---------------------|---|
| Non restorative     | _Aesthetic chemical treatments (bleaching, micro-abrasion)<br>_Direct bonding |
| Minimally invasive  | _Direct bonding<br>_Ultra-thin Veneers<br>_Modern inlay and onlay techniques  |
| Micro-invasive      | _Classical veneers, inlay and onlay   |
| Macro-invasive      | _Crowns and bridges   |

Tab. II

**Table I** Treatment decision process.

**Table II** Modern progressive treatment concept and various types of procedures.



conditions such as minor aesthetic form and colour corrections or extensive decays in non-vital teeth, lead to evident solutions (direct and respectively indirect restorations), while the majority of other cases lie in a "gray zone" which actually makes a pertinent choice more intricate. A simple yet effective approach to this dilemma relies on a sound bio-mechanical analysis of the teeth potentially involved in the treatment status, combined to the usual functional and aesthetic analysis. Then, having as a prime objective the respect of tooth biology and conservation guides clinician to a logical decisional tree, such as presented in table I.

The "Bio-aesthetic" philosophy actually give priority to chemical color improvements (vital bleaching, non-vital bleaching, micro-abrasion), associated to direct composite restorations and bonded ceramic restorations for more extensive decays, limiting the use of traditional full crowns to existing restoration

replacement and a few conditions of extreme tooth "fragilization" (weakening). The progressive treatment concept presented in table II then summarizes the modern vision of aesthetic restorative dentistry.

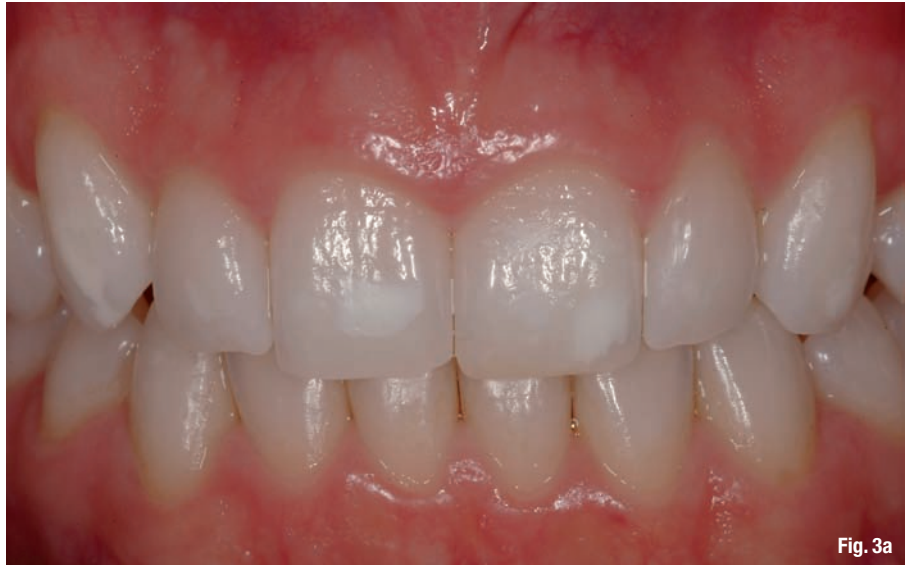

Fig. 3a

**Fig. 3a** Pre-operative views of a young patient showing enamel hypocalcifications and asymmetrical tooth forms.

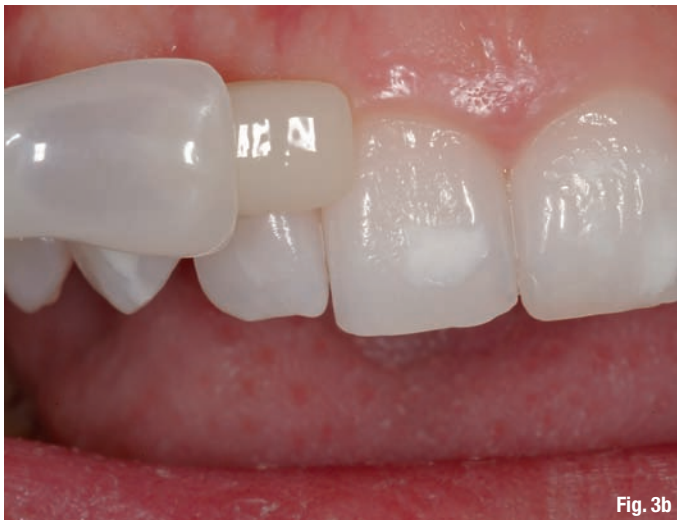

Fig. 3b

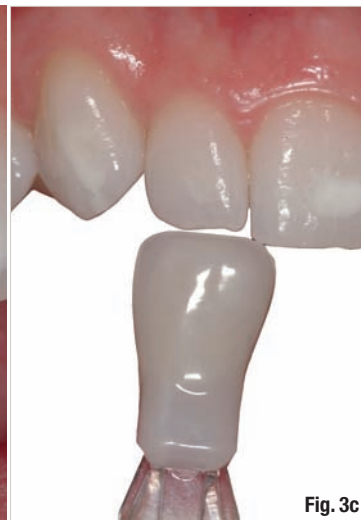

Fig. 3c

**Figs. 3b & c** Shade selection is performed using a special dual-laminate shade guide which grants colour predictability (inspiro).  
**Figs. 3d & e** A partial mock-up (teeth #11 and #12) is made to assess the impact of planned restorations on the smile configuration.

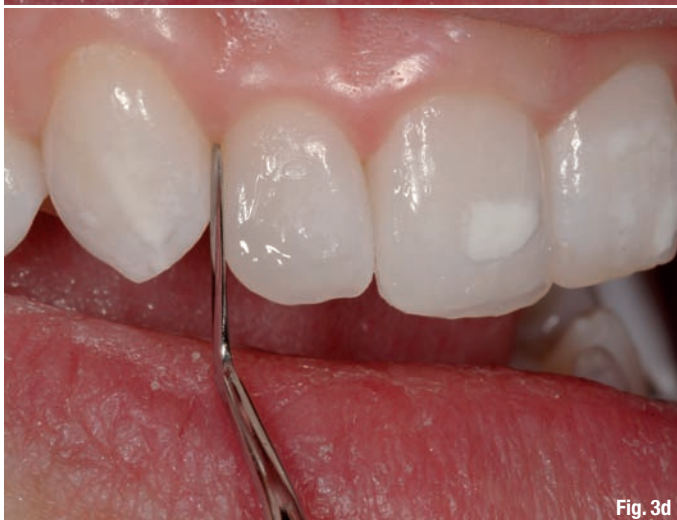

Fig. 3d

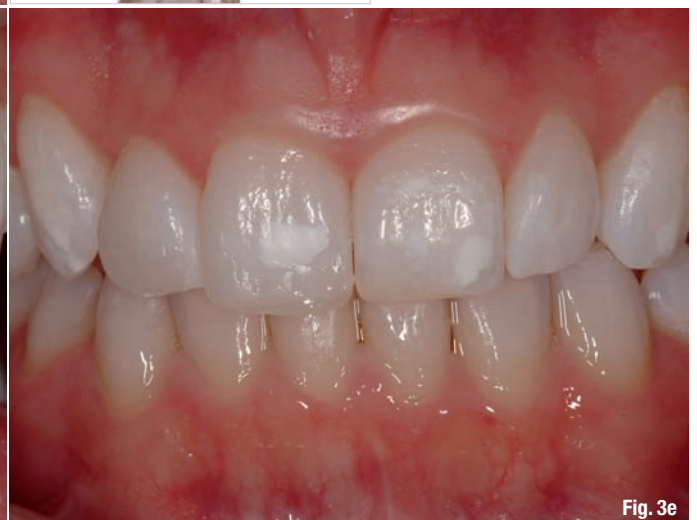

Fig. 3e