

**FOR THE DENTAL PROFESSIONAL**

# DENTAL TRIBUNE

— The World's Dental Newspaper · Middle East & Africa Edition —

PUBLISHED IN DUBAI

www.dental-tribune.me

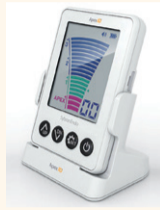May-June 2016 | No. 3, Vol. 6



## HYGIENE TRIBUNE

Poor dental health may predict reduced ability to leave one's house

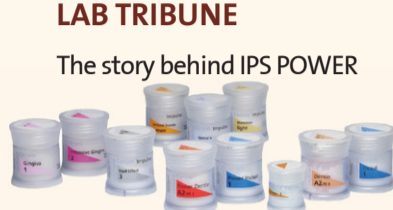
►Insertion



## ENDO TRIBUNE

Getting to the oo.oo point

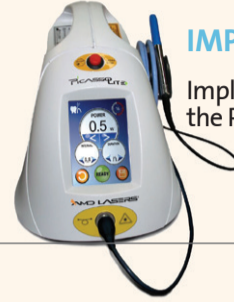►Insertion



## LAB TRIBUNE

The story behind IPS POWER

►Insertion



## IMPLANT TRIBUNE

Implant uncover with the Picasso diode laser

►Insertion

## A time-saving procedure to create natural esthetics in posterior restorations

By Ivoclar Vivadent AG

A flowable bulk-fill composite complements the existing Tetric N-Ceram Bulk Fill. For many years, the universal composite Tetric N-Ceram

has been proven successful in restorative dentistry. As part of the ongoing development of restorative materials, a further innovation is now launched on the market: Tetric N-Flow Bulk Fill.

The new flowable composite complements the mouldable Tetric N-Ceram Bulk Fill composite. In essence, Tetric N-Flow Bulk Fill is based on the composition of Tetric N-Ceram Bulk Fill. The material is applied as a bulk-fill base in Class I and Class II restorations. Just like the existing version, it can be light-cured in large increments of up to four millimetres,

Dental Tribune MEA & CAPMmea would like to greet all on the occasion of Ramadan.

Wishing you all a blessed and joyous Ramadan Mubarak! May you celebrate in good health and prosperity.



Ivoclar Vivadent AG Headquarters

►Page 2

## AMD LASERS®

EFFECTIVE. PRACTICAL. AFFORDABLE. WORLD CLASS LASERS.



# #1 Lasers in the World



### GLOBE

ADDRESS: 11, EL OBOUR BUILDINGS, OROUBA AV. HOLIOPOLIS, CAIRO, EGYPT  
TELEFAX: +2024045621 - +2024010579  
MOB: +2 01000 99 6265  
WEBSITE: WWW.GLOBEEGYPT.NET  
EMAIL: INFO@GLOBEEGYPT.NET



### TAMER DROGUERIE

ADDRESS: BEIRUT-LEBANON  
WEBSITE: WWW.TAMERHOLDING.COM  
E-MAIL: DENTAL@TAMERHOLDING.COM  
PHONE: 961.1.694 000  
FAX: 961.1.694 777



### DUBAI MEDICAL EQUIPMENT

UNITED ARAB EMIRATES  
TEL. NO: +971 6 5308055  
FAX NO: +971 6 5308077  
MOB : +971 50 7370011  
MOB : +971 55 4417490  
DT\_UAE@EMIRATES.NET.AE



866.999.2635 AMDLASERS.COM





◀Page 1

requiring only short light exposure times. Excellent affinity to cavity walls and self-levelling consistency round off the benefits offered by this volume replacement material. The flowable version contains the same Ivocerin light initiator, patented shrinkage stress reliever and light sensitivity filter like Tetric N-Ceram. The light sensitivity filter extends the working time under ambient and operatory light.

#### Time savings of up to 55%

User studies have shown that clinicians can save up to 55% of the time required for the incremental technique if they use a bulk-fill material (with Tetric N-Flow and Tetric N-Ceram).


#### Ivocerin light initiator and Aessencio technology

Another strength of the new composite lies in the Aessencio tech-

nology. This technology causes the translucency of the material to decrease from 28% to approx. 10% during polymerization. In combination with the highly reactive patented Ivocerin light initiator, the Aessencio technology enables composite increments up to a thickness of 4 mm to be cured, while at the same time a low dentin-like translucency can be maintained, allowing, among other things, discoloured tooth structure to be masked. This property makes Tetric N-Flow Bulk Fill the ideal companion for Tetric N-Ceram Bulk Fill, which features an enamel-like translucency. Tetric N-Flow Bulk Fill should be covered with a load-bearing composite (e.g. Tetric N-Ceram Bulk fill or Tetric N-Ceram). For restorations in deciduous teeth, the material can be applied without a capping layer.



New: Tetric N-Flow Bulk Fill

Tetric®, Ivocerin® and Aessencio® are registered trademarks of Ivoclar Vivadent AG. 

#### Contact Information

Ivoclar Vivadent AG  
Bendererstrasse 2  
9494 Schaan/Liechtenstein  
Tel.: +423 235 35 35  
Fax: +423 235 33 60  
E-mail: [info@ivoclarvivadent.com](mailto:info@ivoclarvivadent.com)  
[www.ivoclarvivadent.com](http://www.ivoclarvivadent.com)

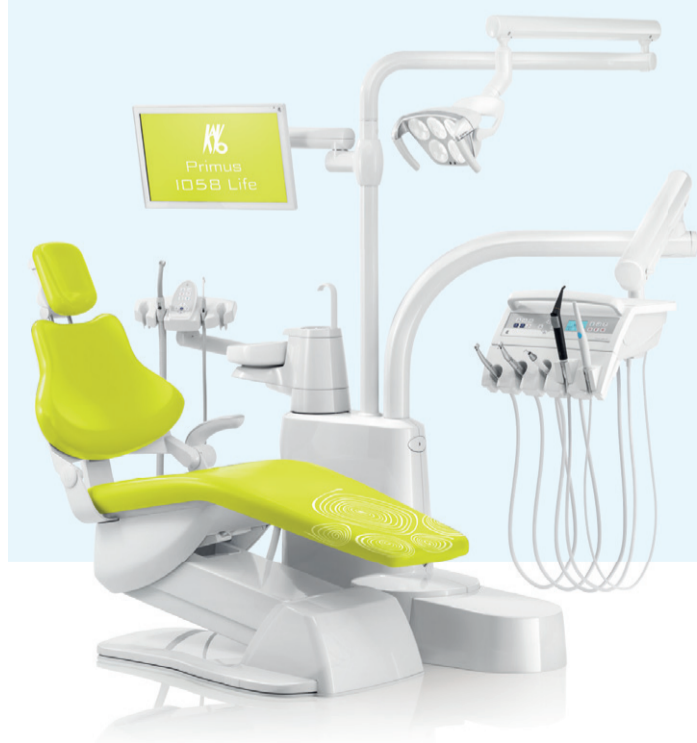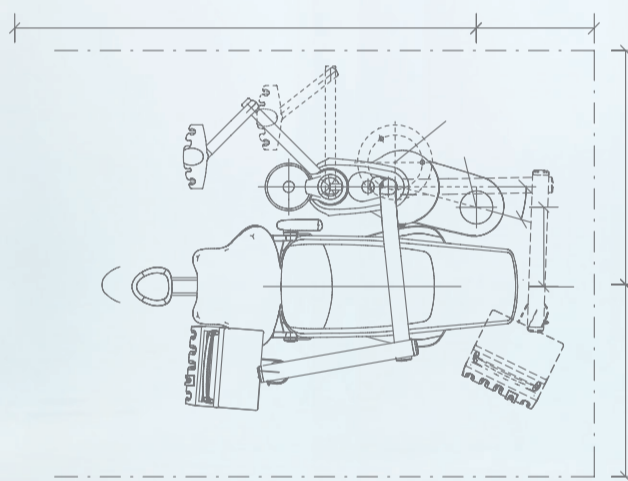
### KaVo Primus™ 1058 Life



Andreas Schweiger,  
Director Research and Development

Designed with passion.  
Engineered with precision.  
Built with perfection.

Discover the new Primus 1058 Life



The Primus 1058 has been the synonym for quality and reliability in the dental world for over 15 years. Consequently, our development team has passionately designed the new Primus 1058 Life around these core values whilst adding a significant number of improvements and innovations including:

- NEW intuitive dentist element
- NEW optimised ergonomics
- NEW contemporary design
- NEW AC chair motor

For More Information:  
[go.kavo.com/MEA](http://go.kavo.com/MEA)



KaVo. Dental Excellence.

KaVo Dental GmbH · D 88400 Biberach/Riß · Telephone +49 7351 56-0 · Fax +49 7351 56-1488 · [www.kavo.com](http://www.kavo.com)

### IMPRINT

**GROUP EDITOR**  
Daniel ZIMMERMANN  
[newsroom@dental-tribune.com](mailto:newsroom@dental-tribune.com)  
Tel.: +44 161 223 1830

**CLINICAL EDITOR**  
Magda WOJTKIEWICZ

**ONLINE EDITOR**  
**SOCIAL MEDIA MANAGER**  
Claudia DUSCHKE

**EDITORIAL ASSISTANTS**  
Anne FAULMANN  
Kristin HÜBNER

**COPY EDITORS**  
Sabrina RAAFF  
Hans MOTSCHMANN

**PUBLISHER/PRESIDENT/CEO**  
Torsten OEMUS

**CHIEF FINANCIAL OFFICER**  
Dan WUNDERLICH

**CHIEF TECHNOLOGY OFFICER**  
Serban VERES

**BUSINESS DEVELOPMENT MANAGER**  
Claudia SÄLWICZEK-MAJONEK

**JUNIOR MANAGER BUSINESS DEVELOPMENT**  
Sarah SCHUBERT

**PROJECT MANAGER ONLINE**  
Tom CARVALHO

**EVENT MANAGER**  
Lars HOFFMANN

**EDUCATION MANAGER**  
Christiane FERRET

**INTERNATIONAL PR & PROJECT MANAGER**  
Marc CHALUPSKY

**MARKETING & SALES SERVICES**  
Nicole ANDRA

**EVENT SERVICES**  
Esther WODARSKI

**ACCOUNTING SERVICES**  
Karen HAMATSCHEK  
Anja MAYWALD  
Manuela HUNGER

**MEDIA SALES MANAGERS**  
Matthias DIESSNER (Key Accounts)  
Melissa BROWN (International)  
Antje KAHNT (International)  
Peter WITTECZEK (Asia Pacific)  
Weridiana MAGESWIKI (Latin America)  
Maria KAISER (USA)  
Hélène CARPENTIER (Europe)  
Barbora SOLAROVA (Eastern Europe)

**EXECUTIVE PRODUCER**  
Gernot MEYER

**ADVERTISING DISPOSITION**  
Marius MEZGER

**DENTAL TRIBUNE INTERNATIONAL**  
Holbeinstr. 29, 04229 Leipzig, Germany  
Tel.: +49 341 48 474 302  
Fax: +49 341 48 474 173  
[www.dental-tribune.com](http://www.dental-tribune.com)  
[info@dental-tribune.com](mailto:info@dental-tribune.com)

**DENTAL TRIBUNE ASIA PACIFIC LTD.**  
Room A, 20/F  
Harvard Commercial Building  
105-111 Thomson Road, Wanchai, HK  
Tel.: +852 3113 6177  
Fax: +852 3113 6199

**THE AMERICA, LLC**  
116 West 23rd Street, Ste. 500, New York  
N.Y. 10011, USA  
Tel.: +1 212 244 7181  
Fax: +1 212 244 7185

**DENTAL TRIBUNE MEA EDITION EDITORIAL BOARD**  
Dr. Aisha SULTAN ALSUWAI, UAE  
Dr. Ninette BANDAY, UAE  
Dr. Nabeel HUMOOD ALSABEEHA, UAE  
Dr. Mohammad AL-OBAIDA, KSA  
Dr. Meshari F. ALOTAIBI, KSA  
Dr. Jasim M. AL-SAEEDI, Oman  
Dr. Mohammed AL-DARWISH, Qatar  
Prof. Khaled BALTO, KSA  
Dr. Dobrina MOLLOVA, UAE  
Dr. Munir SILWADI, UAE  
Dr. Khaled ABOUSEADA, KSA  
Dr. Rabih ABI NADER, UAE  
Dr. George SANOOP, UAE  
Dr. Olivier CARCUAC, UAE  
Dr. Ehab Heikal, Egypt  
Aiham FARRAH, CDT, UAE  
Retty M. MATTHEW, UAE

**PARTNERS**  
Emirates Dental Society  
Saudi Dental Society  
Lebanese Dental Association  
Qatar Dental Society  
Oman Dental Society

**DIRECTOR OF mCME**  
Dr. Dobrina Mollova  
[mollova@dental-tribune.me](mailto:mollova@dental-tribune.me)  
Tel.: +971 50 42 43072

**DIRECTOR**  
Tzvetan Deyanov  
[deyanov@dental-tribune.me](mailto:deyanov@dental-tribune.me)  
Tel.: +971 55 11 28 581

**DESIGNER**  
Kinga Romik  
[k.romik@dental-tribune.me](mailto:k.romik@dental-tribune.me)

**PRINTING HOUSE**  
Al Nisr Printing  
P.O. Box 6519, Dubai, UAE



# SMALL CHANGE. BIG DIFFERENCE.

The new imaging plate scanner XIOS Scan completes the intraoral family from Sirona. Whether you're taking the first steps into the digital world or establishing or updating a fully digital practice, XIOS Scan and XIOS XG Sensors offer perfectly synchronized solutions for every-workflow. **Enjoy every day. With Sirona.**



THE NEW  
IMAGING PLATE  
SCANNER:  
**XIOS Scan**

SIRONA.COM

The Dental Company

**sirona.**



# Direct Restorative in treating function and aesthetics

By Dr. Jan van Lierop

Do we always respect the true role of the anterior dentition? Or do we get caught up in the creation of beauty to the disadvantage of function. In this clinical case we show how the understanding of the entire occlusal complex is critical in establishing a beautiful and stable long-term result. By first creating stable anterior and canine guidance we can protect the dentition and the restorations, adding to long-term stability of both.

## Understanding

When faced with obvious aesthetic shortcomings (as in Figure 1) we have to guard against getting caught up in the obvious. Often by looking closer we can identify the true underlying cause. Here the signs of abfraction, loss of posterior support through molar erosion and the lack of canine guidance (Figure 2 and 3) had played a critical role in the eventual wear and chipping of the anterior teeth (Figure 4), part of the initial aesthetic complaint.

## Function

To establish a stable aesthetic result, it is essential that we stabilize the occlusion first. This was achieved by systematically restoring the palatal anatomy of the anterior teeth (Figure 5 and 6) using direct restoratives (Filtek™ Supreme XTE A2B) in a single visit. This established critical anterior and canine guidance (Figure 7). In a subsequent visit, only a few days later, the lower posterior teeth were restored to their original anatomy (Filtek™ Supreme XTE A2B) thereby creating total occlusal contact and stability (Figure 8).

## Aesthetics

3 months after the occlusion had been stabilized, anterior aesthetics was created following a digitally designed plan (Figure 9). By transferring the digital plan to an analogue model we could create stents to guide in the aesthetic restoration (Figure 10). By using Filtek™ Supreme XTE (shade A2D and A1E) in a layering technique a beautiful result was achieved (Figure 11 and 12). Realizing the ultimate goal of achieving protective function and long-term aesthetics. [DT](#)



**Dr van Lierop**  
Dr Jean van Lierop is a private practitioner in Hout Bay Dental Studio clinic in Cape Town, South Africa. After graduating from the University of Stellenbosch in 1999, Dr Jean van Lierop spent some time in private practice in the Netherlands and United Kingdom. He achieved his PDD in Aesthetic dentistry at the University of Western Cape (Cum Laude), and is completing an MSc in Restorative Dentistry at the same University. He is also a visiting lecturer at the University of the Western Cape's post graduate restorative department. His primary interest lays in the use of direct restoratives, in particular their use in the conservative treatment of dental erosion and tooth wear.

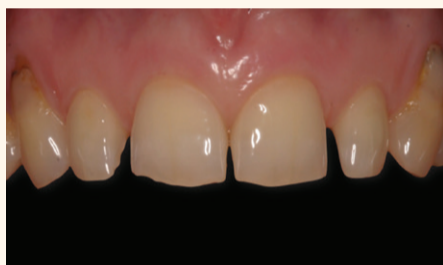

Figure 1

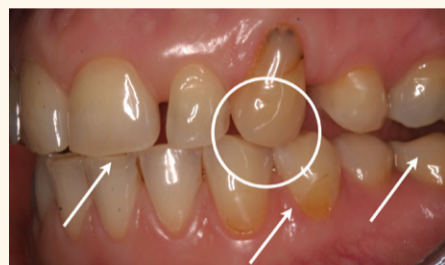

Figure 2

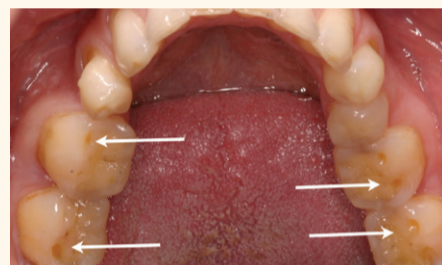


Figure 3

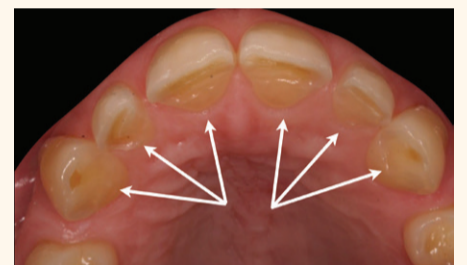


Figure 4

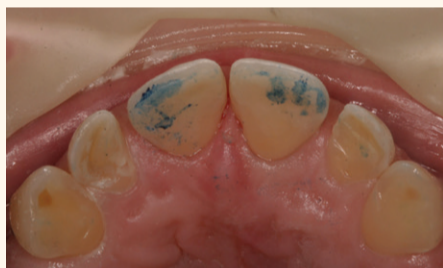

Figure 5

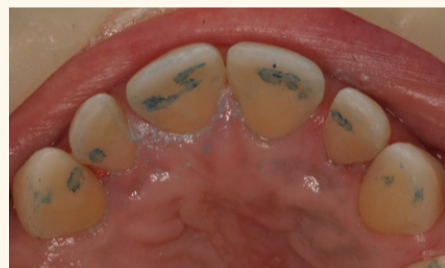

Figure 6

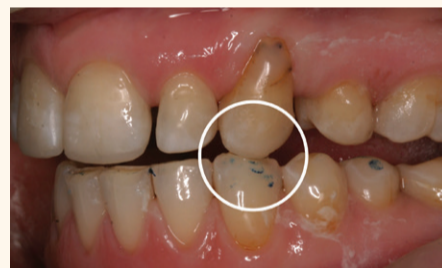

Figure 7

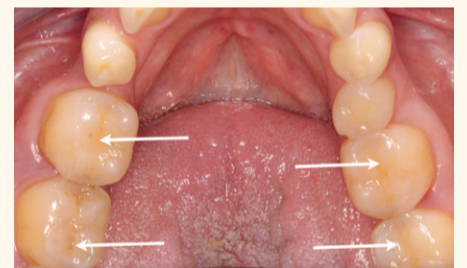


Figure 8

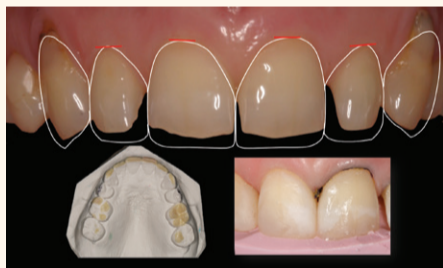


Figure 9

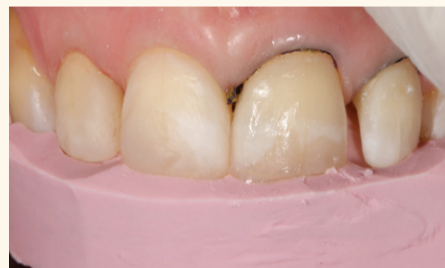

Figure 10

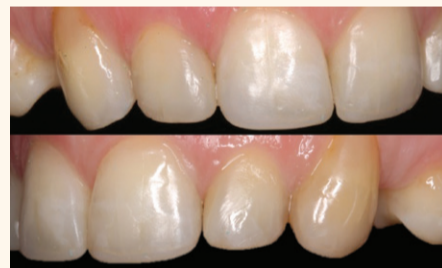

Figure 11

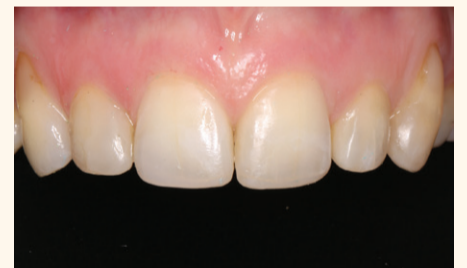

Figure 12

Filtek™ Supreme XTE Universal Restorative material name in MEA region is Filtek™ Z350XT Universal Restorative.

## Professional development with 3M<sup>SM</sup> Health Care Academy

Science. Knowledge. Solutions. Dentistry in Practice. International Expert Meeting, Warsaw, 3-4 May 2016

By 3M

The Dentistry in Practice event held in Warsaw in May, offered through the 3M<sup>SM</sup> Health Care Academy, was dedicated to all dentists seeking practical tips to solve daily problems in their practices. Throughout the event participating international dental practitioners had the opportunity to share their most successful techniques and newest science that allows dentists to overcome their everyday challenges.

### Science in and around us

The International Science. Knowledge. Solutions. Expert Meeting in Warsaw hosted 20 specialized sessions led by 20 experienced dental professionals within Central Eastern Europe and Middle East and Africa Region. They explored and discussed how science is driving evolutions in dentistry and how it can be applied to one's daily work. The sessions covered clinical cases and innovative technologies that make it easier to find solutions for better clinical outcomes as well as improve the safety,

health and comfort of the patient. With easy access to the knowledge exchanged by experts on [www.dentistryinpractice.com](http://www.dentistryinpractice.com), we allow every dentist to become a part of the conference directly from his or her home or office. In a quick and simple way, dentists can review videos of the Specialized Sessions that were recorded during the Expert Meeting in Warsaw online at any time.

### Knowledge for development

3M is connecting the specialist com-

munity to drive the exchange of knowledge, clinical experience and ideas that result in brilliant technological solutions. Our goal is to make sure that our solutions have a real impact on the everyday practice of dentists and enable them to achieve greater clinical success. Working with patients is a real challenge and responsibility, requiring constant development and enhancements towards modern, science-based solutions. This is why we created a dedicated website that allows dentists to watch videos online and provides the opportunity to obtain practical tips with their utmost convenience in mind. We want to be everyday partners and advisors in your practice.

### Solutions for simplified and better outcomes

Every dentist can be a part of the 3M<sup>SM</sup> conference, with access to its content online. After registering, our partner dentists will receive notifications every two weeks about new

conference video materials, which will be regularly uploaded on [dentistryinpractice.com](http://dentistryinpractice.com). 3M, aiming to be partner in the daily work of dentists, has developed this innovative and convenient exchange of knowledge to improve dental practices through easy-to-apply solutions. This will help specialists to continue their education in a modern way, and to share their learnings and experiences throughout the dental community.

With [www.dentistryinpractice.com](http://www.dentistryinpractice.com), 3M helps science to move out of the laboratory and into daily practice for optimal clinical outcomes and the highest patient satisfaction. [DT](#)

### Contact Information

Elena Golubeva  
Marketing Manager  
Oral Care Solutions Division CEEMEA  
[egolubeva@mmm.com](mailto:egolubeva@mmm.com)

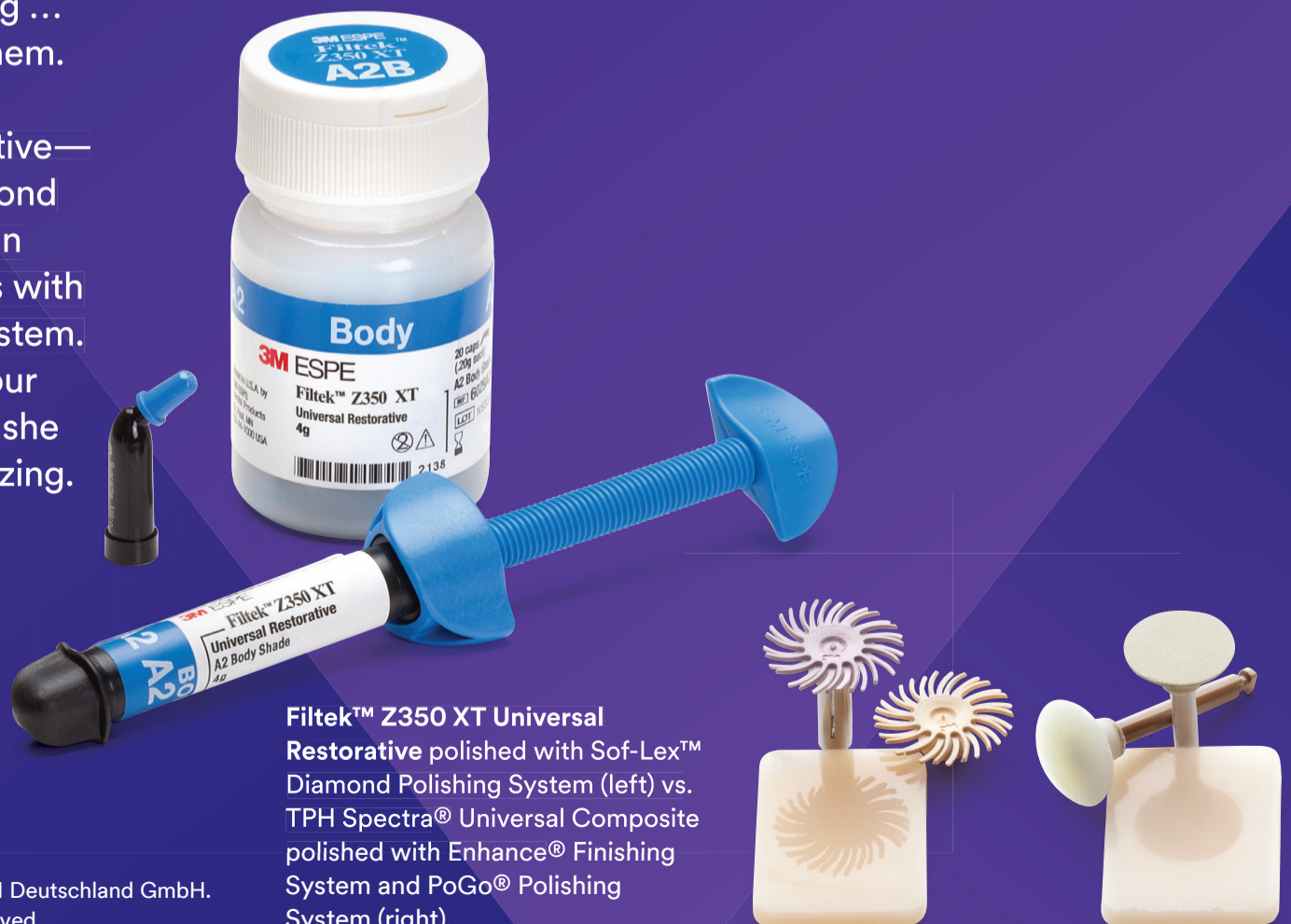

**3M** Science.  
Applied to Life.™

# A beautiful smile she can't wait to share.

There are things in life worth sharing ... and now, her smile can be one of them. Restore with beautifully strong Filtek™ Z350 XT Universal Restorative—and polish with the Sof-Lex™ Diamond Polishing System. Together, they can produce a diamond paste-like gloss with the convenience of a rubberized system. Oh, don't be surprised if word of your great work gets around ... because she shares everything she thinks is amazing.

[www.3MGulf.com/espe](http://www.3MGulf.com/espe)



Filtek™ Z350 XT Universal Restorative polished with Sof-Lex™ Diamond Polishing System (left) vs. TPH Spectra® Universal Composite polished with Enhance® Finishing System and PoGo® Polishing System (right).



## PROMEDICA

Highest quality made in Germany

### Light-curing nano-ceram composite

- Perfect aesthetics
- Highly biocompatible
- Low polymerisation shrinkage
- Universal for all cavity classes
- Comfortable handling, easy modulation
- Also available as a flowable version

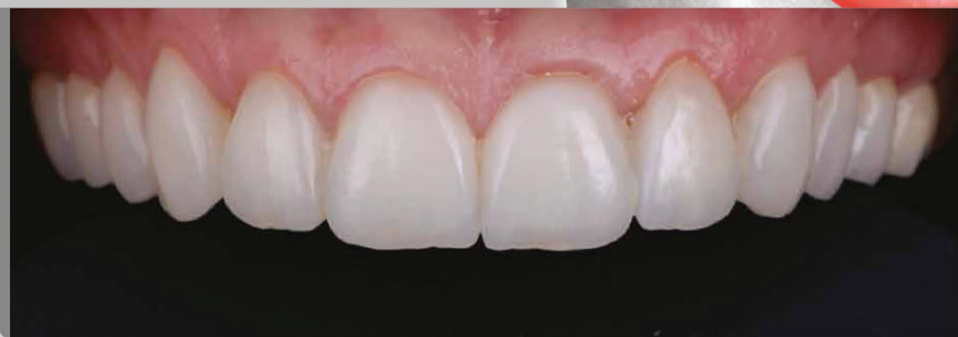

**PROMEDICA**

**Dental Material GmbH**  
24537 Neumünster / Germany  
Tel. +49 43 21 / 5 41 73  
Fax +49 43 21 / 5 19 08  
eMail info@promedica.de  
Internet www.promedica.de



**ARCHITECT**  
of the SMILE



[www.qualident-online.com](http://www.qualident-online.com)

Dubai - 04 3427576  
Sharjah - 06 5255199



**QUALIDENT**  
DENTAL LABORATORY

## Will India be the next big dental market?

By DTI

**HYDERABAD, India:** The Indian dental care services market is estimated to experience a double-digit growth rate, reaching up to US\$2.2 billion (147 bn. Indian rupees) by 2020. According to Ken Research, India has already witnessed a compound annual growth rate of 12 per cent for the period of 2010 to 2015 as dental awareness and disposable income have increased. Taking into account factors such as continued economic growth and reforms, India might have the potential to become the largest market for dental products and materials worldwide.

According to the Indian Dental Association, India's population of 1.2 billion had access to 180,000 dentists, including 35,000 specialists, in 2014. This number is projected to grow to 300,000 by 2018. Around 5,000 dental laboratories and 300 dental institutes currently provide basic and advanced oral health care. Expected growth in the number of dental chains will increase the share of organised dental clinics across the country. Although the vast majority of dental products are imported from Germany, the US, Italy and Japan, foreign companies continue to invest in India and establish production units.

Most importantly, patient demand for better health care facilities has increased. As a country without a

unified health care system, more Indians are purchasing private oral health insurance. A rising elderly population, changing lifestyles, and increased private and public health care expenditure are additional factors for the growth of the dental care market. Furthermore, dental companies are focusing on improving dental services for tourists seeking lower-cost treatment across India.

Ken Research recommends that domestic companies focus on effective marketing strategies and attractive discounts. In addition, free dental check-ups, dental outreach programmes and mobile clinics should improve the oral health care situation in less-developed regions, as substantial differences between rural and urban areas regarding access to dental clinics remain. The current dentist-population ratio is reported to be 1:9,000 in urban and 1:200,000 in rural areas. Many Indian citizens, especially in poorer areas, have yet to be educated about preventative oral health care.

The publication, India dental care service market outlook to 2020—Increasing awareness on oral care and rising number of organized players to foster future growth, is available online at [www.kenresearch.com](http://www.kenresearch.com). The report covers various aspects, such as market size, structure and segmentation, as well as the demographics of domestic and foreign customers. **DTI**



# Splyce ID: Designing Bespoke Modern Wonder Clinics - Part IV (Circular Shapes)

By Menaka Ramakrishnan, India

Circles are congruous with infinity. The shape signifies interminable peace, balance and harmony. So how does one incorporate this into a Dental Clinic? Splyce Interior Design ideated the most efficacious ways to do this.

Four years ago Splyce Interior Design conceptualized a clinic for the same client in Dubai Healthcare City. The relaxing aura and ambience have gotten several laurels. The Same Day Dental Clinic attributes their triumph to impeccable service and seamless interiors.

The specialty of Splyce is creating novel yet concrete designs, particularly clinics. The effective functionality of the space is imperative followed by adding precise atmospheric elements. Dr. Costa, leading dentist at the Same Day Dental Clinics, had entrusted Splyce with this project before. Now, the clinic had to be customized to dentist-clients on Jumeirah Beach Road, Dubai. Dr. Costa has been practicing since 1984,

therefore the space needed to reflect his astounding qualifications and experience.

Ranjit Prasad, Creative Director of Splyce, envisioned circular shapes along with shades of white and grey to be used within the clinic space. The first facet of this is the flamboyant, circular ceiling crystal chandelier that is placed right at the reception. The very presence of this chandelier fills the customer with tranquility. Consequently all other areas of the clinic branch out from this central zone in an organic distribution. It's so important to feel relaxed at a dental clinic, principally before intricate procedures. Splyce manages to set a peaceful tone as soon as the customer sets foot into the clinic.

Circular clouds lights are placed above each treatment chair in the procedure rooms. These lights incite a visual of clouds. White circular lights are also placed in strategic locations throughout the clinic such as the waiting areas. Curvilinear pieces of furniture are used in the reception and meeting rooms. This comple-

ments the Zen-like sensation.

The client required superlative materials for this project. As the colour palette was mainly white and grey, the choices were limited. The colour white signifies sterility and cleanliness. Therefore the floor has been exclusively built around this shade. Warmer tones of white leather have been used for the waiting and relaxation areas to emulate cosiness. Solid surface resin was chosen as the countertop material. The dental chairs also imitate this leitmotif. Carpets were placed in the meeting rooms and admin areas to entice the reverberation of sound.

Natural light has been fruitfully used as well, with large windows being placed in the meeting room and waiting areas. Glass windows coupled with the colour white enlarges the space. The aesthetic is analogous to being in a premiere spa. The tech-



nology used is up-to-the-mark as well, predominantly in the dental laboratory space and treatment areas.

Splyce Interior Design has clearly demonstrated the evolution of a run-of-the-mill dental clinic, into a peaceful and specialized setting. Dentist trips are no longer dreadful, but manageable thanks to them. Our goal is to integrate meaningful design into the space we create. Every element in the space we create is placed to achieve something significant, as is the case with Same Day Dental Clinic. Watch this space for further prodigious design inputs by Splyce ID.

Splyce Interior Designs is a boutique agency driven to meet satisfactions of a clientele that know the value of good design and incorporated that into their own philosophy. Splyce believes its reason d'être is creating stunning designs that exceeded client expectations. [DVI](#)

**Splyce Interior Design LLC**  
Unit 124, 3rd floor  
Oasis Centre, SZ Road  
Dubai, UAE  
T: +971 4 3806560

## The glow of the art



### BRILLIANT EverGlow™

Universal Submicron Hybrid Composite

Outstanding polishability and gloss retention ←

Brilliant single-shade restorations ←

Ideal handling through a smooth consistency ←

Good wettability on the tooth surface ←



**COLTENE**

everglow.coltene.com | www.coltene.com



# Treatment planning: Retention of the natural dentition and the replacement of missing teeth

**ADA C.E.R.P.**® | Continuing Education Recognition Program

Centre for Advanced Professional Practices (CAPP) is an ADA CERP Recognized Provider. ADA CERP is a service of the American Dental Association to assist dental professionals in identifying quality providers of continuing dental education. ADA CERP does not approve or endorse individual courses or instructors, nor does it imply acceptance of credit hours by boards of dentistry.

CAPP designates this activity for 2 CE Credits



mCME articles in Dental Tribune have been approved by:  
HAAD as having educational content for 2 CME Credit Hours  
DHA awarded this program for 2 CPD Credit Points

By Scott L. Doyle, DDS

Preservation of the natural dentition is the primary goal of dentistry. Published surveys indicate that patients generally value teeth and express a desire to save their natural dentition in favor of extraction whenever possible.<sup>1,2</sup> Significant technological and biological improvements have been made in all disciplines of dentistry, making long-term retention of natural teeth more attainable. Patients entrust dental professionals to make appropriate recommendations regarding the maintenance and restoration of their oral health and function. It is essential to employ an evidence-based, interdisciplinary approach that addresses the interests of the patient when determining the best possible course of treatment.

In July 2014, the American Association of Endodontists, in collaboration with the American College of Prosthodontists and the American Academy of Periodontology, hosted a two-day Joint Symposium titled "Teeth for a Lifetime: Interdisciplinary Evidence for Clinical Success." Approximately 375 general dentists and specialists assembled in Chicago to focus on preserving the natural dentition.

The educational program included evidence-based presentations on advanced regenerative techniques, improvements in technology, minimally invasive restorative methods and best practices for interdisciplinary treatment planning. Dr. Alan Gluskin, chair of the 2014 Joint Symposium Planning Committee, concluded that the current evidence directs clinicians to consider saving the natural dentition as the first option when developing treatment plans. Dental implants are one of the most significant advancements in contemporary dentistry. This innovation has had profound effects on endodontic, periodontic and prosthodontic treatment planning for the rehabilitation of edentulous spaces and for teeth with an unfavorable prognosis.<sup>3</sup> Implant-supported restorations minimize unnecessary preparation of intact abutment teeth and allow fixed prosthodontic replacement when suitable abutments are absent. With appropriate usage and case selection, implant dentistry provides a viable option for the replacement of missing teeth.<sup>4,5</sup>

There has been an increasing trend toward replacing diseased teeth with

dental implants. Often, an inadequate or inappropriate indication for tooth extraction has resulted in the removal of teeth that may have been salvageable.<sup>6</sup> Teeth compromised by pulpal or periodontal disease have value and should not be extracted without thoroughly evaluating restorability and potential retention therapies.<sup>7</sup>

A recent systematic review published in the Journal of the American Dental Association highlights a key question: "Is the long-term survival rate of dental implants comparable to that of periodontally compromised natural teeth that are adequately treated and maintained?"<sup>8</sup> Nineteen studies with a follow-up period of at least 15 years were included in the analysis.

The results show that implant survival rates do not exceed those of compromised but adequately treated and maintained teeth. These findings support other studies comparing long-term survival of implants and natural teeth,<sup>9,10</sup> providing an important message: Periodontally compromised teeth can be retained with quality treatment and appropriate maintenance. Therefore, it may be advisable to postpone implant consideration for the periodontitis-susceptible patient to fully utilize and extend the capacity of the natural dentition.<sup>11</sup>

## Treatment planning options

A key focus of the Joint Symposium involved treatment planning decisions regarding endodontic treatment and implant therapy. Should a tooth with pulpal disease be retained with root canal treatment and restoration, or be extracted and replaced with an implant-supported restoration? This assessment involves a challenging and complex decision-making process that must be customized to suit the patient's needs and desires.<sup>12-14</sup> The topic has received considerable attention in the literature, the media and at dental continuing education courses. Endodontic treatment and implant therapy should not be viewed as competing alternatives, rather as complementary treatment options for the appropriate patient situation (Figs. 1a, b). Root canal treatment is indicated for restorable, periodontally sound teeth with pulpal and/or apical pathosis. Endodontic treatment on teeth with nonrestorable crowns or teeth with severe periodontal conditions is contraindicated, and other

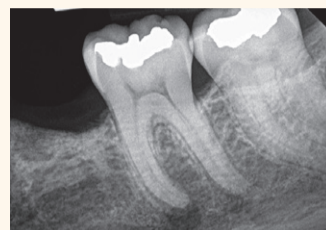

Fig. 1a. Pre-op image of tooth #19 with pulp necrosis and symptomatic apical periodontitis. The patient is interested in rehabilitation of the edentulous space. (Photos/Provided by American Association of Endodontists)

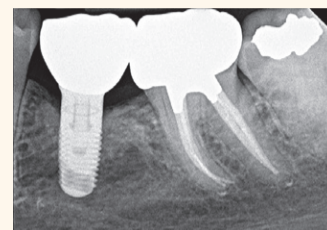


Fig. 1b. Three-year recall image. The patient has benefited from both root canal treatment and implant therapy. Courtesy of Dr. Tyler Peterson and the University of Minnesota School of Dentistry.

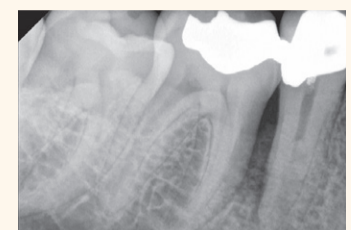

Fig. 2a. Pre-op image of tooth #29. Note lateral radiolucency and complex canal anatomy.

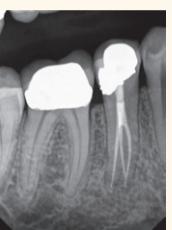


Fig. 2b. Two-year recall image reveals both excellent endodontic and restorative treatment. Note healing of lateral radiolucency. Courtesy of Dr. Joe Petrino.

| Authors                     | Number of Teeth | Follow-up (years) | Survival (percent) |
|-----------------------------|-----------------|-------------------|--------------------|
| Salehrabi and Rotstein (24) | 1,463,936       | 8                 | 97                 |
| Chen et al. (25)            | 1,557,547       | 5                 | 93                 |
| Lazarski et al. (26)        | 44,613          | 3.5               | 94.4               |

Table 1. Survival rates following initial nonsurgical root canal treatment. (Table/Provided by American Association of Endodontists)

options such as implant placement should be considered.<sup>15</sup> When making treatment decisions, the clinician should consider factors including outcome assessment, local and systemic case-specific issues, costs, the patient's desires and needs, esthetics, potential adverse outcomes and ethical factors.<sup>16</sup>

## Outcome assessment: Success and survival

Treatment outcomes play a key role in the assessment of different treatment options. Patients often ask whether a procedure is going to be successful or not. This question can be challenging for a clinician to answer due to the variety of reported outcomes in the literature.<sup>17</sup> There are differences in the methodology and criteria used to evaluate the outcomes for root canal treatment and implant prosthetics, which makes comparisons between success rates difficult, if not impossible.<sup>18</sup> Endodontic studies have historically used "success" and "failure" as outcome measures and have focused on a strict combination of radiographic and clinical criteria.<sup>19</sup> In contrast, the implant literature has primarily reported "survival,"<sup>20, 21</sup> i.e., the implant is either present or absent. Therefore, implant studies that solely evaluate survival as an outcome measure will likely publish higher success rates than endodontic studies that rely on biologic healing and factors related to the entire restored tooth. To establish more valid and

less biased comparisons, the same outcome measures should be used. A more patient-centered measure is to compare the outcome of survival, which is considered to be an asymptomatic tooth/implant that is present and functioning in the patient's mouth.<sup>22,23</sup>

Multiple large-scale studies including millions of teeth have used survival to assess the outcome following root canal treatment. An investigation using an insurance database of more than 1.4 million root canal-treated teeth demonstrated that 97 percent were retained within an eight-year follow-up period.<sup>24</sup> Other studies show similarly high survival rates (Table 1).<sup>25,26</sup> An epidemiological approach allows for the assessment of tooth retention from a large sample of patients experiencing actual care in private practices. Systematic reviews<sup>27</sup> and controlled studies from academic settings complement the previous findings. Two prospective trials each reported 95 percent survival rates at four years<sup>28</sup> and four to six years<sup>29</sup> for teeth after initial root canal treatment.

## Predictable tooth retention: Nonsurgical root canal treatment and restoration

The majority of endodontic treatment is performed by general dentists with a high degree of success.<sup>26</sup> For complex cases, referral to an endodontist with additional training and expertise may result in more

favorable outcomes<sup>30</sup> and positive patient experiences.<sup>31</sup>

Interdisciplinary care is important for the management of endodontically treated teeth. The restorative dentist plays a significant role in the outcome by providing an appropriate and timely restoration.<sup>32</sup> Root canal treatment is not complete until the tooth is coronally sealed and restored to function. Multiple studies have confirmed that a definitive restoration has a significant impact on survival.<sup>24,25,27,28,33</sup> Therefore, the likelihood of a favorable outcome increases with both skillful endodontic care and prompt restorative treatment (Figs. 2a, b).<sup>34</sup>

Advancements in technology aid in attaining high levels of tooth retention. The dental operating microscope, nickel-titanium instruments, apex locators, enhanced irrigation protocols and dentin preservation strategies are examples of improvements that allow clinicians to predictably manage a greater range of treatment options. Additionally, cone-beam-computed tomography facilitates more accurate diagnosis and improved decision-making for the management of endodontic problems.<sup>35,36</sup>

## Comparative studies: Endodontically treated teeth and single-tooth implants

Large-scale systematic reviews have addressed the relative survival rates of endodontically treated teeth and single-tooth implants. The Academy of Osseointegration conducted a meta-analysis using 13 studies (approximately 23,000 teeth) on restored endodontically treated teeth and 57 studies (approximately 12,000 implants) on single-tooth implants. The outcome data demonstrated no difference between the two groups during any of the observation periods.<sup>37</sup> Another systematic review supported by the American Dental Association compared the outcomes of endodontically treated teeth with those of a single-tooth implant-restored crown, fixed partial denture and no treatment after extraction. At 97 percent, the long-term survival rate was essentially the same for implant and endodontic treatments. Both options were superior to extraction and replacement of the missing tooth with a fixed partial

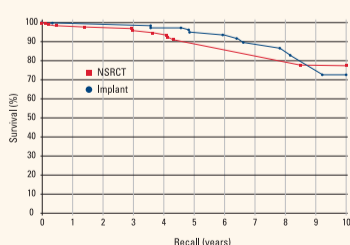


Fig. 3. A matched-case comparison of survival rates after treatment with either a restored endodontically treated tooth (n=196) or a restored single-tooth implant (n=196) performed at the same institution. J Endod 2006;31.

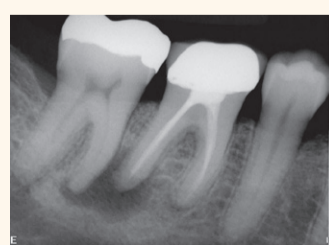


Fig. 4a. Pre-op image of tooth #30 with previous endodontic treatment and persistent apical periodontitis. A dentist initially recommended extraction and replacement of this tooth with an implant. The patient requested a second opinion from an endodontist who determined the tooth to be treatable.

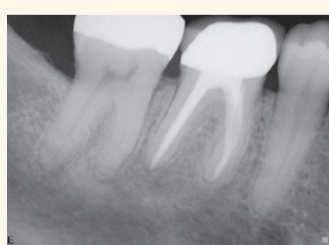

Fig. 4b. Four-year recall image demonstrates apical healing following nonsurgical retreatment. Accurate diagnosis prevented the unnecessary treatment of tooth #31. Courtesy of Dr. Martin Rogers.

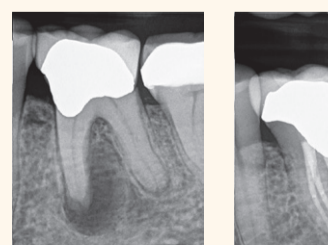


Fig. 5a. Pre-op image of tooth #19 with pulp necrosis and chronic apical abscess.

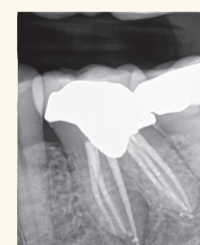


Fig. 5b. Two-year recall image demonstrates excellent endodontic treatment and healing of apical periodontitis. Courtesy of Dr. Deb Knaup.



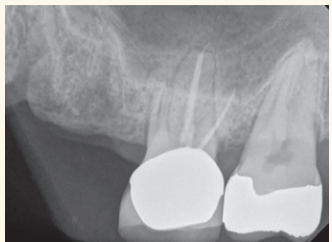

Fig. 6a. Pre-op image. Tooth #14 was determined to have a vertical root fracture of the MB root. The patient expressed a strong desire to retain the natural dentition but also to rehabilitate the edentulous space.

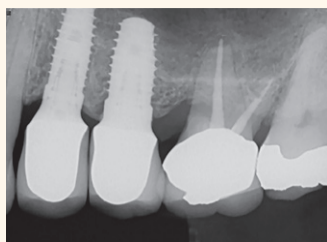


Fig. 6b. Two-year recall image. Tooth #14 had retreatment and resective surgery on the MB root. Two dental implants have restored the edentulous space. Courtesy of Dr. Brian Barsness and the University of Minnesota School of Dentistry.

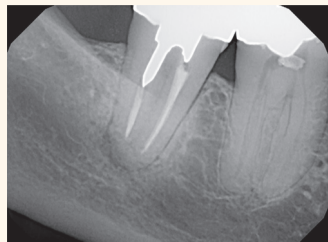


Fig. 7. Pre-op image.

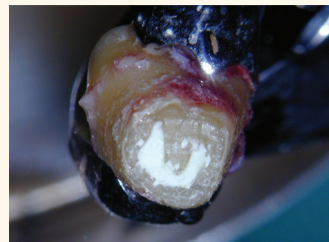

Fig. 8. Root-end filling with MTA.

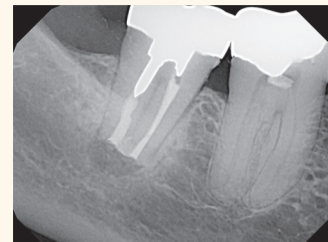


Fig. 9. Post-op image.

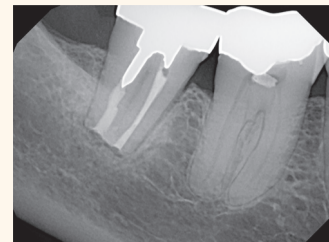


Fig. 10. Seven-month recall image.

denture.<sup>38</sup>

Retrospective studies also have compared the outcomes for the two treatment options. A study conducted at the University of Minnesota compared the outcomes of 196 restored endodontically treated teeth with 196 matched single-tooth implants.<sup>39</sup> Both groups had 94 percent survival rates. The survival curves for these two groups are provided in Figure 3. Another investigation from the University of Alabama provided similar results.<sup>40</sup> Based upon similar survival rates, the decision to treat a compromised tooth endodontically or replace it with an implant must be based on factors other than treatment outcome.<sup>37,41</sup> Several factors influence the decision-making process.<sup>42-44</sup> The following lists provide an overview of case-specific factors that should be considered in making this treatment decision.

### Systemic factors

- The list of potential risk factors for peri-implantitis or implant failure is extensive. It includes systemic disease, genetic traits, chronic drug or alcohol consumption, smoking, periodontal disease, radiation therapy, diabetes, osteoporosis, dental plaque and poor oral hygiene.<sup>45</sup>
- There are few medical conditions that directly affect endodontic treatment outcomes. Risk factors that may be associated with decreased survival of root canal-treated teeth include smoking,<sup>46</sup> diabetes,<sup>28,46</sup> systemic steroid therapy<sup>28</sup> and hypertension.<sup>47</sup>
- Patients taking antiangiogenic or antiresorptive (i.e., bisphosphonates) medications may have an increased risk for developing medication-related osteonecrosis of the jaw. This may affect treatment planning for both implant and endodontic treatment.
- It is generally recommended to wait for the completion of dental and skeletal growth prior to implant placement.<sup>48</sup>

### Local factors

- Accurate diagnosis.
- Restorability assessment: removal of caries/restorations; adequate ferrule.
- Strategic nature of the tooth as it fits into the comprehensive restorative plan.
- Caries risk and oral hygiene.
- Periodontal assessment: tissue biotype, adequate biologic width.
- Presence of crack(s), root fracture(s), resorption.
- Occlusion and parafunction.
- Teeth with less than two proximal contacts and those serving as fixed partial denture abutments may have lower survival.<sup>27</sup>
- Need for adjunctive treatment (crown lengthening, orthodontic extrusion, sinus lift, bone graft, etc.), which may impact financial cost and time to function.
- Quantity and quality of bone.
- Proximity to anatomical structures (maxillary sinus, inferior alveolar nerve, etc.)
- Implant esthetics in the anterior region may be challenging.<sup>49</sup>

In addition to systemic and local factors, it is critical to include the patient's concerns during treatment planning. Common patient-centered factors include costs, treatment duration, satisfaction with treatment and the potential for adverse outcomes.

Financial considerations can influence a patient's decision when weighing treatment options. The availability of dental insurance may also impact choices.<sup>50</sup> Endodontic treatment and restoration offer considerable economic advantages to the patient.<sup>51-53</sup> A benefit of root canal treatment is the short time frame required to completely restore both dental function and esthetics. In one study of about 400 patients, the restored single-tooth implant showed a longer average and median time to function than similarly restored endodontically treated teeth. Additionally, the implant group had a higher incidence of post-treatment complications requiring subsequent treatment interventions.<sup>39</sup> This increased post-operative care can impact patients in terms of additional visits, lost wages and unforeseen costs. Clinicians should consider the patient's preferences, which are often related to function, comfort and esthetics. Tooth loss is associated with an impaired quality of life,<sup>54</sup> and surveyed patients express a clear desire to save their natural dentition whenever possible.<sup>2</sup> Large-scale surveys of post-endodontic patients have demonstrated that endodontic treatment not only preserves the natural tooth, but also significantly improves patients' quality of life.<sup>55</sup> More than 97 percent of patients report being satisfied with their endodontic treatment.<sup>31</sup> If an implant is used to restore an edentulous space, a similarly high percentage of patients have a positive experience with implant therapy.<sup>56</sup> Furthermore, comparative studies demonstrate that patients report a high degree of satisfaction with the overall experience following both procedures.<sup>55</sup>

Despite high survival rates, both endodontically treated teeth and implants are susceptible to complications. Nonrestorable caries, prosthetic failures, periodontal disease, crown/root fractures and specific endodontic factors are examples of complications following root canal treatment.<sup>57</sup> Complications associated with implants and related prostheses include: surgical, implant loss, bone loss, peri-implant soft-tissue, mechanical and esthetic/phonetic.<sup>58</sup> A retrospective study directly compared the rates of additional interventions related to complications. Implant cases had a substantially higher need for subsequent intervention and maintenance visits than endodontically treated teeth.<sup>40</sup> However, a more recent prospective study suggests that patients from both groups have minimal complications at one-year follow-up.<sup>15</sup>

### Endodontic retreatment options

The consequences of failure and subsequent treatment differ be-

tween endodontics and implants. Endodontic failure can usually be addressed successfully by retreatment, microsurgery or by extraction and potential implant placement. Intervention after implant failure may vary from minimal restorative repairs to multiple corrective surgeries and/or the use of a different prosthesis.<sup>59</sup>

Nonsurgical retreatment, or revision, is often the first choice to address post-treatment apical periodontitis,<sup>60,61</sup> provided that the tooth is suitable for further restoration and that the restoration will have a good long-term prognosis (Figs 4a, b).<sup>62</sup> Current best evidence indicates that the survival of nonsurgical retreatment is similar to that of primary treatment, and that the two treatments share similar prognostic factors.<sup>63</sup> Two studies specifically evaluated survival following retreatment. An epidemiological study using an insurance database of 4,744 retreated teeth reported an 89 percent survival rate at five years<sup>64</sup> and a prospective trial of 858 retreated teeth reported a 95 percent survival at four years.<sup>28</sup> Modern techniques and rationale contribute to excellent potential outcomes for retreatment. An important factor when considering retreatment is the ability to identify and address the etiology of post-treatment disease.<sup>65</sup> Primary sources of nonhealing are persistent intracanal microorganisms or ingress of microorganisms following treatment. If the etiology of the problem is deemed correctable via an orthograde approach, retreatment is often the first choice. If not, a surgical approach may be the more predictable option.<sup>65</sup> Contemporary endodontic microsurgery has undergone significant technological and procedural advancements.<sup>66,67</sup> Recently performed studies suggest that microsurgical techniques using biocompatible root-end filling materials provide significant improvements over traditional methods. A meta-analysis showed contemporary microsurgical techniques to have a significantly improved outcome (94 percent) compared to older techniques and instruments (59 percent).<sup>68</sup> A recent systematic review investigating current microsurgery found survival rates of 94 percent at two to four years and 88 percent at four to six years, indicating that teeth treated with endodontic microsurgery tended to be lost at low rates over the time studied.<sup>69</sup> Microsurgery, with appropriate case selection, is a predictable procedure for teeth that may have been considered for extraction in the past.

### Ethics and interdisciplinary consultation

Clinicians are ethically bound to inform patients of all reasonable treatment options, explain the risks and benefits involved with the available treatment options, and obtain informed consent before initiating treatment. This information should be conveyed in an impartial manner. Patients value participation in the decision-making process and should be encouraged to exercise autonomy by communicating their preferences.<sup>70</sup> Clinical treatment decisions regarding either endodontic

treatment or tooth extraction with implant therapy must always be made in the best interest of the patient using the best, most current evidence.

Should it be necessary, experts from the dental team may need to be called upon to assist the clinician in rendering the highest quality of care (Figs 5a, b). The standard of care must be applied equally to all clinicians, generalists and specialists alike. The AAE's Endodontic Case Difficulty Assessment Form and Guidelines provides valuable information to aid the clinician in case selection and determining whether to treat or refer. Patients are deserving of the best possible outcome for each case. Interdisciplinary communication and collaboration during treatment planning maximize this likelihood. Specialists and restorative dentists should be viewed as partners in the treatment planning team. Endodontists are uniquely positioned to evaluate the restorability and prognostic longevity of teeth and recommend whether to attempt natural tooth preservation or consider extraction and replacement with an implant.<sup>71</sup> Likewise, the endodontist should be well-versed in implant treatment planning to assist patients and referring colleagues in making an informed choice regarding all replacement options.<sup>72,73</sup>

If a tooth has a questionable prognosis, the endodontic specialist becomes an indispensable part of the treatment planning team. The endodontist has experience with various treatment options that have potential to preserve the natural dentition. Consultation regarding a questionable tooth is often in the patient's best interest prior to considering extraction. If the prognosis of a restorable tooth is categorized as questionable or unfavorable in multiple areas of evaluation, extraction should be considered after appropriate consultation with all relevant specialists. Only then is the decision to extract an informed choice. Extraction is an irreversible treatment, but if necessary, dental implants provide an excellent option to replace missing teeth (Figs. 6a, b).

### Case report

A case report (Figs. 7-10) demonstrates an alternative treatment option for a patient to save a natural tooth. A 70-year-old female presented to an endodontist's office with a complaint of persistent pain to biting. Tooth #31 had a history of root canal treatment and coronal restoration. A thorough examination, including CBCT, led to the diagnosis of previously treated tooth #31 with symptomatic apical periodontitis. A detailed explanation of the risks and benefits associated with all treatment options was presented. The patient expressed a strong desire to save her tooth and consented to intentional replantation. Tooth #31 was atraumatically extracted and continuously hydrated with Hanks' Balanced Salt Solution. No cracks or fractures were visible. Apical microsurgery was performed extraorally. The root end was resected, ultrasonically prepared and filled with mineral trioxide aggregate. The tooth was replanted. The patient remains asymptomatic and very satisfied

with her treatment.

A recent systematic review and meta-analysis revealed a mean survival rate of 88 percent for intentional replantation.\* With careful case selection, intentional replantation may allow for a reasonable, cost-effective treatment option for teeth that do not heal following endodontic treatment. Clinicians are advised to explore all options before recommending extraction. Referral to an endodontist can aid in the retention of a compromised tooth.

### Conclusion

Patients are living longer; therefore, preservation of the natural dentition is more important than ever. Helping patients maintain their "Teeth for a Lifetime" is the fundamental goal of dentistry and often aligns with the desires of the patient. A wide range of endodontic procedures result in a high level of tooth retention and patient satisfaction. Large-scale studies provide strong support that the restored endodontically treated tooth offers a highly predictable, long-term approach to preserving "nature's implant" — a tooth with an intact periodontal ligament. Thus, excellent endodontic treatment followed by an immediate restoration of equal quality promises to give patients service and function while maintaining their esthetics for years. The results of multiple studies indicate that the high survival rates for the natural tooth are similar to those reported for the restored single-tooth implant. Therefore, clinicians must consider additional factors when making treatment planning decisions, all of which must be in the best interest of the patient. Endodontic treatment and implant therapy should not be viewed as competing alternatives, rather as complementary treatment options for the appropriate patient situation. [www.aae.org/colleagues](http://www.aae.org/colleagues)

This article originally appeared in ENDODONTICS: Colleagues for Excellence, Spring 2015. Reprinted with permission from the American Association of Endodontists, ©2015. The AAE clinical newsletter is available at [www.aae.org/colleagues](http://www.aae.org/colleagues).

A complete list of references is available from the publisher, and also at [www.aae.org/colleagues](http://www.aae.org/colleagues).

Case report contributed by Dr. Robert S. Roda.



Scott L. Doyle, DDS, MS. He currently practices with Metropolitan Endodontics in Minneapolis and serves as an associate clinical professor for the Division of Endodontics at the University of Minnesota. Doyle is a diplomate of the American Board of Endodontics. He is a past president of the Minnesota Association of Endodontists, chair of the AAE Continuing Education Committee and serves as a reviewer for the Journal of Endodontics. Doyle has written multiple articles in scientific journals, as well as a chapter on the "Endodontic Applications of CBCT" in an upcoming textbook.