

# implants

international magazine of oral implantology

3<sup>2013</sup>



| **research**

Retromolar bone grafts prior to implant placement – Part I

| **overview**

Periimplant lesions – causes and treatment options

| **case report**

GTR and recession coverage in immediate implantation





## DENTSPLY Implants – the new powerhouse in implant dentistry

**DENTSPLY Implants is the union of two successful and innovative dental implant businesses: DENTSPLY Friadent and Astra Tech Dental\*.**

DENTSPLY Implants offers a comprehensive line of implants, including ANKYLOS<sup>®</sup>, ASTRA TECH Implant System<sup>™</sup>, and XiVE<sup>®</sup>, digital technologies such as ATLANTIS<sup>™</sup> patient-specific CAD/CAM solutions, regenerative bone products and professional development programs.

DENTSPLY Implants is built upon the fundamental values of open-mindedness, a thorough scientific approach, a dedication to long-term clinical evidence and a

strong customer focus. Our current DENTSPLY Friadent and Astra Tech Dental customers can rest assured knowing that the world-class products they know will continue to be supported.

We are confident that dental professionals around the globe will come to recognize DENTSPLY Implants as their new partner of choice for integrated implant solutions, dedicated support and better patient care.

**We invite you to join our journey to redefine implant dentistry.**

\*DENTSPLY Implants was launched in North America April 2012. Transition to the new business in other geographical locations around the globe will follow.

**ANKYLOS<sup>®</sup> ASTRA TECH IMPLANT SYSTEM XiVE<sup>®</sup> ATLANTIS<sup>™</sup> ATLANTIS ISUS<sup>™</sup> FRIOS<sup>®</sup> EXPELTEASE<sup>™</sup> Facilitate<sup>™</sup>**

[www.dentsplyimplants.com](http://www.dentsplyimplants.com)



Dr Roland Hille

# Dear colleagues,

The 43<sup>rd</sup> International Annual Congress of the DGZI takes place in Berlin, Germany – the city that never sleeps and which is always good for a surprise.

As in the previous years, DGZI has compiled a programme which is good for a surprise as well, although in a strictly implantological sense. It was our task to elicit practical and reliable concepts to support your individual success, following the motto "from practice—for the practice". Our speakers have applied their concepts successfully for many years. Therefore, they will tune in this year's congress motto "Practice-oriented Implantology" with their speeches on Saturday. Our special prosthetic podium supports DGZI's team spirit, offering a symbiosis of dental and dental technical topics from the perspective of sustainability as the only way to modern dentistry.

A firework of practice-oriented science will be held on Saturday. Renowned speakers will give you an update on the state of the art of practice-relevant topics. As has been known for many years, DGZI favours plain language. Following various controversial and refreshing discussions on short implants, mini implants and periimplantitis, this year's topic is the "All-on-Four Concept—Practice-oriented and science-based?". We are pleased that Dr Paolo Malo has accepted our request to present his concept and arguments during an open discussion. I am looking forward to hearing the results gained by discussion group and auditorium. Feel free to join the discussion! DGZI will accept each individual opinion. Furthermore, DGZI scientific advisory board has launched a scientific study on the All-on-Four Concept at the University of Bonn, Germany. Its results will be presented at the 43<sup>rd</sup> International Annual Congress of the DGZI for the first time.

Our international podium will again provide you with a cross section of international science, since DGZI is known to be the implantological society which has the best network in Germany. Our corporate podiums and the legendary party night at the Wasserwerk, Berlin titled "Lounging, Dining, Clubbing", will take you on a trip to the adventurous side of Berlin.


I am looking forward to welcoming you at this special weekend, which celebrates the German unification, at its centre stage in Berlin for the 43<sup>rd</sup> International Annual Congress of the DGZI.

Yours,

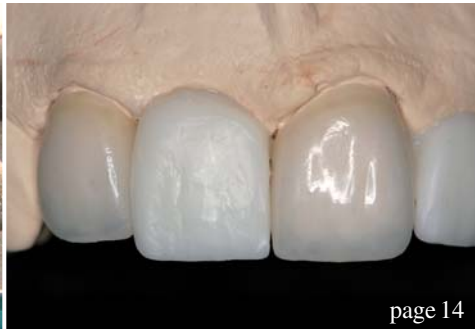Dr Roland Hille  
Scientific Director

Programme and  
registration form

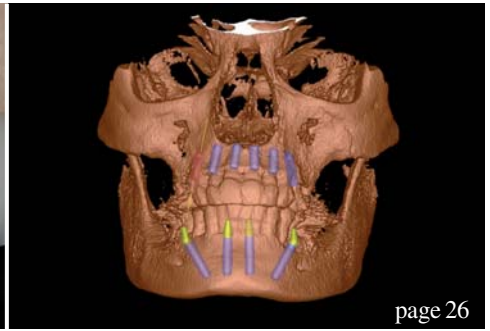




page 06



page 14



page 26

| editorial

03 Dear **Colleagues**  
| Dr Roland Hille

| research

06 **Retromolar bone grafts prior to implant placement—Part I**  
| Andreas Sakkas *et al.*

| case report

14 **GTR and recession coverage in immediate implantation**  
| Dr N. Papagiannoulis *et al.*

| overview

20 **Periimplant lesions — causes and treatment options**  
| Dr Georg Bach

26 **Fast & Fixed as an alternative treatment in cases of periodontitis profunda**  
| Dr Regina Schindjalova

| industry report

30 **The use of the LiteTouch Er:YAG laser in peri-implantitis treatment**  
| Prof. Tzi Kang Peng *et al.*

36 **Safe interdisciplinary navigation**  
| Dr Frank Schaefer *et al.*

41 **Peri-implantitis prophylaxis by sealing implant gaps and hollow spaces**  
| Prof. Dr Dr Claus Udo Fritzemeyer

| news

44 **Manufacturer News**

47 **News**

| meetings

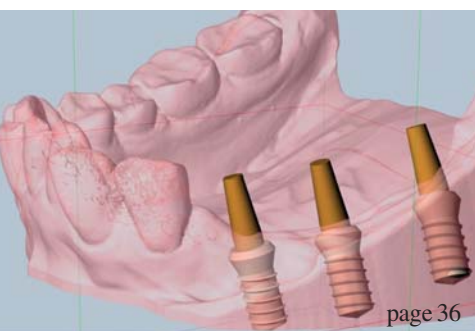
49 **Nobel Biocare Global Symposium 2013 in New York**  
| Nobel Biocare

| about the publisher

50 | imprint



Cover image courtesy of Isy by Camlog, [www.camlog.de](http://www.camlog.de)  
Original Background: ©Vladim Georgiev  
Artwork by Sarah Fuhrmann, OEMUS MEDIA AG.



page 36

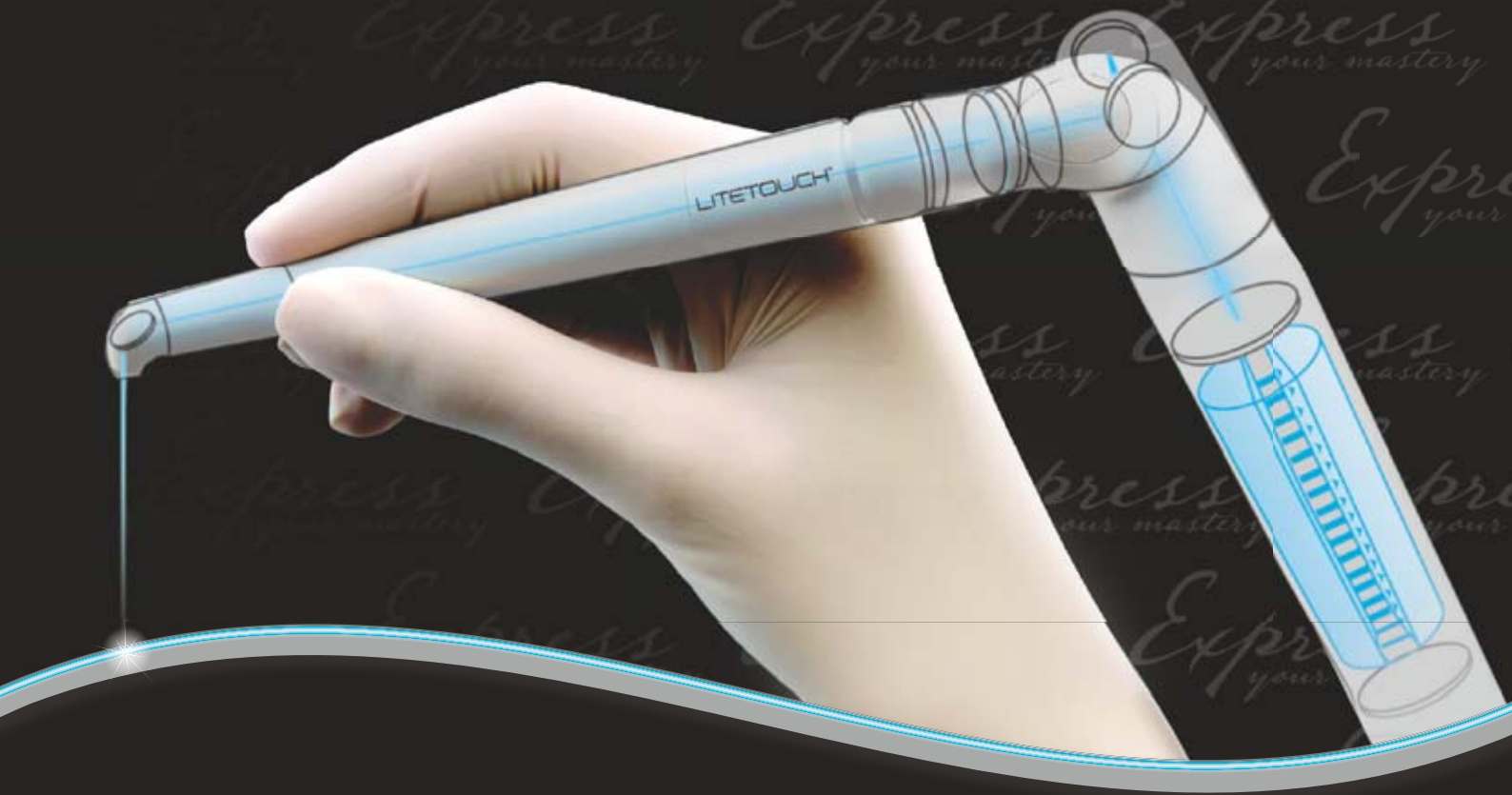

page 47



page 49

**Syneron**<sup>TM</sup>  
DENTAL LASERS



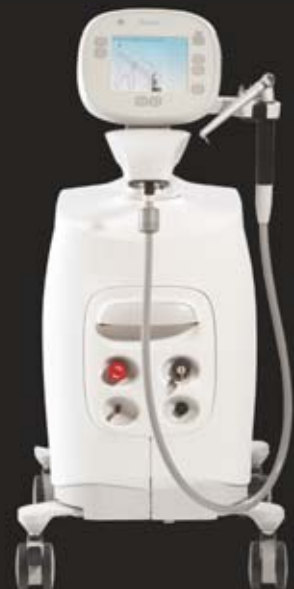Education. Technology. Family.

Join the Syneron Dental Lasers Family

presenting

**LITETOUGH**<sup>TM</sup>

The unique fiber-free Er:YAG laser  
that has changed the face of laser dentistry



L-1P87/692EN



To learn more about our innovative technology solutions,  
contact: [dental@syneron.com](mailto:dental@syneron.com), [www.synerondental.com](http://www.synerondental.com)



# Retromolar bone grafts prior to implant placement

## Outcomes and complications—Part I

**Authors** Andreas Sakkas, Carsten Winter, Frank Wilde & Alexander Schramm, Germany

### Introduction

The dental rehabilitation of partially or totally edentulous patients with oral implants has become common practice with reliable long-term results.<sup>1</sup> However, unfavourable local conditions of the alveolar ridge due to atrophy, periodontal disease, trauma sequel, malformation or neoplasia may cause insufficient bone volume, which may complicate the therapy of the masticatory function with dental implants.<sup>2</sup> When alveolar ridges lack the appropriate bone volume, additional surgical reconstructive procedures are required.

The use of autologous bone grafts with dental implants was described originally by Brånemark et al. in 1975, and today is a well-accepted procedure in oral and maxillofacial rehabilitation.<sup>3-5</sup> Insertion of an endosseous implant requires sufficient bone volume for complete bone coverage. Physiologically, an ideal bone grafting material should provide osteogenicity, osteoinductivity and osteoconductivity for new bone formation. Despite some recent advances in bone-substi-

tute technology, autogenous bone grafts remain the "gold standard" in reconstructive surgeries because of their osteoinductive, osteoconductive and non-immunogenic properties. Guided bone regeneration (GBR) is an alternative technique to onlay grafting for localised alveolar ridge augmentation prior to dental implant placement.<sup>6,7</sup> The clinical potential of membrane techniques for bone regeneration was recognised by Nyman et al.<sup>8</sup> They demonstrated that membranes act as a physical barrier when applied over bone defects, preventing the ingrowth of competing, non-osteogenic cells into the membrane-protected space.<sup>7,9</sup> Space provision, such as guided tissue regeneration, was shown to be effective in regenerating new bone on atrophied alveolar ridge, either vertically or horizontally, with the use of a membrane. Similar to onlay bone graft, which also serves as a space maintainer, GBR may incur similar complications that pertain to the use of onlay graft. Complications related to GBR may come from membrane exposure, miniscrew exposure and contamination. Exposed membranes or fixation screws often cause local inflammation with decreased bone formation.<sup>10</sup>

**Figs. 1 & 2** Exposure of the recipient site for the graft prior to harvest, measurement of its dimensions and the minimal time elapsed between graft harvest and placement.

**Fig. 3** Preoperative situation.

**Fig. 4** Mean surgical time of five minutes for harvesting.

**Fig. 5** Inferior osteotomy connecting the posterior and anterior vertical cuts.

**Figs. 6 & 7** Fixing of the block grafts after appropriate separation into smaller parts.

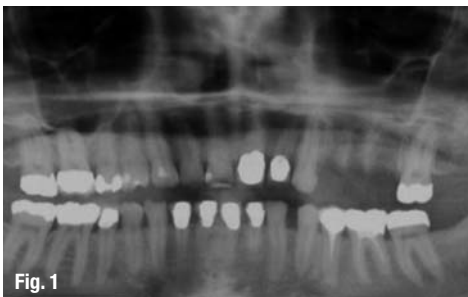


Fig. 1

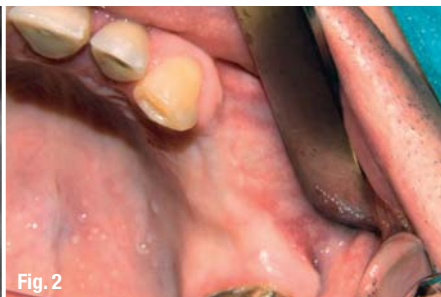

Fig. 2

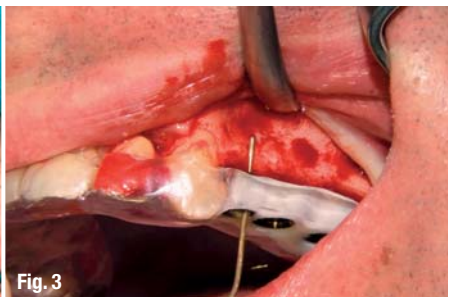

Fig. 3

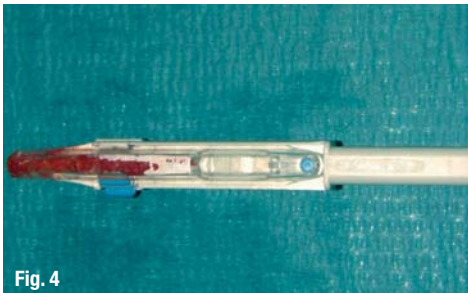


Fig. 4

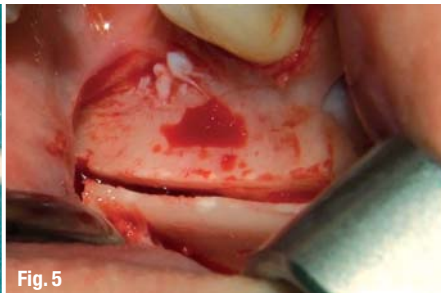


Fig. 5





Fig. 6

# Legacy™ System

100% Compatible with Zimmer® Dental



**Reality Check**  
Zimmer Customers

## Legacy™3 Implant

All-in-One Packaging includes implant, abutment, transfer, cover screw & healing collar €145

## Legacy™ Implant System Advantages:

**Industry-Compatible Internal Hex**

Prosthetic compatibility with Zimmer Dental Screw-Vent®, BioHorizons® & MIS implants

**Surgical Compatibility with Tapered Screw-Vent®**

No need to change surgical protocol or tools

**Three Implant Designs & Packaging Options**

Allows for selection based on price, packaging or thread design

**Legacy1:** €115 includes cover screw, healing collar & plastic carrier

**Legacy2:** €130 includes cover screw, healing collar & temporary abutment/transfer

**Legacy3:** €145 includes cover screw, healing collar & preparable abutment/transfer

**Micro-Threads**

Reduce crestal stress for improved initial stability

**Widest Range of Dimensional Options**

The entire Legacy system includes seven implant diameters (3.2, 3.7, 4.2, 4.7, 5.2, 5.7, 7.0mm) & six implant lengths (6, 8, 10, 11.5, 13, 16mm)



Laboratory Abutment	Straight Snap-On	Straight Contoured	15° Angled Contoured	Gold/Plastic	Zirconia/Ti Abutment	Plastic Temporary Abutment	Ball Attachment	GPS™ Attachment	Angled GPS™ Attachment	Multiple-Unit w/Cap & Transfer	Multiple-Unit w/Cap & Transfer
€60	€75	€75	€75	€90	€90	€30	€68	€90	€90	€75	€90

## Legacy™1

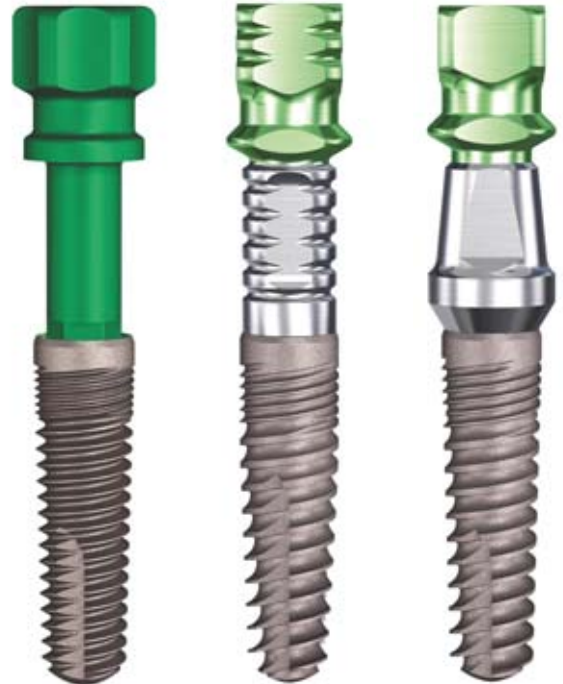Standard "V" Threads  
Matches Screw-Vent®

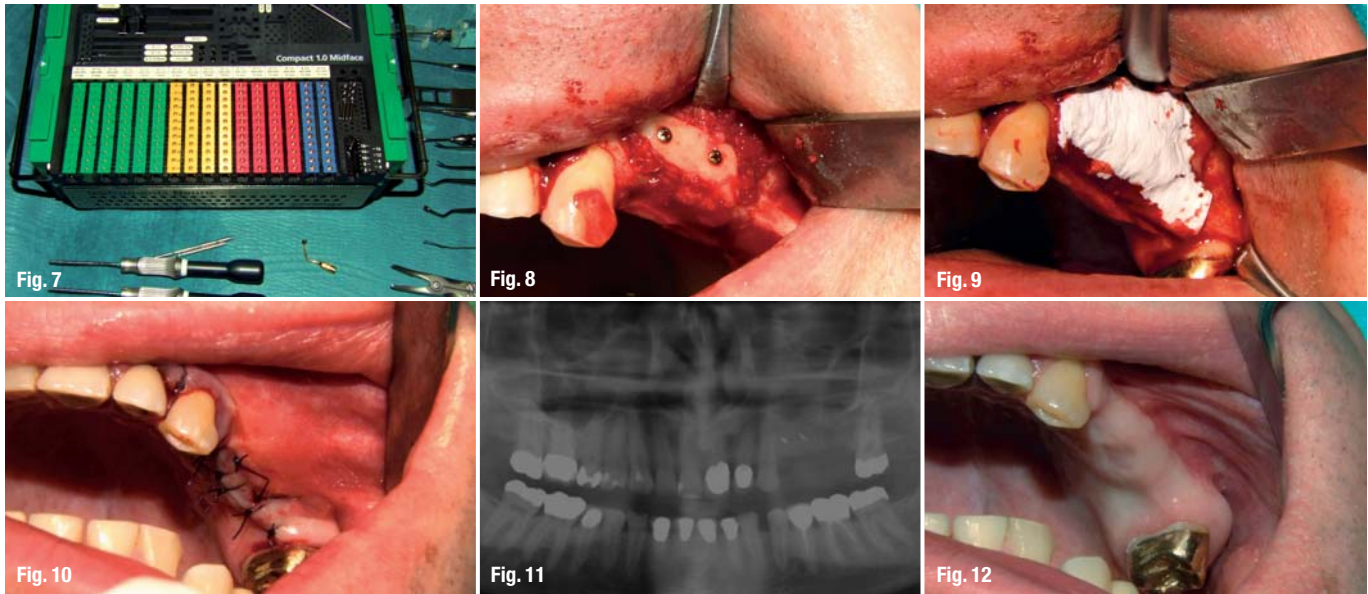
## Legacy™2

Spiral Threads  
for Increased Stability

## Legacy™3

Buttress Threads  
for Increased Surface





**Figs. 8 & 9** Filling of the small gaps between bone graft and alveolar crest with corticocancellous bone.

**Fig. 10** Periosteal releasing incisions.

**Fig. 11** Orthopantomographic control to evaluate the outcome of the surgical procedure.

**Fig. 12** Crestal incision and subperiosteal dissection of the alveolus, removal of the fixation screws. Implant site preparation with guidance from the laboratory-made splint. Positioning of the implants.

The significance of early membrane exposure on the regenerative outcome has been somewhat controversial in guided tissue regeneration and GBR procedures. Several studies have shown better responses when the membranes remained submerged than when they became exposed during healing.<sup>11,12</sup> However, other studies failed to show such differences.<sup>13,14</sup>

It must be pointed out that patients affected by partial edentulism do not easily accept major surgical procedures that may imply hospitalisation or general anaesthesia. These disadvantages, together with the fact that dental implants do not demand a large amount of bone, lead to the growing use of autogenous block bone grafts from intraoral sources rather than from extraoral.<sup>15-20</sup>

The use of the mandible as a donor site is said to be less invasive, to save surgical and anaesthetic time and to be accomplished in the outpatient operatory.<sup>13,21,22</sup> Harvesting of bone grafts from the retromolar region has been reported several times before.<sup>22-26</sup> In the repair of localised alveolar defects, bone grafts from the retromolar region offer several benefits: a) the proximity of donor and recipient sites that reduces operative and anaesthetic time; b) conventional surgical access; and c) making them ideal for outpatient implant surgery. Minimal discomfort and decreased morbidity are also reported for this type of bone grafting.<sup>27-29</sup> This technique can be combined with impacted third molar extractions.<sup>30</sup>

The purpose of the present retrospective study was to evaluate the surgical success and to assess the rate of complications that arise from harvesting retromolar bone grafts in a group of partially edentulous patients prior to implant placement. We used a two-stage technique. In the first surgical stage, one or more cortico-

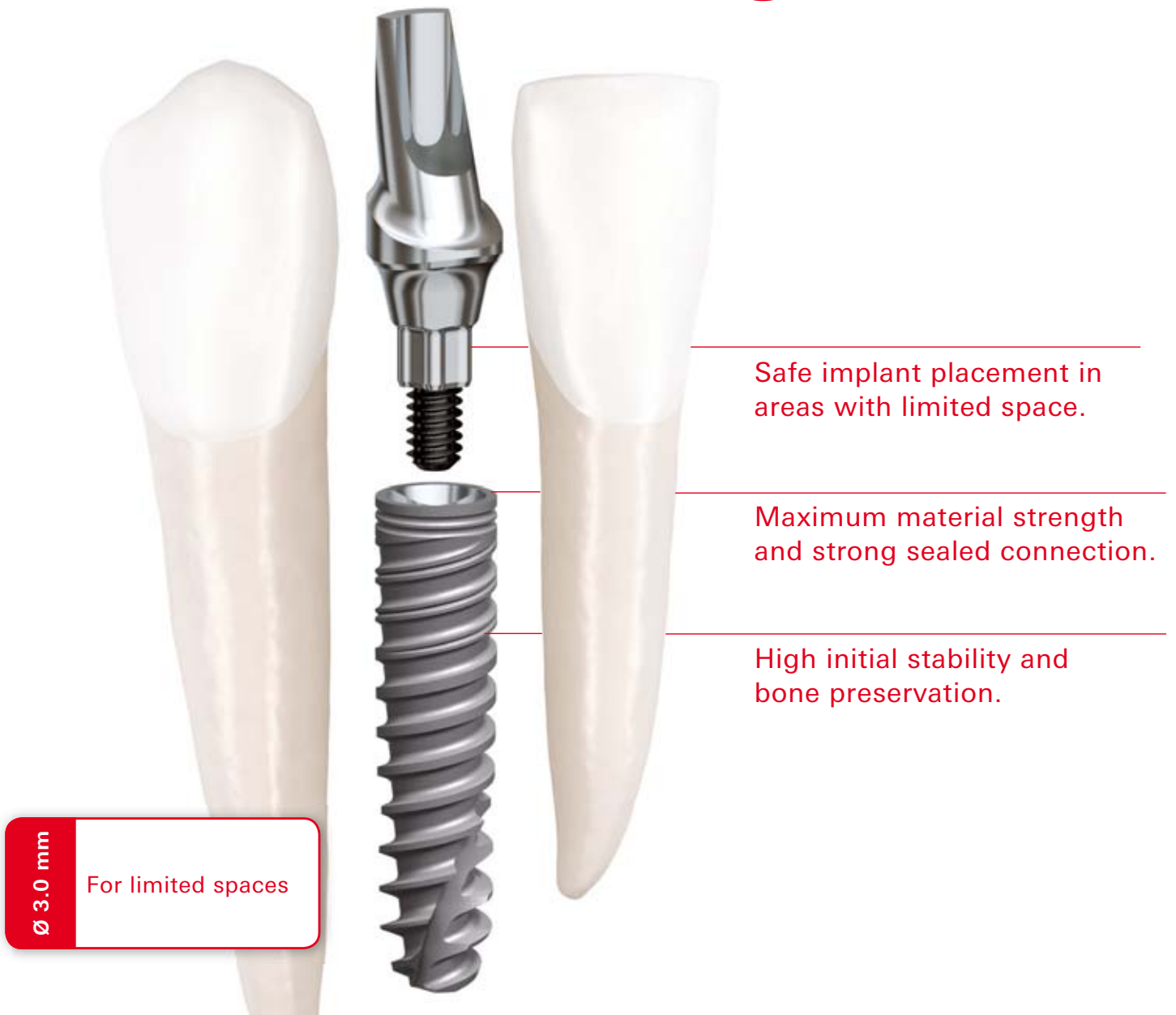cancellous bone blocks harvested from the retromolar region were fixed with osteosynthesis titanium screws to the recipient site as onlay grafts to achieve a horizontal and/or vertical augmentation of the ridge volume. In the second procedure, three to six months later, the screws were removed and implants were placed. The results regarding bone augmentation, donor and recipient site morbidity, bone graft stability and resorption prior to implant placement were recorded during the postoperative period and healing phase. Complications associated with this procedure mostly involve infection, incision line opening, nerve dysfunction, wound dehiscence, loss of portion of the bone graft, and graft mobilisation (Table 1).<sup>31</sup> A short review of the literature is presented in Table 2.

### Materials and methods

A consecutive retrospective study was conducted on patients who underwent retromolar onlay bone grafting from January 2008 until January 2011. Files of 86 patients (77 males and 9 females) reporting 104 bone graft operations were reviewed. Patients ranged in age from 20 to 58 years (average 37.9 years). From the current study, patients were excluded if their data covered: a) grafting of bone defects caused by tumour resections, osteoradionecrosis and bisphosphonate-associated osteonecrosis, b) grafting of bone defects in syndrome patients with craniofacial involvement and with congenital malformations, such as cleft patients, c) grafting of extraction sockets and intraalveolar defects simultaneously with immediate implant placements and d) augmentations including the application of distraction osteogenesis. Medical history, cause of tooth loss and smoking status at the time of operation were recorded. All patients underwent primary clinical and radiographic examinations and were diagnosed as having an inadequate quantity of bone for implant placement.



# Smaller and stronger.



**It's called NobelActive 3.0.** This unique implant is the ideal solution for narrow spaces in the anterior region. The drilling procedure is designed to retain as much bone as possible, while the implant body and thread design condenses bone during insertion enhancing initial stability. The sharp apex and cutting blades enable you to adjust the implant position for optimal

restorative orientation. Together with the strong sealed connection and built-in platform shifting, NobelActive 3.0 allows you to safely produce excellent esthetic results. After 45 years as a dental innovator we have the experience to bring you future-proof and reliable technologies for effective patient treatment. **Their smile, your skill, our solutions.**



Visit [nobelbiocare.com/active3](http://nobelbiocare.com/active3)

