

cosmetic dentistry

— beauty & science

2²⁰¹²

| **special topic**

Clinician's guide
for porcelain laminate veneers

| **research**

Dentine hypersensitivity: Simplified

| **case report**

Aesthetics and function:
Orthodontic–surgical collaboration
as a key to success

0377113

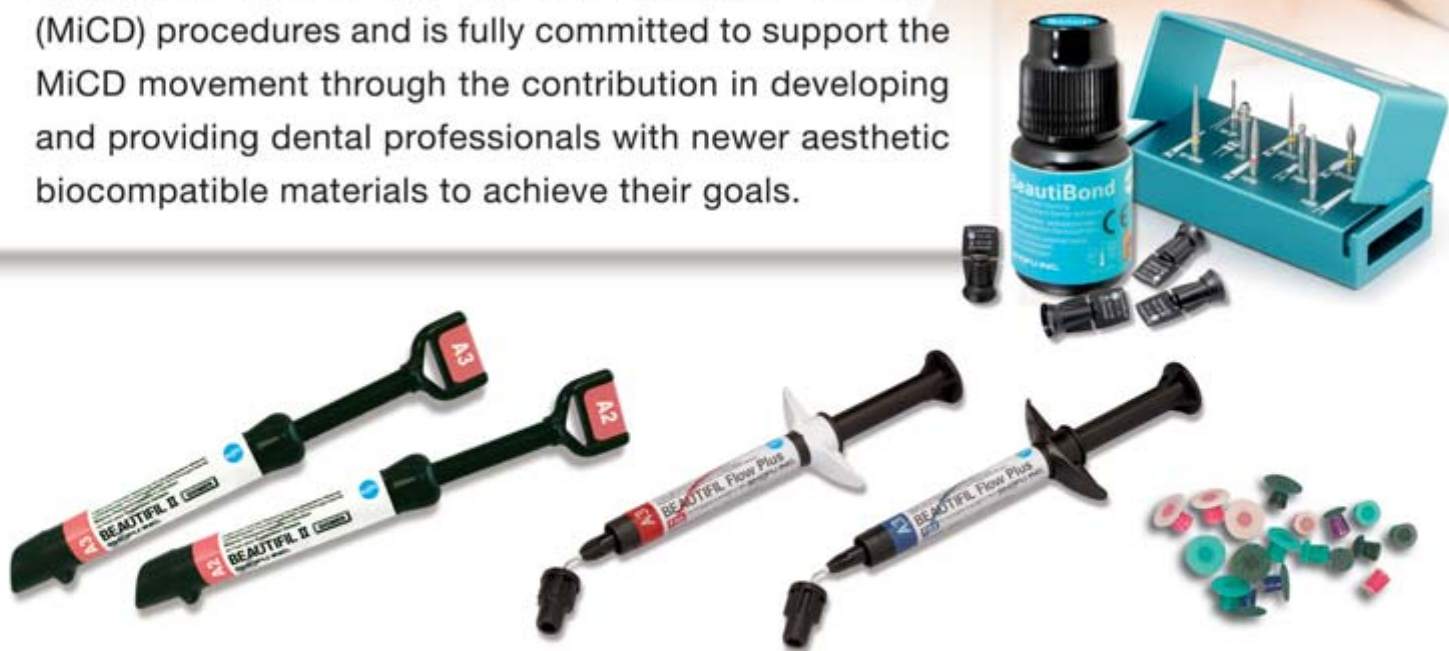

Adopt the trend...



Minimally Invasive
Cosmetic Dentistry

SHOFU recognizes the development of new clinical techniques in minimally invasive cosmetic dentistry (MiCD) procedures and is fully committed to support the MiCD movement through the contribution in developing and providing dental professionals with newer aesthetic biocompatible materials to achieve their goals.



For more information, simply contact your nearest **SHOFU** dealer.



SHOFU INC. SINGAPORE BRANCH

Tel (65) 6377 2722 Fax (65) 6377 1121 eMail mailbx@shofu.com.sg website www.shofu.com.sg

Dear Reader,

_Welcome to this year's second edition of **cosmetic dentistry**!

As the Co-Editor-in-Chief of the official journal of the Asian Academy of Aesthetic Dentistry (AAAD), I am excited to invite you to the 12th AAAD and 23rd Japan Academy of Esthetic Dentistry (JAED) joint meeting in Sapporo, Japan, from 20 to 22 July 2012. We are expecting another wonderful meeting that will bring all our academy members together in sharing precious knowledge, expertise and friendship.

The JAED, which has nearly 4,000 members, has set a beautiful location for the meeting: Sapporo, which attracts many tourists for the Sapporo Summer Festival, a cheerful event that takes place in the heart of the city. The organising committee has put great effort into the scientific programme, with an emphasis on integrating aesthetic dentistry to meet the patient's needs and desires. Among the invited speakers, Dr Marcos Vargas, professor at the University of Iowa, will present on anterior composite restorations; Dr Mark Latta, professor and Dean of the Creighton University School of Dentistry, on posterior composite restorations; Dr Wynn Okuda, past President of the American Academy of Cosmetic Dentistry (AACD), on contemporary cosmetic dentistry in the daily practice; and me, on how to maximise aesthetic success with tooth whitening.


A new introduction to the conventional joint meeting this year is the academy presidents' lecture section, with Dr Hisashi Hisamitsu representing the AAAD, Dr Akira Senda the JAED, and Dr Ronald Goodlin the AACD.

One of the major highlights will be the special lectures by country representatives of our AAAD. We are all anticipating a great meeting with considerable active participation by all of our academy members!

Our second edition of **cosmetic dentistry** is a continuum of the first edition, which focused on the minimally invasive cosmetic dentistry concept. The clinical articles and case reports beautifully illustrate how to formulate a smile design and provide step-by-step procedures for successful porcelain laminate veneers.

I would like to thank our readers, authors, supporting companies and the **cosmetic dentistry** team for their continuous support in making this magazine extraordinary, and I am confident that you will enjoy this issue!

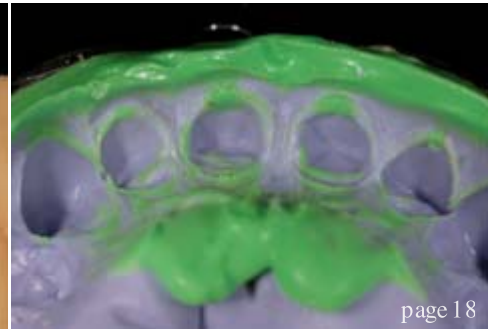
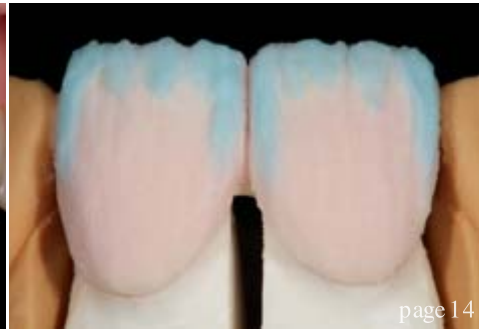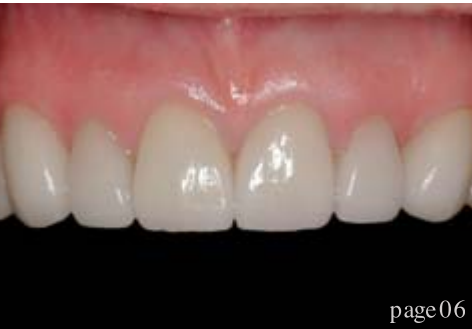Yours faithfully,



Dr So Ran Kwon
Co-Editor-in-Chief
President, Korean Bleaching Society
Seoul, Korea



Dr So Ran Kwon
Co-Editor-in-Chief



| editorial

03 Dear Reader

| Dr So Ran Kwon, Co-Editor-in-Chief

| special topic

06 The five-phase key to the Pros GPS:
Clinician's guide for porcelain laminate veneers

| Dr Seok-Hwan Cho

14 **On smile design:** Conservatively placed
IPS d.SIGN veneers to correct a diastema

| Harald Heindl & Dr Stephen Phelan

18 **Lithium disilicate**—An effective solution
for aesthetically demanding indications

| Dr Igor Ristić

| research

22 Dentine hypersensitivity: **Simplified**

| Dr Fay Goldstep

| case report

26 **Aesthetics and function:** Orthodontic–surgical
collaboration as a key to success

| Drs Martin Jaroch & Friedrich Bunz

32 **Ethical smile design** with the **Inman Aligner**—
A case study

| Dr Andrew Wallace

| industry news

36 **CLEARFILS³ BOND PLUS:**
High-tech and high speed for high performance

| Kuraray

| news

38 **Mission: Passion, ethics and professionalism**

| Letter from Dr Luca L. Dalloca, new President of ESCD

| meetings

40 **International Events**

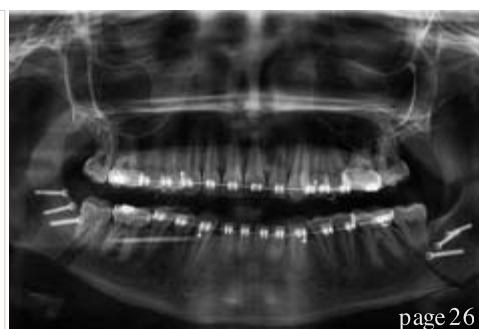
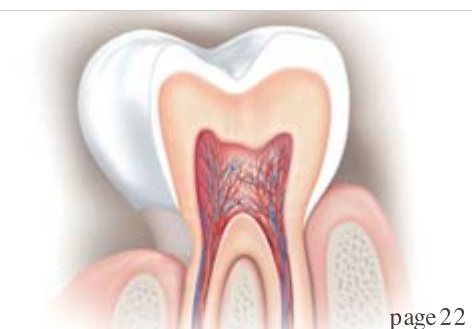| about the publisher

41 | submission guidelines

42 | imprint



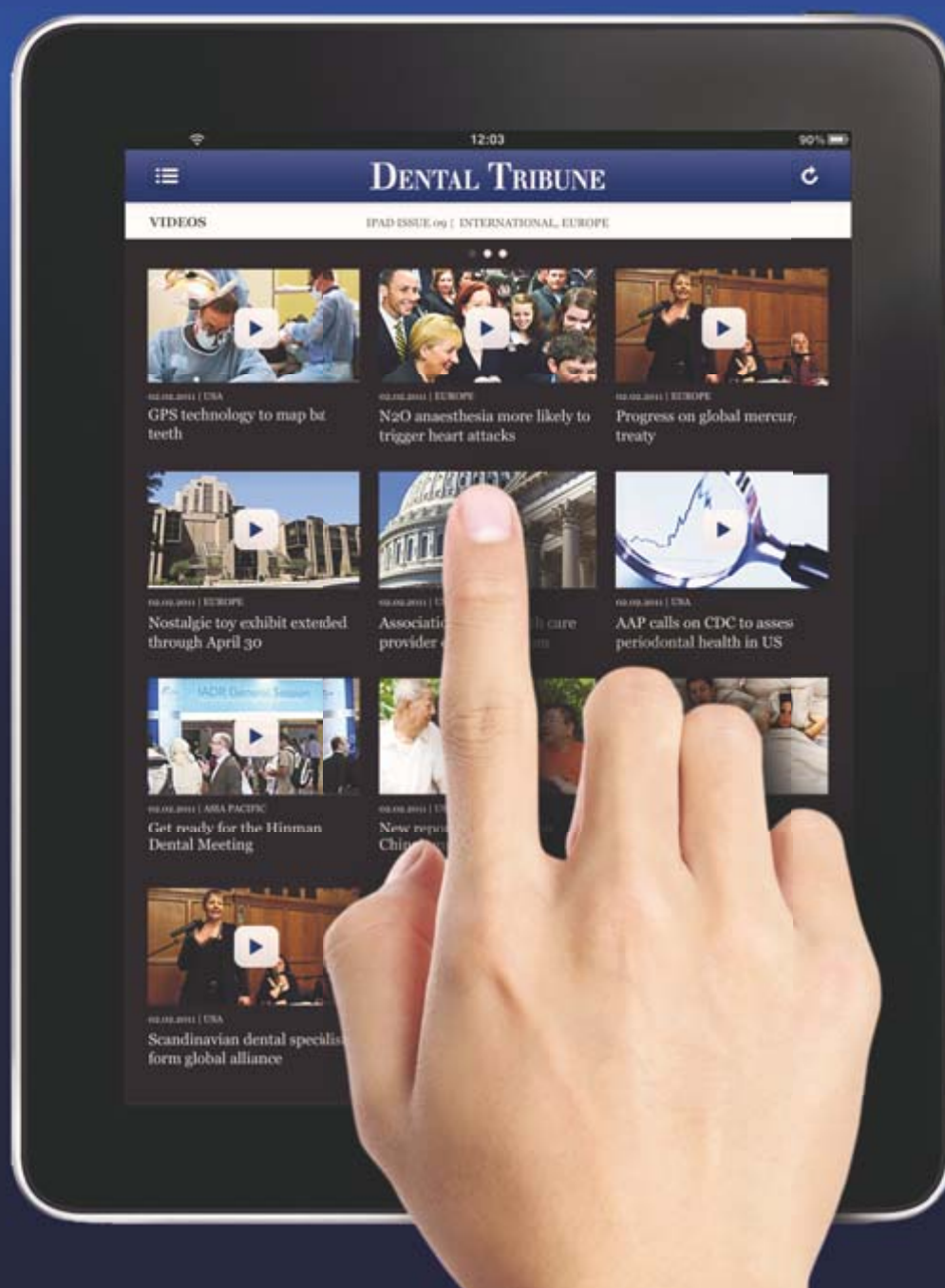Cover image courtesy of
BestPhotoStudio.



Dental Tribune for iPad – Your weekly news selection

Our editors select the best articles and videos from around the world for you every week. Create your personal edition in your preferred language.

ipad.dental-tribune.com

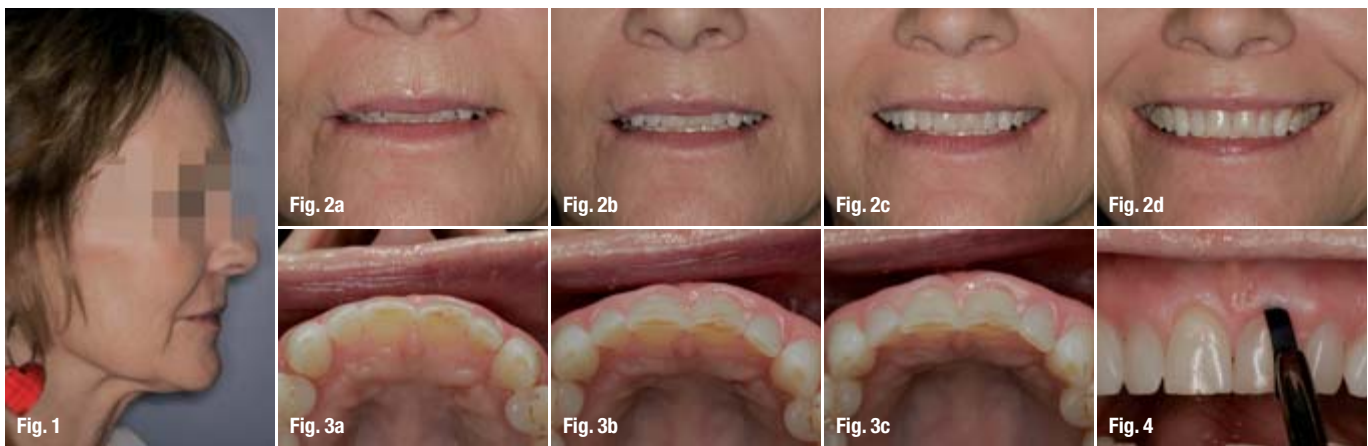

DENTAL TRIBUNE

— The World's Dental Newspaper —

The five-phase key to the Pros GPS: Clinician's guide for porcelain laminate veneers

Author_Dr Seok-Hwan Cho, USA

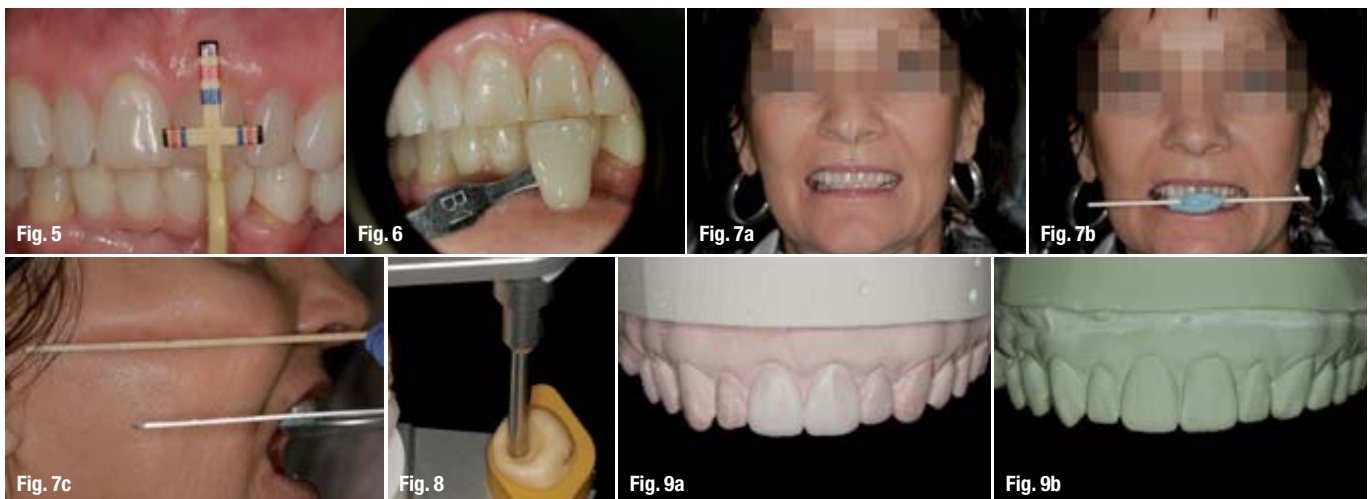

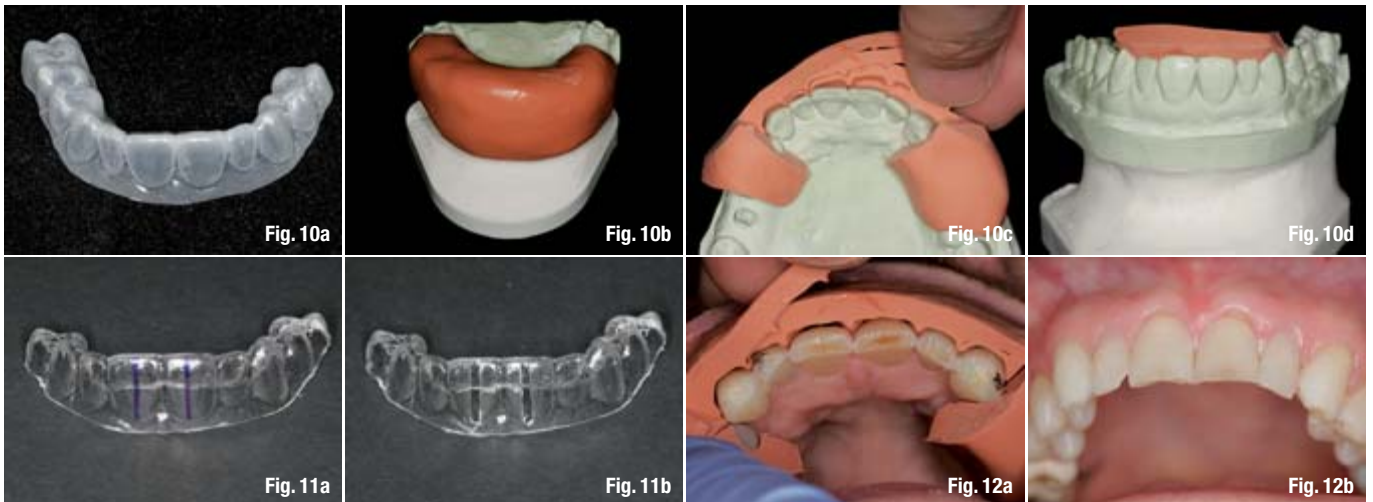
_Introduction

Porcelain laminate veneers (PLVs) have become a reliable treatment option because of recent advances in resin cements and ceramic materials. The advantages of PLVs include minimal reduction of enamel, superior aesthetic properties, great colour stability, and reliable bonding to the enamel. However, failures of PLV treatment, such as the patient's dissatisfaction with the aesthetic appearance and

ceramic fracture, continue to trouble both clinicians and patients. They stem from incorrect diagnosis, improper material selection, and defective tooth preparation. Therefore, the success of PLV treatments depends on the systematic and comprehensive assessment of patients and the scientific selection of dental materials.¹

Therefore, before a clinician starts to prepare teeth for veneers, it is critical that a comprehensive





and detailed treatment plan first be completed. It is equally critical that the treatment plan be discussed with the patient. Based on the author's experience and recommendations from other prominent authorities in aesthetic dentistry, a dentist must obtain the big picture, from the initial patient evaluation all the way to maintenance of the completed PLVs.

The purpose of this article is to introduce a step-by-step guide for PLVs. We could title it "the Pros GPS", since it is intended to guide readers to successful veneer restoration outcomes, both aesthetic and functional, by helping them avoid some of the pitfalls encountered by many dentists during PLV treatment. There are five phases to the Prosthodontic GPS: diagnosis, preparation design, provisionalisation, material selection and cementation.

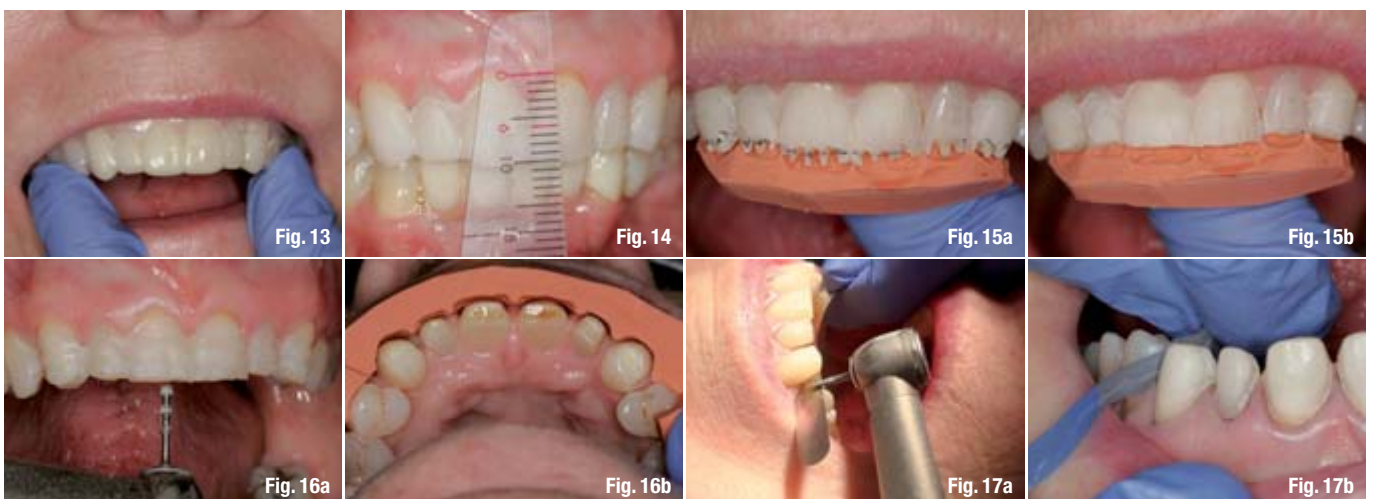Diagnosis

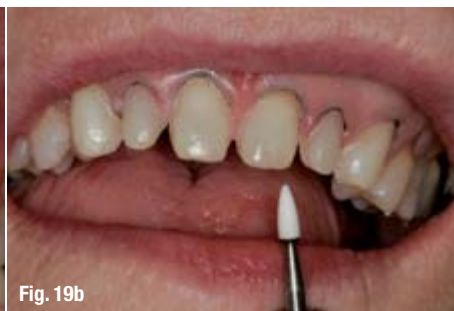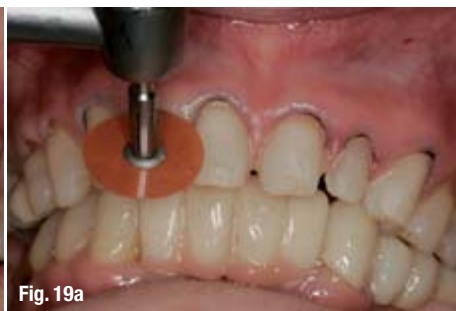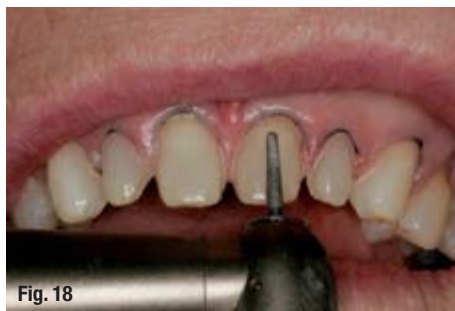A 61-year-old Caucasian female patient with minimal medical history presents for correction of her maxillary anterior teeth. She wants you to make

her teeth more rounded in order to enhance her feminine and youthful smile. How would you proceed?

First, start with facial and smile analysis. If you do not need to change the vertical dimension of occlusion, a profile evaluation such as E-line or the nasolabial angle is more important than a facial proportion evaluation (Fig. 1). The E-line profile evaluation is based on the maxillary anterior tooth position (sagittal angulation). If there is a large discrepancy between the average (anatomic) value and the patient's value, you may need to consider orthodontic treatment prior to PLV treatment. In addition, the symmetry and shape (such as ovoid or square) of the patient's face must be evaluated.

For smile analysis, record the patient's gradual smile change from a rest (repose) position to a dynamic and full-smile position (Figs. 2a-d). This series of photographs will enable you to evaluate the patient's lip mobility and the smile line, which is an imaginary line drawn along the incisal edges of the maxillary anterior teeth. Based on the rest posi-





tion photograph, you can evaluate how much of the maxillary anterior teeth is displayed below the patient's upper lip. This incisal display depends on the age and sex of the patient.² The full-smile photograph will enable you to evaluate a high lip line and the buccal corridor. The tooth-surface photographs can be taken in three planes: incisal third, middle third and cervical third (Figs. 3a–c).

Second, perform an intra-oral examination. Evaluate the symmetry of gingival level and dental caries. Then evaluate the biotype with articulating paper (Fig. 4). A thin biotype may decrease long-term stability because it tends to be less resistant to trauma during restoration procedures (such as retraction-cord insertion) and has a higher prevalence of gingival recession after cementation. Tooth proportion is evaluated with Chu's Aesthetic Gauge (Hu-Friedy; Fig. 5).

Third, evaluate tooth shade with the Rite-Lite (AdDent). It is a shade-matching light that supplies a constant colour temperature of 5,500 K (Fig. 6).

Fourth, evaluate the dental radiographs. Check for the apex lesion and root proximity.

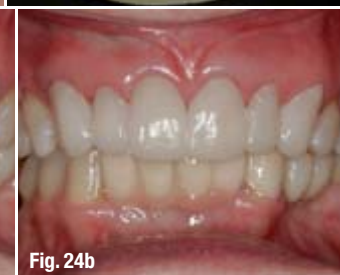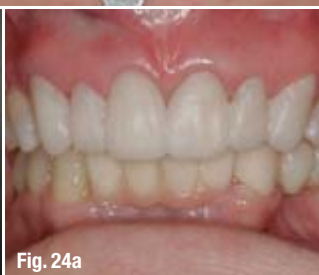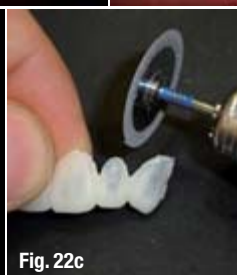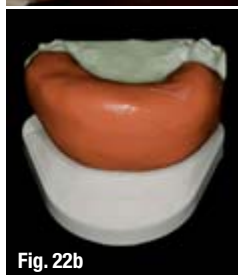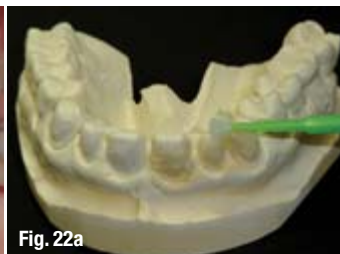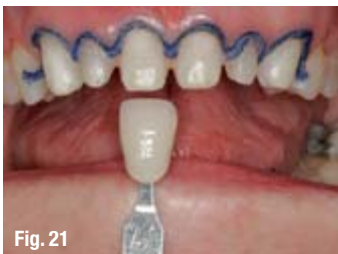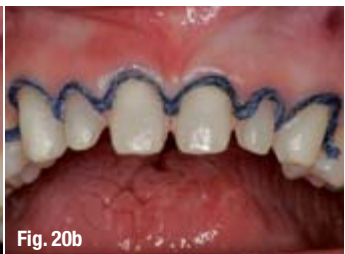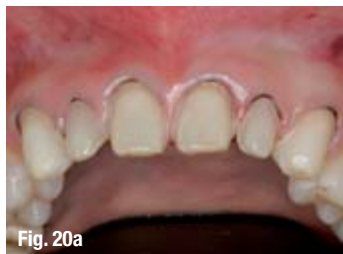Fifth, evaluate and transfer the midline, interpupillary line, and Camper's lines as illustrated in Figures 7a to c.

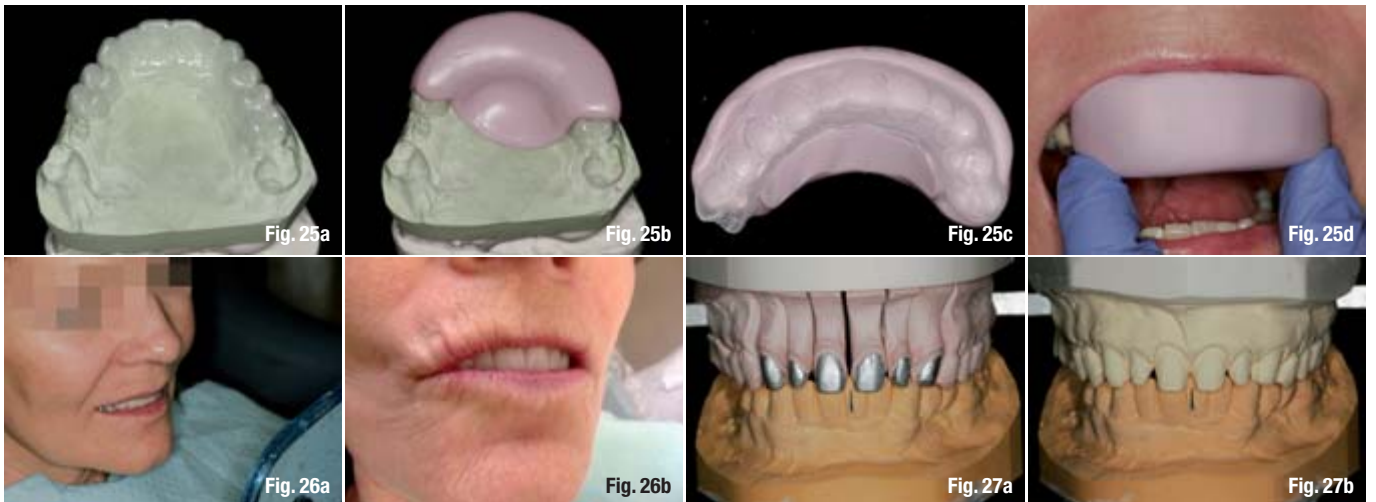
Sixth, perform the mounted cast evaluation on an articulator. Assess horizontal and vertical overlap (overjet and overbite) between maxillary and mandibular incisors. In order to preserve anterior guidance (maxillary anterior lingual surfaces), a custom incisal table needs to be made with auto-cure resin (Fig. 8).

Seventh, make a diagnostic wax-up on the mounted cast. Do not forget to duplicate the wax-up (Figs. 9a & b).

Preparation design

This section discusses veneer preparation design. I recommend incisal wrapping with either a butt margin or a mini-chamfer finish line. This finish line will assist dental ceramists in making a determination with respect to form and shape, and will assist clinicians in making a positive seating during cementation. However, you should avoid placing the finish line on the concave lingual fossa to prevent high tensile stress of the porcelain. In addition, avoid placing the finish line on the occlusal contact points. Opening interproximal contacts is recommended. Closed proximal contacts will interfere with improvement of the shape and translucency, since it is very difficult to separate the dies.





First, before a veneer preparation is initiated, make a thermoplastic matrix for a resin mock-up and a silicone matrix on the duplicated wax-up cast (Fig. 10). You can cut this silicone matrix into two depth-reduction guides: one for incisal reduction and the other for labial reduction (which is notebook-shaped with incisal third, middle third, and cervical third layers). Alternately, you can also use a thermoplastic matrix for the depth reduction (Fig. 11).

Second, have the patient return to make a resin mock-up on the patient's teeth. This is a great communication tool with the patient and will enhance the patient's acceptance of the proposed treatment plan. Before making the resin mock-up, with the silicone labial-reduction guide from the previous step (Fig. 10c), mark with a pencil any over-contoured area (Fig. 12a) and then reduce that area in order to achieve a better adaptation of the silicone matrix or the thermoplastic sheet (Fig. 12b). After that, you can make the mock-up resin with a flowable composite resin, carried in the thermoplastic sheet with no dental bonding agent (Fig. 13). Once the patient agrees to the proposed treatment plan for PLVs, use this resin mock-up during the following tooth-preparation steps. You should verify the mock-up resin with a ruler (Fig. 14).

Third, over the mock-up resin, complete the incisal reduction with a #330 bur to achieve an

even 2 mm reduction and verify the reduction with a silicone incisal-reduction guide (Figs. 15a & b). Then, make the labial reduction with 3 mm (834.314.016, Komet Dental) and 5 mm (834.314.021, Komet Dental) depth cutter burs in the cervical and middle areas, respectively (see Fig. 16a). Verify your veneer preparation with a notebook-shaped labial silicone matrix (0.3 mm to ~0.7 mm; Fig. 16b). It is important to achieve even amounts of preparation with depth cutting burs over the resin mock-up and to avoid over-reduction of the tooth structure, thus preserving the enamel for predictable cementation.

Fourth, do the interproximal reduction. Use a metal matrix to avoid damaging adjacent teeth. Polish the interproximal areas with polishing strips to create smooth and even surfaces (Figs. 17a & b).

Fifth, create the cervical finish line. I prefer a slight sub-gingival position when I intend to change the shade of the tooth. A chamfer cervical finish line is created along the free gingival margin without placing a retraction cord. Then, with a thin retraction cord (Ultrapak Cord #00, Ultradent Products) placed in the sulcus, make another equi-gingival chamfer finish line following the displaced free gingival level (Fig. 18). When the retraction cord is removed later, you will see a 0.5 mm sub-gingival margin placement. However, do not remove the

