

Journal of

# Oral Science & Rehabilitation

Journal for periodontology, implant dentistry,  
dental prosthodontics and maxillofacial surgery

ISSN 2365-6123 (Print)

ISSN 2365-6891 (Online)

Volume 3 — Issue 1/2017

**dti** Dental  
Tribune  
International



# Essential Dental Media

Dental Tribune International

# The World's Largest News and Educational Network in Dentistry

[www.dental-tribune.com](http://www.dental-tribune.com)

**dti** Dental  
Tribune  
International

Journal of

# Oral Science & Rehabilitation

On research and education

Reference

**García-Gallego A,  
Georgantzis N,  
Martín-Montaner J,  
Pérez-Amaral T**

(How) do research and administrative duties affect university professors' teaching?  
Appl Econ.  
2015 May 5;47(45):4868–83.

It is well proven that research and education constitute a positive feedback system. A recent study among 609 university professors concluded that educators who carry out frequent research activities perform significantly better at their teaching activities.<sup>1</sup> This is equally true when seen from the student perspective. Research is itself a very powerful educational tool. Being involved in research activities takes students to a level of critical thinking and in-depth study that can rarely be achieved with other educational methods. Even more importantly, science itself would certainly benefit from the involvement of students in research, as they will always bring with them fresh and challenging ideas and enthusiasm.

For all these reasons, educational plans and educators should ensure that undergraduate and postgraduate students have the opportunity to participate in research activities as early as possible.

**Dr. David Peñarrocha Oltra**  
Associate Editor



**03**

**Editorial**

Dr. David Peñarrocha Oltra

**06**

**About the *Journal of Oral Science & Rehabilitation***

**08**

**Marco Tallarico et al.**

Comprehensive rehabilitation and natural esthetics with implant and orthodontics (CRANIO): An interdisciplinary approach to missing maxillary lateral incisors

**18**

**Alberto Monje and Hom-Lay Wang**

Biological and physical properties of bone block grafting biomaterials for alveolar ridge augmentation

**32**

**Jörg-Ulf Wiegner et al.**

Retrospective analysis of periimplantitis therapy of 158 implants

**44**

**Masataka Hirose et al.**

Bone augmentation of canine frontal sinuses using a porous  $\alpha$ -tricalcium phosphate for implant treatment

**52**

**Natalia Ribes Lainez et al.**

Importance of a preoperative radiographic scale for evaluating surgical difficulty of impacted mandibular third molar extraction

**60**

**Andrea Papini et al.**

Kinesiographic analysis of lateral excursive movement on the horizontal plane: the retrusive component

**68**

**Marco Tallarico and Silvio Meloni**

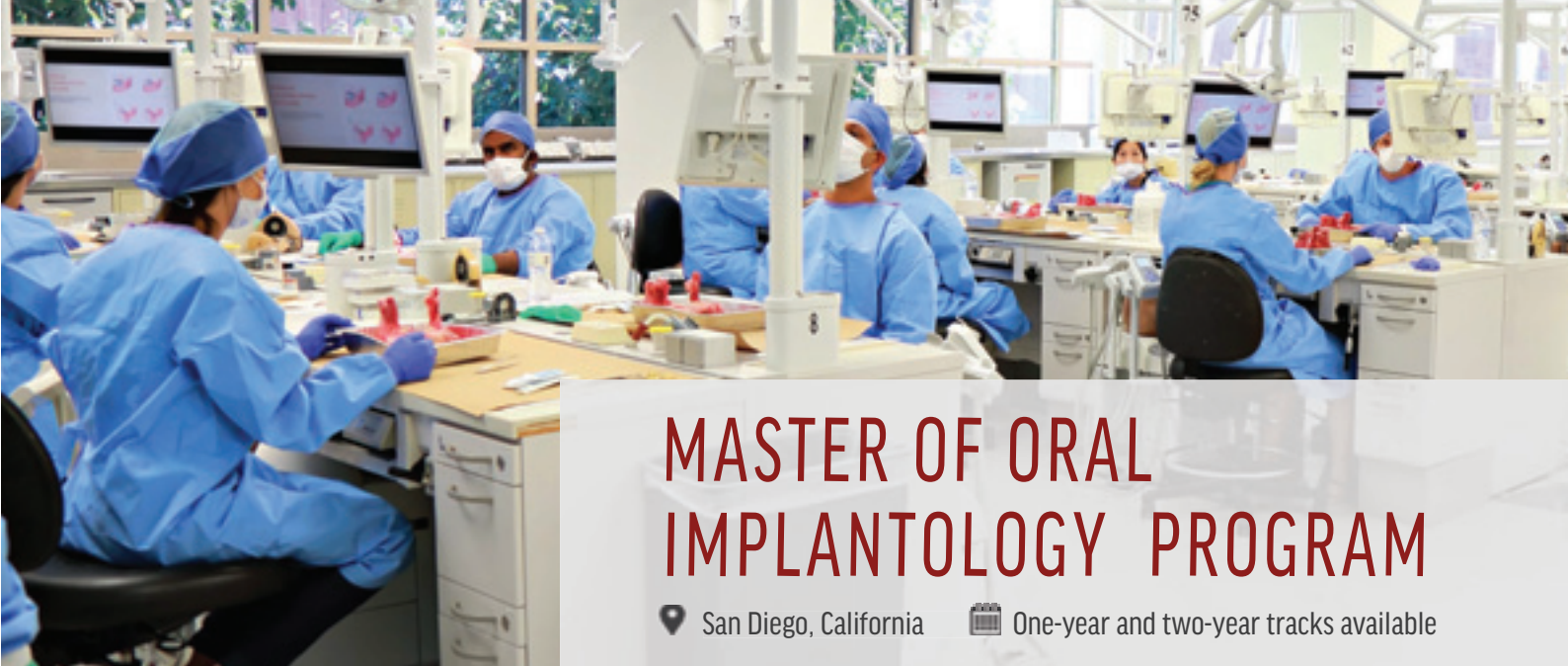Open cohort prospective study on early implant failure and physiological marginal remodeling expected using sandblasted and acid-etched bone level implants featuring an 11° morse taper connection within one year after loading

**80**

**Guidelines for authors**

**82**

**Imprint — about the publisher**



# MASTER OF ORAL IMPLANTOLOGY PROGRAM

📍 San Diego, California

📅 One-year and two-year tracks available

## ADVANCED SURGICAL & PROSTHETIC IMPLANT TRAINING PROGRAM



The advanced surgical & prosthetic *Master of Oral Implantology Program* is designed for general dentists of all implant experience levels, as well as specialists in the fields of prosthodontics, periodontics and endodontics. The goal of the program is to provide doctors with the right tools for a successful career in implant dentistry.

The California Implant Institute and its world-renowned faculty have developed the most comprehensive curriculum focusing on essential information that is immediately useful to doctors, their staff, and their patients. Through in-class interactive lectures, online webinars, hands-on laboratory sessions, live-patient surgical experiences, and much more, participants will gain the highest level of knowledge and technical skills necessary to provide safe, appropriate, and efficient treatments.

Understanding the value of the time invested to complete the Master of Oral Implantology Program, CII offers a unique opportunity for doctors to fully customize their program track to best fit their availability while having the least impact on their practice.

Visit the CII website for detailed curriculum and schedules.

## Faculty Members



**Louie Al-Faraje, DDS**

Diplomate, American Board of Oral Implantology  
Academic Chairman, California Implant Institute



**Mamaly Reshad, DDS, MSc**

Former Section Chair for Fixed Prosthodontics and  
Operative Dentistry, University of Southern California



**Christopher A. Church, MD**

Diplomate, American Board of Otolaryngology  
Director, Loma Linda University Sinus and Allergy



**James L. Rutkowski, DMD, PhD**

Diplomate, American Board of Oral Implantology  
Past President, American Board of Oral Implantology



**Patrick Palacci, DDS**

Head of Brånemark Osseointegration Center  
in Marseille, France



**Domenico Cascione, CDT, B.S.**

President of OPERART LLC, a dental laboratory  
in Santa Monica, California

## Training Overview

The Program consists of 7 modules for a total of 1,000 CE units:

- **Didactic / In-Class Lecture Module**  
Over 60 days of interactive academic learning
- **Live-Patient Surgical Module**  
Perform 30+ surgical implant placements and 20+ bone grafting procedures
- **CAD/CAM Computer Guided Module**  
Hands-on workshop focused on implant surgery
- **Implant Prosthodontics Module**  
Hands-on implant-oriented occlusion workshop and on-site shadowing of a Prosthodontist
- **Hands-On Cadaver Module**
- **Oral Sedation Certification Module**
- **Academic and Research Module**



[www.implanteducation.net](http://www.implanteducation.net)

[info@implanteducation.net](mailto:info@implanteducation.net)

+1 858.496.0574

## About the *Journal of Oral Science & Rehabilitation*

The aim of the *Journal of Oral Science & Rehabilitation* is to promote rapid communication of scientific information between academia, industry and dental practitioners, thereby influencing the decision-making in clinical practice on an international level.

The *Journal of Oral Science & Rehabilitation* publishes original and high-quality research and clinical papers in the fields of periodontology, implant dentistry, prosthodontics and maxillofacial surgery. Priority is given to papers focusing on clinical techniques and with a direct impact on clinical decision-making and outcomes in the above-mentioned fields. Furthermore, book reviews, summaries and abstracts of scientific meetings are published in the journal.


Papers submitted to the *Journal of Oral Science & Rehabilitation* are subject to rigorous double-blind peer review. Papers are initially screened for relevance to the scope of the journal, as well as for scientific content and quality. Once accepted, the manuscript is sent to the relevant associate editors and reviewers of the journal for peer review. It is then returned to the author for revision and thereafter submitted for copy editing. The decision of the editor-in-chief is made after the review process and is considered final.

## About Dental Tribune Science

Dental Tribune Science (DT Science) is an online open-access publishing platform ([www.dtscience.com](http://www.dtscience.com)) on which the *Journal of Oral Science & Rehabilitation* is hosted and published.

DT Science is a project of the Dental Tribune International Publishing Group (DTI). DTI is composed of the leading dental trade publishers around the world. For more, visit

[www.dental-tribune.com](http://www.dental-tribune.com)



## **Benefits of publishing in the journal for authors**

There are numerous advantages of publishing in the *Journal of Oral Science & Rehabilitation*:

- Accepted papers are published in print and as e-papers on [www.dtscience.com](http://www.dtscience.com).
- Authors' work is granted exposure to a wide readership, ensuring increased impact of their research through open-access publishing on [www.dtscience.com](http://www.dtscience.com).
- Authors have the opportunity to present and promote their research by way of interviews and articles published on both [www.dtscience.com](http://www.dtscience.com) and [www.dental-tribune.com](http://www.dental-tribune.com).
- Authors can also post videos relating to their research, present a webinar and blog on [www.dtscience.com](http://www.dtscience.com).

## **Subscription price**

€50.00 per issue, including VAT and shipping costs.

## **Information for subscribers**

The journal is published quarterly. Each issue is published as both a print version and an e-paper on [www.dtscience.com](http://www.dtscience.com).

## **Terms of delivery**

The subscription price includes delivery of print journals to the recipient's address. The terms of delivery are delivered at place (DAP); the recipient is responsible for any import duty or taxes.

Copyright © 2016 Dental Tribune International GmbH. Published by Dental Tribune International GmbH. All rights reserved. No part of this publication may be reproduced, stored or transmitted in any form or by any means without prior permission in writing from the copyright holder.

# Comprehensive rehabilitation and natural esthetics with implant and orthodontics (CRANIO): An interdisciplinary approach to missing maxillary lateral incisors

Marco Tallarico,<sup>a</sup> Cesare Luzi,<sup>b</sup> Giorgia Galasso,<sup>c</sup>  
Roberta Lione<sup>d</sup> & Paola Cozza<sup>d</sup>

<sup>a</sup> Private practice, Rome, Italy; Surgical, Micro-Surgical and Medical Science Department, University of Sassari, Sassari, Italy; and Osstem AIC, Italy

<sup>b</sup> Private practice, Rome, Italy; and Department of Orthodontics, University of Ferrara, Ferrara, Italy

<sup>c</sup> Orthodontics Postgraduate Training Program, Department of Pediatric Surgery, Bambino Gesù children's hospital, Rome, Italy

<sup>d</sup> Department of Clinical Sciences and Translational Medicine, University of Rome "Tor Vergata," Rome, Italy; and Department of Dentistry, "Nostra Signora del Buon Consiglio" University, Tirana, Albania

## Corresponding author:

### Dr. Marco Tallarico

Via di Val Tellina 116  
00151 Rome  
Italy

T +39 328 075 8769  
me@studiomarcotallarico.it

## How to cite this article:

Tallarico M, Luzi C, Galasso G, Lione R, Cozza P. Comprehensive rehabilitation and natural esthetics with implant and orthodontics (CRANIO): an interdisciplinary approach to missing maxillary lateral incisors. J Oral Science Rehabilitation. 2017 Mar;3(1):8–16.

## Abstract

### Background

The absence of the maxillary lateral incisors creates a functional and esthetic problem that can be managed with different treatment modalities.

### Case presentation

The present case is reported to illustrate an interdisciplinary approach involving orthodontics and restorative dentistry to manage the case of a 24-year-old Caucasian female with agenesis of the maxillary right lateral incisor, presence of the maxillary right canine in place of the lateral incisor, microdontia of the maxillary left lateral incisor, and midline deviation. Treatment included space opening and positioning of a 3 mm implant supporting a single-unit crown, placed using computer-assisted, template-guided surgery.

### Conclusion

Comprehensive interdisciplinary rehabilitation according to the CRANIO philosophy was effective in successfully restoring function and esthetics in a young female patient affected by congenitally missing maxillary lateral incisor.

### Keywords

Interdisciplinary treatment, agenesis, dental esthetics, dental implants, guided surgery.



## Introduction

Congenital tooth agenesis is a common dental anomaly, with reported incidences of 2.7% to 12.2%, excluding third molars. In the permanent dentition, maxillary lateral incisors are the most commonly affected,<sup>1</sup> with a prevalence rate of between 1% and 4%<sup>2</sup> and a female predominance of approximately 2:1 compared with males.<sup>3</sup> This anomaly is not usually an isolated phenomenon, but is associated with other dental anomalies, such as peg-shaped contralateral incisors.<sup>1</sup> Therefore, the concurrence of several dental anomalies in the same subject results in functional and esthetic problems, which may in turn affect the patient's self-confidence and social relationships from a very young age.

Treatment options for missing lateral incisors include space opening, followed by the placement of a conventional fixed bridge or a single-unit implant-supported crown, and orthodontic space closure with anatomical recontouring of the canines.<sup>4</sup> Selecting the most appropriate therapy is still a challenge. Numerous clinical characteristics must be analyzed, such as the patient's age, occlusal relationships, profile, smile line, presence or absence of third molars, and size, shape and color of the canines.<sup>5</sup>

In order to maximize the esthetic and functional results, an interdisciplinary approach involving an orthodontist, an oral surgeon and a restorative dentist has become essential. Comprehensive rehabilitation and natural esthetics with implant and orthodontics (CRANIO) is a philosophy based on interdisciplinary treatments to achieve stable occlusion and healthy hard and soft tissue and to enhance the natural esthetic appearance and subsequent patient satisfaction.

The aim of the present study was to describe an interdisciplinary approach to a clinical case presenting with a missing maxillary lateral incisor treated in two phases: orthodontic space opening, followed by placement of a narrow 3 mm diameter implant and restored with a screw-retained lithium disilicate crown veneered on a zirconia abutment.

## Case report

A 24-year-old Caucasian female was referred to our private clinic to seek a second opinion for treatment, with the chief complaint of an unattractive smile and the mobility of the primary

maxillary right canine. Clinical examination and radiographs confirmed the advanced root resorption of the primary maxillary right canine, the agenesis of the permanent maxillary right lateral incisor, with the presence of the permanent canine in place of the lateral incisor, and microdontia of the maxillary left lateral incisor (**Figs. 1a–c**). Intraoral observation revealed an Angle Class II relationship of the molars and canine, an increased overjet, a normal overbite and a lower dental midline that was displaced 3 mm to the left compared with the upper midline.

Cephalometric analysis (Dolphin Imaging 11.7, Dolphin Imaging and Management Solutions, Chatsworth, Calif., U.S.) highlighted a mesofacial facial pattern, with a Class II sagittal skeletal relationship (**Fig. 2**). The patient presented with a symmetrical and proportional face and flat facial profile, with the upper lip positioned 4 mm and the lower lip 2 mm behind the Ricketts E-line.

The previously proposed treatment was extraction of the primary canine with space maintenance for a future implant rehabilitation and canine substitution with a veneer restoration. In contrast to this, the alternative treatment proposed was extraction of the primary canine, followed by orthodontic space recovery for implant placement in the lateral incisal area, with alignment and leveling of the dental arches. The option of correcting the Class II relationship would have required orthognathic surgery, which was refused by the patient.

The patient was initially very skeptical toward such a comprehensive treatment option. However, after discussion with both the orthodontist (CL) and implantologist (MT) of the advantages and disadvantages of all of the available treatment options, it became clear to the patient that the overall advantages of the proposed interdisciplinary treatment, involving orthodontic treatment, implant placement and prosthetic rehabilitation, would provide improved esthetic and functional results. The disadvantages of the proposed treatment were related to costs and a longer treatment time.

The orthodontic treatment lasted 18 months. After the extraction of the primary canine, full-arch bonding with a fixed esthetic multibracket appliance was performed, and the maxillary right canine was strategically bonded with a mesial tip back to enhance root control. Skeletal anchorage by means of an orthodontic miniscrew (Aarhus System, American Orthodontics, Sheboygan, Wisconsin, U.S.; 1.5 mm diameter,