

cosmetic

dentistry beauty & science

trends & applications

The prosthetic revolution

case report

Minimal invasiveness—
maximal effectiveness

industry report

New materials for a classic indication

Craft the *Perfect* *Smile* **Today!**

Cosmetic Enamel Rejuvé Kit

for Smile Rejuvenation
& all Cosmetic enhancements

DESIGNED FOR:

- Creating new smiles,
- Revival of aged smiles,
- Brightening dull smiles,
- Correcting less than perfect smiles,
- Enhancing existing smiles



For more information, simply contact your nearest
Shofu Dealer Today!



SHOFU DENTAL ASIA-PACIFIC PTE. LTD.
www.shofu.com.sg

Official Partner



Minimally Invasive
Cosmetic Dentistry

Dr Florin Lăzărescu

Guest Editor



Dear readers,

The concept of aesthetic and cosmetic dentistry has evolved during last several years, involving other new concepts and trends in dentistry. At aesthetic dentistry congresses all over the world, the topics are involving concepts of minimally invasive dentistry and focusing on the differences between analogue and digital workflows. Implant placement in the aesthetic zone and soft-tissue manipulation for achieving aesthetic results are mandatory subjects among the invited speakers. A broad range of topics are taken into consideration when the scientific committee decides on the invited speakers and topics.

The same situation applies to publications in aesthetic and cosmetic dentistry. In this issue of **cosmetic dentistry**, the authors have approached the same concepts: minimal invasiveness in a case report of total rehabilitation in centric relation combining indirect and direct restorative solutions; looking at digital versus analogue in a case report on ceramic veneers in the anterior region; minimally invasive prosthetic procedures and digital solutions for treatment planning.

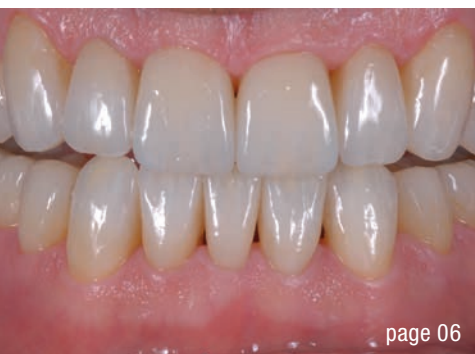I am very pleased that this issue of **cosmetic dentistry** will be distributed at the 15th annual meeting of the European Society of Cosmetic Dentistry (ESCD), which is being held in Lisbon in Portugal on 20 to 22 September. It is gratifying that many of the authors in this **cosmetic dentistry** issue are founding or active members of the ESCD, or invited speakers to the congress.

This anniversary edition of the ESCD meeting will really be an outstanding one according to the complexity of organisation and number of participants (more than 600). There will be two main podiums and two parallel hands-on sessions over the three days. For the first time at the event, there will be a live TV studio, from where interviews with speakers, participants, members of the industry and organisers will be broadcast live on ESCD's Facebook page. For those unable to come to Lisbon, we offer the possibility of viewing the scientific sessions online.

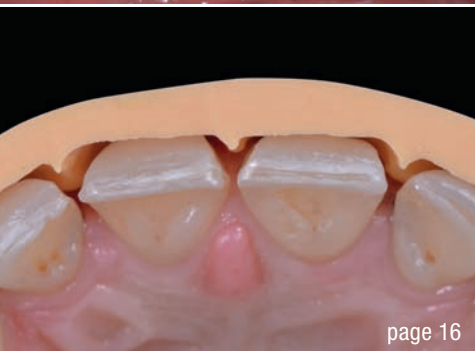Self-registration will make the registration process a smooth one and the social programme throughout the event (ESCD & Friends, president's dinner, Portuguese night) will foster further cohesion among the members of our society.

I wish you all an instructive read and that you will be inspired by the topics addressed and be able to implement the methods in your day-to-day practice. I also wish you three days of science and pleasure in Lisbon, together with the ESCD and the Dental Tribune International family.

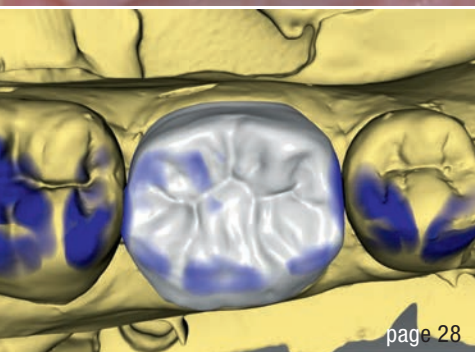
Dr Florin Lăzărescu
Guest Editor



page 06



page 16



page 28

Cover image courtesy of
kiuikson/Shutterstock.com



editorial

Dear readers 03
Dr Florin Lăzărescu

trends & applications

The prosthetic revolution 06
Dr Mauro Fradeani

**Aesthetic Digital Smile Design:
2-D-/3-D-assisted communication and software design** 10
Dr Antonello Demartis, Luca Borro & Dr Valerio Bini

case report

Digital vs. analogue workflow on ten ceramic veneers in the maxilla 16
Dr Michalis Diomataris, Dr Stavros Pelekanos & Michalis Papastamos

Minimal invasiveness—maximal effectiveness 20
Dr Maciej Żarow

industry report

TouchWhite Teeth Bleaching 24
Dr Nguyen Linhlan

Age-appropriate aesthetics 26
Carolin Wehning

New materials for a classic indication 28
Drs Eduardo Mahn & Juan Pablo Sánchez

new materials

Bioactivity in restorative dentistry: A user's guide 32
Dr Fay Goldstep

meetings

Sometimes faster, sometimes safer, sometimes both—
The digital practice at IDS 2019 38

International events 40

about the publisher

submission guidelines 41

international imprint 42

The medical power of light

TouchWhite[®] Laser Assisted Tooth Whitening

Faster, safer and more patient friendly treatment

- Utilizing the unique laser tissue interaction of the Er:YAG laser wavelength and Fotona's VSP pulse mode
- Up to 10 times shorter treatment times
- Safer - no unnecessary thermal burden on the tooth or pulp
- More comfortable for patients while achieving the same or better whitening efficacy
- Any bleaching gel color can be used
- Perfect, natural looking results after one single treatment

Available only with

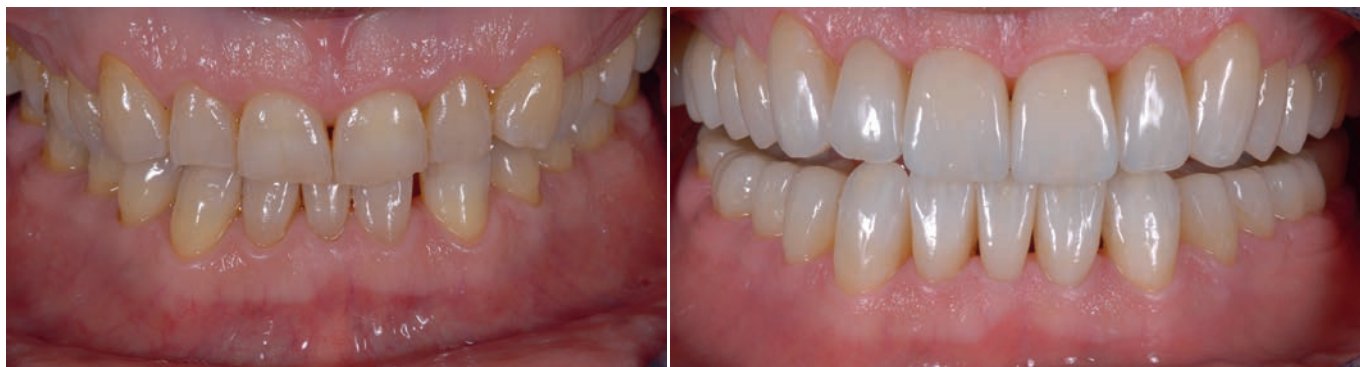

LightWalker[®]

The prosthetic revolution

Minimally invasive prosthetic procedures and new digital tools for the treatment plan

Dr Mauro Fradeani, Italy



Minimally invasive prosthetic procedures

Nowadays, the demand for prosthetic treatments owing to imperfect teeth is steadily rising. The importance given to aesthetics in our society is growing, especially among young people, and clinicians ought to be increasingly conservative in their treatments and take precautionary measures.

This type of approach allows the dentist to maintain most of the remaining dental structure while re-establishing a proper relationship between function, aesthetics, and duration of the prosthetic restoration. Minimising the removal of enamel while aiming to satisfy the aesthetic expectations of the patient represents a risk for the clinician, especially when the remaining tooth structure is already partly worn. When treating a case extending to both arches with a severely worn dentition, the goal of the clinician should be to obtain micromechanical retention and mechanical strength though paradoxically limiting the amount of tooth preparation.

By preserving the maximum amount of enamel, the clinician will be able to reduce occlusal ceramic thickness without compromising the resistance and aesthetic result of the restoration. The use of a minimally invasive prosthetic procedure (MIPP) will help the dentist to reduce the biological cost of enamel removal. The key steps of this technique are the following:

1. Increase the vertical dimension of occlusion (VDO);
2. reduce the thickness of the monolithic ceramic material;

3. preserve the enamel during tooth preparation;
4. adhesively bond the restorations.

1. Increase of the vertical dimension of occlusion

In prosthetic restorations extended to at least one full arch, an increase in the VDO of the patient is important in order to achieve a successful aesthetic and functional and restorative result. This procedure will help the clinician to reduce the amount of dental tissue removed in conventional preparation. By increasing the VDO, the clinician will be able to avoid invasive dental and occlusal preparation and thus be able to bond the ceramic restoration to the remaining enamel. A permanent increase in the VDO is a safe and predictable procedure if done up to 5 mm (considering the absence of disease affecting the temporomandibular joint and the presence of correct disc alignment); in any case, any discomfort related to the patient's new VDO ratio will last no longer than one to two weeks.

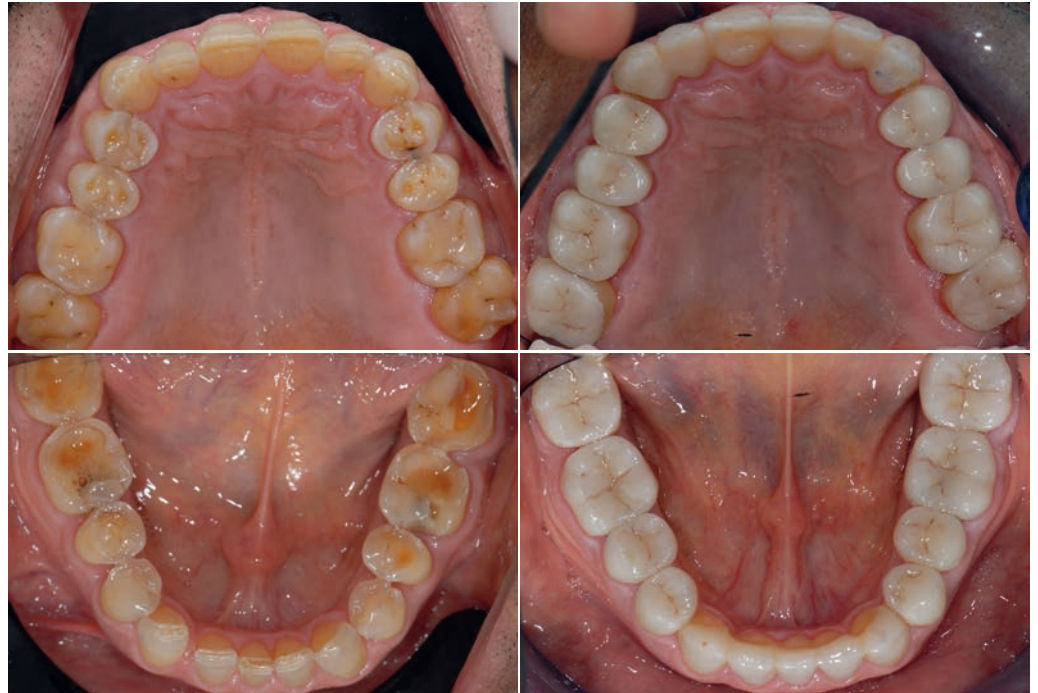
When determining a modification in the VDO vertical dimension, the clinician may consider the use of the following techniques:

- Evaluation of the required space for restorative material;
- interocclusal rest space;
- evaluation of the facial proportions;
- phonetics (“m” and “s” sounds); and
- acrylic preoperative mock-up.

Among these techniques, the one most effective in order to gain acceptance of the new VDO by the patient is the evaluation of speech, particularly with regard to sibilants or “s” sounds.

2. Reduction of the thickness of the monolithic ceramic material

The reduction in the thickness of the ceramic material used in the restoration is a great advantage of the MIPP technique. It has been proven that minimally invasive lithium disilicate occlusal restorations, if supported by enamel, have a high load-bearing capacity and therefore a high resistance to fracture. The key to the success of the restoration is its adhesive bonding, which must always be on enamel and involve an etchable ceramic material.



3. Preservation of enamel during tooth preparation

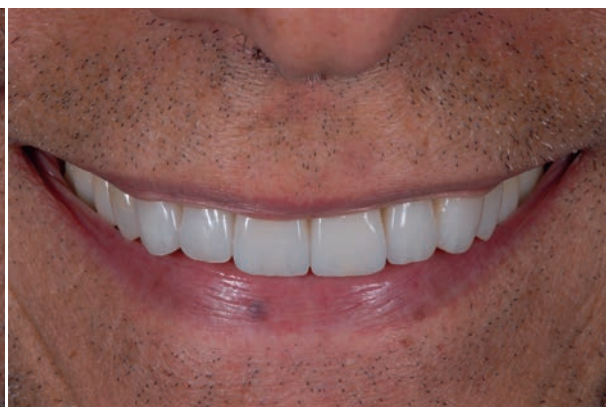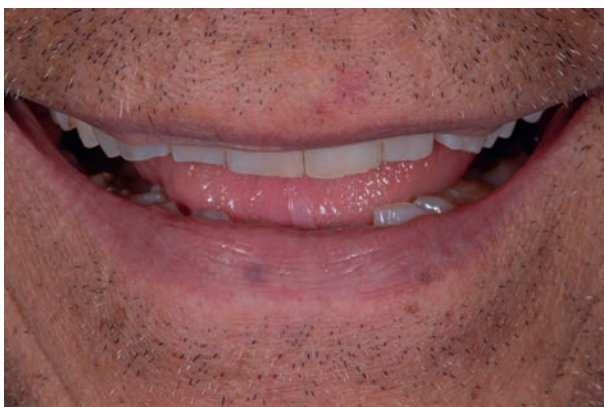The preservation of enamel during tooth preparation is highly important in order to implement the MIPP technique. The recommended conventional thickness in the occlusal area for porcelain restorations is 1.5 to 2 mm; however, these values can be reduced by using an etchable monolithic ceramic material with a decreased thickness bonded to enamel.

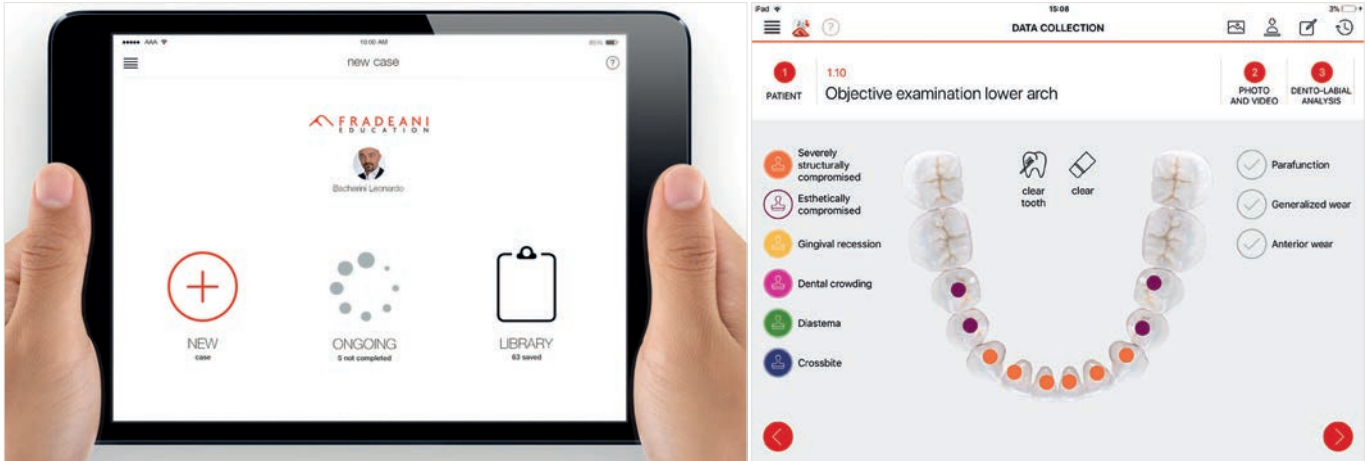
4. Adhesive bonding of the restorations

Adhesion to enamel can influence the design of the tooth preparation, allowing the clinician to maintain the maximum amount of dental structure and thereby achieve excellent treatment results, including lower post-cementation sensitivity, improved support of the ceramic restoration and avoidance of endodontic intervention. Moreover, a correctly performed adhesive procedure can eliminate the need for extensive tooth preparation, as well as the use of anaesthesia. Success will depend on the ability to establish good adhesion between the tooth structure and the porcelain with correct performance of the etching procedure and appropriate use of adhesive materials.

The MIPP technique is characterised into six different classifications, which can be divided into two main approaches:

1. Confirmatory approach when the patient's occlusion is left in maximum intercuspation:
 - MIPP 0: additional restorations (anterior, posterior) with no preparation, mainly on enamel
 - MIPP 1: partial restorations (anterior veneers, posterior restorations) with minimal tooth preparation, mainly on enamel
2. Reorganisation approach in the case of a modification of the VDO and centric relation (CR):
 - MIPP 2A: partial restorations (veneers, posterior restorations) with minimal tooth preparation, mainly on enamel in CR
 - MIPP 2B: full-coverage veneers (patient with open bite in CR) with minimal tooth preparation, mainly on enamel



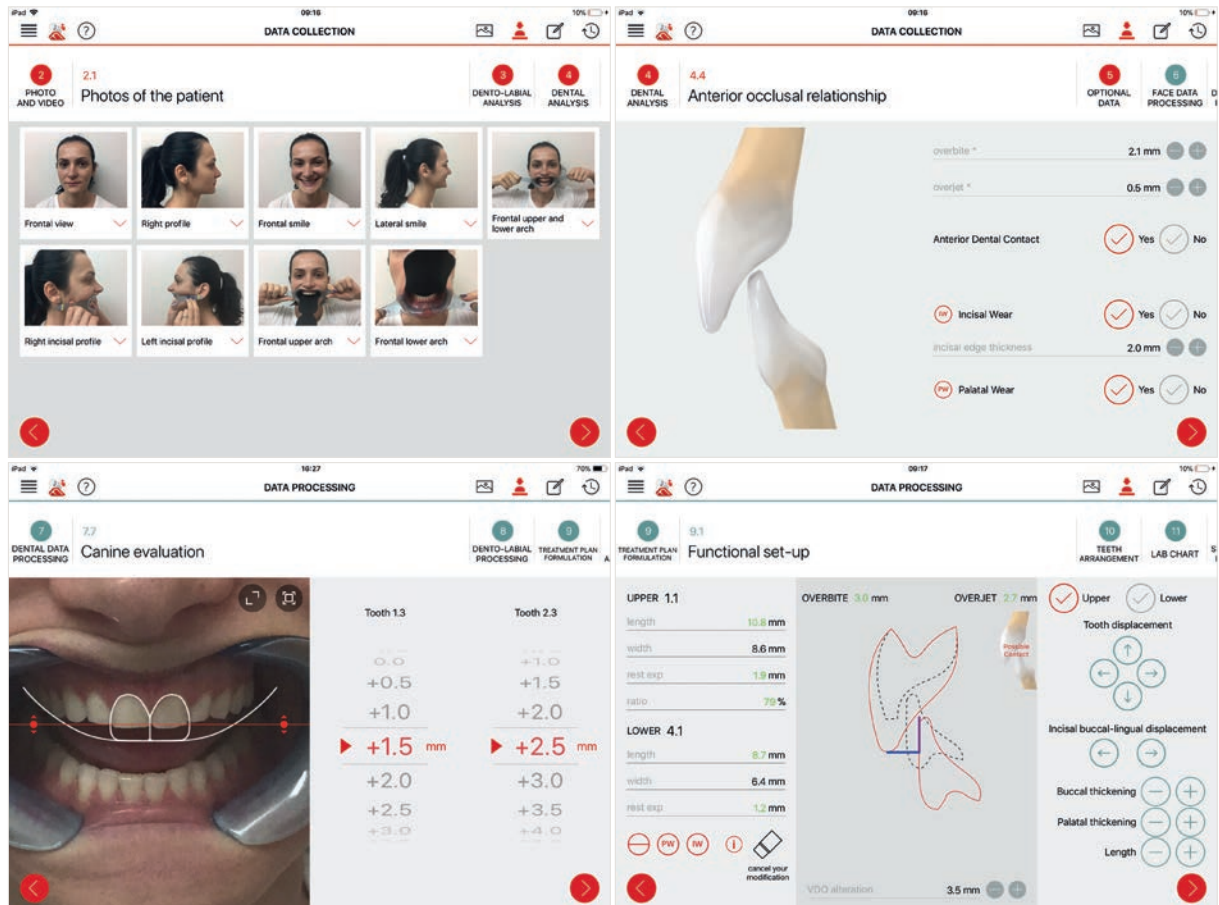


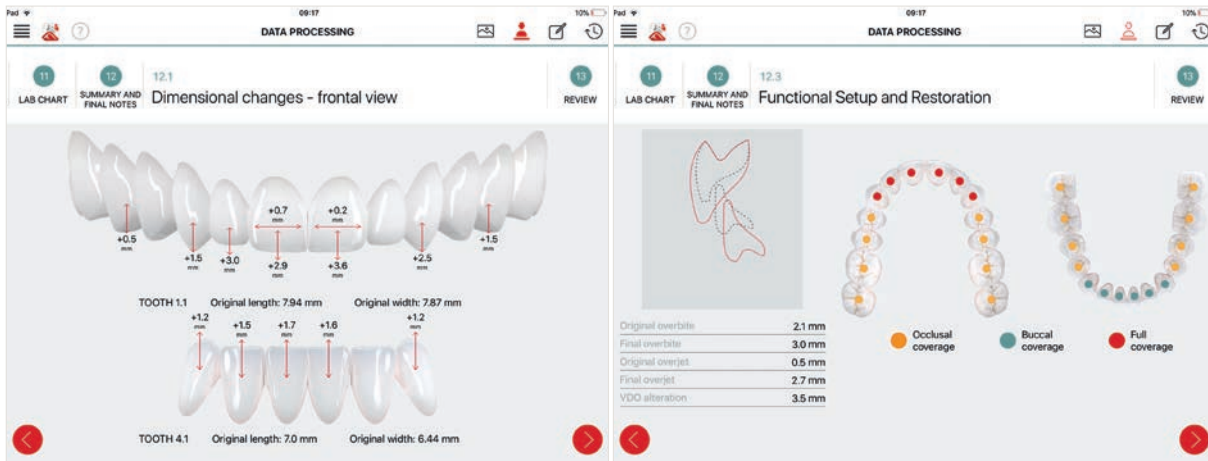
- MIPP 3A: one arch in CR with VDO alteration and tooth structure preservation, mainly on enamel
- MIPP 3B: two arches in CR with VDO alteration and tooth structure preservation, mainly on enamel

The use of the MIPP technique in prosthetic restorations aids the clinician in achieving excellent functional and aesthetic results, avoiding invasiveness in the reduction of the tooth structure and thus allowing a more physiological occlusion and a better distribution of occlusal forces.

New digital tools for the treatment plan: Guided Esthetic Treatment App

The need of clinicians all over the world for a tool that supports them in formulation of the correct treatment plan, combined with new technologies that simplify and accelerate many prosthetic procedures, led us to develop a multimedia application that assists the dentist in all of the phases of data collection and analysis. This app is designed to interact with other available technological tools (such as new-generation 3-D face scanners), thus





facilitating an entirely digital workflow for prosthetic rehabilitation.

The GETApp (Guided Esthetic Treatment App) was developed according to the systematic approach to data collection created by Dr Mauro Fradeani. The app automatically analyses all of the values and information on the patient collected by the clinician to determine the best possible treatment to be chosen. The user can modify the suggested treatment plan at any time, by adapting the selected parameters according to his or her specific needs.

The tool guides the dentist step by step through the complete decision-making process, aiding him or her in achieving optimal aesthetic and functional results. The two main phases of data collection and processing offer detailed clinical explanations, which contribute to making GETApp a modern educational system for both simple and complex prosthetic rehabilitation.

By the clinician following all of the suggested steps and entering all of the requested values and parameters, the app automatically generates a PDF file containing all of the information provided by the clinician. This allows him or her to easily share with the dental laboratory every detail for the fabrication of the ideal prosthetic work.

In conclusion, the benefits and possibilities provided by the GETApp to the clinician are as follows:

- Collection of data for patient anamnesis (the GETApp system can replace the medical records);
- collection of all of the clinical data necessary for good communication with the dental team (radiographs, periodontal chart, health of each tooth, tooth colour, previous dental treatments to be redone, stomatognathic dysfunction);
- guided and predictable method for dental photography and case documentation;
- collection of all aesthetic and functional values necessary for formulation of the treatment plan;

- complete and automatised support in formulation of the treatment plan;
- effective communication with the dental laboratory; and
- effective communication with the patient.

Innovative operative protocols such as the MIPP, combined with the use of modern digital systems such as the GETApp, represent a revolution in the approach to prosthetic treatment. These new procedures will undoubtedly help the clinician to confidently perform comprehensive treatments involving dentures, crowns and veneers on natural dentition and implants, from simple to complex full-mouth rehabilitation.

about



In 1979, **Dr Fradeani** graduated in medicine and surgery from the University of Ancona (now the Università Politecnica delle Marche), Italy, where he then completed a specialisation in dentistry in 1983. He is a past President of the European Academy of Esthetic Dentistry (2003/2004) and of the Accademia

Italiana di Odontoiatria Protesica (1999/2000), and was a visiting associate professor in prosthetics at Louisiana State University, New Orleans, US, from 1999 to 2008. He is an active member of the American Academy of Esthetic Dentistry and maintains membership of the American Academy of Fixed Prosthodontics. He is the founder and Director of the ACE Institute in Pesaro, Italy. He is also the founder and Director of Fradeani Education, an educational project developed together with a group of expert speakers with the goal of promoting an Italian model of excellence in dentistry throughout the world. He is the author of the two-volume series *Esthetic Rehabilitation in Fixed Prosthodontics*, translated into 11 languages (Quintessence, 2004 and 2008). He runs a private practice in Pesaro limited to prostheses on natural dentition and implants.