

cosmetic

dentistry

— beauty & science

3²⁰¹¹

| **case report**

MiCD: When less is more!

| **clinical technique**

Predictable diastema closure using an innovative, indirect mock-up technique

| **industry report**

The three pillars of aesthetics

dentistry

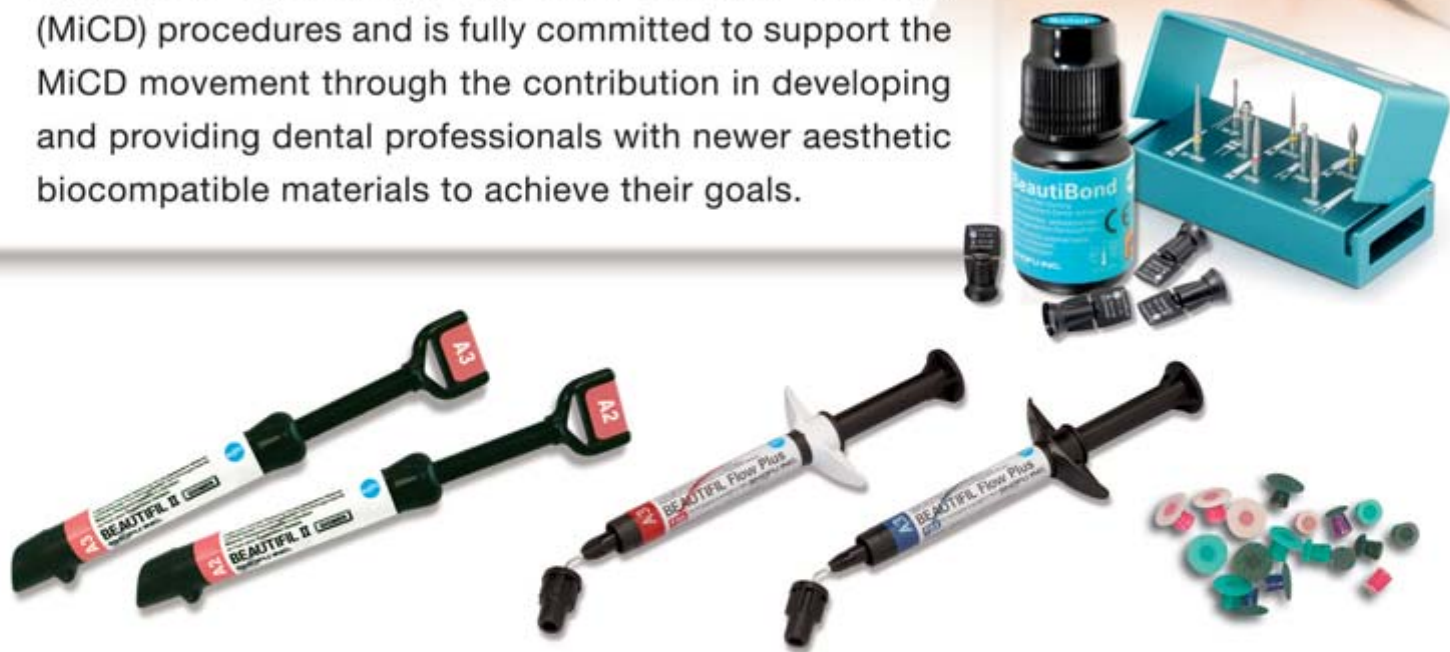

Adopt the trend...



Minimally Invasive
Cosmetic Dentistry

SHOFU recognizes the development of new clinical techniques in minimally invasive cosmetic dentistry (MiCD) procedures and is fully committed to support the MiCD movement through the contribution in developing and providing dental professionals with newer aesthetic biocompatible materials to achieve their goals.



For more information, simply contact your nearest **SHOFU** dealer.



SHOFU INC. SINGAPORE BRANCH

Tel (65) 6377 2722 Fax (65) 6377 1121 eMail mailbx@shofu.com.sg website www.shofu.com.sg

Dear Reader,


_Welcome to this year's third edition of **cosmetic dentistry**! I hope you enjoyed the first and second editions, which are also available online at www.dental-tribune.com free of charge so that we can truly share our expertise and knowledge.

I have been a member of the Asian Academy of Aesthetic Dentistry (AAAD) for many years and recently also became a member of the American Academy of Esthetic Dentistry. Another change in my professional life has been the transition from being a private practitioner in Seoul, Korea, to an appointment as full-time associate professor at the Department of Restorative Dentistry and Center for Dental Research at Loma Linda University's School of Dentistry in California. Therefore, it is with great excitement that I would like to use this opportunity to serve as a bridge for the East and the West to work together in harmony for the progress of cosmetic dentistry. I am confident that our magazine will aid in this goal for collaboration.

Global cosmetic dentistry is on the way! The Japan Academy of Esthetic Dentistry (JAED) with its nearly 3,000 members and the Korean Academy of Esthetic Dentistry (KAED) with its more than 2,000 members have been very strong pillars in supporting the AAAD. The JAED, under the leadership of its President, Dr Toru Sato, established a collaboration with the American Academy of Cosmetic Dentistry (AACD) last year. This year, the KAED, headed by Dr Myung-Jin Kim, followed this example. The AACD is recognised as the largest cosmetic academy worldwide with more than 7,000 members. The collaboration of the academies will lead to a continuous exchange of speakers between the academies and I hope that there will also be more submissions of informative articles to **cosmetic dentistry**.

This colourful edition is concerned particularly with minimally invasive dentistry using composites and with relevant industry reports on adhesive systems and composite resin materials. You will also enjoy information on meetings and international events and much more. I sincerely hope that you will enjoy this edition and successfully apply the information to your clinical practice.

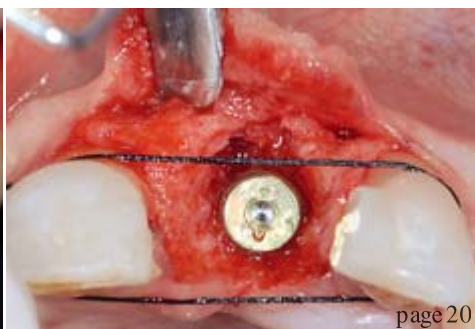
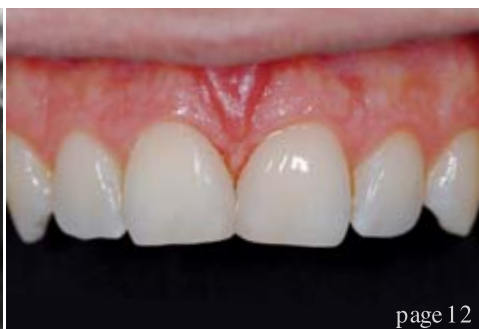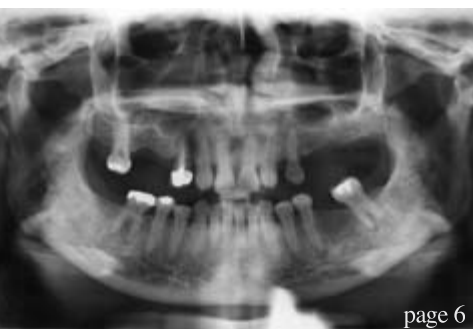Yours faithfully,



Dr So Ran Kwon
Co-Editor-in-Chief
President, Korean Bleaching Society
Seoul, Korea



Dr So Ran Kwon
Co-Editor-in-Chief



| editorial

03 Dear Reader

| Dr So Ran Kwon, Co-Editor-in-Chief

| special

06 Minimally invasive cosmetic dentistry:
When less is more!

| Assoc Prof Adrian U.J. Yap

| clinical technique

12 Predictable diastema closure using an innovative,
indirect mock-up technique

| Prof So Ran Kwon & Prof Gerald E. Denehy

| industry report

16 Basic technical properties of
CLEARFIL SE BOND

| Dr Toshimoto Yamada & Dr Junpei Sugizaki

20 Single-tooth implants in the aesthetic zone—
Challenge and opportunity

| Dr Ata Anil

26 The three pillars of aesthetics

| Dr Julio R. Reyna & Dr Gustavo W. Oshiro

| industry news

30 Amaris—Simply beautiful, beautifully simple

| VOCO

31 CLEARFIL SE BOND

| Kuraray

32 Kohler Matrix forceps with tungsten carbide coating

| Kohler Medizintechnik

| feature

34 German dentist launches programme
to help domestic violence survivors

| Yvonne Bachmann

| meetings

36 Wow, what a meeting!

| Dr Philip Lewis

40 International Events

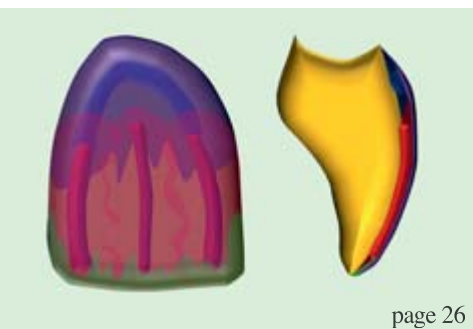
| about the publisher

41 | submission guidelines

42 | imprint



Cover image courtesy of dpaint.



**Precision demands
the right equipment.**



CLEARFIL™ SE BOND

The adhesive that meets your high demands – with a durable marginal sealing thanks to the exceptionally high hydrolysis resistance & with least postoperative sensitivity.

CLEARFIL™ SE BOND is Kuraray's high performance, self-etching adhesive for direct restorations – known for its outstanding long-term marginal sealing thanks to the product's powerful hydrolysis resistance. Furthermore, dentists and patients value the product's least postoperative sensitivity.

CLEARFIL™ SE BOND enables an excellent long-term performance due to the high sealing ability of the bonding agent and the mild-etching, low technique sensitive self-etching primer.

With the in vitro study on the marginal adaptation to enamel and dentin*¹, CLEARFIL™ SE BOND shows its effectiveness by an outstanding, durable marginal adaptation. Moreover, in 2010, CLEARFIL™ SE BOND proves its exceptional strength within an 8 year clinical study*² showing a retention rate of 97%.

Thus, CLEARFIL™ SE BOND is appreciated as the Gold Standard amongst several universities and opinion leaders.

*¹ Source: K. Huber, G. C. Lier, B. Bott, and M. Hanning: Marginal Adaptation of Composite Resin Restorations Using Self-etching Adhesives, Joint Meeting of the Continental European, Israeli, and Scandinavian (NOF) Divisions of the IADR, Abstract #59, August 25-28, 2004.

*² Source: B. Van Meerbeek, M. Peumans, A. Poitevin, A. Mine, A. Van Ende, A. Neves, and J. De Munck: Relationship between bond-strength tests and clinical outcomes, Dental Materials 26, e100–e121, 2010.

Minimally invasive cosmetic dentistry: **When less is more!**

Author _ Assoc Prof Adrian U.J. Yap, Singapore

Minimally invasive dentistry (MiD), also known as minimal intervention dentistry and preservative dentistry, is a practice mindset and philosophy. There is no escape from MiD in clinical practice. All clinicians practice MiD periodically whether consciously or unconsciously. As a practice philosophy, there are principles of being, knowledge and/or conduct.

Although MiD relates to most oral diseases and aspects of dentistry, its application to caries is probably the most evolved. Carious lesions that are demineralised and non-cavitated are now "healed" instead of surgically removed. Tyas *et al.*¹, as part of a FDI Commission-initiated project, provided an overview of the principles and concepts of MiD, suggested techniques and presented the results of clinical studies as they pertain to dental caries. The principles of MiD in relation to caries management are:

- _ remineralisation of early lesions;
- _ reduction in cariogenic bacteria, in order to eliminate the risk of future demineralisation and cavitation;
- _ minimum surgical intervention of cavitated lesions;
- _ repair rather than replacement of defective restorations; and
- _ disease control.

Based on these foundational tenets, generic MiD principles can be proposed for all oral diseases. They are:

- _ early detection and diagnosis of disease (D);
- _ control of contributing (predisposing, precipitating and/or perpetuating) factors (C);
- _ curative and least invasive management of disease or pathological effects (M); and
- _ assessment and monitoring of intervention outcome (O).

These tenets are not only applicable to dental caries, but also to aesthetic problems causing patients "dis-ease". Dental aesthetic problems, like other diseases, can be caused by genetic or developmental anomalies, infection agents (e.g. caries and periodontal disease) and/or environmental factors (malnutrition, diet, stress, trauma, etc.) and include:

- _ discoloured teeth;
- _ poorly shaped teeth;
- _ broken or worn teeth;
- _ ugly fillings (secondary to dental caries);
- _ spaces between teeth;
- _ crooked teeth; and
- _ missing teeth.

Non-invasive options	Minimally invasive options
Smile training	Aesthetic recontouring of teeth/gums
Remineralisation of white spot lesions	Direct restoration with micro-preparation, air abrasion and laser
Take-home and in-office bleaching	Direct or indirect veneers
Direct veneers without tooth preparation	Inlays, onlays and partial veneer crowns
Bonded pontics	Adhesive bridges
Bruxism guards	Dentures
Sectional orthodontics	Mini-implants
Table I	Orthodontics

Table I _ MiCD treatment options for managing various aesthetic problems.

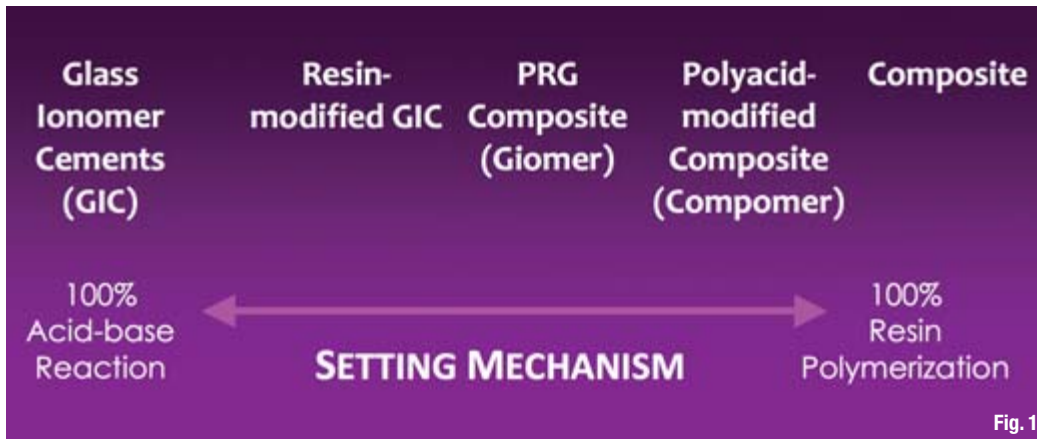

Fig. 1_Continuum of direct restorative materials used in MiCD.

Minimally invasive cosmetic dentistry (MiCD) aims to correct the afore-mentioned aesthetic disease and to fulfil patients' aesthetic desires and demands by using conservative and minimally invasive treatment options. The least amount of dentistry is performed and any tooth structure removal is kept to the absolute minimum required to achieve the desired aesthetics. The benefits of MiCD are highlighted by Koirala² and include reduction of dental fear, increased patient confidence, promotion of trust, enhancement of professional image, tooth preservation and reduction of treatment cost.

Treatment options can be broadly classified as non-invasive or minimally invasive and are listed in Table I. To achieve optimal aesthetic results, more invasive procedures, including conventional implants, periodontal surgery and crown therapy, are sometimes required to complement MiCD treatment options.

MiCD materials

In view of the varied procedures, the entire range of materials used in MiCD is beyond the scope of this article. Emphasis is placed on direct aesthetic restorative materials that conserve the maximum amount of tooth structure because they are utilised in the majority of MiCD procedures performed in clinical practice. The continuum of direct restorative materials used in MiCD, based on their setting chemistry, is shown in Figure 1.

Glass ionomer cements (GICs) consist of basic glasses (calcium or strontium fluoro-aluminosilicate) and acidic co-polymers (polyalkenoic acids) that set through an acid-base reaction. The set cement consists of the original glass particles sheathed by siliceous hydrogel and bonded by a poly-salt matrix. Although their aesthetics is fair, they release fluoride and can chemically bond to tooth tissue. GICs also shrink minimally on setting and have a similar coefficient of thermal expansion to dentine.

Indications for the highly viscous version of these cements include the restoration of non-stress-bearing areas of anterior and posterior teeth and "open-sandwich" restorations. The latter involve the use of glass ionomer as a base under composite restorations. Resin-modified GICs were developed to overcome the early moisture sensitivity of conventional cements. In addition to decreasing moisture sensitivity, resin modification also improves setting characteristics, aesthetics, physical and handling properties. The resin is typically incorporated by substituting acidic co-polymers with a water-HEMA (hydroxyethyl methacrylate) mixture or the use of acidic co-polymers with methacrylate side chains. Despite the addition of resin,




Fig. 2_SEM image of a giomer restorative with the PRG filler particles. (Image courtesy of SHOFU)

which usually constitutes 4.5 to 6 % of the set material, resin-modified GICs retain a significant acid-base reaction as part of their overall curing process, bond chemically to teeth and are capable of fluoride release and re-charge. Their caries preventive effect³ and clinical uses are similar to those of their conventional counterparts.

Composites, compomers (polyacid-modified composite) and giomers (pre-reacted glass ionomer composite) all require resin polymerisation to set

and intermediary bonding agents (micromechanical bonding) to adhere to teeth. They can be employed to restore all cavity classes (Class I to VI) and are especially useful for direct veneers and bonding.

Composite resins consist of a resin matrix (commonly bisphenol A-glycidyl methacrylate [Bis-GMA] or urethane dimethacrylate [UDMA] with triethylene glycol dimethacrylate [TEGDMA] as a diluent monomer), ceramic fillers (amorphous silica and silicate particles) with coupling agent and minor additives such as initiators, activators,

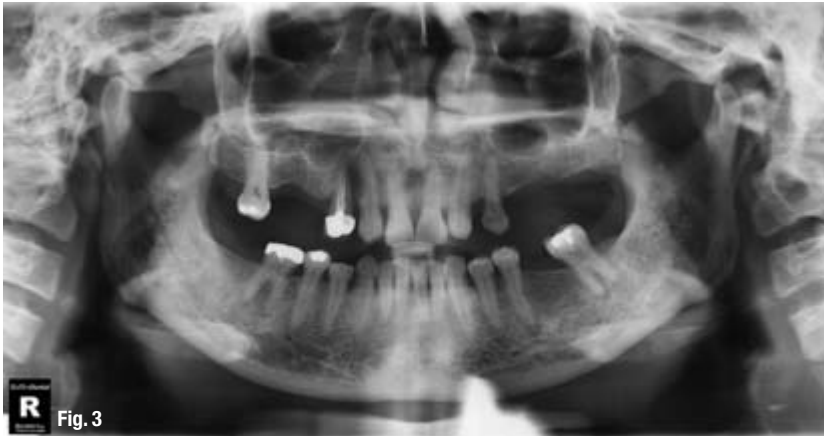

Fig. 3 Panoramic radiograph of the patient.

colouring pigments and stabilisers. Resin polymerisation can be activated chemically and/or by light. Composite resins have excellent aesthetics, physical properties and handling but are technique sensitive and shrink on curing (ranges from 1 to 5 % by volume). Compomers contain the essential components of GICs. The acid component is, however, dehydrated and incorporated in the resin matrix. After light curing, the acid-base reaction occurs slowly when the dehydrated acid is activated through water sorption resulting in a partially ionic structure within the resin matrix. Compomers are capable of fluoride release but the total fluoride release and re-charge is significantly lower than that of GICs.⁴ The water sorption needed for the acid-base reaction to take place has been shown to compromise the aesthetics and physical properties of compomers.⁵

Giomers are the most recent category of hybrid restorative material. They are touted as a true hybridisation of composites and GICs because they have the fluoride release and re-charge of GICs and the aesthetics, handling and physical properties of composite resins. Giomers are based on PRG technology in which pre-reacted GICs are used as fillers (Fig. 2). Currently available commercial products are based on S-PRG in which only the surface of the glass fillers are reacted with polyacid and a glass core remains. Examples of giomer restorative

products include Beautifil II and Beautifil Flow Plus (SHOFU).

The fluoride release and re-charge of giomers are significantly better than that of compomers but lower than GICs.^{4,6} A recent study has reported reduced dental plaque formation and bacterial adherence on giomers when compared with composite resins.⁷ This had been attributed to the formation of a material film layer on the surface of giomer restorations after contact with saliva. This material film layer, which consists of aluminium, silica, strontium and other ions, originates from the PRG filler and has also been observed with GICs.⁸

The clinical performance of giomer restorations has been evaluated in several studies involving Class I, II and V cavities up to eight years of duration. After three years, Matis *et al.*⁹ found no significant difference between giomer and micro-filled composite restorations in all the parameters evaluated. Gordan *et al.*¹⁰ evaluated the performance of giomer restorations over eight years and report no restoration failure. Significant changes were detected only for marginal adaptation at occlusal surfaces and marginal staining at proximal surfaces. Although recurrent or secondary caries is a major cause of restoration failure,¹¹ this was not observed with giomer restorations. The latter may be accounted for by their better demineralisation inhibition effect at the margins of restorations when compared with compomers and composites.¹²

MiCD in clinical practice

The spectrum of MiCD procedures and techniques involving the use of direct restorative materials has been extensively covered.¹³ The modification of tooth colour, shape, size, position and defects, as well as the replacement of missing teeth, can be conservatively achieved with no to minimal tooth preparation. Psychological (perception, personality, desire), health (general, specific, dentogingival), functional (occlusion, phonetics, comfort) and aesthetic (macro, mini, micro) factors must be considered when designing a smile and this has been incorporated by Koirala into a Smile Design Wheel.²

The following case presentation highlights the key principles of MiD (DCMO) as it applies to aesthetic dis-ease and precautions related to MiCD.

Case study

A 43-year-old female patient was referred by her general dentist for management of her aesthetic

Clinical signs	Radiographic signs	Symptoms
Increasing tooth mobility	Angular bony defects	Sensitive, painful or sore teeth
Fremitus and migration of teeth	Increased width of periodontal ligament space	Uncomfortable, uneven or "lost" bite
Cracked or fractured teeth/restorations	Increased width of lamina dura	Occlusion-related periodontal pain
Abfraction cavities	Changes in alveolar bone	Symptoms of temporomandibular disorders
Occlusal wear and heavy occlusal contacts	Vertical reduction of interdental septum	
Occlusal discrepancies	Root resorption	
Soft tissue indentations	Furcation defect	
Signs of temporomandibular disorders		

Table II

problems for social reasons. She had congenitally missing lateral incisors, a history of multiple tooth fracture and was unhappy with the spaces and shape of her upper anterior teeth. With the exception of her upper right second molar, all upper molars and second premolars were lost owing to fracture. Her posterior support was derived solely from her first premolars because she had a missing lower right second molar (Fig. 3) and did not have an upper denture. Although her upper right first premolar was crowned and her left first premolar was "pristine", both teeth were cracked.

Early detection and diagnosis of disease

The patient's aesthetic problems were exacerbated by developmental anomalies (congenitally missing laterals) and environmental factors, including occlusal disease (OD). Occlusal disease is defined as "the process resulting in the noticeable loss or destruction of the occluding surfaces of the teeth".¹⁴ The disease process is caused primarily by parafunction, especially sleep bruxism. The detrimental effects of OD could have been greatly minimised by early detection and management with a bruxism splint. Occlusal considerations are particularly important in MiCD because they have a sig-

nificant impact on restoration success. The clinical and radiographic signs and symptoms of OD are listed in Table II.

As part of the diagnosis process, quality of life issues must be explored in addition to the usual history taking, examination and special tests (e.g. electric pulp test, salivary function test). Discussion of quality of life issues should focus on patients' wants, needs and expectations with regard to:

- _ appearance;
- _ tooth sensitivity;
- _ tooth or restoration fracture or failure;
- _ soft tissue discomfort;
- _ loosening or moving teeth;
- _ bite problems; and
- _ jaw pain and dysfunction.

If MiCD is planned in the presence of OD, patients must be educated on the advantages and disadvantages of MiCD to conventional therapy, the possibility of failure and need for protection. The patient concerned was aware of her occlusal problems but wanted a quick, non-invasive and economical solution to improving her anterior aesthetics in view of a social commitment.

Table II. Signs and symptoms of occlusal disease.

Fig. 4a Pre-treatment. Fig. 4b Post-treatment.

