

cosmetic dentistry

— beauty & science

3²⁰¹³

| **CE article**

Same-day inlay/onlays
strive to save the tooth

| **special topic**

Dentofacial aesthetic analysis
using 3-D software

| **technique**

Periodontal tissue repair
in the aesthetic zone



New Orleans

American Dental Association
ANNUAL SESSION
OCTOBER 31 - NOVEMBER 3, 2013

ADA American Dental Association®
America's leading advocate for oral health



Cosmetic Dentistry Lectures

Make the 2013 ADA Annual Session your first choice for cosmetic dentistry education

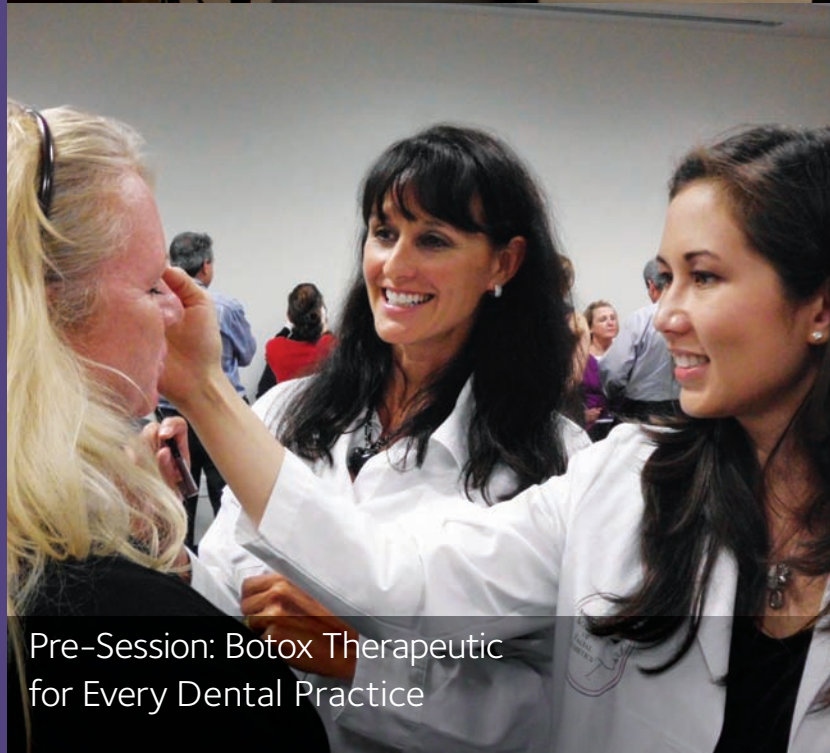Select from 18 cosmetic dentistry courses at the 2013 Annual Session and learn from renowned speakers such as Dr. Louis Malcmacher, Dr. Bud Mopper, Dr. Lee Ann Brady, Dr. David Hornbrook and more.

**Register before September 20
for the lowest rates.**

ADA.org/session



Education in the Round



Pre-Session: Botox Therapeutic
for Every Dental Practice

Smile aesthetics and occlusion: A controversial topic in dentistry



Dr Sushil Koirala
Editor-in-Chief

_Cosmetic dentists around the world routinely perform various diagnostic and therapeutic procedures that involve occlusion (fillings, crowns, bridges, removable prostheses, implant-supported restorations, full mouth rehabilitation and orthodontics). Aesthetics is related to human perception, desires and personality, and is basically guided by social trends, while occlusion is related to forces and entails the relation between the maxillary and mandibular teeth when they are in contact and the masticatory system's response to the forces generated by the new position of the teeth. Smile aesthetics and occlusion has been, and is still to some extent, controversial, as there are numerous questions related to smile and occlusion that have not been answered with scientific certainty and there are many diverse and polarised opinions regarding this.

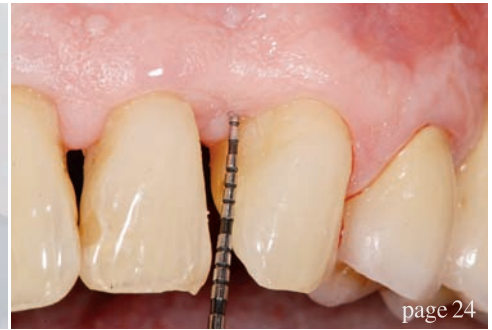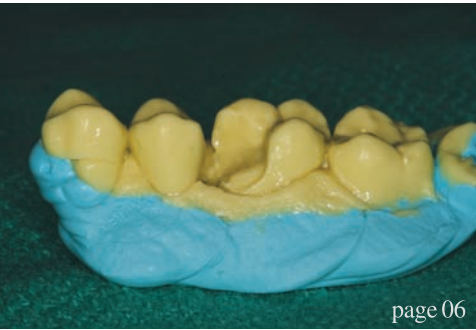In their undergraduate education, dental students are not fully trained in the science and art of both smile aesthetics and occlusion. When these new graduates enter into clinical practice and begin undertaking complex clinical cases, many become confused with the numerous theoretical recommendations and varied concepts about cosmetic dentistry and occlusion in academic and clinical dentistry. In order to understand the core relationship between smile aesthetics (macro, mini and micro) and occlusion (masticatory force management), a clinician must be familiar with the pros and cons of all the popular concepts and theories regarding smile aesthetics and occlusion, and based on this select the most conservative treatment that is best suited to the patient and that will ensure health and function.

With this in mind, two global educational academies, namely Minimally Invasive Cosmetic Dentistry (www.micdglobalacademy.com), or MiCD, and Teeth, Muscles, Joints and Airway Harmony (www.tmjaharmony.com), or TMJA, have been established with the aim of promoting healthy, comprehensive dentistry by disseminating the relevant knowledge and information regarding various concepts, theories and clinical protocols concerning smile aesthetics and occlusion.

I am pleased to mention here that recently the Faculty of Dentistry of Thammasat University in Thailand and the Vedic Institute of Smile Aesthetics in Nepal, along with three supporting partners (SHOFU Dental Asia-Pacific in Singapore, Tekscan in the USA, and Bio-Research Associates in the USA), signed a memorandum of understanding to establish the MiCD and TMJA Harmony International Training and Treatment Center at the Faculty of Dentistry of Thammasat University. This centre will coordinate with various like-minded clinicians, academics and researchers working in the field of cosmetic dentistry and offer structured, skill-based training in MiCD and TMJA harmony dentistry especially for dentists in the Asia Pacific region.

In this year's third issue of **cosmetic dentistry**, we have included various clinical articles, from simple cosmetic restorations to complicated implant treatment. I hope you will enjoy reading this issue.

Dr Sushil Koirala
Editor-in-Chief
President Vedic Institute of Smile Aesthetics (VISA)
Kathmandu, Nepal



| editorial

- 03 **Dear Reader**
| Dr Sushil Koirala, Editor-in-Chief

| CE article

- 06 **Same-day inlay/onlays** strive to save the tooth
| Drs Lorin Berland & Sarah Kong, USA

| special

- 14 **Dentofacial aesthetic analysis** using 3-D software
| Dr Valerio Bini, Italy
- 20 **Digital dental photography**
Settings for your camera and lighting systems
| Dr François Grossetti, France

| technique

- 24 **Periodontal tissue repair** in the aesthetic zone
| Prof. Giulio Rasperini & Dr Giorgio Pagni, Italy

| case report

- 28 **Structure and volume** in delayed immediate
implantation
| Dr Georg Bach & Christian Müller, Germany

| industry news

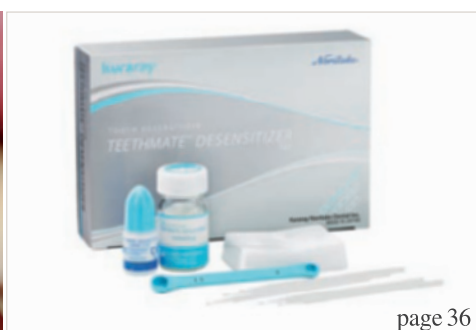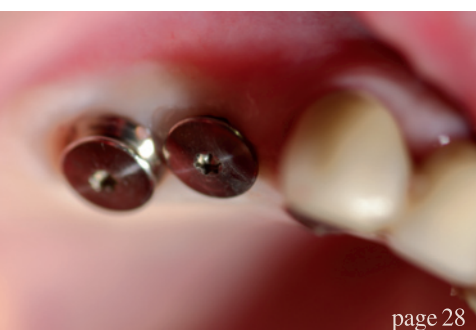- 36 **Kuraray Europe** introduces a unique desensitiser:
TEETHMATE DESENSITIZER
| Kuraray

| meetings

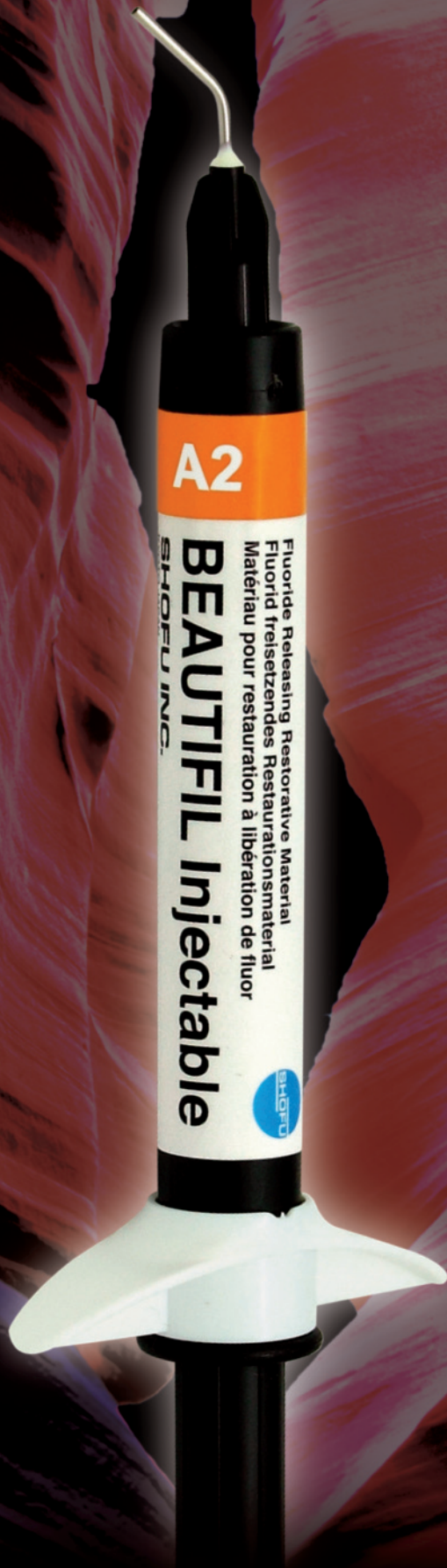- 38 **Progressive educational collaboration**
in Asia Pacific region
- 40 **International Events**

| about the publisher

- 41 | submission guidelines
42 | imprint



In a LEAGUE of its *own ...*



Inject Beauty & Strength as you directly stack and shape Beautifil Injectable into life-like aesthetic restorations that exhibit superior endurance to occlusal load, sustained fluoride protection and unique anti-plaque effect.

SHOFU DENTAL ASIA-PACIFIC PTE. LTD.

Tel (65) 6377 2722 Fax (65) 6377 1121

mailbx@shofu.com.sg website www.shofu.com.sg

Official Partner



Minimally Invasive
Cosmetic Dentistry

Same-day inlay/onlays strive to save the tooth

Authors_ Drs Lorin Berland & Sarah Kong, USA

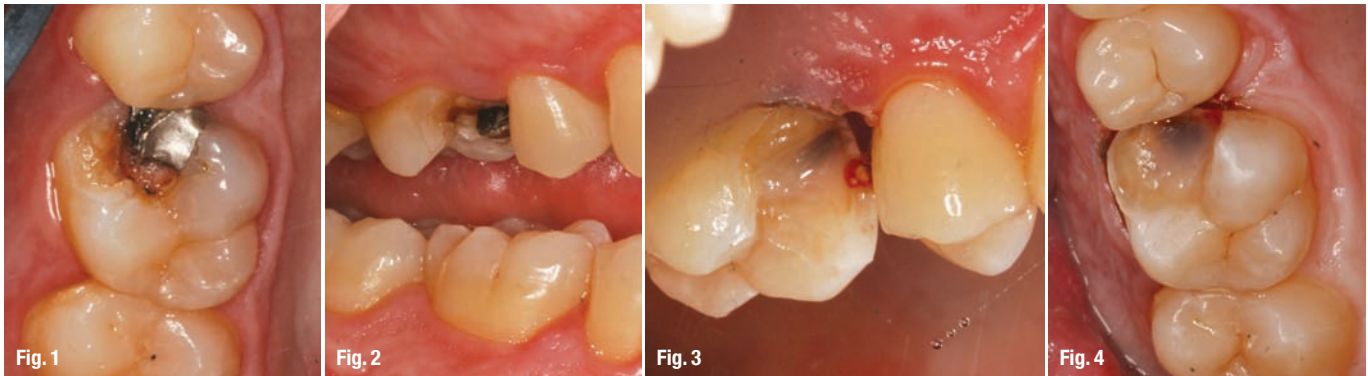

Fig. 1 _#3 pre-op, palatal view. (Photos/Provided by Dr. Lorin Berland and Dr. Sarah Kong)
Fig. 2 _#3 pre-op, buccal view.
Fig. 3 _Decay removed and lining placed.
Fig. 4 _Prepped tooth, palatal view.

_The name of the game in dentistry today is to save the tooth for use in the future. In this age of adhesive dentistry, respecting and preserving the remaining healthy tooth structure as well as improving aesthetics have become components of value as well. With today's advanced technology and materials, longevity is mainly a matter of diagnosis, correct treatment planning and proper execution of technique.

silver fillings is running out. We have to remember that amalgam technology is more than 150 years old. At that time, people lost their teeth a lot earlier and died a lot earlier, too.

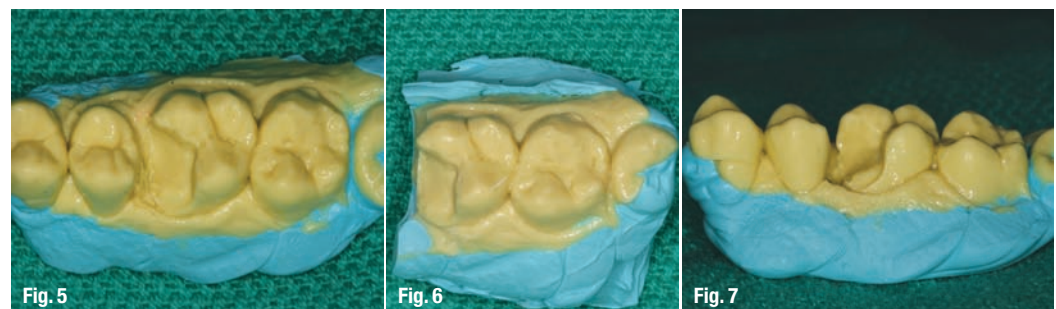
Now, however, we have a population that is over 50 years old and growing—and they want to keep their teeth feeling good and looking good. Patients are now living longer and they want and expect to keep their teeth for a lifetime.

The problem with replacing old amalgams with tooth-coloured composites is that they are difficult, inconsistent and unpredictable. Yet, the warranty on these 30-, 40- and 50-year-old

Adhesive dentistry offers a more conservative restorative approach to conventional dentistry. Why take away healthy tooth structure when

_ce credit **cosmetic dentistry**

By reading this article and then taking a short online quiz, you can gain ADA CERP CE credits. To take the CE quiz, visit www.dtstudyclub.com. The quiz is free for subscribers, who will be sent an access code. Please write support@dtstudyclub.com if you don't receive it. Non-subscribers may take the quiz for a \$20 fee.



there's a viable alternative? Why not attempt to save the good and just replace the bad? Direct composites and laboratory composite resin systems are valuable and worthwhile options to preserve tooth structure and long-term dental health. After all, preserving a patient's natural tooth, whenever possible, is always in his or her best interest.

It has been our experience that providing multiple, large interproximal posterior composites directly can be difficult to achieve on a consistent basis in the oral environment, especially when replacing amalgams. Why? Because they take a lot of chair time. Amalgams require bulk. That's why we were taught the block type preparation to provide the necessary bulk for strength.

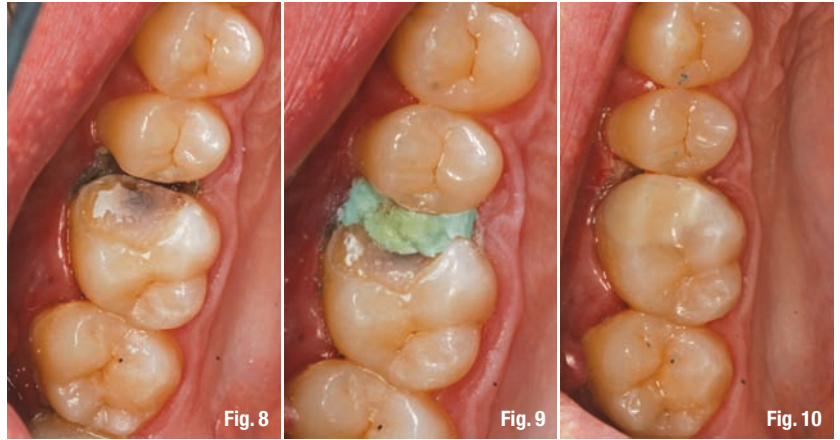
Furthermore, because amalgams do not bond, we were taught to create undercuts and "extension for prevention." As mercury contracts and expands with cold and hot temperature changes over time, cracks form in the glasslike nature of teeth.

Most of the time, these large preps are difficult to restore with direct composite. There are isolation and contamination issues, and it is difficult to replicate nature in the mouth in a timely, cost-effective and predictable manner for every case, every time. In addition, curing in layers makes for a long appointment and increases the possibility of contamination. It is uncomfortable for patients to keep their mouths open for the prolonged amount of time necessary.

Often, large direct posterior composite resins yield unsatisfactory results in terms of esthetics, and especially long-term function, due to curing and contamination issues.

However, when we do same day inlay/onlays out of the mouth and in the laboratory, we find that multiple posterior restorations are easier, stronger and more anatomically correct. Because they are processed at the same time, they can be even more time efficient than using a CAD/CAM system and reduce tooth movement during the transitional phase that can result in altered contact or occlusion.

Not having to deal with provisional restorations absolutely eliminates those untimely emergencies when temporaries break or come off. Those costly, non-productive, uncomfortable and unhappy second appointments can also be avoided, saving everyone time and money. In addition, without concerns about retention



of temporaries, preparation can be even more conservative.

_Case 1

In this case, the patient came to our office on an emergency basis with a broken tooth on the upper right molar. It was no surprise that the tooth had a previously placed MO amalgam with recurrent decay that caused the mesiobuccal cusp to fracture off completely (Figs. 1 & 2). Often, teeth that have had old amalgam fillings tend to break due to cracks caused by the expansion and contraction of the metal alloy in the tooth's glasslike substance.

In addition, caries detectors were non-existent when the bulk of amalgam restorations were placed so many teeth have recurrent decay under the old amalgam fillings.

After thorough clinical and radiographic examinations were performed, it was determined with the patient's input that a same-day onlay would be the most prudent option for this tooth. This way, he would be receiving the maximum amount of care in the least amount of time.

The procedure

After placing topical anaesthetic, articaine HCl 4 % with 1:1,00,000 epinephrine was ad-

Fig. 5 _Silicone model.

Fig. 6 _Sectioned model.

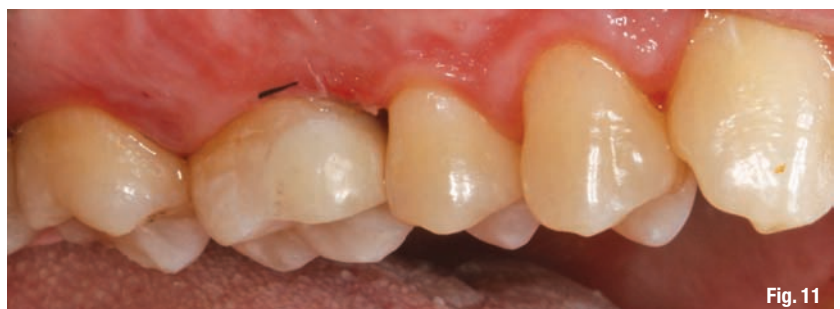Fig. 7 _Silicone model, buccal view.

Fig. 8 _Tooth ready to bond.

Fig. 9 _Expasyl placed interproximally prior to seat.

Fig. 10 _Onlay seated, palatal view.

Fig. 11 _Onlay seated, buccal view.



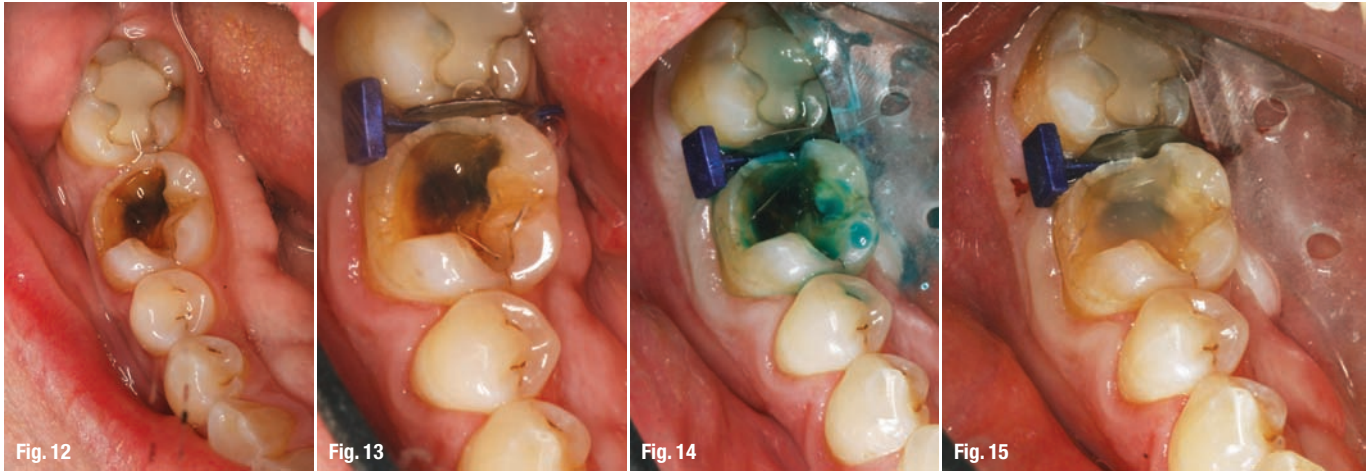

Fig. 12

Fig. 13

Fig. 14

Fig. 15

Fig. 12_Tooth #30 pre-op.
Fig. 13_FenderWedge in place.
Fig. 14_Caries detector.
Fig. 15_Prep with liner.

ministered to achieve profound anaesthesia. Next, a nitrous oxide nasal mask was placed to decrease the patient's exposure to mercury aerosol while the amalgam was being removed. In this case, because the patient opted not to use nitrous oxide, pure oxygen was administered through the nasal mask.

We continued by isolating tooth #3 with a rubber dam. This step was essential to reduce the amount of amalgam ingested by the patient. It also offers isolation, higher visibility and better dentistry for our patients. If doing quadrant dentistry, I like to use the split-dam technique, which stretches to include several adjacent teeth in a quadrant. A FenderWedge (Directa) was then placed to separate and protect the adjacent tooth during prep, air abrasion, etching, bonding and refining while continuing to wedge the teeth for a tighter interproximal contact in the final restoration.

To facilitate removal of the remaining amalgam restoration, an hourglass-shaped diamond bur was used as diamonds are less likely to produce the fracture and craze lines associated with

carbide burs. High-speed evacuation was used throughout the procedure to help decrease possible inhalation and ingestion during amalgam removal.

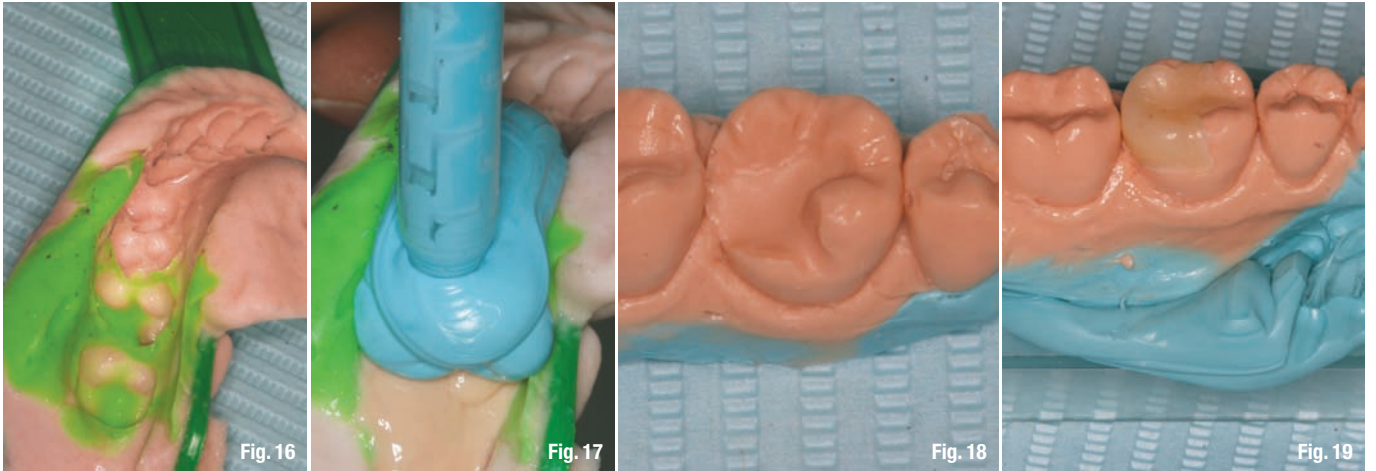
Caries detector was painted onto the prepared surface, and it was noted that cracks associated with the long-time expansion and contraction of the mercury-filled amalgam restoration had contributed to the apparent interproximal decay. Once the decay was carefully and completely excavated using a small, round diamond bur and a spoon excavator, the tooth was insulated in a few important steps (Fig. 3).

First, disinfectant was placed on the prepared dentinal surface (Hemaseal & Cide, Advantage Dental Products) and air-thinned. Then, two coats of self-etching bonding agent (OptiBond All-In-One Unidose, Kerr Dental) were placed to provide reduced postoperative sensitivity and high dentin bond strength.

After air thinning and light curing, a flowable composite (Premise Flowable, Kerr Dental) in the lightest shade was added to the internal walls and floor to create an even floor and to fill in undercuts that were originally prepared for amalgam retention. A flat-end cylinder, fine-grit, short shank diamond was used to refine the tooth preparation after insulation was completed (Fig. 4).

Next, two identical hydrocolloid alginate impressions (Dux Dental) were taken fast and accurately. They take only 90 seconds to set with our chosen materials, so they are ideal for same-day inlay/onlays. Before expressing the hydrocolloid material into the prepped tooth, we squirted a little surfactant (Prep-Wet Plus, Dux Dental) onto the tooth to wet the prep while my assistant mixed the alginate.

“Adhesive dentistry offers a more conservative restorative approach to conventional dentistry. Why take away healthy tooth structure when there’s a viable alternative? Why not attempt to save the good and just replace the bad?”



Meanwhile, a second assistant was loading a syringe with warm Identic Syringable Hydrocolloid Cartiloids (Dux Dental) to hand to me. The "plug" was initially squirted away from the prep and then into the prep itself so as not to interfere with a "clean" impression. Once the tray had been loaded with the alginate (Identic, Dux Dental), the first assistant handed it to me. The tray was inserted with gentle pressure and held steady for 90 seconds. Another impression was taken using the same aforementioned steps.

The patient then had about an hour break while the inlay was being made and was able to make the most efficient use of his time by having his teeth cleaned with the hygienist during this break in treatment. This not only made the time seem to go by faster for the patient, but it also eliminated "dead time" in our schedule.

The patient made the most of his time in the chair, fixing his broken tooth and getting his teeth cleaned. This type of combination treatment lends itself to a more productive day when scheduled this way, and patients really appreciate it.

Lab work

Meanwhile, back in the lab, the impressions were first disinfected and then poured with MACH-SLO (Parkell) and based with bite registration material on a C-Bite articulator (C-Bite, Dental Products) (Fig. 5). An electric waxing unit was used to block out any undercuts on the die (Ultra Waxer, Kerr Lab).

The onlay was incrementally built in composite layers with a D2 primary dentin base shade (Premise Indirect Primary Dentin, Kerr Dental)

followed by an A2 facial dentin shade (Premise Indirect Facial Dentin, Kerr Dental) and a neutral incisal shade (Premise Indirect Incisal, Kerr Dental).

Once the onlay was cured with light, heat and pressure in the BelleGlass curing unit (Kerr Dental) for 10 minutes, it was fitted, adjusted and polished on the silicone models (Figs. 6 & 7) with various burs and polishing wheels. All margins, contacts and contours were easily and accurately verified outside the mouth, saving valuable chair time and clinical frustration.

Seating the onlay

When seating the onlay, a medium size Isolite (Isolite Systems) was applied for easy isolation, suction, bite rest and illumination during the cementation of the onlay. No further anaesthesia needed to be administered as the tooth had been lined with flowable composite during the prep stage. Patients really appreciate this—especially because they are almost back to "normal" by the time they leave.

The onlay was then tried in to verify proper contacts, contours, margins and esthetics. Before cementation, Expasyl (Kerr Dental) was gently packed into the sulcus (Fig. 8). The aluminium chloride dried the tissue, reducing the risk of sulcal seepage and contamination. The FenderWedges were then inserted beneath the interproximal floor to slightly separate and isolate the adjacent teeth and to help facilitate seating the onlay.

After rinsing the Expasyl (Kerr Dental) thoroughly, the enamel and composite core were gently micro etched with aluminum oxide (Etch-Master, Groman Dental) to increase retention

Fig. 16 Identic Hydrocolloid impression.

Fig. 17 Basing the poured impression.

Fig. 18 Silicone model.

Fig. 19 Model with undercuts waxed.