

**DENTAL ACADEMIA TRIBUNE**

Interview: Dr. Rani,  
 Dean of College of Dentistry,  
 University of Sharjah in UAE



> page 10

**DENTAL LAB TRIBUNE**

Crowns VS Veneers  
 All the way  
 to creating aesthetic



> page 8

**MEDIA CME**

Conservative dentistry  
 achieved through a multi-  
 disciplinary approach

> page 6



**NEWS**

Dental Tribune  
 Middle East & Africa  
 kick off!

> page 2



# Planmeca extends university network with €70 million agreement

By Dental Tribune International

**H**ELSINKI & KUOPIO, Finland/  
 RIYADH, Saudi Arabia: Dental  
 equipment manufacturer Plan-  
 meca has struck a major deal  
 with two dental institutes in Finland  
 and the Middle East. In an announce-  
 ment released on Friday, the company  
 stated that it had signed an agree-  
 ment on the delivery and installa-  
 tion of dental equipment estimated to  
 be worth at least €70 million with  
 the King Saud University's College of  
 Dentistry in Riyadh in Saudi Arabia.  
 Hundreds of dental units and imaging  
 systems will also be provided to the  
 University of Eastern Finland in Kuopio,  
 according to a second agreement.



Dental students from the University of Maryland School of Dentistry performing clinical training with Planmeca equipment. The school has been partnering with the Finnish company since 2009. (DTI/Photo courtesy of University of Maryland, USA)

The contracts mark further substantial  
 business transactions for Planmeca,  
 which reported €700 million in revenue  
 last year. The equipment will be  
 shipped and installed at both dental  
 schools over the next

two months, where they will be  
 available for use in the upcoming  
 academic year, the Finnish company  
 said.

>> See FILLING, page 3

## Dr Aisha Sultan elected as Vice-President of the APDF

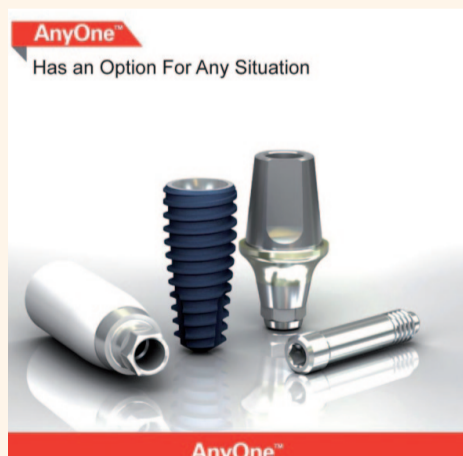By Emirates Dental Society



Dr Aisha Sultan Alsuwaidi, President of the Dental Society of the Emirates Medical Association (EMA) rocked the recent Asia Pacific Dental Federation Executive Council Election

held in Taipei, Taiwan last June 2012 winning the Vice-President post for the Middle East Region. The contest was fiercely battled by candidates from all over the Asia Pacific region, but Dr. Aisha emerged victorious and secured one of the five Vice-Presidential positions that were at stake. The election results reflect the admiration and respect that Dr Aisha enjoys within the APDF as a representative of the Emirates Dental Society. **DT**

## MegaGen launches new product in the Middle East



South Korean dental implant company, MegaGen, has begun its launch of the new AnyOne system and the Xpeed surface treatment in the Middle East.

By Dental Tribune Middle East & Africa

**D**UBAI, UAE: MegaGen, a South Korean based company, is one of the fastest growing dental implant companies in the global market. With a focus on finding minimally invasive solutions for clinicians & patients, MegaGen is already known around the world for its Rescue Short & Super Wide system - offering impressive clinical

results and proven long term success. The newer AnyRidge system offers a uniquely effective solution to clinicians in compromised or weak bone situations, with unsurpassed initial stability. With the introduction of the new AnyOne system and the Xpeed surface treatment to MegaGen's impressive range of products, MegaGen offers a solution for every clinical case.

Megagen has been present in most of the world's leading implant markets for several years. The AnyRidge international study group has been running in Europe, the United States & Asia since 2009 and we are happy to announce also in the Middle East since earlier this year. On the 12th of September, Megagen hosted introductory seminars for all clinicians who were able to attend at such short notice. An introduction to the company was followed by a clinical overview of the features & benefits of the systems with crucial insight into the importance of implant systems in achieving initial stability. Techniques for ridge split & shorter implant placement were discussed. Megagen is planning many international clinical studies including UAE & other Middle Eastern clinicians and is organizing courses & lectures to help understand the advanced product concepts. **DT**

**PH Prodont Holliger**  
 1<sup>st</sup> FRENCH MANUFACTURER OF DENTAL INSTRUMENTS AND PRODUCTS  
 MADE IN FRANCE  
 DENTISTS-LIKE DESIGN LIKE DENTISTS  
 info@prodont-holliger.fr  
 www.prodont-holliger.com

# Dental Tribune Middle East & Africa Edition kick off!



By Tzvetan Deyanov  
Business Development Manager

**D**UBAI, UAE: Dental Tribune Middle East & Africa (DT MEA) is part of the globally renowned Dental Tribune International Publishing Group – a combined network including more than 100 trade publications that reach more than 650,000 dentists in more than 90 countries in 25 languages. The unique publishing platform combines print and online media, offering a multitude of marketing

channels to reach the largest dental community worldwide in a fast paced professional style.

DT MEA will be publishing the *DentalTribune*, first global newspaper for dental professionals every other month in the Middle East & Africa region. In addition, DT MEA will be blasting out the top stories through the *eNewsletter* every other week delivering on-demand; quick and accurate weekly news feeds from the entire Middle East & Africa region. Simultaneously, all news will be available on [www.dental-tribune.com](http://www.dental-tribune.com), the global on-line destination for dentists seeking real-time clinical and product information, regional landing pages in local language with well-placed online advertising and Company profiles.

Through the *DentalTribune* newspaper, den-

tal professionals will receive a concise and highly readable format published in the region, featuring various innovative supplements such as *mCME Articles*, *Dental Lab Tribune* – (focusing entirely on the Dental Lab & Technicians), *Academia Tribune* (focusing on the regional Dental Education) together with sections such as *regional news*, *industry*, *research & development*, *latest products and events*.

No wonder Google ranks [www.dental-tribune.com](http://www.dental-tribune.com) among the most comprehensive, up-to-date and influential websites in dentistry given the hourly updated news feeds from Dental Tribune correspondents and publishers from across the globe. In order to benefit from the high Google ranking, the ever increasing online audience, and to generate active sales leads

[www.dentaltribune.com](http://www.dentaltribune.com) offers a search engine optimized *Company Profile* to the Dental Industry. This microsite contains all relevant company information and works as a gateway for all interactive industry advertising.

Dental Tribune International Group is chosen as official media partner of numerous dental associations around the world such as the FDI, ICOI, IADR and many more. An experienced international correspondent network and renowned local editorial boards ensure the highest journalism standards.

Welcome to Dental Tribune Middle East & Africa. **DT**

Dental Tribune Middle East & Africa  
E: [deyanov@dental-tribune.com](mailto:deyanov@dental-tribune.com)  
M: +971 (0)55 112 8581  
[www.dental-tribune.com](http://www.dental-tribune.com)

## The Emirates Dental Society Board visits Taiwan



By Emirates Dental Society

**T**he Dental Society Board of the Emirates Medical Association (EMA) flew to Taiwan last June to attend the 34th Asia Pacific Dental Congress (APDC) held in the city of Taipei. The delegation was headed by Dr Aisha Sultan Alsuwaidi President of the Dental Society and accompanied by Board Members Dr Nabeel Humood Alsabeeha and Dr

Ramesh Bulbule together with Secretary Mrs Baheyya Shamsuddin. The Congress was a great avenue for Dental Delegations from all over the Asia and Pacific Region to meet and exchange views on matters related to dental education, science and technology. The Congress was a success; both in its scientific and trade show component attracting a huge local and international audience. The 35th APDC is scheduled to be held in Kuala Lumpur, Malaysia in the period from 7 – 12 May, 2013. **DT**

## Mediclinic International Acquires Remaining Shares of Emirates Healthcare Holdings Limited

By Dental Tribune Middle East & Africa

**D**UBAI, UAE: On the 27th of August 2012, Mediclinic International Ltd, announced and completed its agreement to buy all the stock it does not own in Emirates Healthcare Holdings Limited (EHHL) of the Varkey Group from the Varkey Group and General Electric.

South Africa's second largest hospital company paid \$223million (Dh819million) to buyout the remaining minority shareholders' 49.63% stake in the company, completing its buyout of EHHL which, with its 11 clinics and hospitals, is Dubai's largest private healthcare provider. Even before the agreed buyout for 100% of the company, Mediclinic was the majority shareholder owning 50.37% of the total stocks, with the Varkey Group and General Electric sharing the minority with 44.39% and 5.24% respectively.

The Varkey group, owner of GEMS Education's network of schools, has commented on this decision to sell as being in line with their goals to refocus more of their attention towards education. In a recent press release, Varkey Group senior director C.N. Radharkrishnan affirms this their goals: "The decision by Varkey Group to exit its healthcare interest is only due to the Group's strategic intent of continuing to focus and grow its education business at a faster pace globally. Varkey Group wishes Mediclinic and the management and staff of Emirates Healthcare continued success in the region"

In an earlier statement, Mediclinic International CEO Danie Meintjes was quoted as saying, "This transaction is the logical next step as we continue to invest in attractive growth and development opportunities across our operations in Southern Africa, Switzerland and the United Arab Emir-

## Nigeria to break world record in tooth brushing

By Dental Tribune International

LAGOS, Nigeria: Last month, the Lagos State Government revealed that it is planning to congregate about 300,000 students from different local schools in order to beat the Guinness World Record for the most people brushing their teeth simultaneously. The event will be organised in the scope of a new dental care programme in Lagos.

In order to promote better oral hygiene among Lagosians and adolescents in particular, the new preventive dental care programme will be implemented in the city's primary health care centres from October.

"It is a school-based oral health intervention programme that will culminate in a world record attempt for the number of people brushing their teeth simultaneously at multiple locations," announced Dr Yewande Adeshina, Special Adviser to the Governor of Public Health, during a world press conference last month.

At noon on 5 December this year, the government hopes to assemble students from about 300 local schools in Lagos, identified through the Ministry of Education, to brush their teeth for one minute, said Dr

Bakare Lawal, the project's head.

In addition, Adeshina stressed that the project is aimed not only at breaking the world record, but also at providing vital health information. "The world record toothbrushing challenge is an opportunity for oral health to be brought to the forefront for Lagos State and Nigeria," said Dr Lola Agbaje, chair of the state chapter of the Nigerian Dental Association.

The current record is 177,003 people brushing their teeth simultaneously at 380 locations across India in an attempt organised by Colgate-Palmolive in association with the Indian Dental Association on 9 October 2007. **DT**

### International Imprint

Licensing by Dental Tribune International  
 Publisher Torsten Oemus  
 Group Editor Daniel Zimmermann  
[newsroom@dental-tribune.com](mailto:newsroom@dental-tribune.com)  
 +49 341 48 474 107  
 Magda Wojtkiewicz  
 Clinical Editor Yvonne Bachmann  
 Online Editor Claudia Duschek  
 Editorial Assistance Sabrina Raaf  
 Copy Editors Hans Motschmann

Publisher/  
 President/CEO Torsten Oemus  
 Director of Finance  
 & Controlling Dan Wunderlich  
 Media Sales Managers Matthias Diessner  
 Vera Baptist  
 Peter Witteczek  
 Maria Kaiser

Marketing &  
 Sales Services Nadine Parczyk  
 License Inquiries Jörg Warschat  
 Accounting Manuela Hunger

Business Development  
 Manager Bernhard Moldenhauer  
 Executive Producer Gernot Meyer

International Editorial Board  
 Dr Nasser Barghi, USA – Ceramics  
 Dr Karl Behr, Germany – Endodontics  
 Dr George Freedman, Canada – Aesthetics  
 Dr Howard Glazer, USA – Cariology  
 Prof Dr I. Krejci, Switzerland – Conservative Dentistry  
 Dr Edward Lynch, Ireland – Restorative  
 Dr Ziv Mazor, Israel – Implantology  
 Prof Dr Georg Meyer, Germany – Restorative  
 Prof Dr Rudolph Slavicek, Austria – Function  
 Dr Marius Steigmann, Germany – Implantology  
 © 2012, Dental Tribune International GmbH. All rights reserved.

Dental Tribune makes every effort to report clinical information and manufacturer's product news accurately, but cannot assume responsibility for the validity of product claims, or for typographical errors. The publishers also do not assume responsibility for product names or claims, or statements made by advertisers. Opinions expressed by authors are their own and may not reflect those of Dental Tribune International.

**Dental Tribune International**  
 Holbeinstr. 29, 04229 Leipzig, Germany  
 Tel.: +49 341 4 84 74 302 | Fax: +49 341 4 84 74 173  
[www.dental-tribune.com](http://www.dental-tribune.com) | [info@dental-tribune.com](mailto:info@dental-tribune.com)

**Dental Tribune Middle East & Africa Edition**

Editorial Board  
 Dr. Aisha Sultan Alsuwaidi, President Emirates Dental Society  
 Dr. Nabeel Humood Alsabeeha, Consultant Prosthodontist, Ministry of Health, UAE

Rodny Abdallah, Dental Technician, CDT, Lebanon

Dr. Dobrina Mollova, MDS, UAE

Director of mCME Dr. Dobrina Mollova  
[info@cappmea.com](mailto:info@cappmea.com),  
 +971 50 42 43072

Business Development  
 Manager Tzvetan Deyanov  
[deyanov@dental-tribune.com](mailto:deyanov@dental-tribune.com)  
 +971 55 11 28 581

Designer Antoaneta Voleva  
[design@dental-tribune.net](mailto:design@dental-tribune.net)

to pay for expansion abroad. **DT**

# Minimizing risks using conventional and digital shade determination, shade communication and shade control

(3-part series)

The technological revolution from conventional to digital technology is gathering increasing momentum in a number of industries. At the same time, customer expectations are also growing, both in terms of greater individuality and quality, and also with regard to faster treatments at a less expensive price.

As these expectations apply to many areas of our lives, it is natural to expect that a guide should also be available for the area of cosmetic dentistry that guarantees individual, esthetic and superior quality tooth shade reproduction.

## The keystones to prosthetic success

Shade determination, shade communication, shade reproduction and shade control are the four keystones of an efficient, standardized process chain in the fabrication of high-quality dental restorations. This structured and standardized approach guarantees the best possible treatment of the patient's needs by the dental surgeon and dental technician. Shade determination is the basis here for all subsequent steps, and so must be performed thoroughly and accurately.

The issue of tooth shade is one of considerable importance to the patient. This is due to the fact that for patients, shade is one of the few tangible points of reference that they have when it comes to evaluating restorative treatment.

## VITA: setting shade standards for 50 years

Those involved in shade taking have a variety of determination systems at their disposal for unique shade description. It has

been over 50 years since VITA Zahnfabrik introduced the VITAPAN classical shade guide. This original A1-D4 shade guide is considered the standard internationally in tooth shade determination and classifies tooth shades as A1-A4 (reddish – brownish), B1-B4 (reddish – yellowish), C1-C4 (grayish shades) and D2-D4 (reddish – gray).

In a further step towards individual determination of the tooth shade, VITA developed the SYSTEM 3D-MASTER, which

was the first tool to illustrate the tooth color space in a structured and comprehensive fashion. This approach is based on the fact that naturally-occurring tooth shades can be determined in a systematic fashion by selecting tooth lightness, chroma and hue. Naturally-occurring tooth shades vary most strongly in terms of degrees of lightness and as a result, incorrect determination is most clearly visible here. The 3D-MASTER SYSTEM uses this information and classifies the 29 sample teeth into 5 levels of lightness, 3

levels of chroma and 2 hues. With the VITA Linearguide 3D-Master, this approach has been perfected – the person taking the shade can determine the tooth shade precisely and methodically in just two steps (1. Lightness, 2. Chroma and hue).

## Digital dental shade taking – fast and precise

Fast and objective results for tooth shade measurement are prerequisite for an effi-

## VITA Easyshade® Advance – To err was human!

More precise than the eye: digital determination and verification of all tooth shades



VITA shade, VITA made.

**VITA**

VITA Easyshade Advance features cutting-edge spectrophotometric shade measurement technology with an integrated light source. As a result, it is entirely independent of ambient conditions and delivers shade results in VITA

SYSTEM 3D-MASTER, VITA classical A1–D4 and VITABLOC shades in a matter of seconds. Increase your reliability and profitability – very easily and entirely digitally with Easyshade Advance. / [www.vita-zahnfabrik.com](http://www.vita-zahnfabrik.com)

<< FILLING, page 1

Planmeca already provides equipment to dental institutions and colleges in more than 25 countries around the world. Earlier this year, the company began supplying one of Malaysia's largest dental schools in Kuala Lumpur with dental units, as well as panoramic and intra-oral imaging equipment.

The equipment provided to the colleges in Riyadh and Kuopio will include Planmeca Sovereign and Compact i dental units, as well as PlanmecaProMax 3D X-ray imaging devices and PlanmecaProX digital intra-oral units. Once installed and networked with each other, they will provide an interactive learning environment for students and help to improve the quality of dental care services, the company said.

As one of the leading institutions in the Arabic world, King Saud University's College of Dentistry currently has more than 120 students enrolled for its BDS programmes. Supported by the Saudi government, it seeks to become an internationally renowned institute for dental education and research by 2030.

The University of Eastern Finland, a recent merger of the University of Joensuu and the University of Kuopio, began educating dentists in 2010. **DT**

cient digital workflow. VITA developed a digital shade-taking device because, in conventional shade determination, external influences and the individual perception of color of the person taking the shade can have a significant impact on the process chain, right from the start of the reproduction process.

The digital shade-taking device VITA Easyshade was launched in 2004, and has been continually improved since then. Now in its third generation, today's VITA Easyshade Advance allows the user to determine tooth shades objectively in a matter

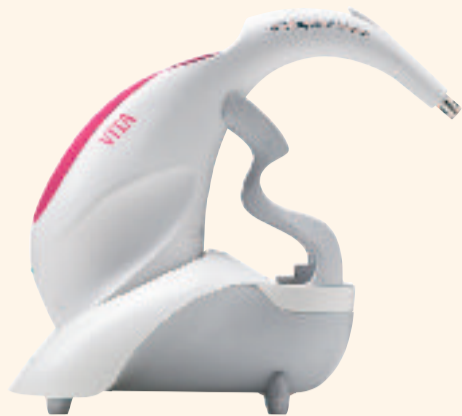

Fig. 1 VITA Easyshade Advance

of seconds. The high measuring accuracy is based on spectrophotometric technology, which ensures that tooth shades can be determined regardless of ambient lighting or reflection. The measurement results are specified in VITA classical A1-D4, VITA SYSTEM 3D-MASTER and in VITABLOCS shades. It can be used to measure and verify both natural dentition and ceramic restorations, allowing the user to implement their own quality management process.

An additional tool is the VITA ShadeAssist communication software that can be combined with VITA Easyshade Advance to optimize the process chain.

In the coming issues, we will be reporting on the areas of "Conventional and digital shade communication" and "Shade reproduction and control".

**VITA Zahnfabrik H. Rauter GmbH & Co. KG**

Headquartered in Bad Säckingen/Germany, VITA Zahnfabrik H. Rauter GmbH & Co. KG has been developing, producing and marketing innovative solutions for dental prosthetics according to consistently high quality standards for over 85 years, and has been known from the very beginning as a pioneer and worldwide trendsetter. The VITA shade standard, for instance,

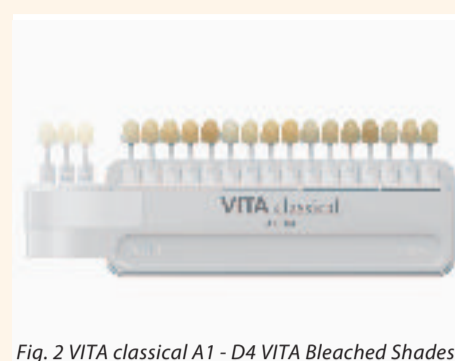


Fig. 2 VITA classical A1 - D4 VITA Bleached Shades

is recognised internationally in the dental branch as a shade reference system. Users in 120 different countries benefit from the comprehensive range of products and services provided by VITA Zahnfabrik. These include analogue and digital tooth shade determination systems, acrylic and ceramic teeth, veneering and framework materials for conventional and computer-aided manufacturing procedures, dental equipment as well as a wide range of service and training facilities. **DT**

**Your contact person**

Gert Schimak  
Tel. + 49 (0) 7761 562 226  
Fax + 49 (0) 7761 562 281  
E-mail: g.schimak@vita-zahnfabrik.com  
Internet: www.vita-zahnfabrik.com

Under the Patronage of  
H. H. Sheikh Hamdan Bin Rashid Al Maktoum  
Deputy Ruler of Dubai, Minister of Finance  
President of the Dubai Health Authority

تحت رعاية  
سمو الشيخ حمدان بن راشد آل مكتوم  
نائب حاكم دبي وزير المالية  
رئيس هيئة الصحة بدبي

**ايكس  
AEEDC  
DUBAI**

Delivering Science & Technology

**UAE INTERNATIONAL  
DENTAL CONFERENCE &  
ARAB DENTAL EXHIBITION**

5 - 7 February, 2013  
Dubai International Convention & Exhibition Centre

www.aeedc.com

- Excellent platform to network with over **28,000** dental professionals and oral health care providers.
- More than **900** exhibitors from **80** representing countries.
- **3 days** of quality education and business opportunities.

Find AEEDC Dubai on

BlackBerry PIN: 286FC1C7  
twitter  
facebook  
LinkedIn  
YouTube

Organised by  
INDEX® CONFERENCES & EXHIBITIONS ORGANISATION EST.

In Cooperation with  
CONVENTION OF DUBAI  
Dubai Health Authority

Strategic Partner  
Scientific Dental Service

Supported by

INDEX® Conferences & Exhibitions Organisation Est.  
Dubai Healthcare City, Ibn Sina Medical Complex #27, Block B, Office 203 | P.O. Box: 13636, Dubai, United Arab Emirates  
Tel: +971 4 3624717, Fax: +971 4 3624718 | E-mail: info@aeedc.com, Website: www.index.ae

**Dental Tribune Middle East & Africa  
welcomes comments and suggestions.**

Please subscribe to our  
**Dental Tribune Middle East & Africa  
eNewsletter at  
deyanov@dental-tribune.com**

**DENTAL TRIBUNE**  
— The World's Dental Newspaper MEA Edition —

Meet us at **IDS**  
Booth V-015  
Hall 10.2  
12.-16.3.2013

**PROMEDICA**  
Highest quality made in Germany

- high quality glass ionomer cements
- first class composites
- innovative compomers
- modern bonding systems
- materials for long-term prophylaxis
- temporary solutions
- bleaching products ...

**All our products convince by**

- excellent physical properties
- perfect aesthetical results

**Light-curing nano-ceram composite**

- highly esthetic and biocompatible
- universal for all cavity classes
- comfortable handling, easy modulation
- also available as flowable version

**Temporary crown & bridge material**

- less than 5 min. processing time
- strong functional load
- perfect long-term aesthetics
- excellent biocompatibility

**Resin-reinforced glass ionomer luting cement**

- strong adhesion
- very low film thickness
- especially suited for zirconia-based pieces

**PROMEDICA Dental Material GmbH**  
phone: +49 43 21/5 41 73 · fax +49 43 21/5 19 08 · Internet: www.promedica.de · eMail: info@promedica.de

**PROMEDICA**

# Dental occlusion/temporomandibular joint and general body health

*Drs Yong-Keun Lee & Hyung-Joo Moon discuss clinical evidence and mechanism of an underestimated relationship*

During the treatment of symptoms originating from disorders of the temporomandibular joint (TMJ) and occlusion, it was found that restoring the TMJ to its normal condition resulted in a change of general body health. In most cases, this change was improved general body health. Owing to similar reports, a connection between TMJ status and general body health was therefore hypothesised. However, the mechanism of this relationship remains unclear.

## TMJ and myofascial pain

Dental occlusion is the relationship between the maxillary and mandibular teeth when they approach each other.<sup>1</sup> The TMJ is the joint of the jaw, which is unique in that it is the only bilateral joint that crosses the midline.<sup>2</sup> As the treatment of dental diseases aims to achieve harmony within the entire stomatognathic system, teeth could be literally considered to be a set of gears anchored in bone, while the upper and lower jaws are attached to each other by the TMJ.<sup>3</sup>

The causes of TMJ disorders can be divided into five categories: dental, trauma, lifestyle habits, stressful social situations and emotional factors.<sup>4</sup> Trauma can be in the form of whiplash, traction appliances and blows to the head, face or jaw.<sup>4</sup> Evidence of significant trauma to the TMJ has also been found following hyperextension of the cervical spine.<sup>5</sup> With regard to habits, bad posture, bad ergonomics at work, oral and childhood habits, as well as poor diet and strenuous activities such as heavy lifting, have been cited.<sup>4</sup>

Myofascial pain, deriving from the hyperalgesic trigger points located in skeletal muscle and fascia, is commonly characterised by persistent regional pain.<sup>6</sup> The myofascial component has generally been considered to be part of pain syndromes that involve TMJ. Trigger points in masticatory muscles are presumably caused by malocclusion, misalignment and habitual parafunction of the jaws, abnormal head and neck postures, or trauma.<sup>6</sup>

## Relationship between TMJ and general body health

There have been several studies on the relationship between occlusion/TMJ and general body health. Among other findings, it has been found that lesions in the masticatory muscles or dentoalveolar ligaments can perturb visual stability and thus generate postural imbalance.<sup>7</sup> The position and functioning of the mandible also have an effect on the centre of gravity.<sup>8,9</sup>

Dental occlusion is associated with reduced lower extremity strength, agility and balance in elderly people.<sup>10</sup> The proper functional occlusion of natural or artificial teeth has been shown to play an important role in generating an adequate postural reflex.<sup>11</sup> The subgroups of general body conditions associated with TMJ may be divided into the following three categories:

### 1) Synchronisation of head & jaw muscles with other muscles

There is a necessary systematic synchronisation of the head and jaw muscles with the other muscles of the body to maintain proper body posture. The functional coupling of the stomatognathic system with the neck muscles is well known. Patients suffering from occlusal or TMJ disorders have reported dysfunction and pain in their neck muscles.<sup>12,13</sup> An imbalance of sternocleidomastoid muscle activity, often leading to neck pain, can be induced by a unilateral loss of occlusal support.<sup>14</sup>

The biomechanical impact on cervical vertebrae during mastication has been calculated, which confirmed that vertical occlusal alteration can influence stress distribution in the cervical column.<sup>15</sup> Possible associations between trunk and cervical asymmetry and facial symmetry have been reported.<sup>16</sup> For example, it has been found that visual perception control is most important in orienting the head in the frontal plane.<sup>16</sup> A relationship between dental occlusion and postural control has also been postulated.<sup>17</sup>

### 2) TMJ and body stability

Dental occlusion/TMJ condition exerts an influence on body stability. Human beings assume a relatively unstable postural state when in the standing position; therefore, the maintenance of a standing position is related to fluctuation in the centre of gravity, which is controlled by information from the ocular region, the three semicircular canals and anti-gravity muscles.<sup>18</sup>

It has been suggested that occlusion and head position affect the centre of gravity, resulting in an increased risk of falling when abnormal.<sup>19</sup> Poor or absent dental occlusion may decrease proprioception in this area, interfering with the proper stability of the head posture.<sup>7</sup> It is thought that tooth loss is a risk factor for postural instability.<sup>20</sup> Physiologically, mechanical receptors in the periodontal membrane control mandibular movements and coordinate masticatory function,<sup>21</sup> and this is related to the motor activity of the neck muscles.<sup>22</sup>

Fluctuation in the centre of gravity caused by altering the occlusal contact area experimentally was examined experimentally, and the results confirmed that occlusal contact affects gravity fluctuation and that appropriate occlusion attained by maintaining even occlusal contact in the posterior region is crucial for gravity fluctuation.<sup>23</sup>

### 3) TMJ & physical performance

TMJ conditions can influence physical performance. Trainers often advise athletes to wear occlusal splints or mouth guards during competitions in order to increase motor performance.<sup>24</sup> It has also been reported that proper teeth clenching plays an effective role in the enhancement of physical performance.<sup>25</sup>

The relationship between the presence of occlusal support in edentulous subjects and their capacity for physical exercise has been investigated, and it was concluded that reconstruction of occlusal support holds significance not only for the restoration of masticatory function but also for the maintenance of physical exercise.<sup>26</sup>

Mechanism of relationship between the TMJ and general body health based on the myofascial aspect It is the first hypothesis of this article that TMJ and other parts of the body are connected through fasciae, which is a connective element between various anatomical structures,<sup>27</sup> very similar to a three-dimensional network extending throughout the whole body.<sup>28,29</sup> This network can be stretched by the contraction of underlying muscles and transmit tension over a distance.<sup>30,31</sup>

The fascial tissues are arranged vertically, from head to toe, and four interconnected transverse fascial planes crisscross the body. Therefore, should an injury occur in one part of the body, pain and dysfunction may occur throughout the body.<sup>32</sup>

### Mechanism based on qi and the meridian aspect

The second hypothesis is that the TMJ and other parts of the body are connected through the meridian system, which is constituted of the fasciae. Traditionally, acupuncture meridians are believed to form a network throughout the body, connecting peripheral tissues to each other.<sup>33</sup> Studies that seek to understand the acupuncture point/meridian systems from a Western perspective have mainly focused on identifying distinct histological features that differentiate acupuncture points from surrounding tissue.<sup>34</sup> One of the histological and anatomical associations with the meridians is intermuscular or intramuscular loose connective tissue (fascia).

Ancient acupuncture texts contain several references to "fat, greasy membranes, fasciae and systems of connecting membranes" through which the qi is believed to flow.<sup>35</sup> In terms of connective tissue associations, several authors have suggested that a connection may exist between the acupuncture meridians, which tend to be located along the fascial planes between muscles or between a muscle and bone or tendon, and the connective tissue.<sup>34,35</sup>

In view of experimental evidence, it has been hypothesised that the network of the meridians can be viewed as a representation of a network of interstitial connective tissues. These findings are supported by ultrasound images showing connective tissue cleavage planes at the acupuncture points in human beings.<sup>34</sup> Rather than viewing acupuncture points as discrete entities, it has been proposed that these points might correspond to sites of convergence in a network of connective tissue permeating the entire body, similar to highway intersections in a network of primary and secondary roads.<sup>34</sup>

### Correlation between trigger points and acupuncture points

Although separated by two millennia, the traditions of acupuncture and myofascial pain therapies share fundamental similarities in the treatment of pain disorders.<sup>36</sup> Recent reports have suggested substantial anatomic, clinical and physiological overlap of the myofascial trigger points and acupuncture points.<sup>36</sup> The analogy between the trigger points and acupuncture points has been discussed since 1977,<sup>37</sup> when 100 per cent anatomic and 71 per cent clinical pain correspondences for the myofascial trigger points and acupuncture points in the treatment of pain disorders were reported.

A number of similarities between them were also suggested. The two structures have similar locations and needles are used at either point to treat pain. The pain associated with the local twitch response at trigger points is similar to the de qi sensation, and the referred pain generated by needling trigger points is similar to the propagated sensation along the meridians.

It was pointed out, however, that the acupuncture points located at the trigger points are not frequently used by acupuncturists, and do not share the same clinical indications as the trigger point therapy.<sup>38</sup> It was further argued that the claim of 71 per cent correspondence between the acupuncture points and the trigger points<sup>37</sup> is conceptually impossible. Furthermore, even putting this conceptual problem aside, no more than 40 per cent of the acupuncture points correlated with the treatment for pain and, more likely, only approximately 18 to 19% of the points are actually correlated.<sup>39</sup> The correlation between the trigger points and the acupuncture points clearly need to be further investigated in the future.

The fascial connection theory we propose can explain the functional connection between dental occlusion/TMJ and other parts of the body based on either myofascial release or the qi and meridian system, or a combination of both. Therefore, dental occlusion should be built up and maintained in a normal natural condition, while causes for deterioration of the TMJ status should be treated in an effort to restore the natural condition.

*Editorial note - This article is a summary of two review papers recently published in the Journal of Alternative and Complementary Medicine 17 (2011): 995-1000 & 1119-24. A complete list of references is available from the authors. DT*

## Contact Information

Drs Yong-Keun Lee and Hyung-Joo Moon are practicing dentistry at the Moon Dental Hospital and ICPB in Seoul in South Korea. They can be contacted at ykleedm@gmail.com.



# Conservative dentistry achieved through a multi-disciplinary approach

*Combining orthodontics and CAD/CAM technology to achieve conservatism for a rehabilitation case*

ADA CERP® Continuing Education Recognition Program

*mCME articles in Dental Tribune have been approved by HAAD as having educational content for CME credit hours. This article has been approved for 2 CME credit hours.*

By Dr. Thomas Colina, DMD

**C**omplex treatment needs can necessitate oral rehabilitation of patients. Often these patients will require a multi-disciplinary approach to correct problems. When patients have significant concerns, such as severe malocclusions or destruction of dental tissue, oral rehabilitation can entail extensive treatment that may involve reconstructions.

To return the patient to optimal function, regain normal form and address possible concerns such as esthetics, an integrated approach that involves various disciplines needs to be taken. The challenge posed to a particular treatment plan may involve the treatment of many teeth and possibly the need to prepare a significant number of teeth and corresponding dental tissue.

Another challenge in reconstruction cases is the cost associated with the restoration of numerous teeth. Cost may be a factor for patients. There are often many options and approaches that can lead to the same successful treatment outcome. The variety of options can be at different ends of the spectrum. Diagnostic tools, including tomograms and the use of CAD/CAM systems, are useful in achieving complex treatment goals. This paper presents a treatment option that is an alternative to the reconstruction approach through the innovative application of multiple disciplines and current technology.

## Case presentation

A 31-year-old male patient presented with the chief complaint of his upper front teeth restorations breaking off a few months after being placed. He has had the front teeth restored numerous times with the same outcome. A comprehensive examination and records revealed the following findings.

## Medical history and functional concerns

There is a history of arthritis in the family. The patient experiences transient pain from his back, neck and shoulders. He has noted he clenches and grinds his teeth day

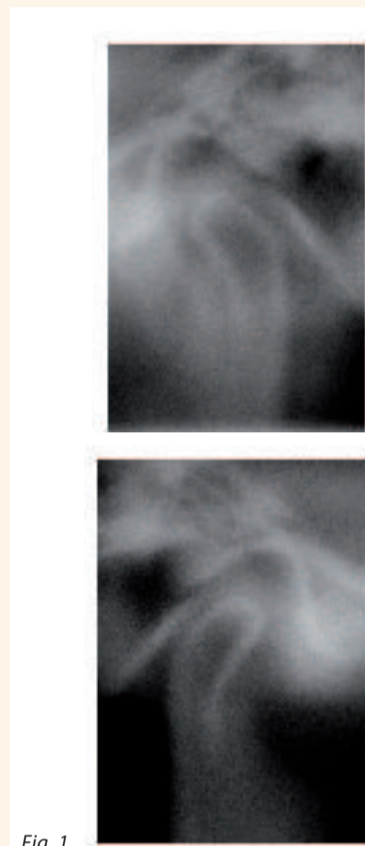


Fig. 1

**Fig. 1** Corrected lateral tomograms of the TMJ at maximum intercuspation. Note the posteriorly displaced condyles that have undergone morphological bending. (Photos/Provided by Dr. Thomas Colina)

and night. He was involved in a motor vehicle accident and sustained head trauma 12 years before his presentation to our office. Along with routine examination protocols, the temporomandibular joint (TMJ) was examined using a TMJ health questionnaire, range of motion examination, muscle palpation and TMJ imaging.

TMJ findings and symptoms were: normal maximum opening to 53 mm; no limitation in excursion; at opening, there is a 2 mm deviation to the left. There is a posterior slide from centric relation to maximum intercuspation. The patient noted cracking noises from the TMJ at opening and closing, and there has been occasional locking of the TMJ through the years. He has slight hearing loss and tinnitus.

As a routine for patients exhibiting TMJ dysfunction, a TMJ tomogram series was taken. Tomographic series was achieved

by use of a CranexTome (Soredex, Tuusula, Finland). The CranexTome has a unique spiral tomography for cross-sectional images. Interpretation of hard tissue imaging study would include the evaluation of condylar and temporal component morphology and integrity of the bony articulating surfaces. The TMJ is assessed for signs of remodeling, degenerative joint disease or morphological variations affecting the TMJ, jaw and skull.

Condylar position in maximum intercuspation is evaluated. The diagnostic tools are used not only for initial assessment to attain a working and definitive diagnosis, but during and after treatment to assess attainment of the treatment objectives. The corrected lateral TMJ view taken at maximum intercuspation reveals a posteriorly displaced condyle and morphological bending of the condyles (Fig. 1). The joint vibration analysis (JVA Bioresearch International, Milwaukee, Wis.) is used to assess TMJ health for patients and yielded fairly normal vibrations of the TMJ.

## Skeletal pattern

Based on a cephalometric analysis, the patient presented with a Class I skeletal pattern with a slight retrognathic mandible.

## Occlusion

A visual examination and cast analysis revealed a Class II dental pattern with a deep overbite and tight overjet, fractured upper incisor restorations, slight crowding of the upper and lower arches, and severe worn dentition (especially the anterior teeth). The upper incisors were retroclined, and the upper and lower incisors had severe wear (Fig. 2).

There was generalized moderate wear on the posterior teeth. The patient presented with a posterior shift of 2 mm from centric relation to maximum intercuspation.

## Treatment options

The following treatment options were presented to the patient:

- *Reconstruction of the arches to achieve an idealized occlusion.* This first option would entail splint therapy and eventual reconstruction to

achieve a stabilized occlusion. This approach will provide a stable occlusion and would entail restoration of numerous teeth — both anterior and posterior — to support the anticipated change in vertical dimension. The disadvantage to the approach is the introduction of artificial material in the mouth and the need for maintenance of the restorations. Of course, this approach also entails significant dental tissue reduction to provide partial and full coverage restorations to support the occlusal scheme.

In addition, although the treatment can be provided in a fairly short amount of time, the cost for the restorations can be significant for most patients.

- *Orthodontic approach to achieve the best possible occlusion and orthopedic alignment.* This approach provides for the patient an option to conserve dental structure, minimize the number of restorations to provide a stable and functional occlusion, and allows cost for the treatment to be more manageable. The disadvantage is the time required to achieve orthopedic and orthodontic correction.

## Treatment plan details

Straight wire appliance treatment (SWA) was proposed to attain ideal inter- and intra-arch alignment augmented by a mandibular repositioning mechanics by way of posterior build-ups and elastics or a fixed orthotic or use of a Twin Force Appliance. This phase of treatment was anticipated to last 20 months. After the orthodontic treatment, restoration of the six anterior maxillary teeth with porcelain restorations would follow. The lower incisors will be evaluated for the need of restorations. The need for an upper bruxing appliance would also be evaluated after the completion of the restorations.

## Discussion of the treatment

The first phase of the treatment was the provision of orthodontic therapy using GAC Innovation C Self Ligating Bracket System. The Innovation C bracket system has a highly translucent porcelain structure and a rhodium coated clip, which provide superb esthetics as well as a high-torque component for the incisors of 17 degrees for the upper central and 10 degrees for the upper lateral incisors. One of the main goals for the treatment was the correction of the maxillary incisor torque. The retroclined upper incisors had contributed significantly to the severe wear of the anterior teeth and had resulted in an intercuspation that produced a posteriorly displaced condyle. The correction of the incisor torque brought about a natural repositioning of the mandible, which was a treatment goal for the patient. The JVA, which has been proven effective in discriminating joint vibrations to assess TMJ1,2 conditions, was utilized to evaluate the TMJ during and after treatment. Anterior repositioning of the mandible has been described in the literature as a viable approach in the treatment of Class II malocclusions and TMJ dysfunction.

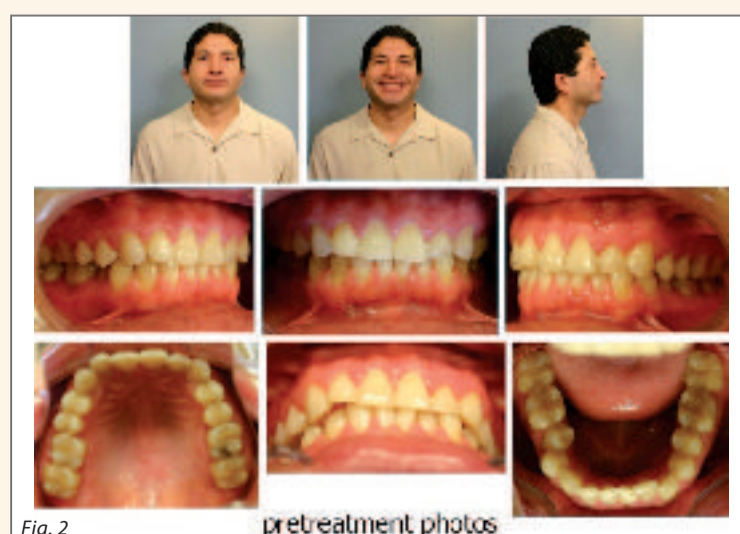

Fig. 2

**Fig. 2** Pretreatment photos.

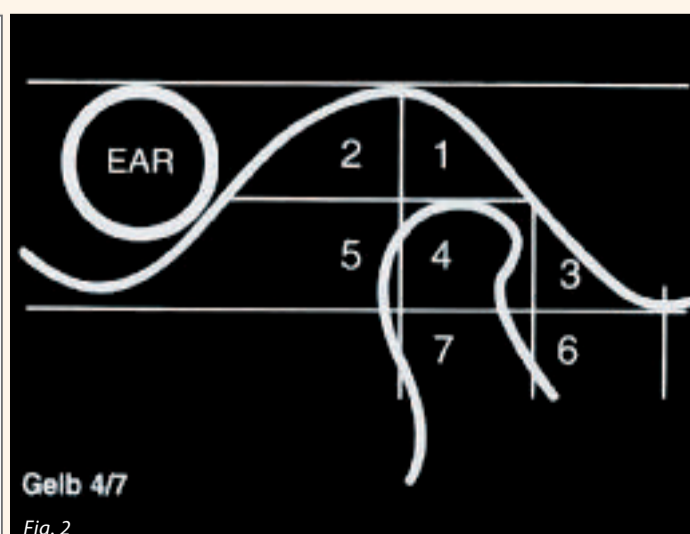


Fig. 3

**Fig. 3** Gelb 4/7 physiologic position.

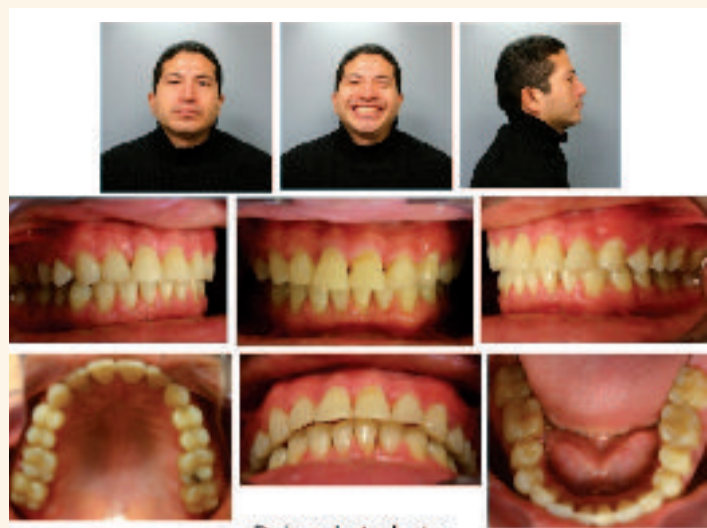

Fig. 4

Fig. 4 Debracket photos.

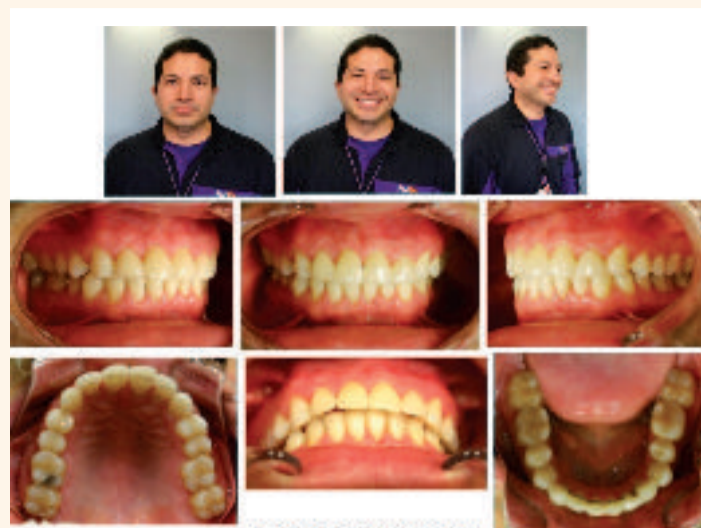

Fig. 5

Fig. 5 Veneer post insert photos.

Woodside<sup>3</sup> and McNamara<sup>4</sup> describe a functional approach to the correction of the Class II malocclusion. Anterior repositioning therapy has had a history of more than 50 years. Gelb<sup>5</sup> referred to his repositioning appliance in 1959 and described the Gelb 4/7 position, which is currently accepted in the literature and recognized by many practitioners treating TMJ dysfunction to correlate with the physiologic position of the condyle in the fossa (Fig. 3). Several functional appliance designs and their efficacy of improving TMJ dysfunction through mandibular repositioning have

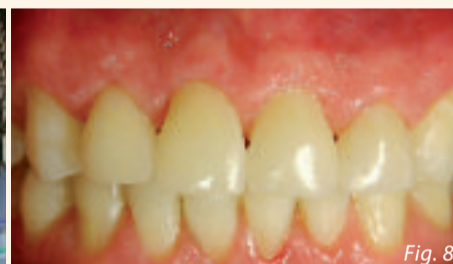vide restorations for only the upper incisor (Figs. 4, 5). The upper incisors were prepared conservatively and restored with porcelain IPS e.max CAD lithium disilicate veneers milled with the chairside E4D Dentist CAD/CAM system (D4D Technologies, Richardson, Texas) (Figs. 6–8).

There are numerous systems that are currently available. Systems are available chairside or laboratory based. The E4D Dentist system allows the restorative dentist to have complete control of design and delivery of restorations. The system uses a laser capture to acquire a digital impres-

sively bonded.<sup>10</sup> The pressable lithium disilicate is indicated for inlays, onlays, thin veneers, veneers, partial crowns, three-unit anterior bridges, three-unit premolar bridges, telescope primary crowns and implant restoration while the machinable lithium disilicate is indicated for all the previous applications except bridges.<sup>11–14</sup>

### Summary

Reconstructive treatment usually entails significant correction of malocclusion and the maxillomandibular relationship. Many



Figs. 6, 7. E4D veneer design for teeth #22, #21, #11 and #12. Conservative design achieved, made possible with post-orthodontic idealized occlusion.

Fig. 8. Reflected frontal closeup.

been described in later literature.<sup>6,7</sup> Simmons<sup>8</sup> further describes the alleviation of symptoms after mandibular repositioning. As noted, there was a natural anterior repositioning of the mandible upon removal of the centric interference in this patient, and appliance therapy was unnecessary. Posterior resin build-ups with Class II elastic therapy were sufficient to erupt the posterior teeth to achieve stability of the posterior segment. The condylar position was evaluated by use of progress tomograms and was supported and accompanied with the alleviation of TMJ related symptoms. To address concerns over the color of the teeth, the patient opted to whiten the teeth before the provision of the definitive restorations for the anterior teeth. Upon evaluation of the post-orthodontic occlusion, to provide an occlusion with anterior guidance at protrusion and canine guidance at lateral excursion, it was adequate to pro-

vide information is condensed, aided by computer, to an intuitive format that allows the restorative dentist to modify the design and send the design to a precise automated milling unit that uses robotic technology. The system essentially automates many of the more mechanical and labor intensive procedures, such as waxing, investing, burnout, casting and/or pressing involved in conventional fabrication of dental restorations.<sup>9</sup>

Lithium disilicate (IPS e.max) has the superior flexural strength of 360 MPa to 400 MPa, as compared to the strength of ceramic for PFM crowns, which has the strength of 80 MPa to 100 MPa; veneered zirconia, which has a flexural strength of 100 MPa; and leucite glass, which has the strength of approximately 150 MPa to 160 MPa. Lithium disilicate is a highly esthetic, high-strength material that can be conventionally cemented or adhe-

sively bonded.<sup>10</sup> The pressable lithium disilicate is indicated for inlays, onlays, thin veneers, veneers, partial crowns, three-unit anterior bridges, three-unit premolar bridges, telescope primary crowns and implant restoration while the machinable lithium disilicate is indicated for all the previous applications except bridges.<sup>11–14</sup>

### References

1. Ishigaki S, Bessette RW, Maruyama T. Diagnostic Ability of the Surface Vibration Analysis of Temporomandibular Joint. Abstract. IADR. Seattle, WA, March, 1994.

2. Knutson M, Radke J. Artificial Neural Network Classification of TMJ Internal Derangement. Abstract. J Dent Res 74 (AADR Abstracts) March, 1995.
3. Woodside DG, Metaxas A, Altuna G. The Influence of Functional Appliance Therapy on Glenoid Fossa Remodelling. American Journal of Orthodontics and Dentofacial Orthopedics. 1987 Sep;92(3):181–198.
4. McNamara, Jr. JA, Carlson DS. Quantitative Analysis of Temporomandibular Joint Adaptations to Protrusive Function, AJO, 1979;76: 593–611.
5. Gelb H, Arnold GE. Syndromes of the Head and Neck of Dental Origin. American Medical Association Archives of Otolaryngology, Vol. 70, December 1959; 681–691.
6. Clark WJ. The Twin Block traction technique, European Journal of Orthodontics, 4, 129–138, 1982; and Lund, DI and Sandler, PJ, The effects of Twin Blocks: a prospective controlled study, American Journal of Orthodontics and Dentofacial Orthopaedics, 113, 104–110. 1998.
7. Lund, D. I. and Sandler, P. J. The effects of Twin Blocks: a prospective controlled study, American Journal of Orthodontics and Dentofacial Orthopaedics, 113, 104–110. 1998
8. Simmons HC, 3rd, Gibbs SJ. Anterior repositioning appliance therapy for TMJ disorders: specific symptoms relieved and relationship to disk status on MRI. J Tenn Dent Assoc. 2009 Fall;89(4):22–30
9. Severance G, Swann L. The Take CARE Approach to Treatment Planning, Preparation and Design for CAD/CAM Restorations. Oral Health. March 2009, 47–52.
10. Fabianelli A, Goracci C, Bertelli E, Davidson CL, Ferrari MA. A Clinical Trial of Empress II Porcelain Inlays Luted to Vital Teeth with Dual-Curing Adhesive System and a Self-Curing Resin Cement. Journal of Adhesive Dentistry, 2006 Dec;8(6):427–431.
11. Tysowsky G. The Science Behind Lithium Disilicate: Today's Surprisingly Versatile, Esthetic and Durable Metal Free Alternative, Oral Health. March 2009. 93–97
12. Sorenson JA, Cruz M, Mito WT, Raffener O, Meredith HR, Foser, HP. A Clinical Investigation on Three-Unit Fixed Partial Dentures Fabricated with Lithium Disilicate Glass Ceramic, Pract Periodontics Aesthet Dent. 1999 Jan-Feb;11(1):95–106.
13. Holland W, Schweiger M, Frank M, Rheinberger V. A Comparison of the Microstructure and Properties of the IPS Empress 2 and the IPS Empress Glass Ceramics. Journal of Biomedical Material Research, 2000;53(4):297–303.
14. Kheradmandan S, Koutayas SO, Bernhard M, Strub JR. Fracture Strength of Four Different Types of Anterior Bridges After Thermo-mechanical Fatigue in the Dual-Axis Chewing Stimulator, Journal of Oral Rehabilitation. 2001 Apr;28(4):361–369. DT

## MEDIA CME Self-Instruction Program

Dental Tribune Middle East & Africa in collaboration with CAPP introduce to the market the new project mCME - Self Instruction Program. mCME gives you the opportunity to have a quick and easy way to meet your continuing education needs. mCME offers you the flexibility to work at your own pace through the material from any location at any time. The content is international, drawn from the upper echelon of dental medicine, but also presents a regional outlook in terms of perspective and subject matter.

### How can professionals enroll?

They can either sign up for a one-year (10 exercises) by subscription for the magazine for one year (\$400) or pay (\$30) per issue. After the payment, participants will receive their membership number and will be able to attend to the program.

### How to earn CME credits?

Once the reader attends the distance-learning program, he/she can earn credits in three easy steps: 1. Read the articles. 2. Take the exercises on www.cappmea.com 3. Fill in the Questionnaire and Submit the answers by Fax (+971 4 36868883) or Email info@cappmea.com

After submission of the answers, (name and membership number must be included for processing) they will receive the Certificate with unique ID Number within 48 to 72 hours.

Articles and Questionnaires will be available in the website after the publication. www.cappmea.com

## Contact Information

**Dr. Thomas Colina, DMD**, is a general dentist practicing in Winnipeg, Manitoba, Canada. He graduated from the University of Manitoba Faculty of Dentistry in 1989. His focus on providing comprehensive dental care often entails a multi- and interdisciplinary approach. Colina is a member of the Manitoba Dental Association, Canadian Dental Association, Academy of General Dentistry and the International Association for Orthodontics. He is a senior certified instructor for the International Association for Orthodontics as well as a clinical instructor for the Department of Dental Diagnostic and Surgical Sciences, University of Manitoba Dental Faculty.



1-737 Keewatin St.  
Winnipeg, Manitoba  
Canada R2X 3B9  
tcolina@mts.net

# Introducing the Dental Lab Tribune



By Rodney Abdallah  
CDT, Lebanon

For the first time dentists and dental technicians will be together in one pool of news, business, industry, politics and science in the world leading dental newspaper.

As a Certified Dental Technician, it is my great pleasure to welcome you to the first Dental Lab Tribune edition within Dental Tribune Middle East & Africa.

I am proud to announce the birth of this

highly anticipated section which is part of the Dental Tribune International Publishing Group, composed of the leading dental trade publishers around the world. Its combined portfolio includes more than 100 trade publications that reach over 650,000 dentists in more than 90 countries in 25 languages.

It is highly important to recognize the importance of the Dental Laboratory and its Dental Technicians who play a vital part of any Dental Team. It is the place which mixes science with art, the backbone of any Dental Clinic much needed in providing the perfect smile as end result.

Dental Lab Tribune will be entirely dedicated in providing the latest news, state-of-the-art research & developments, products and education with special focus on

developing further Dental Laboratories and the already skilful Dental Technicians. Working together with world leading Dental Professionals, Dental Tribune Middle East & Africa will be delivering the much needed information to its readers. As part of the Editorial Board, together with my colleagues we intend to keep Dental Lab specialists informed of the latest developments, events and advances in both general and specific Dental Lab topics in an easily accessible format including graphs, tables and figures which will appear in their original articles.

By placing an emphasis on publishing novel and high-quality research papers together with the latest industry developments related to the Dental Lab, the Dental Lab

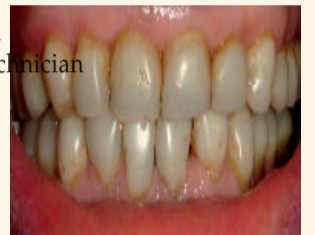Tribune section aims to influence the practice of Dentistry on a Dental Lab, research, industry and policy-maker level on international basis.

Readers will have direct contact with industrial players in a knowledge exchange environment, creating a forum for discussions, questions and exchange of valuable information through our 'feedback session'.

For the above targets, I would like to invite all Dental Lab specialists to interact with Dental Lab Tribune. I look forward to exchanging all related Dental Lab experience with you. **DT**

Yours faithfully,

Rodny .Z. Abdallah  
Certified Dental Technician



## Crowns VS Veneers

All the way to creating esthetic Reconstruction of aesthetic & its functionality in combined (Crowns-Veneers) case.

Dr. Sami Bseso & CDT. Aiham Farah  
Damascus/Syria

**45** year old female presented to the clinic unsatisfied with the appearance of the composite veneers she had on her upper and lower anterior teeth, besides a phonetic problem with the letter S in particular. She desired functional and aesthetic restorations.

### Diagnosis:

Intra Oral clinical exam showed discoloration, lake of vitality, and poor appearance of the composite veneers on the upper and lower anterior teeth and the upper premolars, plus a little deep bite in the centric occlusal jaws relation, what prevented from having proportionate dimensions (width to length).

Radiographic testing revealed good and bad endo-treatment for different teeth with a questionable over all prognoses. Also it appeared to have generalized horizontal bone resorption, which played a major role in the loss of the inter-dental papillae. Fig1

### Preliminary Clinical Treatment:

- Extraction of: 17
- Selective endo-treatment for: 14,15,16,26
- Casted post and core for: 36,37 (cemented with Vivaglass glass ionomer cement).
- Fiber reinforced composite post and core for: 22,26 (posts were cemented using Variolink II and a composite core were built up)

### Restorative Treatment Plan & Implementation

Prior to setting up a plan, the dental technician examined the patient's oral cavity and face carefully at the dentist's office, answered all her questions and developed an idea about her expectations. A collaborated plan by the dentist and technician then was created.

Treatment workflow was initiated by taking preliminary impressions.

### New Vertical Dimension.

Taking into consideration that our priorities were the reconstruction of aesthetics and its functionality, the dental technician proceeded with a diagnostic wax-up in the new planned vertical dimension of occlusion on the upper teeth and 36-37 from the

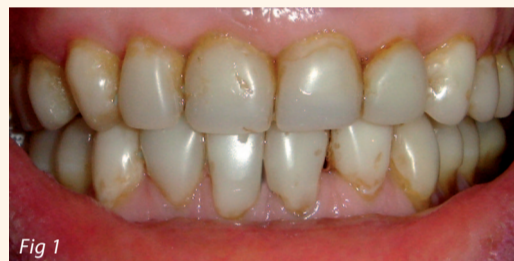

Fig 1: Preoperative situation showing the poor appearance of the composite veneers on the upper and lower anterior teeth.

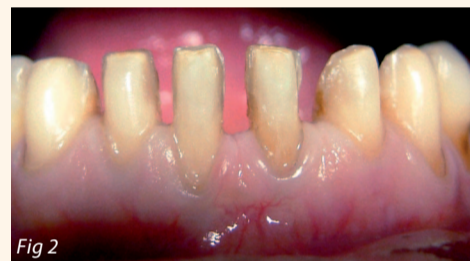

Fig 2: Full crown preparation for uppers, with rounded shoulder.

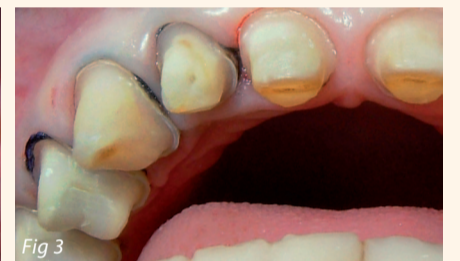

Fig 3: Veneers preparation for lowers, with equigingival chamfer.

lower teeth (the missing vertical dimension was gained by means of waxing up to the new occlusion level).

According to the new vertical dimension, a diagnostic template of silicon (silicon index) was made to the upper and lower teeth to be used as a visual aid, as a preparation guide to the dentist, and as a mold for placement of the temporary restorations in the new vertical dimension of occlusion.

### Determining restorative materials and corresponding preparation forms

To be restored by **All-ceramic crowns from IPS Emax Press**, maxillary and 36,37 teeth

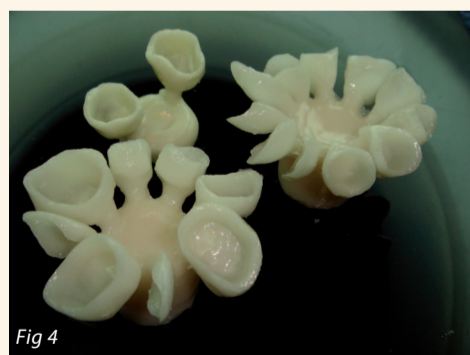

Fig 4: Crowns & veneers (full contour) pressed with (Value 1 ingot) and two coping with (HO1).

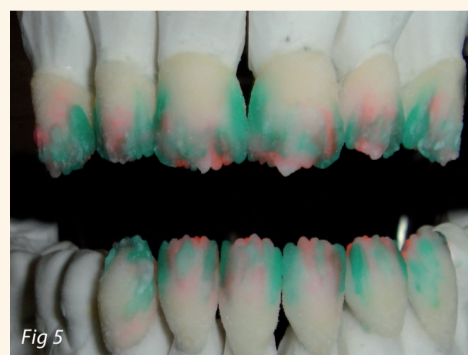

Fig 5: Internal effects layering by Impulse material from IPS e-max Ceram.

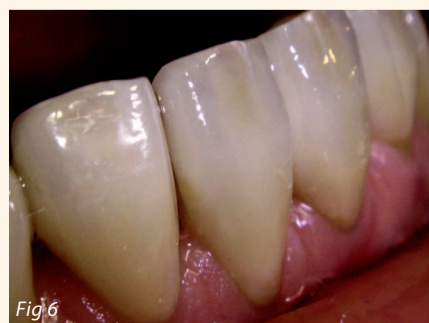

Fig 6: The cemented lower veneers showing how internal effects scheme treat light.

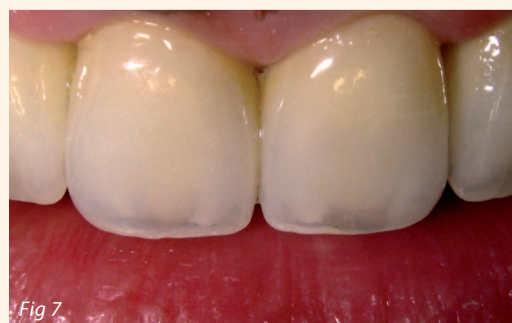

Fig 7: The cemented upper crowns showing the mamelon effect and the neat contouring of the interdental triangle and the healthy papilla.

were prepared with the aid of the silicone index. The prepared finishing lines of the abutments had rounded shoulder. According to esthetic and biological considerations, they were either equigingival or supragingival. Fig 3

To be restored by **All-ceramic veneers from IPS Emax Press**; The Six interior lower teeth were prepared with the aid of a silicone index. The prepared finishing lines of the abutments were chamfer and equigingival. Fig 2

**Final impressions** were taken to the upper and lower teeth with addition silicone (Virtual silicone from Ivoclar Vivadent)

**The shade** of the final restorations was cho-

sen according to the patient desire, her skin color and the shade of the natural (not treated) lower posteriors.

**Direct temporary** restorations were made with the aid of the Index, and no signs or symptoms of discomfort were observed or reported over two weeks.

### LAB WORK:

#### Ingot judgment selection

I chose the new **V1 impulse** ingot from IPS e.max press, because the final shade chosen A1 was a little extra bright, but before taking the final decision, I had to make sure that the prep color was vital with no discoloration spots on its surface (ND1, ND2) and especially in the lower veneers due to the limited coverage capability, as I learned from my experience that the degree of translucency in Value ingots placed between that of the LT and HT ingots and little more toward the HT.

for interiors; I pressed the V1 as a full anatomical structure and proceeded with a cut back technique simultaneously on the entire upper crowns and lower veneers.

for upper posteriors; I pressed the V1 as a cusp supported design copings And proceeded with the layering technique .

except teeth 24-25, and since both abutments used here are metal posts, I pressed HO1 (high opacity), then proceeded with the layering technique. (Fig: 4)

#### The internal effects concept.

**Light absorbing** materials are incorporated into the layering scheme to allow light to penetrate into the tooth more rapidly; these materials are usually applied to the incisal third or to the proximal surface of the tooth.

Besides their light-absorbing properties, teeth have **light-reflecting** properties too.



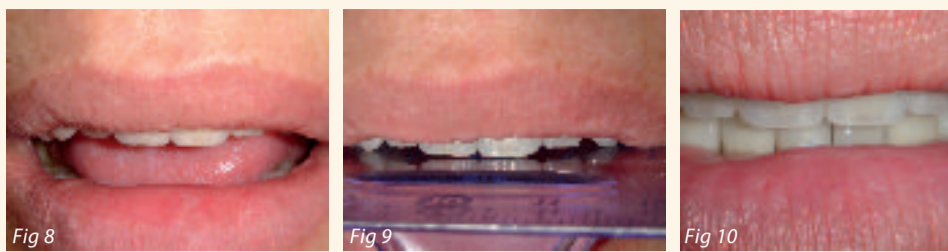


Fig 8,9: The disharmony of the smile line noticed in the try-in photos.  
Fig 10: After fixing the smile line, the natural harmony with the lips.

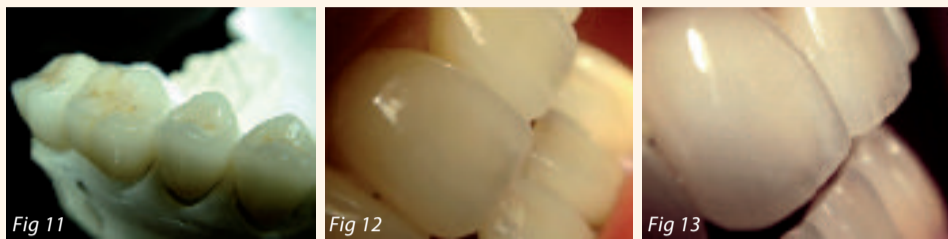

Fig 11: The layered posterior crowns after glaze  
Fig 12,13: Shallow vertical texture on the labial incisal third.

The reflecting materials have to be adequately reflective without being opaque. The light-absorbing materials should not be applied excessively to produce grey and glassy looking results. **We don't want to fabricate teeth that look great on the model but appear gray and glassy in the mouth.**

**Foundation bake.**

1st. Shading the cervical third and bring it closer to A1 by using Shades from IPS Emax Ceram.

2nd. Since my goal is to create teeth that demonstrate the entire spectrum of effects shown by natural dental enamel, I used Impulse material on the incisal third to achieve this spectrum. (Fig 5)

3rd. Sprinkling transpa neutral powder on the whole surface, to cover the parts that are not yet covered by powder materials, lowers the value of the V1 frame, and match it accurately to A1 value wise.

**Second bake;**

I used shaded Cervical Transparent powder on the cervical third in the second bake.

This material demonstrates slightly higher fluorescence than the convenient transparent material, and gives us a smooth transition to the pink gingiva. (Fig 6 , Fig 7 ) show clearly the internal effects on the upper crowns and lower veneers after cementation, the actual look in the mouth and the way they treat light.

**Back to the clinic with try-in**

The patient had a clinical try-in of the final restoration; notes and desires of the dentist and the patient were taken into consideration.

Disharmony was noted in the smile line (misalignment with the eye line) (Fig 8, fig 9, fig 10), an important issue that would have been missed if a clinical try-in was not done. And this is where taking pictures of the patient's lips and face plays a crucial role in the technician work quality, so he would be able to make the appropriate adjustments while observing these photos.

**Third bake;**

Fixing the smile line was the main adjustment needed, so I added incisal edge, created the Halo effect (which is caused, in natural teeth, due to light refraction at the incisal edge), and is usually duplicated by using certain material (IE powder from IPS Ceram Impulse).

Posteriors crowns were built up using the layering technique with IPS Emax Ceram Dentin, Impulse and Incisal. (Fig 11)

**Surface Texture and glaze:**

Ovoid tooth usually is more convex than any other tooth shape, has a rounded outer shape, and curvilinear transition angles with a few lobes. This is why a very narrow and shallow vertical depressions were created on the labial surface of the centrals and laterals giving the interiors their soft esthetic composition. (Fig 12, fig 13)

**Closing the gingival embrasures:**

As you noticed from the preoperative situation, the unhealthy loss of the grayish interdental papillae is a consequence of wrong counterling in the direct composite, where contact areas were elongated toward the tissue, what made the gingival embrasures too close, impinging on the tissue and creating unhealthy periodontal condition. Therefore the tissue receded; and now for the papilla to grow back, the distance between the contact points and the tips of the papilla must be less than 5 mm, which was the main focus of the contouring on a non separated stone model where papillae are still represented there and work can be done relatively (fig 14).

**Cementation and follow up:**

Upper anterior restorations and premolars were finally cement-

ed with variolink-N (Base and catalyst), lower anterior veneers with variolink-N (only Base), and posterior crowns with Vivaglass (glass ionomer) cement. ( fig 15 ) During the follow up appointment, a final check up and modifications were made to eliminate all occasional interferences.

**Conclusion:**

Being able to Choose the same ingot for fabricating every single restoration in this case (whether they were full crowns OR veneers) was a big advantage, it serves in achieving the accurate matching and harmony among all the restorations in the following dimensions (Value, Hue, Chroma, translucency, depth...) as long as the thicknesses were close. **DT**

**Contact Information**



Dr Sami Bissasu Damascus, Syria  
samimbg@hotmail.com  
CDT Aiham Farah Damascus, Syria  
aihamfarah@gmail.com



# HIGH TECHNOLOGY

## Dental Lab.

**Our target:**  
Our target is to connect doctors with the highest and new technology of dental laboratories field

**Our mission:**  
We make more than great art to your patients smile

**Our work:**

- Ceramic work
- Zircon work
- In ceram work
- In ceram support by zirconium 30%
- E-max work
- Implant work
- Acrylic work
- Chrome cobalt work
- orthodontic work
- Aesthetic Smile work

CONTACT US

AL shaqaek Bldg.Next to New Expo Center  
Sharjah to Dubai road sharjah U.A.E

Tel: 009716-5775177 Fax: 009716-5775277 P.O.BOX: 61800.shj  
E-mail: HighTDL@hotmail.com

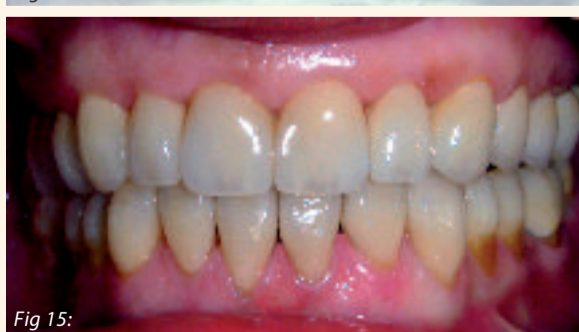
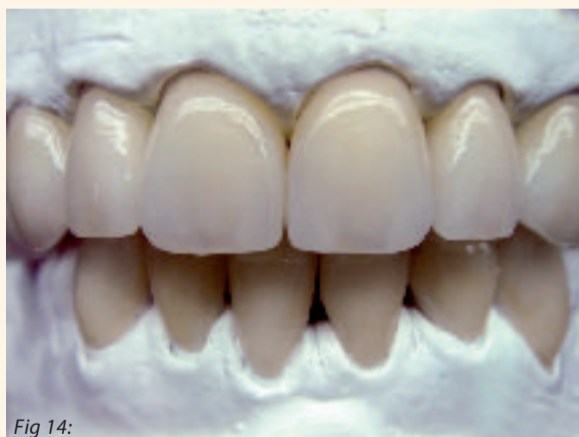
Fig 14: Final work on a non-segmented stone model showing the interdental papillae closure.  
Fig 15: Final intraoral results and the accurate shade matching of the upper crowns and lower veneers.