

cosmetic dentistry _ beauty & science

3²⁰¹²

| **research**

Evolving conservative dentistry

| **patient communication**

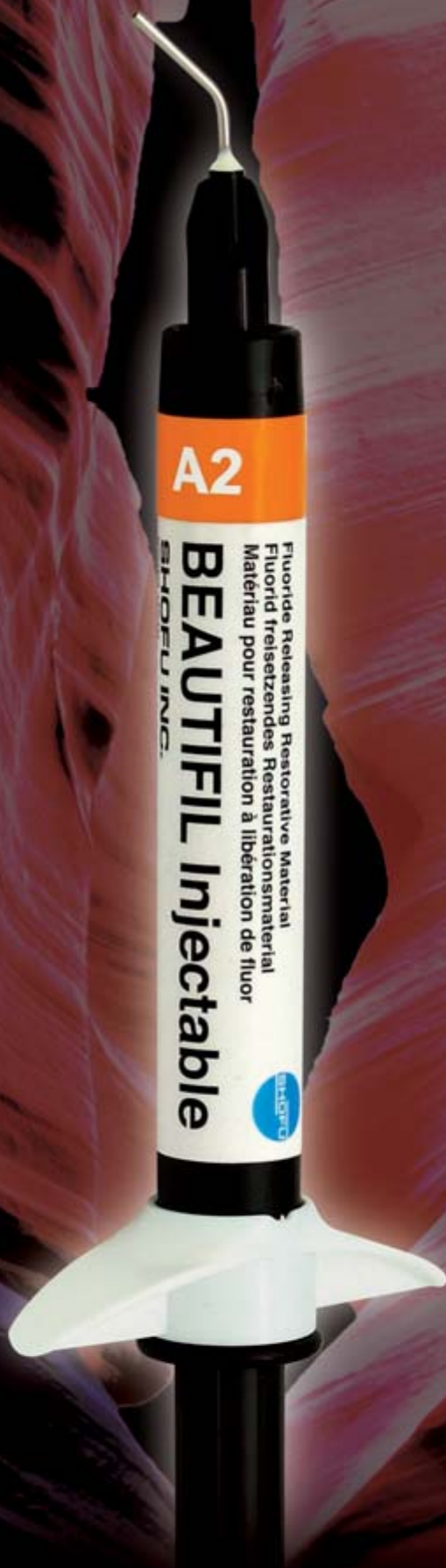Diagnostic mock-up

| **special report**

Aid project in Tanzania

037113

In a **LEAGUE** of its *own ...*



Inject Beauty & Strength as you directly stack and shape Beautifil Injectable into life-like aesthetic restorations that exhibit superior endurance to occlusal load, sustained fluoride protection and unique anti-plaque effect.

SHOFU INC. SINGAPORE BRANCH
Tel (65) 6377 2722 Fax (65) 6377 1121
mailbx@shofu.com.sg website www.shofu.com.sg



Official Partner



Minimally Invasive
Cosmetic Dentistry

Dear Reader,

Do you do force finishing in cosmetic dentistry?

I have been practising clinical dentistry for almost 20 years. Now my major clinical workload is shifting towards the management of complex smile defects due to occlusal disharmony. These cases are always difficult to manage because destructive force components are not visible.

In the performance of cosmetic dentistry, the force components are frequently neglected or misunderstood. Therefore, the physical strength of tooth-coloured restorative materials is still an important topic in cosmetic dentistry. The clinician hopes that the selected restorative materials will overcome potential fracture of the restorations and hence generally selects materials that are much stronger than natural teeth. However, it is necessary to understand that the highly concentrated bite-force locations within the occlusal scheme may not always fracture the restorations, but will create other problems with the teeth, muscles and/or joints in some patients. Therefore, if the clinician overcomes potential fracture through material choice, he or she may actually be ignoring the underlying force factors.

It is interesting to note that, globally, we cosmetic dentists spend more of our clinical time and effort on aesthetic outcome. This is because aesthetic components are always visible to both the clinician and patient, and the outcome can be immediately appreciated. However, the force components are invisible, and their negative effects are not easily appreciated clinically until they become chronic. Another reason that occlusal force can be overlooked is that special tools and clinical techniques are required to demonstrate and measure the force factors clinically. Therefore, force is the most neglected component in cosmetic dentistry.

Last year, I proposed the integration of the concept of force finishing into the conventional case-finishing protocol of dentistry. I am pleased to mention here that the concept has been widely accepted in dentistry. I think it is because the word "finishing" is greatly relevant in dentistry. The concept of force finishing is based on the universal principles of force balance and load timing during dynamic occlusion. Optimally, after proper force finishing, all teeth should come into contact with one another at about the same time and with harmonised occlusal forces and measurably short disclusion timing. When this does not occur, the clinical case is considered to be unbalanced and poorly force finished.

In cosmetic dentistry, forces are finished using articulating paper marks, but scientifically speaking such marks can tell the clinician only about the location of tooth contact and the contact area. In order to achieve quality force finishing, the clinician needs to use the proper tools and technology. The fundamental tool for force finishing is a digital force scanner (T-Scan III, Tekscan) that can measure clinical bite-force data precisely and objectively, while displaying the findings for clinical interpretation and treatment. Such clinical data helps the clinician to achieve tooth-contact forces and timing sequences that are preservational, rather than destructive, regarding the final case result.

It is to be noted that whatever the theory or concept of occlusal scheme selected during the treatment procedure, the role of force finishing is paramount to achieving long-term optimum results in terms of health, function, aesthetics and high patient satisfaction with minimal biological cost.

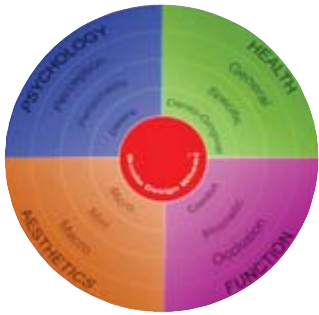Yours faithfully,



Dr Sushil Koirala
Editor-in-Chief
President Vedic Institute of Smile Aesthetics (VISA)
Kathmandu, Nepal



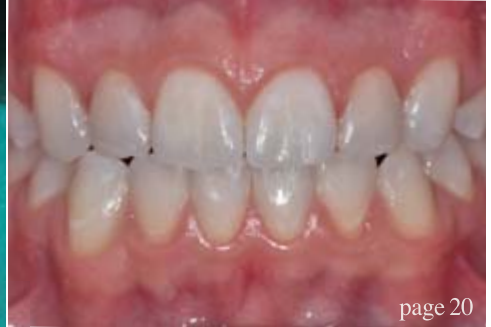Dr Sushil Koirala
Editor-in-Chief



page 6



page 14



page 20

| editorial

03 Dear Reader

| Dr Sushil Koirala, Editor-in-Chief

| special topic

06 MiCD customised case-finishing concept and clinical protocol

| Dr Sushil Koirala

| research

14 Evolving conservative dentistry

| Dr George Freedman

| patient communication

20 Enhancement of aesthetic treatment planning and communication using a diagnostic mock-up

| Drs Laurie St-Pierre & Deborah S. Cobb

| industry report

26 Simple layering technique with direct composite restorations

| Dr Valdas Vilkinis

| opinion

30 Un-cosmetic dentistry

| Dr Michael Zuk

| special report

34 Daktari for Maasai— First dental project at Ololosokwan clinic

| Prof. Martin Jörgens & Dr Caroline Kentsch

| industry news

39 CLEARFIL DC CORE PLUS KIT: Stressless and reliable

| Kuraray

| meetings

40 International Events

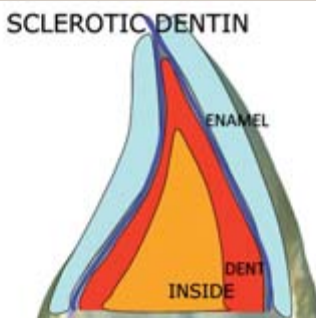
| about the publisher

41 | submission guidelines

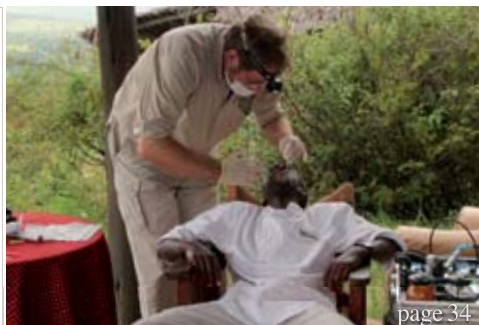42 | imprint



Cover image courtesy of Kuraray Europe GmbH, www.kuraray-dental.eu.



page 26



page 34

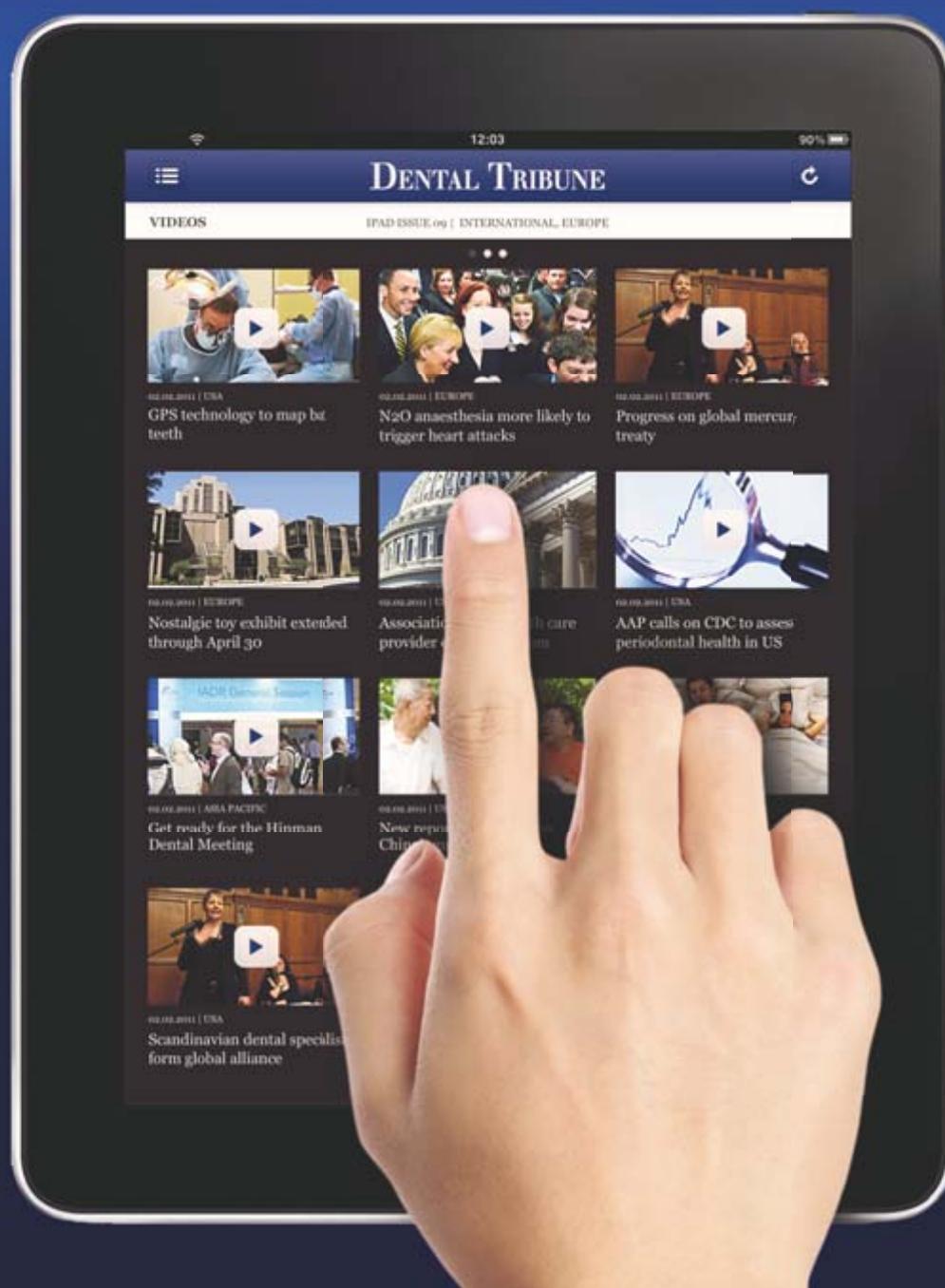

page 40

Dental Tribune for iPad – Your weekly news selection

Our editors select the best articles and videos from around the world for you every week. Create your personal edition in your preferred language.

ipad.dental-tribune.com



DENTAL TRIBUNE

— The World's Dental Newspaper —

MiCD customised case-finishing concept and clinical protocol

Author_Dr Sushil Koirala, Nepal

The sooner the better: Follow early diagnosis and intervention approach.

Smile Design Wheel approach: Understand psychology, establish health, restore function and enhance aesthetics (PHFA sequences of the Smile Design Wheel—Fig. 2).

Do no harm: Minimise the possible biological cost.

Evidence-based selection: Select materials, tools, techniques and protocols based on scientific evidence.

Keep in touch: Encourage regular follow-up and maintenance.

Fig. 1

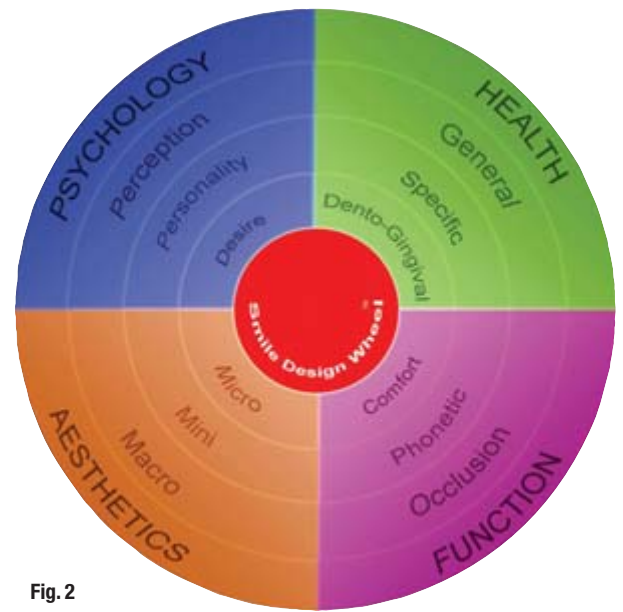


Fig. 2

Fig. 1_MiCD core principles.¹

_Abstract

Fig. 2_Smile Design Wheel.

Case finishing is one of the important clinical steps in dentistry. Aesthetics, functional forces and oral health are the three fundamental components that need to be considered during case finishing. Aesthetic components are clinically visible and guided by the subjective analysis (perception) of the patient and the clinician. However, the force components are invisible,

and their adverse effects are not easily appreciated clinically until the effects become chronic. Moreover, the force components require special tools and clinical techniques to demonstrate

- I. Molar relationship: The distal surface of the distobuccal cusp of the maxillary first molar occludes with the mesial surface of the mesiobuccal cusp of the mandibular second molar.
- II. Crown angulation (mesiodistal tip): The gingival portion of each crown is distal to the incisal portion and varies with each tooth type.
- III. Crown inclination (labiolingual, buccolingual):
 - _Anterior teeth (incisors) are at a sufficient angulation to prevent overeruption.
 - _Maxillary posterior teeth: The lingual tip is constant and similar from the canine to second premolar and increased in the molars.
 - _Mandibular posterior teeth: The lingual tip increases progressively from the canines to the molar.
- IV. No rotations.
- V. No spaces.
- VI. Flat occlusal planes.

Fig. 3

Fig. 3_Andrews' six keys to occlusion.²

and measure them clinically. Therefore, the force is the most neglected component in cosmetic dentistry during case finishing.

When the force components are not addressed properly during the treatment, clinicians may encounter various clinical problems, such as damaged restorations (veneers, onlays, crowns and bridges); fractured teeth; tooth mobility; abnormal tooth wear and sensitivity; pain in the teeth, muscles and jaw joints; and increased neck pain, ear pain and headache.

In cosmetic dentistry, forces are finished based on articulating paper mark interpretation and the patient's proprioception feedback. It has been documented in the literature that articulating paper is a poor indicator of occlusal disharmony and cannot measure occlusal load and the timing of tooth contacts. The proper tools and techniques can measure precisely and objectively the necessary occlusal parameters required for finishing the force components in cosmetic dentistry.

Minimally invasive cosmetic dentistry customised case finishing integrates the concept of force finishing into the conventional case-finishing protocol of dentistry, in the hope that it will help practitioners to achieve long-term optimum results in terms of health, function and aesthetics, and high patient satisfaction with minimal biological cost.

_Introduction

The treatment modalities and protocol of health care should be aimed at the establishment of health and the preservation of the human body with its natural function and aesthetics. The comprehensive concept of minimally invasive cosmetic dentistry (MiCD) and its treatment protocol were introduced in 2009 with the basic aim of a clinician effecting optimum clinical therapeutic improvements in smile enhancement, while performing corrective procedures that require as little clinical intervention as possible.¹

The intervention level of the treatment in MiCD depends on the type of smile defects and the aesthetic needs of the patient.¹ The five core principles (Fig. 1) of the MiCD concept help to guide the clinician in achieving the desired smile enhancement with minimal clinical intervention. However, the core principles must be adapted from case selection to the final case-finishing stages. Proper case finishing is not possible without understanding its two com-

1. Centric relation theory (Schuyler):⁸ The occlusion is determined by the manner in which the ligaments brace the components of the jaw joint, particularly the rearmost hinge axis. There are various clinical techniques proposed to record centric relation (CR). The bimanual manipulation technique of Dawson,⁹ the Lucia jig and the leaf-gauge technique, as reported by Long,¹⁰ are popular techniques for positioning the mandible in CR. Prior to this, chin-point guidance and swallowing techniques were used to locate and record CR.

2. Neuromuscular theory (Jankelson):¹¹ The occlusion is determined by gravity and based on the position in which the jaw muscles are most relaxed. Trans Electric Nerve Stimulation (TENS) is employed to relax the muscles.

3. Intercuspal theory: The occlusion is determined by the habitual fit with the most tooth contact.

4. Anterior protrusive position theory (Gelb 4/7 position):¹² The occlusion is determined by the manner in which the muscles brace the components of the jaw joint. The Gelb 4/7 jaw position is found by using appliances to open the occlusion and reposition the mandible forwards and downwards of the true centre of the glenoid fossa.

Fig. 4

ponents, namely the micro-aesthetics and the occlusal forces.

It is, however, the force component that is often neglected, or improperly considered, in cosmetic dentistry. This article describes an MiCD customised case-finishing (MCCF) concept and protocol that respect both force and aesthetic components.

_MiCD customised case-finishing concept

Case finishing is one of the most important steps in any clinical treatment in dentistry. It has three major components that need to be considered: aesthetics, overall health and occlusal function. It is interesting to note that case finishing is viewed differently in different disciplines of dental medicine. In orthodontics,

Fig. 5_Mechanism of occlusion-force alteration.¹⁵

Clinicians can affect the occlusal forces by altering the following five areas during occlusal scheme preparation:¹⁵

1. Intercuspal position (ICP) contacts: Restorative dentists can control which teeth come into contact and the number of tooth contacts during closure in the ICP.

2. Excursive contacts: By altering the number and type of tooth contacts in eccentric excursions, restorative dentists have the ability to change muscular contraction and the distribution of forces.

3. Angle of tooth contacts: It is well known that the depth of the overbite or steepness of the angle of guidance of the teeth will have an impact on the manner in which forces are distributed.^{37,38} The angle of impact will affect not only the distribution of the force but also the ability of the muscle to contract.

4. Condylar position: The condylar position chosen will have a dramatic impact on the ability to control which teeth contact each other and when they contact.

5. Vertical dimension of occlusion: The vertical dimension of occlusion can be opened or closed when restoring at least one arch. Decreased vertical dimension increases the occlusal forces.

Fig. 5

case finishing fundamentally focuses on six keys to occlusion (Fig. 3) described by Andrews,² whereas in cosmetic dentistry, it is considered the last step of the clinical procedure and entails

Fig. 6 Force-finishing clinical facts.

1. Unilateral tooth contacts increase force in the opposite joint.
2. Bilateral even tooth contacts during ICP give more stability to the teeth, muscles and joints.
3. When the number of occluding teeth increases, the total percentage of forces to each tooth decreases.
4. The vertical forces created by tooth contacts are well accepted by the periodontal ligament, but horizontal forces cannot be effectively dissipated.³⁹ These forces may create pathological bone responses or elicit neuromuscular reflex activity in an attempt to avoid or guard against the incline plane contacts.⁴⁰ Hence, directing the occlusal force through the long axis of the tooth (axial loading) should be a goal of force finishing in the posterior teeth. Axial loading can be accomplished by cusp tip to flat surface contacts or by creating reciprocal incline contacts (also known as tripodisation).
5. The amount of the force that can be generated between teeth depends on the distance of the teeth from the temporomandibular joint, combined with applied muscular force vectors (fulcrum principle). Greater force can be applied to the posterior teeth than to the anterior teeth.⁴¹⁻⁴³ The posterior teeth function effectively when accepting the axial forces (axial loading) applied during closure of the mouth. They accept these forces well, primarily owing to their position in the arches because the force can be directed through the long axes and thus dissipated effectively.¹⁶
6. The anterior teeth are not positioned well in the arches to accept heavy axial force. They are normally positioned at a labial angle to the direction of closure, so loading them axially is nearly impossible.⁴⁴
7. The anterior teeth, unlike the posterior teeth, are in proper position to accept horizontal forces of eccentric mandibular movements.^{43,45,46}
8. The anterior teeth should immediately disclude the posterior teeth during excursive movements,^{13,14,16} resulting in friction-free excursive movements that limit wear on teeth and activate low levels of excursive muscle function.⁴⁷
9. The canines are best suited to accepting the horizontal forces that occur during eccentric movements.^{40,45,48} This is because:
 - a) They have the longest and the largest roots and therefore the best crown/root ratio.^{44,49}
 - b) They are surrounded by dense compact bone, which tolerates the forces better than the medullary bone found around the posterior teeth.⁵⁰
 - c) The canines are centred on sensory input and the resultant effect on the muscles of mastication. Apparently, fewer muscles are active when the canines contact during eccentric movements than when posterior teeth contact.^{51,52}
 - d) Lower levels of muscular activity would decrease forces to the dental and joint structures, minimising pathosis. It is therefore suggested that during force finishing of left or right laterotrusive excursive movements, canine guidance is the preferred excursive control in order to best dissipate any damaging horizontal forces. When canine guidance cannot be achieved during case finishing, the most favourable alternative to canine guidance is group function. The most desirable group function consists of the canines, premolars and sometimes the mesiobuccal cusp of the first molar. Any laterotrusive contacts other than the mesial portion of the first molar are not desirable because of the increased amount of muscle force that can be created as the contact nears the fulcrum (temporomandibular joint).¹⁶

Fig. 6

refining the micro-aesthetic components of the smile. Cosmetic dentists spend their clinical time and effort rather on the aesthetics of the final result. This is because, aesthetic components are visible to both the clinician and patient, and the outcome can thus be appreciated immediately.

However, the force components are invisible, and their negative effects are not easily appreciated clinically until the effects become chronic. Another reason that force finishing may be overlooked is that it requires special tools and clinical techniques to demonstrate and measure the force factors clinically. Therefore, force is the most neglected component in cosmetic dentistry during case finishing.

In cosmetic dentistry, forces are finished based on articulating paper mark interpretation and the patient's proprioception feedback. It has been documented in the literature that articulating paper is a poor indicator of occlusal disharmony,³⁻⁵ and studies have shown that mark size varies with the same applied load, with differing thickness of paper, surface texture of tooth and restorations, and that mark interpretation is an operator-based subjective procedure. Moreover, paper cannot measure the timing of occlusal forces.³⁻⁶

A proper case-finishing protocol must be based on both subjective and objective analysis. In order to measure the occlusal load and timing of occlusal forces, it is necessary to use proper tools, which can measure precisely and objectively the necessary occlusal parameters required in cosmetic case finishing. Computerised instrumentation to analyse occlusal forces was introduced by Tekscan Inc in 1984 as T-Scan I.⁷ Over the past 27 years, it has evolved to become a very precise diagnostic and treatment tool that is used to manage the force components in any conventional case-finishing approach to dentistry.

Every clinical case is different, as it is related to the patient's state of health, his or her functional requirements, and his or her aesthetic needs and desires. Function is directly related to the forces that a patient generates within his or her stomatognathic system. There are four different theories of occlusion. Each of these theories has their value, and treatments that are founded on each have been successful. These theories of occlusion differ in their consideration of the positioning of the jaw or temporomandibular joint during treatment, which are known as jaw-position theories (Fig. 4).

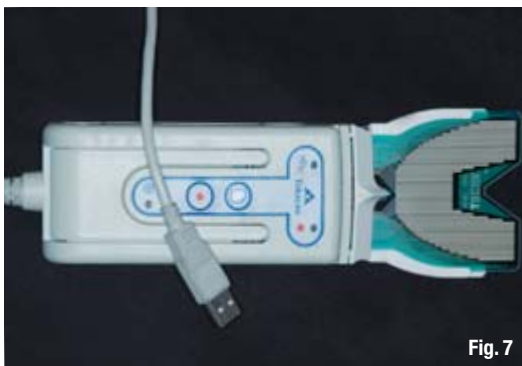

Fig. 7




Fig. 8

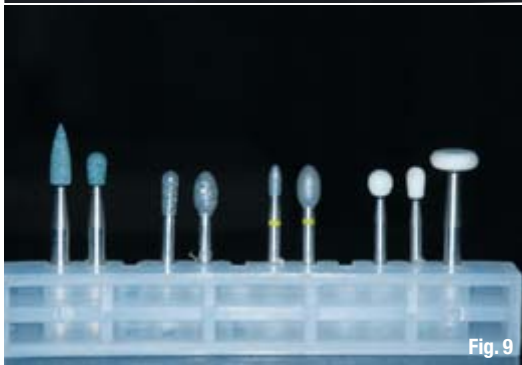


Fig. 9

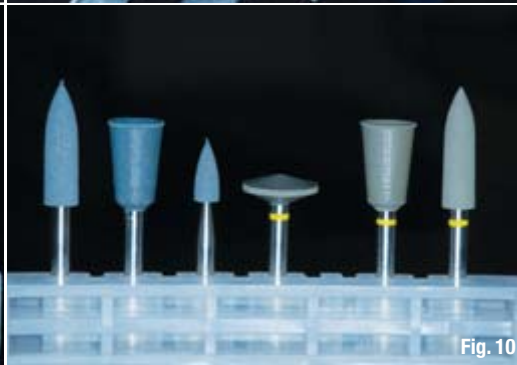


Fig. 10

Fig. 7 T-Scan III: Digital occlusal analysis tool used to measure occlusal force percentage and tooth-contact timing.

Fig. 8 Articulating paper with holder, a necessary item for locating the tooth-contact point and surface area during force finishing.

Fig. 9 Dura-Green stones, Diamond points and Dura-White stones (all Shofu) can be used to contour the pressure spots selectively during force finishing.

Fig. 10 Diamond-impregnated silicone points to finish and polish the contoured tooth and restoration surfaces.

However, all of these theories agree on the following issues:

1. Teeth during mandibular closure: All teeth should occlude simultaneously in mandibular closure movement.¹³⁻¹⁶
2. Occlusal load distribution on arch: An equal percentage of occlusal force should be shared between the right and left arch halves.
3. Occlusal load on tooth: An equal percentage of occlusal force should be distributed on each tooth counterpart.
4. Excursive contacts: The anterior teeth should immediately disclude the posterior teeth during excursive movements.¹³⁻¹⁶

Based on the laterotrusive movements from centric occlusion, various concepts of functional

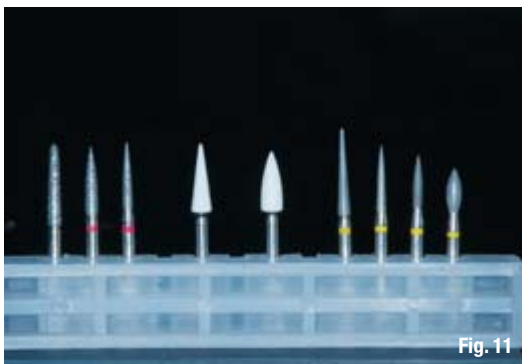


Fig. 11

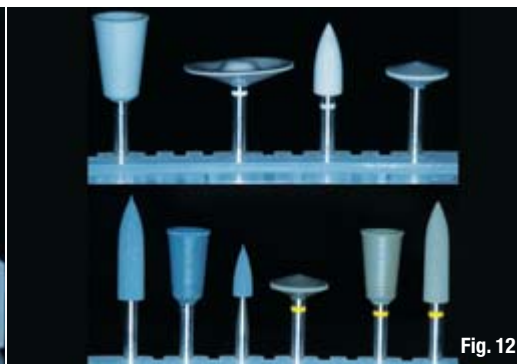

Fig. 12

Fig. 11 Diamond points and Dura-White stones to contour and texture the tooth and restoration surfaces.

Fig. 12 Diamond-impregnated silicone points to finish and polish the contoured tooth and restoration surfaces.



Fig. 13

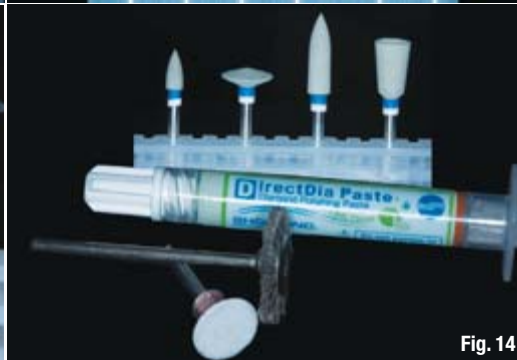

Fig. 14

Fig. 13 Super Snap disk and strips (Shofu): For labial and interdental surface finishing and polishing.

Fig. 14 Diamond paste, diamond-impregnated silicone points and a Robinson brush are used to achieve super polishing or enamel-like lustre of the restoration and tooth surfaces.