

implants

international magazine of oral implantology

4²⁰¹²



| **research**

Cost effectiveness in implant dentistry

| **case report**

Implant-prosthetic rehabilitation of the severely atrophic maxilla

| **industry report**

The early abutment technique

dentistry

CONFIDENCE IN LIMITED SPACE

STRAUMANN® NARROW NECK CrossFit®

The Straumann Soft Tissue Level solution to address space limitations

- Confidence when placing small diameter implants
- Wide range of treatment options
- Simplicity in daily use



reddot design award
winner 2012



More information on www.straumann.com

COMMITTED TO
SIMPLY DOING MORE
FOR DENTAL PROFESSIONALS

Dear Colleagues,



Dr Rainer Valentin

_With the successful 42nd DGZI annual congress already lying in the past, we can surely say that we were offered an ambitious programme and renowned national and international speakers, as well as a nearly perfect organisation by Oemus Media AG. Titled "Quality-oriented implantation—ways to long-term success", the congress impressively demonstrated the scope of modern dentistry in general and implantology in particular, but it also and more importantly showed their limits.

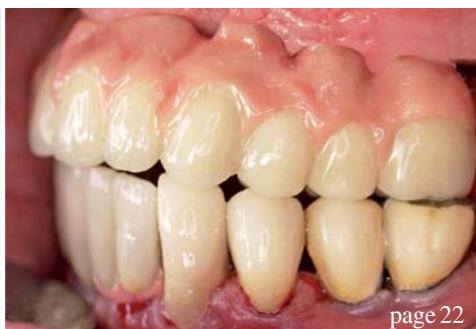Resulting from the constant increase in implants placed, implantology has grown from a budding specialty to the driving force of dentistry. Of course, the number of complications and failures was bound to increase along with the growing practical relevance of implantology. Avoiding biological, technical and aesthetic complications while ensuring long-term success have become the primary aim in implantology. Therefore, self-reflection and the reflection of individual therapy approaches have become more important.

Whether you do this by visiting congresses, in discussions with colleagues, by participating in study groups or via education and special training in curricula is entirely your choice. Since, however, more and more beginners have decided for our curricula in the past, we decided to re-design them. Because of the variations with regard to their personal experience in oral implantology, participants can now place their educational focus individually by combining five compulsory and three freely selectable modules.

With this in mind, I wish you the best of luck and pleasant work. Enjoy reading this year's final issue of implants!

Yours,

Dr Rainer Valentin



| editorial

- 03 Dear **Colleagues**
| Dr Rainer Valentin

| research

- 06 **Implant design** and the maintenance of
peri-implant tissue
| Prof Sergio Alexandre Gehrke
- 12 **Cost effectiveness** in **implant** dentistry
| Dr Mauro Labanca

| overview

- 18 **Perio** meets **implant** dentistry
| Prof Dr Rainer Buchmann

| case report

- 22 **Implant-prosthetic rehabilitation** of the
severely atrophic maxilla
| Prof Dr Gregory-George Zafiropoulos *et al.*
- 28 **CAD/CAM patient-specific abutments** and
a new implant design
| Prof Dr Frank Liebaug *et al.*

| industry report

- 34 The **early abutment** technique
| Dr S. Marcus Beschnidt

| news

- 38 **Manufacturer** News
- 48 **News**

| education

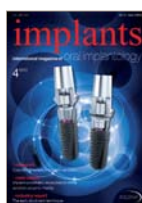- 40 42nd international **annual congress:**
DGZI stays on target
| Dr Georg Bach
- 44 Practical Training at **Osteology in Monaco**

| events


- 46 On the trail of **implant innovation** at **IDS 2013**

| about the publisher

- 50 | imprint



Cover image courtesy of CAMLOG Biotechnologies,
www.camlog.de
Original Background: ©Mike McDonald
Artwork by Sarah Fuhrmann, OEMUS MEDIA AG.

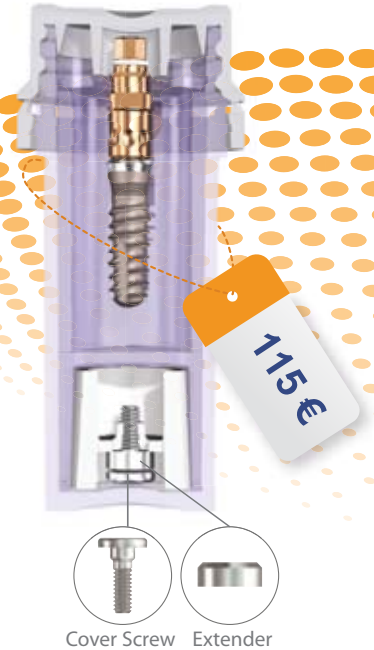


SwishPlus™

Compatible with Straumann®



All-in-One Packaging



Cover Screw Extender

SwishPlus™ Implant

All in One Packaging includes implant, compatible carrier, cover screw & healing collar for only 115 Euro

SwishPlus™

Straight with Micro-Grooves & Straumann Threads

Swish™ Implant System Advantages:


Internal Octagon (Niznick US Pat. #4,960,381 Licensed to Straumann)

Prosthetic compatibility with Straumann's Tissue-Level implants (Standard, Standard Plus and Tapered Effect)

Internal square broached in flats of octagon for fixture-mount engagement (Pat. Pend.)

SwishPlus™ : €115 includes cover screw, healing collar & carrier compatible with Straumann tool & standard ratchet

- 1 2mm neck half textured for tissue-level or esthetic placement
- 2 Micro-grooves for improved tissue attachment & reduced stress
- 3 Progressively-deeper single-lead threads for increased surface area & complete surgical compatibility
- 4 Self-tapping groove for increased initial stability
- 5 Tapered apical end to initiate self-tapping



Implant design and the maintenance of peri-implant tissue

Author_Prof Sergio Alexandre Gehrke, Brazil



Fig. 1

_Introduction

The number of patients whose teeth are replaced with implants in aesthetic areas has increased greatly. Proportionately, so have the requirements regarding the outcome of treatment. Unlike the early years of implant osseointegration, many are placed in the anterior maxilla and other aesthetically visible regions. Consequently, several studies have been published about implant treatment and its results in aesthetic regions (Belser et al. 2003).

tance (Novaes et al. 2006), periodontal disease (Kozlovsky et al. 2007), occlusal overload (Mangano et al. 2010), a gap in the implant-abutment interface (King et al. 2002), the quality of peri-implant soft tissue (Kim et al. 2009), the relation between crown and implant (Blanes et al. 2007), and the location of the implant-abutment junction (IAJ; Hermann et al. 1997). The integrity of the bone-implant interface results from local microbiological control (Mangano et al. 2010) and a continuous process of bone remodelling replacing fatigued bone.

The IAJ can be located in various positions with respect to the alveolar bone crest (supra-crestal, crestal or sub-crestal; Fig. 1). This location is of great importance for aesthetic restoration. Positioning the IAJ in the most apical position can create an emergence profile best suited for prosthetic reconstruction (Buser & Von Arx 2000).

The Morse taper connection implant has been extensively studied for its benefits with respect to peri-implant tissue biology (Weigl 2004). Among the main benefits are decreased bacterial colonisation in the implant-abutment interface and the reduction of micro-movement of placed implants. These factors are

Fig. 1_Position of the implant in relation to the alveolar bone crest (supra-crestal, crestal or sub-crestal).

Fig. 2_Initial radiographic (a) and clinical (b) findings.

Figs. 3a-c_Image after the alveolar extraction (a), an illustration of an ideal position (b), and the prepared site from a more palatal direction (c).

Peri-implant bone loss causes retraction of soft tissue and makes aesthetic reconstruction a rather complicated task. Several factors are cited as possible causes of peri-implant bone loss, such as inter-implant dis-

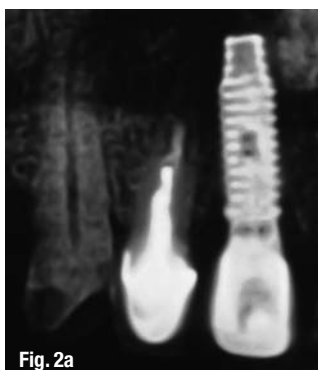

Fig. 2a

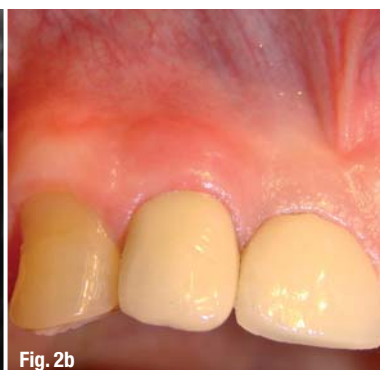

Fig. 2b

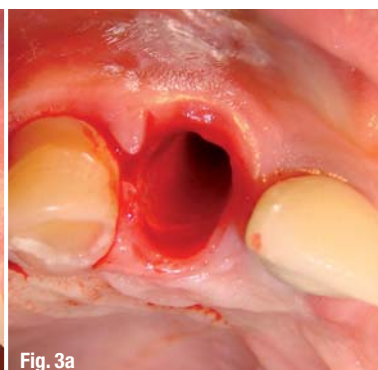


Fig. 3a

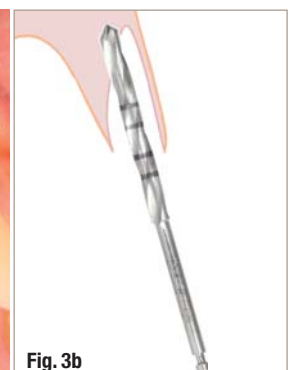

Fig. 3b



PERFECT FIT BY DESIGN

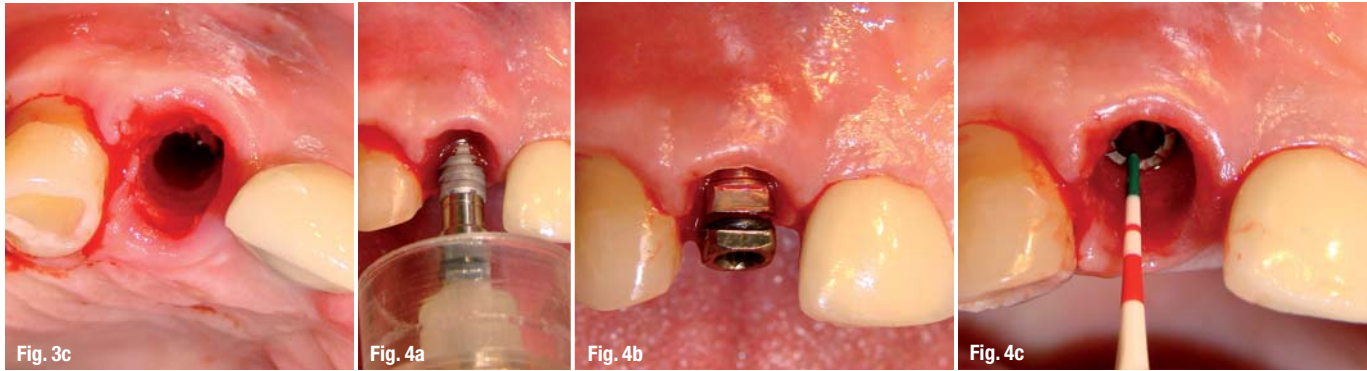
In combining Soft Tissue and Bone Level implants with a comprehensive prosthetic portfolio, Straumann has devised one system for all indications. The **Straumann® Dental Implant System** – excellent product quality designed for convincing, naturally esthetic outcomes.



Featuring the
SLActive® surface!

More information on www.straumann.com

COMMITTED TO
SIMPLY DOING MORE
FOR DENTAL PROFESSIONALS



Figs. 4a–c Image of implant being placed in the implant bed (a), its final position (b), and the probe marking about 2 mm below the level of the central alveolar bone crest of the tooth (c).

essential for the prevention of peri-implant cervical bone loss (Cochran et al. 2009; Mangano et al. 2009; Schwarz et al. 2008) because these micro-movements between the implant and the abutment could lead to the formation of a micro-gap (Rack et al. 2010), resulting in internal contamination of the implant (Jansen et al. 1997; Steinebrunner et al. 2005).

This case report is aimed at demonstrating the advantages of the design of the Morse taper implant (Implacil De Bortoli) for maintenance of the anatomy of the peri-implant tissue.

Case presentation

A 53-year-old male patient requested treatment of a coronal fracture of the right maxillary lateral incisor, which had been endodontically treated with a metal-ceramic crown with a metal core (Fig. 2). During surgical planning, factors essential to treatment success were observed, among which was the maintenance of the proximal bone crest, which is essential in determining the prognosis of the interproximal papilla of the implants (Rack et al. 2010) and future difficulties rising from the adjacent tooth, the central incisor, which was a prosthesis supported by an implant.

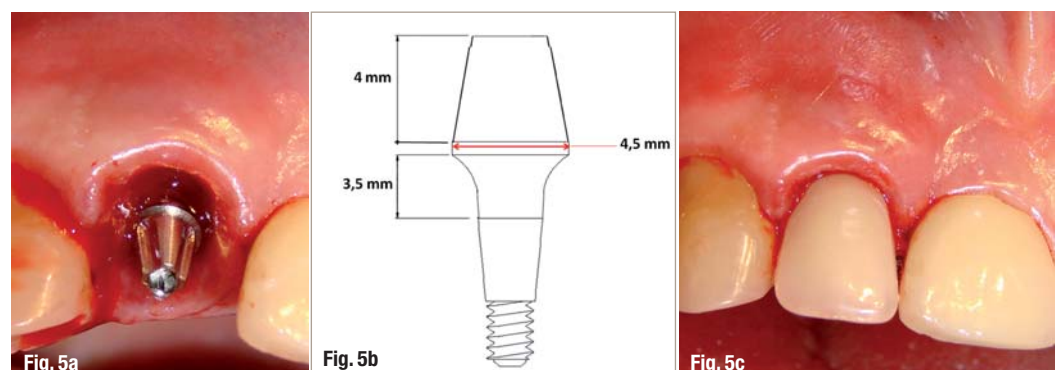
During drilling, it was observed that the pocket depth was less than 4 mm, since the fracture was fresh. After evaluating the patient's need for immediate aesthetics and his general condition, we chose to extract the remaining root and immediate placement of the implant

and of the provisional. After anaesthesia, appropriate syndesmotomy was performed without displacement of the incision or tissue, in order not to disrupt the gingival line and to keep the papilla in position in seeking to prevent bone loss. This was achieved by performing an atraumatic extraction of the tooth (Fig. 3a).

An osteotomy was then performed in order to ensure the ideal position of the implant with regard to the future position of the prosthesis (Fig. 3b). The surgical sequence of the perforations followed the standard protocol specified for the placement of tapered implants, paying attention to the mesiodistal and buccolingual positioning of the implant, which should be around 1 to 2 mm for the buccal palate in relation to neighbouring teeth. The osteotomy started with super sharp drill launches in the predetermined position towards the palatal wall of the socket, preserving the labial plate. Subsequently, we used a 2 mm drill to the planned depth with a direction indicator to verify the need for adjustments in the orientation of the implant. This was followed by conical drills of 3.5 mm and 4 mm (Fig. 3c). The selected implant was a tapered Morse cone implant of 4 mm in diameter and 13 mm in length (Implacil De Bortoli).

The implant was placed in the implant bed (Fig. 4a) manually using with a torque meter (Fig. 4b), positioning the implant approximately 2 mm below the level of the central bone crest of the alveolar bone (Fig. 4c). The crash was performed at a torque of 50 N cm. An abutment (3.5 x 4.5 x 4 mm) was immediately placed (Fig. 5a).

Figs. 5a–c The positioned abutment (a), diagram showing the dimensions of the measured values (b), and the seated provisional (c).



Nobel Biocare Global Symposium 2013 – New York

JUNE 20–23, WALDORF ASTORIA NEW YORK

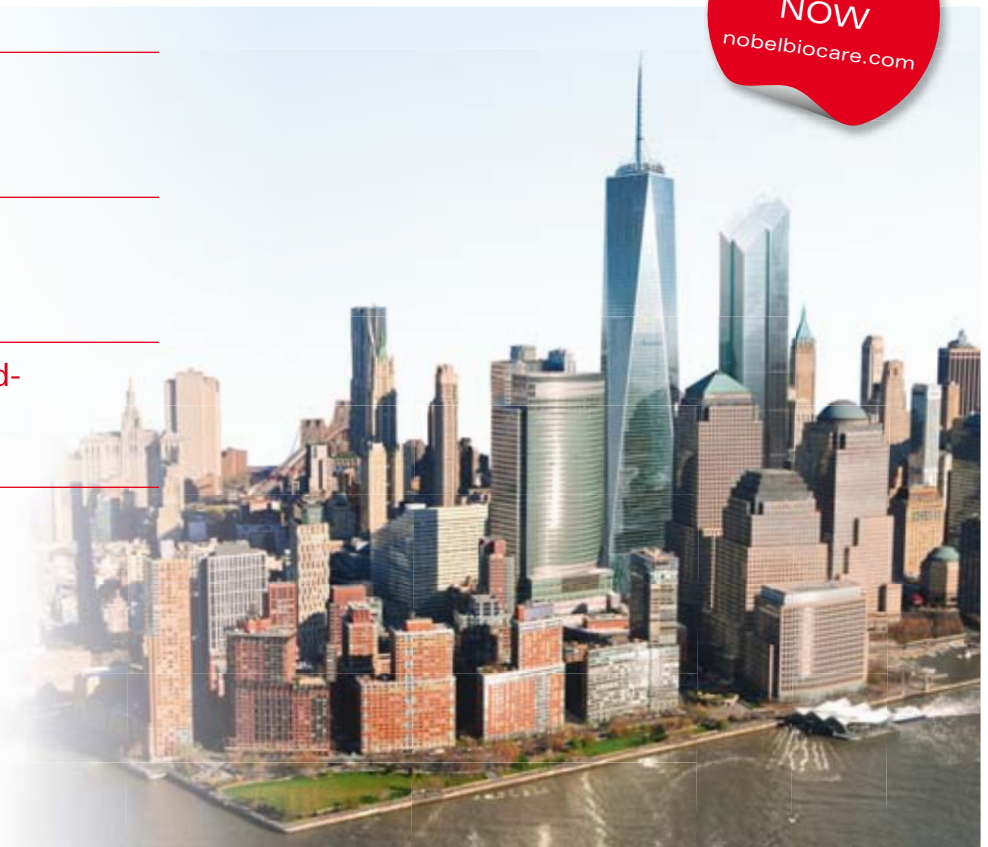

Gain insight how to treat
more patients better

Experience the best in
implant dentistry

Learn from over 100 world-
renowned leaders

Enjoy the fascinating
city of New York



Designing for Life: Today and in the future. Join the leading experts in implant dentistry at the event not to be missed in 2013. This exciting four-day Nobel Biocare Global Symposium 2013 in New York is your number one opportunity to gain the full 360-degree perspective on how you can treat more patients better. Benefit from an innovative and insightful program format designed to maximize your learning experience. Update yourself on the key factors for successful oral rehabilitation such as diagnostics

and treatment planning, surgical and restorative treatments and patient follow-up. Understand how to effectively restore missing single teeth, multiple teeth and edentulous jaws. Learn more about important clinical themes such as minimally invasive, graftless solutions, immediate replacement and function, soft tissue health and esthetics. Find out how you can utilize this knowledge to achieve even better results. **Register now!**



nobelbiocare.com/newyork2013

