

# DENTAL TRIBUNE

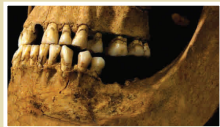The World's Dental Newspaper • Pakistan Edition

PUBLISHED IN PAKISTAN

www.dental-tribune.com.pk

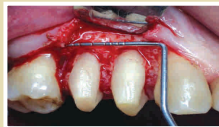
SEPTEMBER, 2014 - No. 05 Vol.1

Teeth reveal details of Richard III's lifestyle



► Page 2

Er:YAG Garnet in laser-assisted crown lengthening



CLINICAL PRACTICE

► Page 4

3rd International conference of Pakistan Prosthodontics Association



EVENTS

► Page 8

## PPA holds 3rd international conference Emerging Trends in Prosthodontics



### DT Pakistan Report

**I**SLAMABAD: The 3rd international conference of Pakistan Prosthodontics Association was held at the Jinnah Auditorium of National University of Sciences and Technology (NUST) Islamabad.

The theme conference of the conference was "Emerging Trends in Prosthodontics." This mega event of the Pakistan Prosthodontics Association (PPA) was attended by over 600 participants including senior and junior level prosthodontists of the country

in addition to prosthodontic faculty of different colleges, residents, house surgeons and undergraduate students.

The main attraction of this conference was its rich scientific program. International speakers from various parts of the world attended the event as guest speakers.

Prof. Dr. Atilla Sertgoz PhD and currently working in the Department of Prosthodontics at Marmara  
*Continued to page 08*

## Improper hospital waste disposal



### DT Pakistan Report

**K**ARACHI: Serious health hazards are being posed by improper medical waste disposal, causing an increase in communicable diseases.

A Senior Administrative officer of Civil Hospital Karachi (CHK), on condition of anonymity, said that incinerator of hospital was out of order and that the improper waste disposal was putting lives of millions at risk.

The hospital waste which requires proper handling includes materials like disposable syringes, drips, urine or blood bags, human body parts, needles fluid and others. Internationally several protocols have been developed to ensure safe disposal of such  
*Continued to page 11*

## PMDC can perform its regulatory functions: Registrar



### DT Pakistan Report

**I**SLAMABAD: The Pakistan Medical and Dental Council (PMDC) said no court of the law in the country had stopped it from regulating medical and

been communicated to the ministry from time to time for information.

dental education and practice.

"There have been no restraining orders from any court on performing its regulatory functions," PMDC Registrar Dr Raja Amjad Mehmood told reporters here.

The registrar said the PMDC had written a letter to the Ministry of NHRSC responding to its objection to the holding of council meetings. He said the PMDC Executive Committee was restored automatically on July 17 after the term of the PMDC Ordinance 2014 ended 120 days after its promulgation. Dr. Raja Amjad said the minutes of the PMDC Executive Committee and Council had

*Continued to page 11*

## Pharma companies stock recover from turbulence amid protests



### DT Pakistan Report

**K**ARACHI: Listed Pharma companies in Pakistan have been witnessing a turbulent time at the trading floor.

*Continued to page 11*



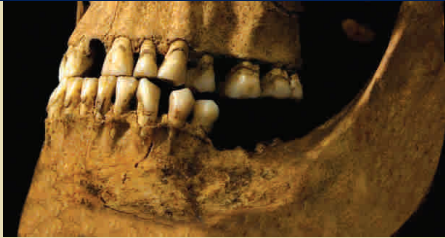# Teeth reveal details of Richard III's lifestyle

DT International Report

LEICESTER, UK: Isotope analysis of bone and tooth material from King Richard III has revealed previously unknown details of his early life and the change in his diet when he became king 26 months before being killed at the Battle of Bosworth. The research, conducted by the British Geological Survey in collaboration with researchers at the University of Leicester, examined the changes in chemistry in the teeth, the femur and the rib, all of which develop and remodel at different stages of life.

Isotope measurements that relate to geographical location, pollution and diet (strontium, nitrogen, oxygen, carbon and lead) were analysed in three locations on the skeleton of Richard III. The teeth, which form in childhood, confirmed that Richard had moved from Fotheringay Castle in eastern England by the time he was 7. The data suggest that during this time he was in an area of higher rainfall, older rocks and with a changed diet relative to his place of birth in Northamptonshire. By examining the femur, which represents an average of 15 years before death, the researchers found that Richard had moved back to eastern England as an adolescent or young adult, and had a diet typical of that of the highest aristocracy.

The third location, the rib, renews itself relatively quickly, so it only represents between two and five years before death. Data from the isotopes in this bone indicate the greatest change in diet. Although an alteration in the chemistry between the femur and the rib of Richard III could indicate relocation, historical records show that Richard did not move from the east of England in the two years prior to his death. As such, this chemical change is more likely to represent a change



in diet relating to his period as king. The difference suggests an increase in consumption of fresh-water fish and birds, which were popular additions to royal banquets at the time and included birds, such as swan, crane, heron and egret. In addition, the bone chemistry suggests he drank more wine during his short reign as king and reinforces the idea that food and drink were strongly linked to social status in Medieval England.

Dr Angela Lamb, isotope geochemist and lead author of the paper, said: "The chemistry of Richard III's teeth and bones reveal changes in his geographical movements, diet and social status throughout his life."

Richard Buckley, OBE, from the University of Leicester Archaeological Services and lead archaeologist in the Richard III dig said, "This cutting edge research has provided a unique opportunity to shed new light on the diet and environment of a major historical figure—Richard III. It is very rare indeed in archaeology to be able to identify a named individual with precise dates and a documented life. This has enabled the stable-isotope analysis to show how his environment changed at different times in his life and, perhaps most significantly, identified marked changes in his diet when he became king in 1483."

The study, titled "Multi-isotope analysis demonstrates significant lifestyle changes in King Richard III", was published online on 16 August in the Journal of Archaeological Science ahead of print.

## After hepatitis accusation: Oral surgeon permanently surrenders license

DT International Report

TULSA, Okla., USA: An oral surgeon from Tulsa accused of exposing patients to HIV and hepatitis has lost his license to practice. Investigations against the 66-year-old were launched in summer 2012, after notification from dental licensing agencies of alleged unsafe injection practices in his office. Authorities found numerous violations of health and safety laws, and major violations of the State Dental Act of Oklahoma.

"The case is closed with us at this point," said Oklahoma Board of Dentistry President James Sparks during a meeting last week, just after the board had voted to accept the permanent surrender of the oral surgeon's license. According to the website [www.tulsaworld.com](http://www.tulsaworld.com), which reported on the case, the accused did not attend the meeting.

Former patients have filed lawsuits against the man, whose practice was found to contain rusted instruments and a disorganized drug cabinet with expired medicines, and to have improper sterilization procedures and insufficient infection control measures in

place. Additionally, it is alleged that staff in the surgeon's practice had taken radiographs without the required authorization. Officials also learned that he allowed dental assistants in the office to perform intravenous sedation, despite not being trained or permitted to do so.

The given number of patients who could possibly be infected with HIV, hepatitis B and hepatitis C owing to the unsanitary conditions varies between 4,000 and 7,000. According to the website, more than 4,200 former patients were tested free of charge at clinics in the Tulsa area, and 89 tested positive for hepatitis C, five for hepatitis B and four for HIV. However, whether infection transmission did indeed occur at the oral surgeon's practice has only been proven in one case thus far. A gene test confirmed that a patient had contracted hepatitis C from a visit to the practice.

The oral surgeon had already stopped practicing voluntarily in spring 2013 and moved to Arizona.

## DENTAL TRIBUNE

The World's Dental Newspaper • Pakistan Edition

### Publisher/CEO

Syed Hashim A. Hasan  
[hashim.hasan@dental-tribune.com.pk](mailto:hashim.hasan@dental-tribune.com.pk)

### Editor Clinical Research:

Dr. Inayatullah Padhiar

### Editors Research & Public Health

Prof. Dr. Ayyaz Ali Khan

### Editorial Assistance

Dr. Ahmed Ali

### Editor - Online

Haseeb Uddin

### Graphics Designer

Sh. M. Sadiq Ali

### Dental Tribune Pakistan

3rd floor, Mahmood Centre, BC-11, Block-9  
Clifton, Karachi, Pakistan.

Tel.: +92 21 35378440-2 | Fax: +92 21 35836940

[www.dental-tribune.com.pk](http://www.dental-tribune.com.pk) [info@dental-tribune.com.pk](mailto:info@dental-tribune.com.pk)

Dental Tribune Pakistan cannot assume responsibility for the validity of product claims or for typographical errors. The publisher also does not assume responsibility for product names or statements made by advertisers. Opinions expressed by authors are their own and may not reflect of Dental Tribune Pakistan.

## International Imprint

### Group Editor

**Daniel Zimmermann**

[newsroom@dental-tribune.com](mailto:newsroom@dental-tribune.com)

Tel.: +49 341 48 474 107

### Clinical Editor

**Magda Wojtkiewicz**

### Online Editors

**Yvonne Bachmann**

**Claudia Duschek**

**Sabrina Raaff**

**Hans Motschmann**

### Copy Editors

### Publisher/President/CEO

**Torsten Oemus**

### Chief Financial Officer

**Dan Wunderlich**

### Business Development Manager

**Claudia Salwiczek**

### Events Manager

**Lars Hoffmann**

### Media Sales Managers

**Matthias Diessner**

(Key Accounts)

**Melissa Brown**

(International)

**Peter Witteczek**

(Asia Pacific)

**Maria Kaiser**

(North America)

**Weridiana Mageswki**

(Latin America)

**Hélène Carpentier**

(Europe)

### Marketing & Sales Services

**Nadine Dehmel**

**Nicole Andrä**

### Accounting

**Karen Hamatschek**

**Anja Maywald**

**Manuela Hunger**

### Executive Producer

**Gernot Meyer**

### Dental Tribune International

Holbeinstr. 29, 04229 Leipzig, Germany

Tel.: +49 341 48 474 302 | Fax: +49 341 48 474 173

[info@dental-tribune.com](mailto:info@dental-tribune.com) | [www.dental-tribune.com](http://www.dental-tribune.com)

### Regional Offices

#### Asia Pacific

Dental Tribune Asia Pacific Limited

Room A, 20/F, Harvard Commercial Building,

105–111 Thomson Road, Wanchai, Hong Kong

Tel.: +852 3113 6177 | Fax: +8523113 6199

#### The Americas

Tribune America, LLC

116 West 23rd Street, Ste. 500, New York, N.Y. 10011, USA

Tel.: +1 212 244 7181 | Fax: +1 212 244 7185

INTRODUCING



**DIGITAL  
DENTISTRY  
SHOW**

AT  
**INTERNATIONAL EXPODENTAL MILAN**

**16 17 18** OCTOBER 2014

EXHIBITION

LIVE PRODUCT PRESENTATIONS

HANDS-ON WORKSHOPS

PRINTED REFERENCE GUIDE

COFFEE WITH THE EXPERTS

[www.DigitalDentistryShow.com](http://www.DigitalDentistryShow.com)

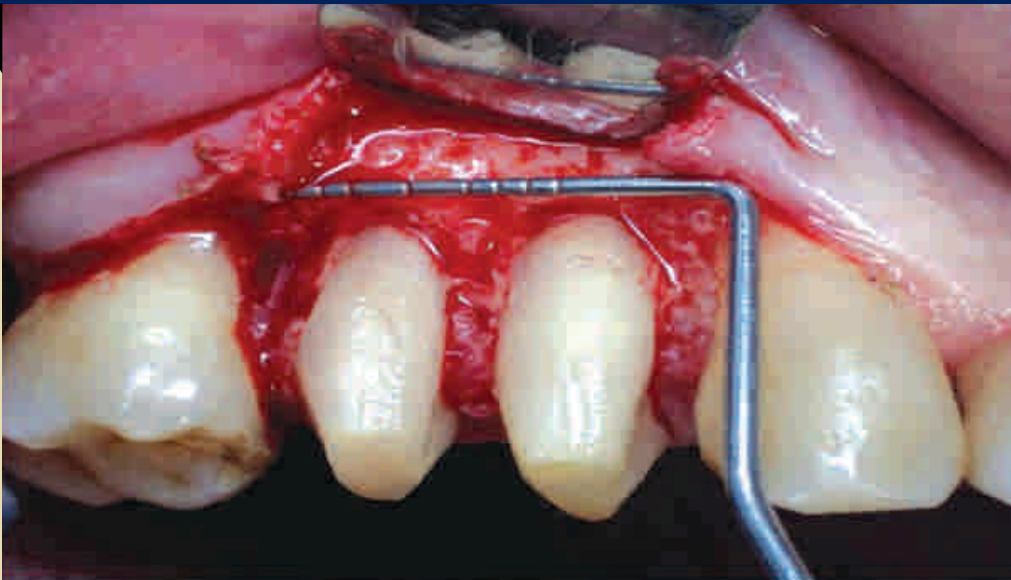
Organized by Dental Tribune International in cooperation with Promunidi.  
Dental Tribune International | Holbeinstraße 29 | 04229 Leipzig | Germany  
T +49 341 48474 134 | F +49 341 48474 173  
E [info@digitaldentistryshow.com](mailto:info@digitaldentistryshow.com) | W [www.DigitalDentistryShow.com](http://www.DigitalDentistryShow.com)

**dti** Dental  
Tribune  
International

**PROMUNIDI**



# Er:YAG Garnet in laser-assisted crown lengthening



This article describes and demonstrates the use of the Erbium:YAG 2940nm laser system (LiteTouch, Syneron Medical Ltd.) as a central tool in the treatment of osseous crown lengthening, and the advantages this wavelength offers versus the use of conventional methods.

**Objectives and methods**

Crown lengthening is a surgical procedure employed for the removal of periodontal tissue, in order to increase the clinical crown height. It is the most frequently used and valuable periodontal surgical procedure related to restorative treatment.<sup>(1-4)</sup>

*The objectives of clinical crown lengthening include*

- 8 Removal of subgingival caries
- 8 Preservation and maintenance of restorations
- 8 Cosmetic improvement

8 Enabling restorative treatment without impinging on biologic width

- 8 Correction of the occlusal plane
- 8 Facilitation of improved oral hygiene

*There are two methods of crown lengthening*

- 8 Orthodontic - coronal extension
- 8 Surgical - apical extension

*Clinical considerations*

- 8 Importance of the tooth
- 8 Subgingival caries
- 8 Clinical crown/root ratio
- 8 Root length and morphology
- 8 Residual amount of bone support
- 8 Furcation involvement
- 8 Tooth mobility
- 8 Aesthetic demands
- 8 Post-op maintenance and plaque control

**Biologic width and aesthetic dentistry**

To utilize crown lengthening, it is important for the restorative dentist to understand the concept of biologic width, indications, technique and other principles.<sup>(7-9)</sup> To maintain healthy periodontal tissue, the attached gingival and biologic width must be considered. Biologic width is measured from the bottom of the gingival sulcus to the alveolar crest and is maintained by homeostasis.<sup>(10,11)</sup> This width consists of the epithelial attachment to the tooth surface and its connective tissue. The average width is 2.04 mm. Impinging biologic width may cause periodontal tissue destruction; therefore, in crown lengthening, the position of the margin is important.

Methods of clinical crown lengthening As mentioned above, there are two methods to lengthen a crown: coronal extension and apical extension. Apical extension of the crown is achieved by surgery, with or without osseous resection. In apical extension there are two methods:

- 8 Open technique: patients who exhibit asymmetrical gingival levels, those with greater than 3 to 5mm of maxillary gingival display, or both may be candidates for surgical gingival and/or alveolar bone repositioning to improve their aesthetics.
- 8 Closed technique - for minor localized biologic width and/or aesthetic gingival zenith corrections. Can be used in lieu of a flap procedure to make the correction and complete the restorative process without the necessary healing time required for open crown lengthening surgeries.<sup>(12)</sup>

**Case presentation**

This clinical report describes a situation in which a crown lengthening procedure was successfully performed with the Er:YAG laser (LiteTouch, Syneron Medical Ltd.) as a principal auxiliary tool, and the advantages of the 2940 nm wavelength versus conventional methods.

*Examination*

Clinical examination of a 57-year-old male revealed missing teeth at the locations #17, 36,

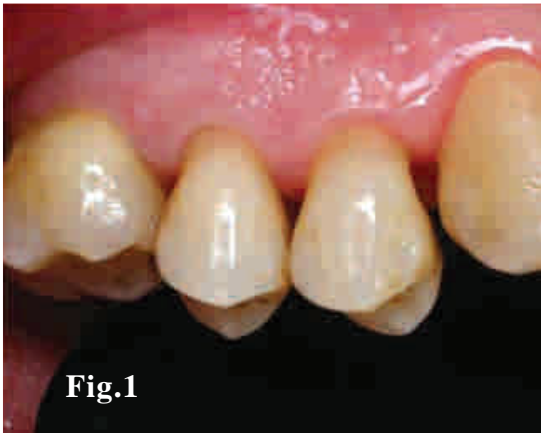

Fig.1

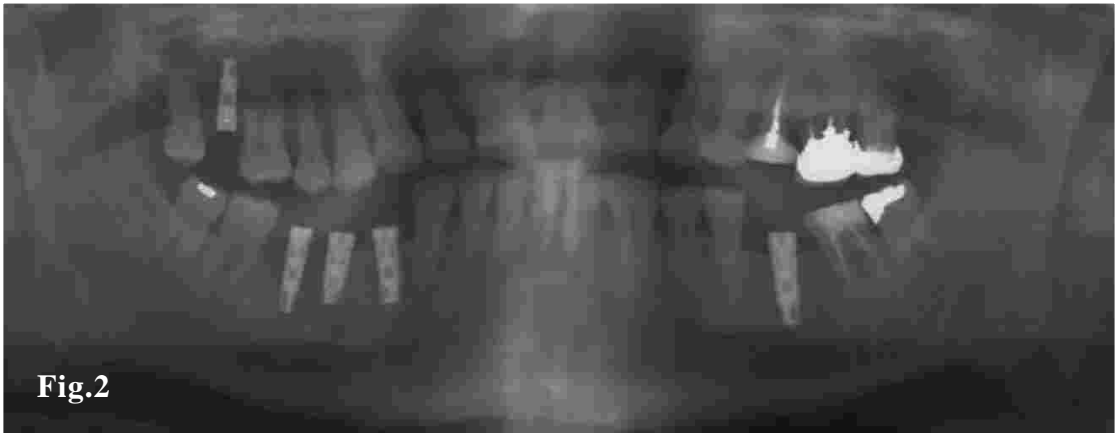


Fig.2

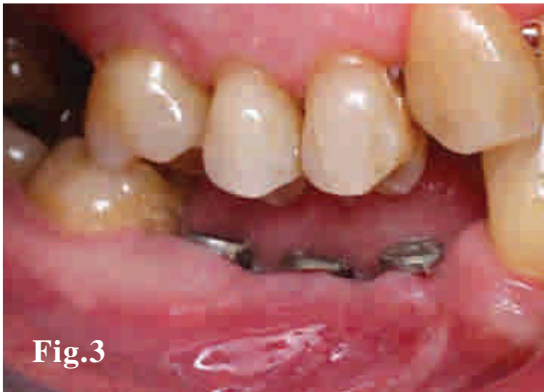

Fig.3

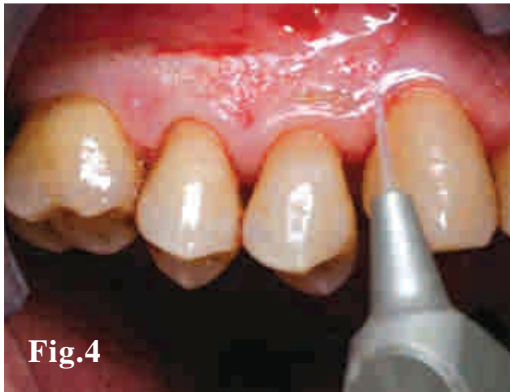

Fig.4

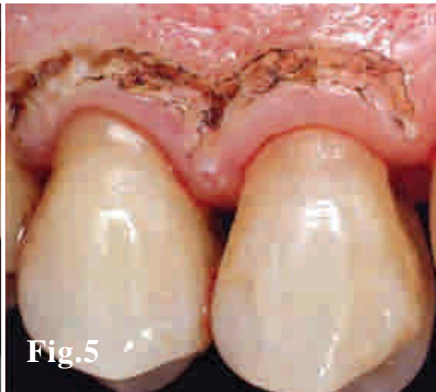

Fig.5

**Fig. 1:** Patient presentation.

**Fig. 2:** Insertion of five implants.

**Fig. 3:** Teeth #14 and 15 in occlusion.

**Fig. 4:** Use of the diode laser to mark the border for incision of the soft tissue.

**Fig. 5:** Incision border

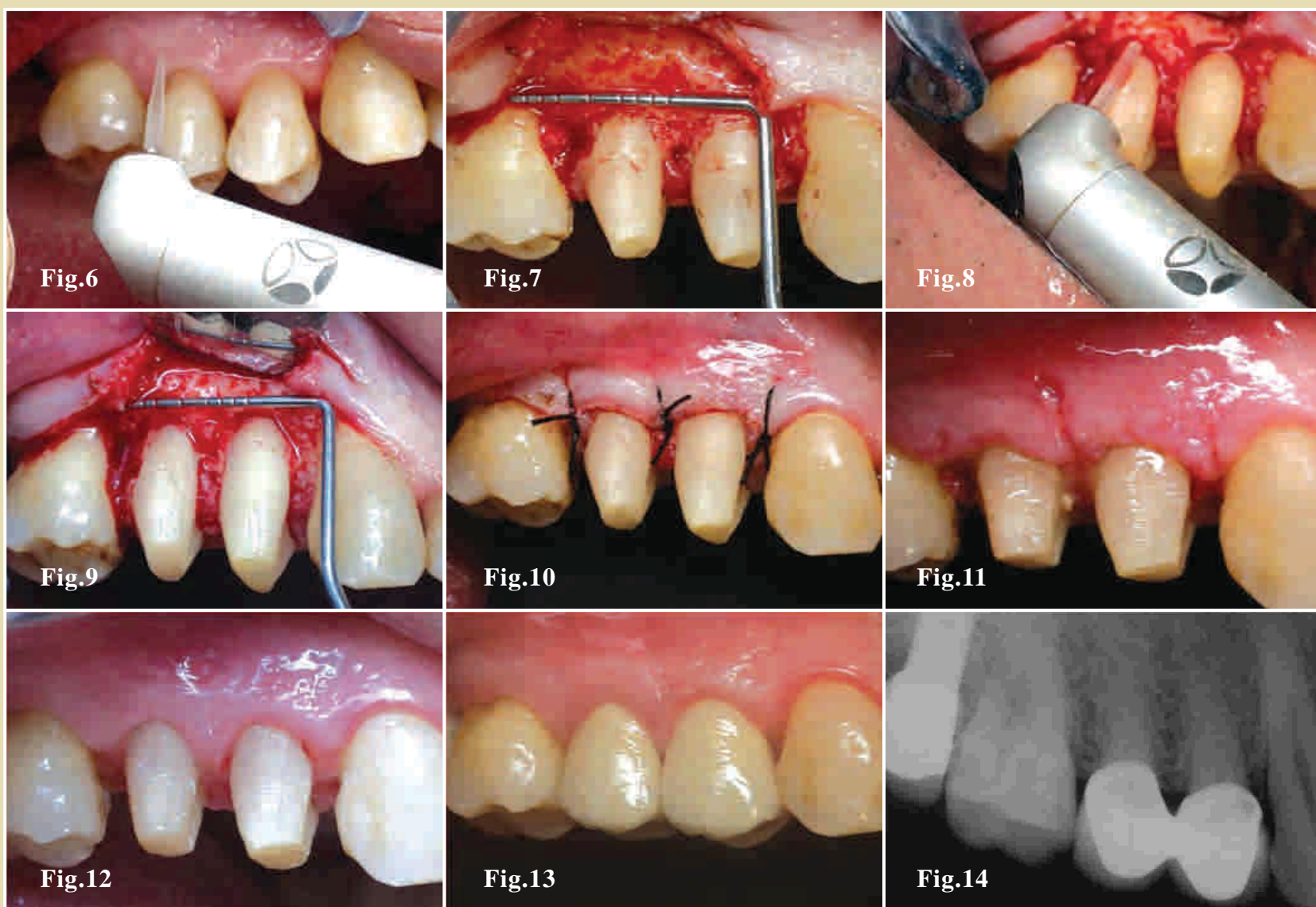
The clinician must create a symmetrical and harmonious relationship between lips, gingival architecture and positions of the natural dentate forms. Spear et al.<sup>(5)</sup> have referred to this diagnostic methodology as facially generated treatment planning, where the maxillary central incisal edges determine where the soft tissue, i.e., gingiva, and bone should be positioned.<sup>(6)</sup>

44, 45 and 46 with overeruption of teeth # 14 and 15 (Fig. 1). Radiographic examination of the area showed overeruption of teeth 14 and 15 with the alveolar bone.

*Treatment options*

The treatment options available in this case were:  
8 Insertion of implants and metal-ceramic crowns at the locations of teeth #17, 36, 44, 45 and 46.





**Fig. 6:** Incision.

**Fig. 7:** Lifting the mucoperiosteal.

**Fig. 8:** Bone ablation.

**Fig. 9:** Bone level after ablation.

**Fig. 10:** Immediately post-op.

**Fig. 11:** One week post-op.

**Fig. 12:** Four months post-op.

**Fig. 13:** Nine months post-op.

**Fig. 14:** Nine months post-op X-ray image.

8 In addition to option one above: crown lengthening for teeth #14 and 15 and covering them with metal-ceramic crowns.

Following discussion with the patient and evaluation of the possibilities for success, it was decided to perform crown lengthening. Treatment would involve the use of the Er:YAG laser to perform the following steps, based upon accepted research:

8 Flap incision<sup>(13-15)</sup>

8 Ablation of soft tissue around the teeth after raising a flap<sup>(16-18)</sup>

8 Remodelling, shaping and ablating of the bone<sup>(13,15,19,20)</sup>

#### Treatment

All five implants were placed in one sitting (Fig. 2). Crown lengthening was performed three weeks postop (Fig. 3). Laser operating parameters employed for the various surgical stages were as follows:

8 Flap Access: Wavelength: 2940nm (Er:YAG), 600-micron sapphire tip, contact mode; 200 mJ per pulse at 35 Hz. Total power: 7 Watts.

8 Soft Tissue Removal: Wavelength: 2940nm (Er:YAG), 1300-micron sapphire tip, non-contact mode; 400 mJ per pulse at 20Hz. Total power: 8 Watts.

8 Bone Surgery: Wavelength: 2940nm (Er:YAG),

1300-micron sapphire tip, non-contact mode; 300 mJ per pulse at 20 Hz. Total power: 6 Watts. With the assistance of a diode laser operating at a power setting of 2.4 W in contact mode, the location of the incision was marked (Figs. 4 and 5). An incision was made with the laser (after anaesthesia) at the buccal and palatal side of teeth #14 and 15 (Fig. 6) and a vertical incision was not required. The buccal and palatal flaps were lifted and the area was explored (Fig. 7); there was soft tissue around the neck of the teeth. The soft tissue was ablated using the laser. Vaporization of soft/granulation tissue (if any exists) after raising a flap is efficient with the Er:YAG laser, offering a lower risk of overheating the bone than that posed by the diode or CO<sub>2</sub> lasers<sup>23</sup> and often obviates the need for hand instruments. Results from both controlled clinical and basic studies have pointed to the high potential of the Er:YAG laser and its excellent ability to effectively ablate soft tissue without producing major thermal side effects to adjacent tissue have been demonstrated in numerous studies.<sup>(16-18)</sup>

The Er:YAG laser was aimed at the surface of the exposed bone which was ablated in non-contact mode (Fig. 8). Studies have shown that Er:YAG laser energy effects on bone include bacterial reduction.<sup>(22)</sup> Following this, all accessible bone surfaces were exposed to laser energy to ablate necrotic bone and to shape and remodel the surface in accordance with established clinical protocols.<sup>(13,15,20)</sup> The bone level around teeth #14 and 15 fits to the bone level of teeth #13 and 16 (Fig. 9). The mucoperiosteal flap was repositioned and sutured with silk 3-0, paying particular attention to primary closure of the flap (Fig. 10).

#### Postoperative instructions

The patient was prescribed antibiotics to avoid infection and painkillers for pain. Instructions were given to rinse with Chlorhexidine 0.2 %, starting the next day for two weeks, three times per day.

#### Management of complications and follow-up

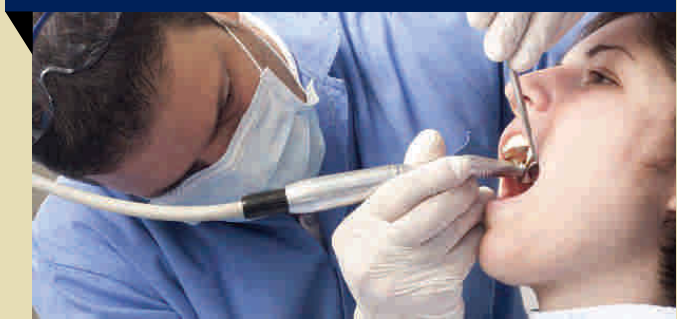The following day the patient reported moderate pain and moderate swelling. There was no tissue bleeding and the site was closed. The flap was showing signs of attachment and was healing nicely. At seven days post-op, the patient returned for inspection and removal of sutures. The swelling had resolved and healing was progressing well (Fig. 11). After five months, the soft tissue was healed completely without complications (Fig. 12). The soft issue had healed over the bone and there were no bony projections observed under the soft tissue. The prognosis is excellent. An impression for two metal-ceramic crowns was taken five months post-op (Fig. 10). An aesthetic result was achieved (Figs. 13 and 14).

#### Conclusion

The Er:YAG laser system (LiteTouch, Syneron Medical, 2940nm) can be employed as an auxiliary tool for the purpose of crown lengthening and has been shown to be effective and safe. The use of the LiteTouch wavelength for these procedures presents many advantages as opposed to conventional methods, including enhancement of the surgical site and less bleeding during the operation, providing the surgeon with a better field of visibility and reducing patient discomfort during use. In addition, anecdotal claims have been made that post-operative effects such as pain and swelling are less pronounced. Finally, the laser offers the dental surgeon enhanced ease of use with the hand piece's 360° swivel capability.



# More English adults see NHS dentists



DT International Report

**L** EEDS, UK: The number of adult and child patients who visit a National Health Service (NHS) dentist is rising, but only the North of England has recorded an increase in the percentage of the child population seen by a dentist compared with eight years ago, the latest figures show. The report also found an 18 per cent rise in the number of dentists performing NHS activity since 2006/7.

Just over 29.9 million adults and children (i.e. patients under the age of 18) in England saw an NHS dentist in the 24 months before June 2014, according to the Health and Social Care Information Centre (HSCIC). This is 1.8 million (6.3 per cent) more than in the 24 months before March 2006, when the reporting series began, and equates to 55.9 per cent of the population seen in the 24 months before June 2014 (compared with 55.6 per cent in the 24 months before March 2006).

However, while the total number and percentage of adults seen by June 2014 are higher than in 2006, the percentage of the child population seen has fallen by almost 1 percentage point.

NHS Dental Statistics for England, 2013/14, which provides information about patients seen by dentists and NHS dental activity in England, shows that 22.0 million adults (52.3 per cent of the adult population) had been seen in the 24 months before June 2014 compared with 20.3 million (51.5 per cent) in the 24 months before March 2006. The report also shows that 7.9 million children (69.2 per cent of the child population) had seen a dentist in the 24 months before June 2014, compared with 7.8 million (70.2 per cent) in 24 months before March 2006.

In terms of the four NHS regions in England (North, South, London, and Midlands and East ), in the 24 months before June 2014, the total number of adults seen rose in all regions compared with the 24 months before March 2006, but only two—the North and the South—saw a rise in the percentage of the population seen (with falls in the London, and Midlands and East regions).

The largest percentage of the adult population seen was in the North at 57.6 per cent (6.9 million)—a rise of 1.1 percentage points (420,000) on 2006. The lowest was in London at 46.6 per cent (3.0 million)—a fall of 1.8 percentage points on 2006.

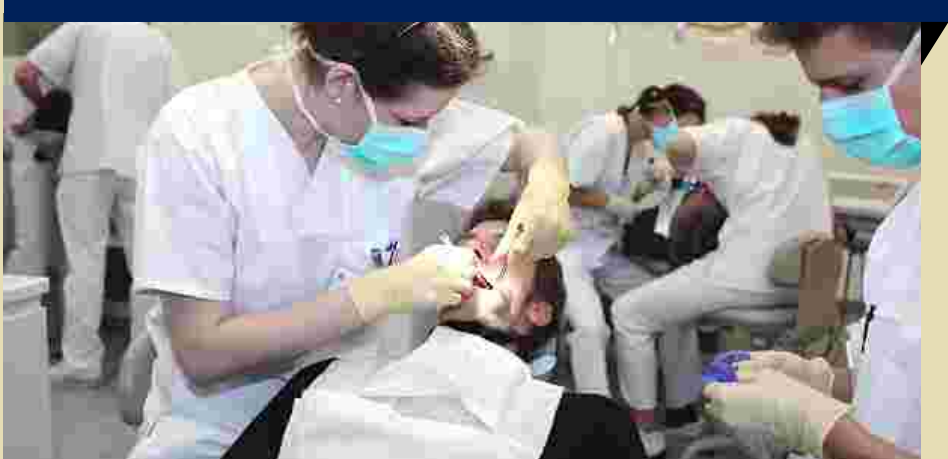The total number of children seen rose in two regions, the North and London, compared with the 24 months before March 2006, but only the North saw a rise in the percentage of the population seen—of 3.1 percentage points (73,000).

The North also accounted for the largest percentage of the child population seen at 74.0 per cent (2.4 million). The lowest was in London at 63.0 per cent (1.2 million)—a fall of 0.8 percentage points on 2006.

HSCIC chair Kingsley Manning said, “Today’s report shows one impact of a growing population on NHS dentistry. While more and more people are taking a turn in the dentist’s chair, the proportion of the population seen is increasing slightly for adults but dipping slightly for children compared to eight years ago.”

Manning explained that both the national and regional situation will be of interest to the public, and provides a basis for further exploration for health professionals. He said that the report also highlights dental workforce statistics, which show an 18 per cent rise in the number of dentists performing NHS activity since 2006/7, and will help to develop a fuller picture of the state of NHS dentistry in England.

# German university introduces new international *Master’s programme*



DT International Report

**K** IEL, Germany: Academics at the Faculty of Medicine at Kiel University have developed a new international master’s degree programme to offer further training for university lecturers in the field of dentistry and medicine. The accredited International Master of Applied Scientific Dental/Medical Education and Research will be offered for the first time this coming winter semester.

“Above all, we want to strengthen the quality of research and teaching in the field of oral medicine and present our teaching approaches, as well as international approaches with this new master’s degree programme,” said Prof. Jörg Wiltfang, Director of the Department of Oral and Maxillofacial Surgery at the University Medical Center Schleswig-Holstein. Wiltfang will co-ordinate the degree programme at the Faculty of Medicine together with Prof. Christof Dörfer, Director of the Department of Dental Preservation and Periodontics at the centre. The advanced degree programme is intended to appeal to the next generation of academics and particularly to international candidates.

During the two-year degree programme, lecturers will teach students the fundamentals of research, establishing a research group, structuring studies and publishing research results. Internationally recognised research results, in particular, also from the Faculty of Medicine, will determine the content of the degree programme. In addition, teaching methods, quality management, staff management and communication are topics included in the curriculum. Students will also learn how to develop and implement teaching curricula independently in accordance with current didactic standards.

The part-time advanced degree programme in this form is unique in Germany and is arranged across four semesters. Twenty places are available per semester. In order to gain admission to the programme, prospective candidates must provide evidence that they have obtained a degree in Medicine or Dentistry and are currently working or had previously worked at a university. Those interested can register for the coming winter semester until 1 October 2014.

The programme was developed in collaboration with the Leibniz Institute for Science and Mathematics Education at Kiel University and the Institute for Quality Development of Schools in Schleswig-Holstein.

# Anaesthetised patient falls and dies in dental practice



DT International Report

**D** ÜSSELDORF, Germany: In a dental office in Düsseldorf, a patient died after a tragic fall. The 45-year-old woman, who had been treated under anaesthesia owing to a mental disability, woke up dizzy in the recovery room and accidentally slammed her head

*Continued to page 11*



# CROIXTURE

PROFESSIONAL MEDICAL COUTURE



## THE NEW 2014-2015 COLLECTION

EXPERIENCE OUR ENTIRE COLLECTION ON [WWW.CROIXTURE.COM](http://WWW.CROIXTURE.COM)





University College of Dentistry, Istanbul, three speakers from UK, namely Dr. Riaz Yar from Hale Barns, Dr. Zulaikha Burki from St. Guys' and Thomas' Hospital London and Dr. Habib Rehman of Eastman Dental Institute London, two speakers from Saudi Arabia including Dr. Iyad Ghoniem from Jeddah and Dr. Rashid Habib from King Saud University Riyadh and last but not the least, one speaker Dr. Mohammad Abdalla Al-Rabab'ah from the University of Jordan, Amman, making it a truly international conference.

The preconference workshops were organized under the expert guidance and facilitation of the international speakers.

The grand opening ceremony of the conference was formally inaugurated by the Chief guest Lt Gen Azhar Rasheed HI(M), Surgeon General , Medical Services Inter Services. The proceedings started with recitation of the Holy Qur'aan followed by the National Anthem.

The chief guest in his address not only thanked the organizers but also appreciated their efforts in organizing the event and hoped that the conference would fulfill its role in professional development of the dentists. He also highlighted the role of his department in promoting medical education.

Commandant Armed Forces Institute of Dentistry (AFID) Brig. Waseem Ahmed delivered the welcome address. He extended his gratitude to

all international speakers and emphasized the importance of the conference in relation to continued professional development of the participants.

Prof. Col. Azad Ali Azad, the President of PPA and chairman of the conference, delivered his address to the audience, providing details of the conference and the workshops. He also presented a historical background on prosthodontists in Pakistan and how the PPA came into being.

Key note lecture on the conference theme was delivered by Prof. Dr. Nazia Yazdanie, the dean of Postgraduate Studies and Head of Prosthodontics at FMH College of Dentistry Lahore. She gave an overview about the past, present and future of prosthodontics in the country and quoted different local and regional studies in relation to her topic. After her lecture, conference mementos were distributed among the chief guest and Prof. Dr. Nazia Yazdanie.

A gala dinner was organized at the beautiful location of Pak China Friendship Center. The event started with a beautiful cultural program highlighting the various cultural factions of the country. It received tremendous applaud from the audience. After a grand dinner, a musical program was presented which was highly appreciated especially by the younger participants.

At the end of the day's proceedings, the

elimination round of quiz competition was held in the main auditorium hall, with teams from 9 different colleges of the country participating. The competition was attended by a number of students who remained busy in bucking up and supporting their respective teams during the questions. At the end of this round, the top 4 teams were selected for the final round.

In the evening, a recreational trip followed by dinner was organized for the prosthodontic faculty and the international guest speakers at the famous La Montana Restaurant in Pir Sohawa area. Everyone enjoyed the night sky and night view of the capital city from the Margalla Hills.

A few of the speakers could not make it to the conference due to the developing political situation in the capital city.

After the scientific sessions, the final round of quiz competition was held and after a tough match, at last, the team of CMH Lahore Medical and Dental College Lahore won the first prize of 30,000 Rs. Second position went to Sharif Medical and Dental College Lahore with a cash prize of 20,000 Rs. Team from Sardar Begum Dental College Peshawar stood third and were rewarded with a cash prize of 10,000 Rs while a consolation prize of 5,000 Rs. was given to the fourth team from FMH College of Dentistry Lahore. All teams

*Continued to page 11*






Tribune CME

## 6 Months Clinical Masters™ Program in **Aesthetic and Restorative Dentistry**

**Dubai Session**, 12-15 November 2014



On location session, **hands on** + online learning  
and mentoring

**Learn from the Masters** of Aesthetic and Restorative Dentistry: \_\_\_\_\_



Prof. Angelo Putignano



Prof. Francesco Mangani

### Topics

- Anterior Composite Restorations Demystifying Anteriors
- Posterior Direct Restorations
- Conservative Indirect Esthetic Restorations

### Registration information: \_\_\_\_\_

**12-15 November 2014**

a total of 4 days of intensive live training in **Dubai** (UAE)

**Curriculum fee: € 3,450**

(you can decide at any time to complete the entire Clinical Masters Program  
and take the remaining session)

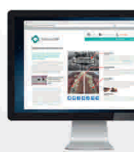Details on [www.TribuneCME.com](http://www.TribuneCME.com)

**contact us at tel.: +49 341 48474 302**

**email: [request@tribunecme.com](mailto:request@tribunecme.com)**

**Collaborate**  
on your cases

and access hours of  
premium video training  
and live webinars



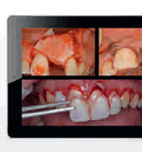**University**  
of the Pacific

you will receive a  
certificate from the  
University of the Pacific



**Latest iPad**  
with courses

all registrants receive  
an iPad preloaded with  
premium dental courses



\*iPad only available for the participants  
in the entire Clinical Master Program

**50** ADA CERP  
C.E. CREDITS

**ADA C.E.R.P.®** | Continuing Education  
Recognition Program

Tribune America LLC is the ADA CERP provider. ADA CERP is a service of the American Dental Association to assist dental professionals in identifying quality providers of continuing dental education. ADA CERP does not approve or endorse individual courses or instructors, nor does it imply acceptance of credit hours by boards of dentistry.

Supported by:  
**ivoclar  
vivadent**  
passion vision innovation