



**Plan your first trip of '12**  
Yankee Dental Congress hits  
New England in January

►Page 10



**New study**  
100 percent success found with  
Straumann Bone Level implants

►Page 14



**Win a trip to NYC!**  
Deadline is approaching;  
don't miss the chance to apply

►Page 17

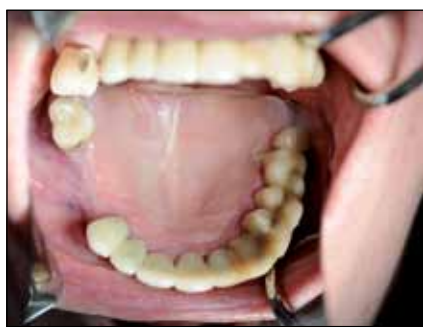

Fig. 1: Pre-operation, vestibule area is relatively broad, flat ridge regions #14 to #16, six weeks after extraction of tooth #14.

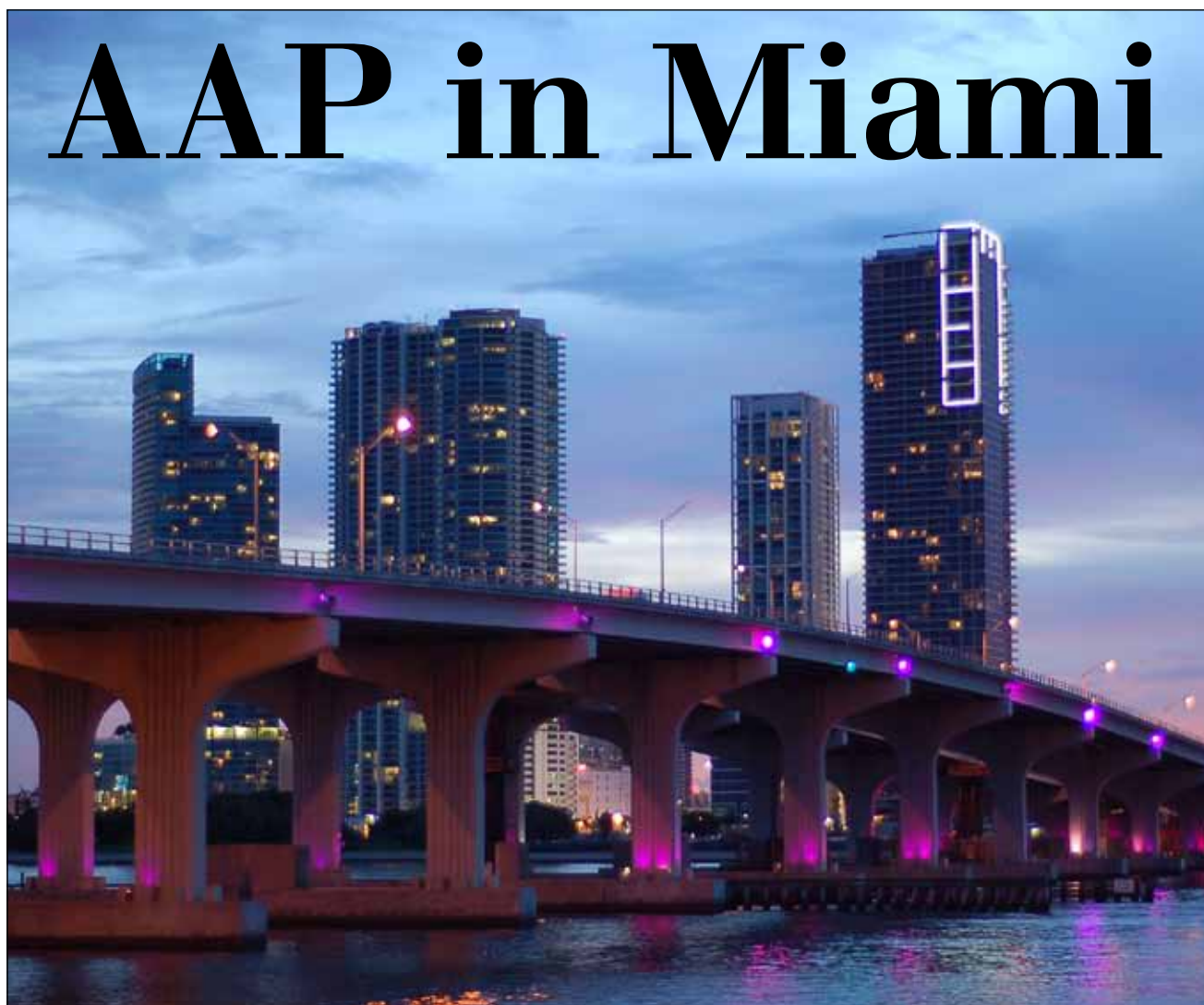## Augmentation: One important basis in implant treatment

By Dr. Frank Liebaug and Dr. Ning Wu

In recent years, new issues have arisen in the field of implant dentistry. The 1980s was the decade of osseointegration; the 1990s, the era of guided bone regeneration. Recently, the focus has mainly been on the improvement of dental esthetics and methods of improving the esthetic and functional results, the load-carrying capacity and the simplification of surgical techniques. These aspects should not be considered separately from each other, as they overlap.

In 1980, Philip Boyne first described procedures for sinus floor augmentation. Since then more than

→ **ii** page 2



The 97th annual meeting of the American Academy of Periodontology will take place Nov. 12-15 in Miami Beach, Fla. (Photo/Provided by stock.xchng, www.sxc.hu)

## Hands-on workshops, interactive general session highlight meeting

The 97th annual meeting of the American Academy of Periodontology will take place Nov. 12-15 in Miami Beach, Fla.

Bringing back a full schedule of continuing education courses, this year's program allows participants access to some of the most recognized names in the periodontal community. Saturday offers hands-on workshops, practice management sessions and the first of three corporate forums.

Additionally, this year the interactive general session returns with a multi-panel conversation presented in conjunction with the European Federation of Periodontology.

Don't miss the welcome reception, where the beat of KC & the Sunshine Band is sure to entertain you! This energetic dance party will be a memory to share with friends and colleagues alike, so register early, as it is a limited attendance event.

Just a sampling of the the intriguing

session topics includes: "Use of Stem Cells for Osseous Reconstruction," "Immediate vs. Delayed Socket Placement: What We Know, What We Think We Know and What We Don't Know," "Strategies to Overcome Difficult Extractions" and "Management of the Deficient Anterior Ridge."

New this year: Make plans to arrive early at the Miami Beach Convention Center on Sunday and Monday mornings. In addition to the opening of the exhibition, the academy is excited to present the "early bird" corporate forum sessions: two 45-minute sessions that will allow attendees to become further acquainted with academy corporate sponsors.

For more information on housing, registration fees and more, visit [www.perio.org](http://www.perio.org).

PRSR STD  
U.S. Postage  
PAID  
San Antonio, TX  
PERMIT #1396

Dental Tribune America  
116 West 25th St., Ste. 500  
New York, NY 10011



← **IT** page 1

1,000 scientific articles on sinus floor augmentation have been published.

Today, the use of osseointegrated dental implants is an effective and reliable method for long-term treatment of patients with partial and total tooth loss. The success rate and predictability of implant treatment depends on several factors but are generally high. The goal is to make this rehabilitative process accessible to as many patients as possible, even those with poor bone quality and/or low bone mass.

Until now, an insufficient amount of bone and poor bone quality have been unfavorable or even a contraindication for implant treatment. Because of poor bone quality and often-progressive bone resorption after tooth loss, the posterior maxilla especially is a high-risk area for the placement of dental implant restorations. If atrophic maxillary bone or a large maxillary sinus is present, the implant treatment is more difficult.

A solution in such cases is the use of shorter implants. However, certain clinical conditions must be met so that an unfavorable relationship between the implant and the restoration length (implant-crown ratio) does not lead to biomechanical problems, improper loading or premature implant loss.

In such cases, the implant treatment must be planned carefully and additional surgical procedures before dental prosthetics, such as a bone graft in the maxillary sinus, are often required to compensate for inadequate bone. In this way, optimal conditions for the insertion of implants in the posterior portions of the alveolar process of the maxilla are created.

In the past, dentists and maxillofacial surgeons avoided complex procedures that required access to the maxillary sinus through the oral cavity, provided such were not necessary. As early as 1984, Brånemark demonstrated with clinical and experimental data that the apical end of an osseointegrated implant can be placed in the maxillary sinus without adversely affecting the health of the sinus area if the Schneiderian membrane remains intact.

Today, it is common knowledge that the long-term success of dental implants depends on the degree of osseointegration. This, in turn, is dependent on the primary stability, on the one hand, which is determined by the density of cortical bone and the bone quality, and on

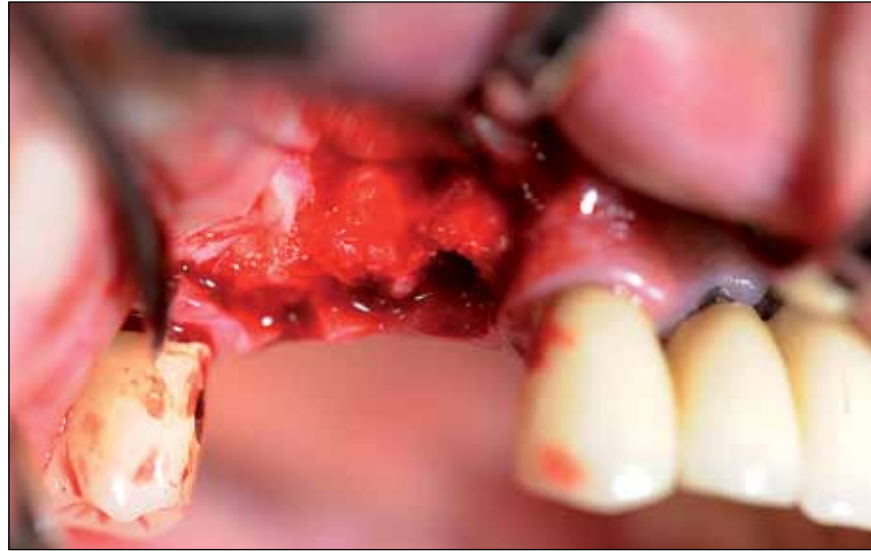

Fig. 2: Surgical site after surgical flap preparation shows fully ossified alveolus of tooth #14, six weeks after extraction.

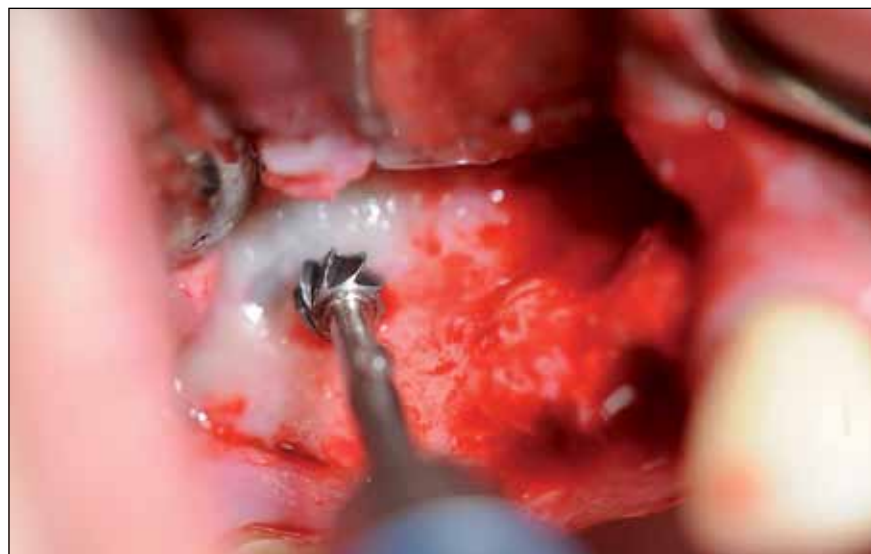
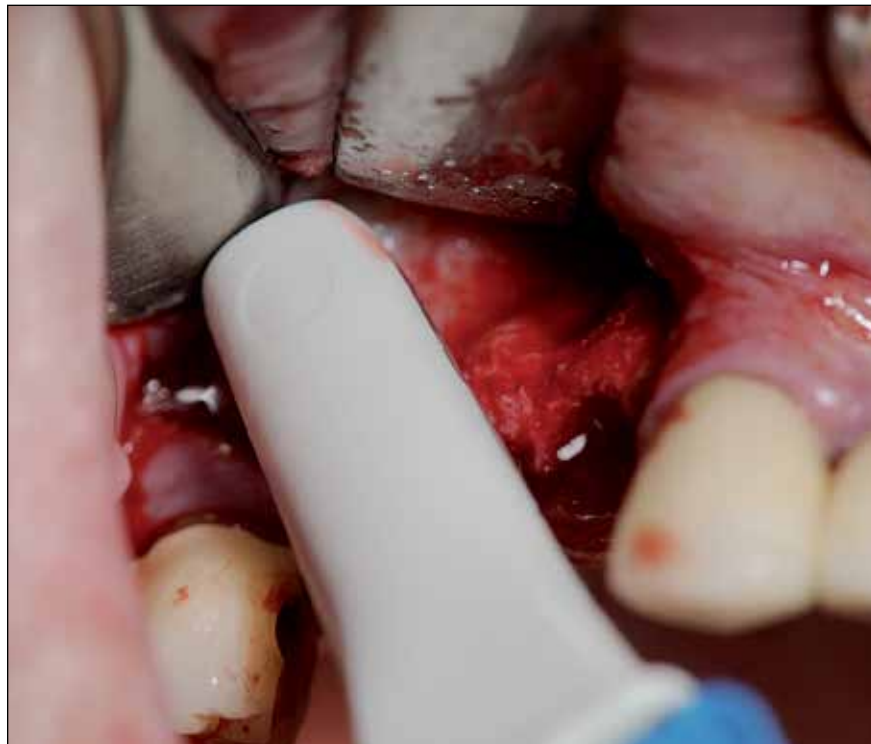
Fig. 3: Pre-preparation of the bone window in region #16 with large Rosecutter to mark the finish line under continuous cooling.



→ **IT** page 4 Fig. 4: Extraction of the patient's own (autologous) bone chips by Safescraper.

## IMPLANT TRIBUNE

The World's Newspaper of Implantology - U.S. Edition

### Publisher & Chairman

Torsten Oemus  
t.oemus@dental-tribune.com

### Chief Operating Officer

Eric Seid  
e.seid@dental-tribune.com

### Group Editor & Designer

Robin Goodman  
r.goodman@dental-tribune.com

### Editor in Chief

Sascha A. Jovanovic, DDS, MS  
sascha@jovanoviconline.com

### Managing Editor/Designer

Implant, Endo & CAD/CAM Tribunes  
Sierra Rendon  
s.rendon@dental-tribune.com

### Managing Editor/Designer

Ortho Tribune & Show Dailies  
Kristine Colker  
k.colker@dental-tribune.com

### Online Editor

Fred Michmershuizen  
f.michmershuizen@dental-tribune.com

### Account Manager

Humberto Estrada  
h.estrada@dental-tribune.com

### Marketing Manager

Anna Wlodarczyk  
a.wlodarczyk@dental-tribune.com

### Marketing & Sales Assistant

Lorrie Young  
l.young@dental-tribune.com

### C.E. Manager

Julia Wehkamp  
j.wehkamp@dental-tribune.com

### International C.E. Sales Manager

Christiane Ferret  
c.ferret@dtstudyclub.com

Dental Tribune America, LLC  
116 W. 23rd St., Suite #500  
New York, NY 10011  
Phone: (212) 244-7181, Fax: (212) 244-7185

### Published by Dental Tribune America

© 2011 Dental Tribune America.  
All rights reserved.

Dental Tribune makes every effort to report clinical information and manufacturer's product news accurately, but cannot assume responsibility for the validity of product claims, or for typographical errors. The publishers also do not assume responsibility for product names or claims, or statements made by advertisers. Opinions expressed by authors are their own and may not reflect those of Dental Tribune International.

### Editorial Advisory Board

Dr. Sascha Jovanovic, Editor in Chief

Dr. Bernard Touati

Dr. Jack T. Krauser

Dr. Andre Saadoun

Dr. Gary Henkel

Dr. Doug Deporter

Dr. Michael Norton

Dr. Ken Serota

Dr. Axel Zoellner

Dr. Glen Liddelou

Dr. Marius Steigmann

## Tell us what you think!

Do you have general comments or criticism you would like to share? Is there a particular topic you would like to see more articles about? Let us know by e-mailing us at [feedback@dental-tribune.com](mailto:feedback@dental-tribune.com). If you would like to make any change to your subscription (name, address or to opt out) please send us an e-mail at [database@dental-tribune.com](mailto:database@dental-tribune.com) and be sure to include which publication you are referring to. Also, please note that subscription changes can take up to 6 weeks to process.

## **IT** Corrections

Implant Tribune strives to maintain the utmost accuracy in its news and clinical reports. If you find a factual error or content that requires clarification, please report the details to Managing Editor Sierra Rendon at [s.rendon@dental-tribune.com](mailto:s.rendon@dental-tribune.com).

# Familiar Confidence. Sensible Compatibility. Endless Opportunities.



## internal hex

Surgically compatible with  
Zimmer® Tapered Screw-Vent®



## tri-cam

Surgically compatible with  
NobelBiocare™ NobelReplace®



The infinity Dental Implant System

### Familiar Confidence.

The infinity System allows you to place our implants with the familiar confidence you get from your existing system.

### Sensible Compatibility.

Designed to work with your existing implant system, you have the flexibility to use your existing surgical drills, drivers, and prosthetics to place and restore the implant.

### Endless Opportunities.

You will notice one difference with the infinity Implant...pricing. We are committed to delivering a compatible implant at pricing that creates significant opportunities for both you and your patients.

Give us a call today to experience infinity!



infinity  
Dental Implant System



For more information, visit us at the **AAP / Miami / Booth #611**

**LIMITED TIME  
INTRODUCTORY OFFER**  
Mention this ad when purchasing  
**five infinity Implants**  
and you will receive a  
**\$200 CREDIT**  
towards your next ACE purchase

\*Offer good while supplies last. Valid  
through December 31, 2011.



ACE Surgical Supply Co., Inc. • 1.800.441.3100 • [acesurgical.com/infinity.html](http://acesurgical.com/infinity.html)



←  page 2

the secondary stability, on the other hand. The latter results from the progressive deposition of bone along the implant surface.

Although an implant that is inserted into bone with reduced height and width and that extends from one end into the sinus cavity shows a good primary stability with a sufficient solid cortex, its anchor remains limited. Thus, osseointegration of the entire implant surface, which is critical to the long-term success, cannot be achieved. If a progressive loss of crestal bone takes place over time, the implant stability is further affected.

Therefore, in the posterolateral maxillary it is often necessary to perform a sinus floor augmentation if there is poor bone quality and insufficient alveolar process height. A sinus floor augmentation and significant pneumatization of the maxillary sinus are indicated in order to be able to use sufficiently long implants to guarantee the anchor in a region of high functional load.

In 1980, Boyne and James wrote the first publication on the treatment of patients with endosseous implants in combination with sinus floor elevation. Access to the maxillary sinus was by means of the intra-oral antrostomy and the preparation of a "bone window." This was then carefully advanced into the cavity and drawn. Therefore, a partial detachment of the Schneiderian membrane from the sinus floor was needed.

Subsequently, a bone graft was placed under the membrane and the opening was obturated again. Generally, the bone from the patients themselves was used as the graft. In a second step, several months after the sinus floor elevation, blade implants were successfully implanted. The prosthetic reconstructions existed in fixed or removable dentures, which were placed in the edentulous sections of the posterior maxilla.

Soon after, Tatum et al. worked on this surgical technique intensively, seeking to improve the results by means of modified procedures. Tatum Sun took on a key role in the development of the procedure for sinus floor elevation using an autogenous bone graft from the iliac crest for the preparation of the implant insertion (Tatum 1977, 1986).

Progress in the field of biomaterials and refined techniques and protocols for the rehabilitation of tooth loss by osseointegrated implants have increased the success rate and the predictability of implant treatment.

#### Xenogeneic grafts

To spare patients an additional removal of autogenous bone in other areas of the spine or of the iliac crest, bone substitute materials (xenogeneic grafts) are used increasingly today. Xenogeneic grafts now are mostly deproteinized (inorganic) bovine bone specimens. These grafts are used either alone or are mixed and used as part of a mixed transplant with autologous transplant patients and bone defect of the patient's blood.

The implant survival rate with the use of xenogeneic grafts is statistically equivalent to the use of particulated autogenous bone grafts. Del Fabbro et al. conducted studies on various bone replacement materials in 2004. Aghaloo and Moy 2007 found a survival rate of 88 percent in pure autologous transplants, 92 percent in mixed grafts with autologous bone, 81 percent in pure alloplastic grafts, 95.5 percent in pure allogeneic grafts and 95.6 percent in pure xenogeneic grafts was found.

These figures are encouraging for dentists and indicate a positive long-term prognosis for implant treatment in the distal maxilla. However, in esthetically challenging zones, an implant insertion without augmentation procedures is almost impossible to achieve, for only connective soft tissue aided by bone or graft material can contribute to esthetically satisfying results.

#### Placement of grafts and implants

The graft material should be inserted starting from the areas that are the most difficult to reach and contact with the bone walls must be ensured to improve the healing of bone. If the sinus membrane (Schneiderian membrane) is very thin, it should be protected and stabilized with a collagen membrane.

The recesses are first filled anteriorly and posteriorly, and thereafter the area of the medial sinus wall was filled too. The graft should not raise the membrane further and must not be compressed too much, as then vascularization particularly with biomaterial will be hampered. The implants are then successively inserted into the prepared implant cavities.

This achieves compaction of the loose cancellous tissue of the maxillary bone after the actual pilot hole with poor bone quality is achieved by means of bone-condensing instruments. This is also a useful and effective way to improve primary stability. After the insertion of the implants from the lateral side, the graft material is placed on the implants, all intermediate space and cavities are filled and the bone window is covered with a small collagen membrane.

The size of the collagen membrane should correspond to the existing bone window. The attachment can take place without the use of pins or absorbable sutures under the mucoperiosteal flap. New studies have shown that there are no differences between the results with the use of collagen membranes and those with membranes made of expanded polytetrafluoroethylene (ePTFE, GORE-TEX; Wallace et al. 2005). Because collagen membranes stick, they can be installed without screws or pins and, because of their absorbability, they do not have to be removed in a later procedure.

#### Suturing and wound care

For the final wound care, the defect is covered passively with the lobes. For this purpose, releasing incisions

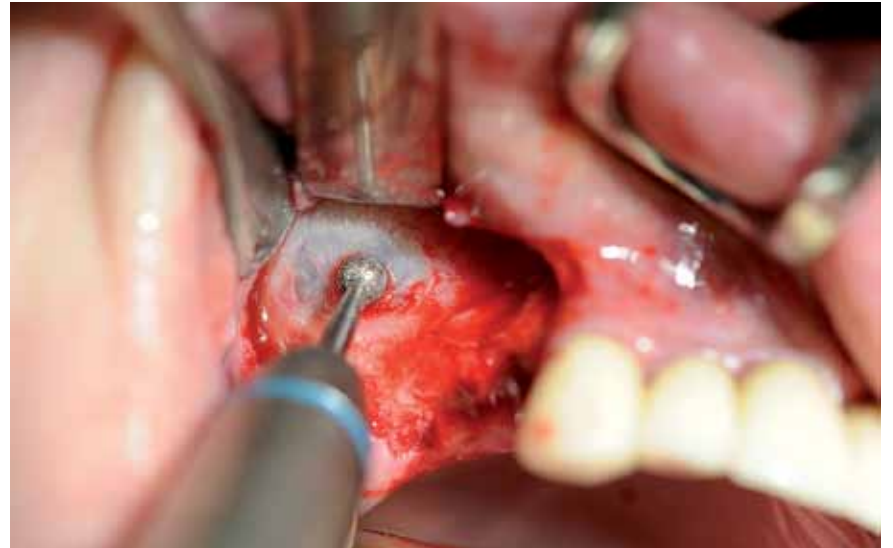

Fig. 5: Careful dissection of the Schneiderian membrane by the use of a diamond bur.

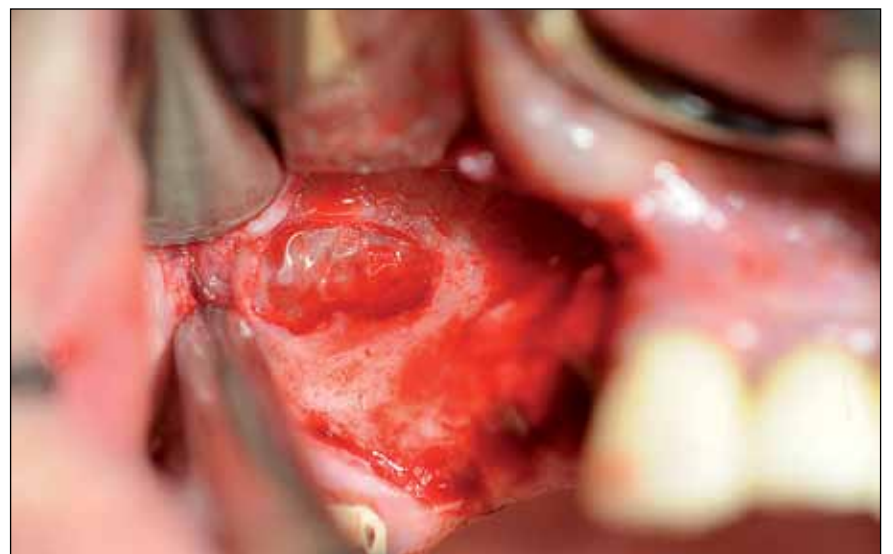


Fig. 6: Illustration of the intact Schneiderian membrane in region #16.

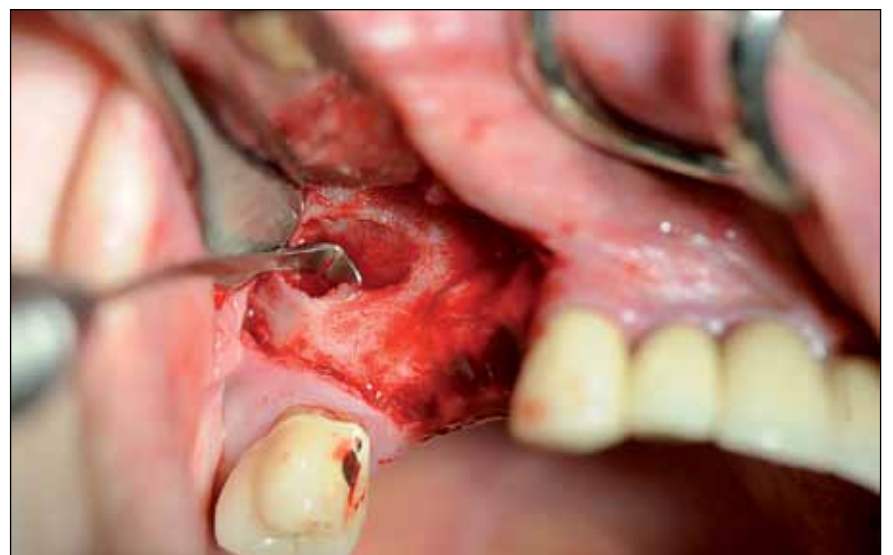

Fig. 7: Carefully solution of the Schneiderian membrane from lateral to caudal.

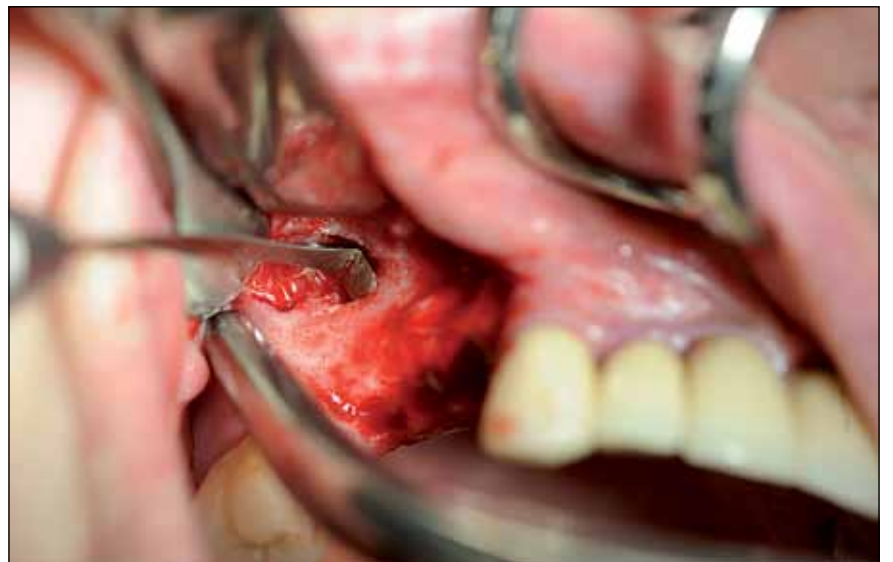
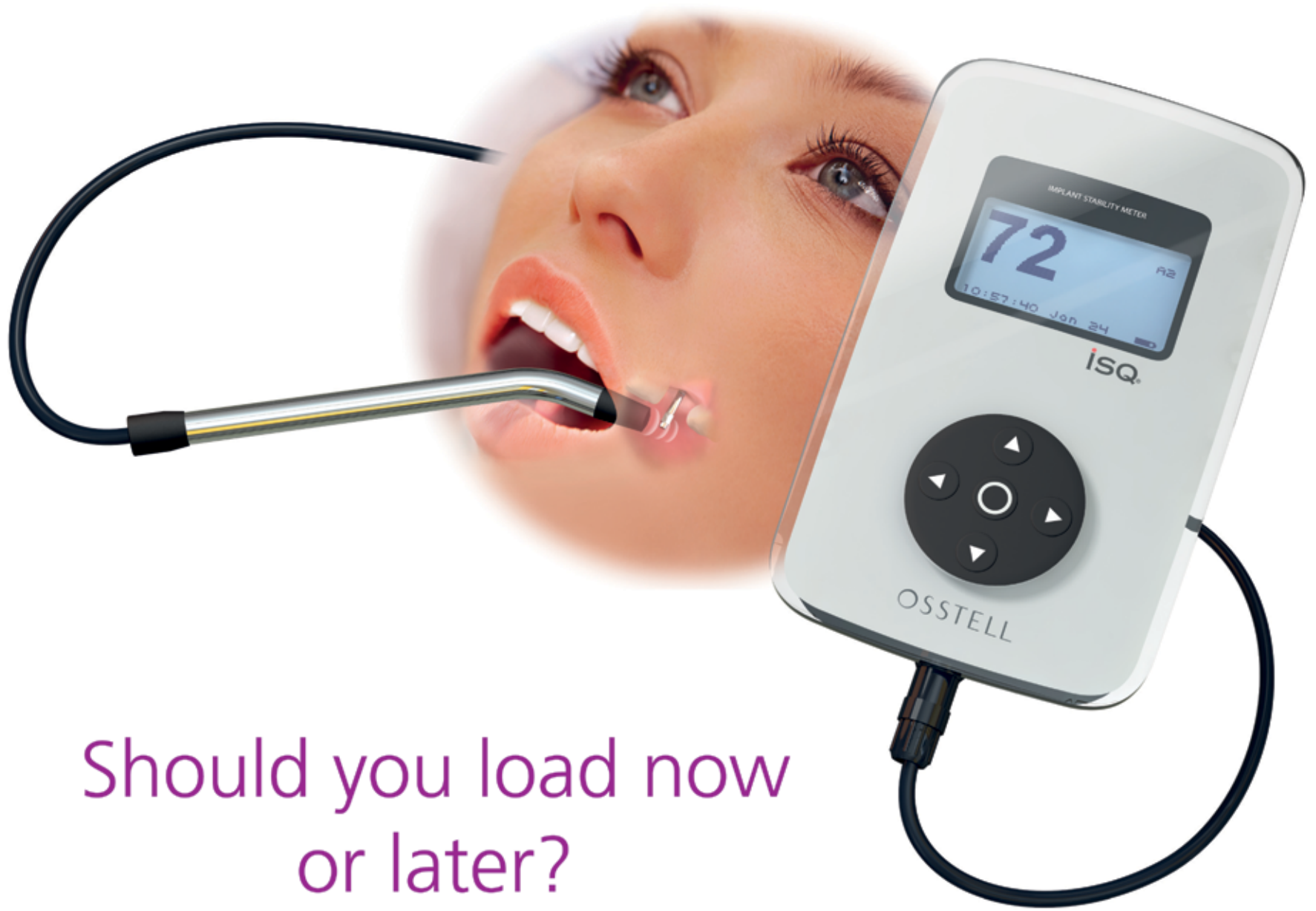
Fig. 8: Lifting and moving of the Schneiderian membrane.

→  page 7



## Should you load now or later? Or much later?

**Osstell ISQ** helps you make optimal implant loading decisions - whether you're doing immediate, traditional or delayed loading. By measuring before the final restoration, and comparing that value to the baseline value taken at placement, the decision on whether to load or not is made quick and easy.

You'll find it especially valuable when treating higher risk patients. Osstell offers the only objective quality assurance system that gives you an early warning if osseointegration isn't progressing as expected. With an objective ISQ-value, it's easy to explain treatment planning and healing times to your patients and colleagues.

You already have the experience and the judgement. Now Osstell brings you and your patient new certainty.

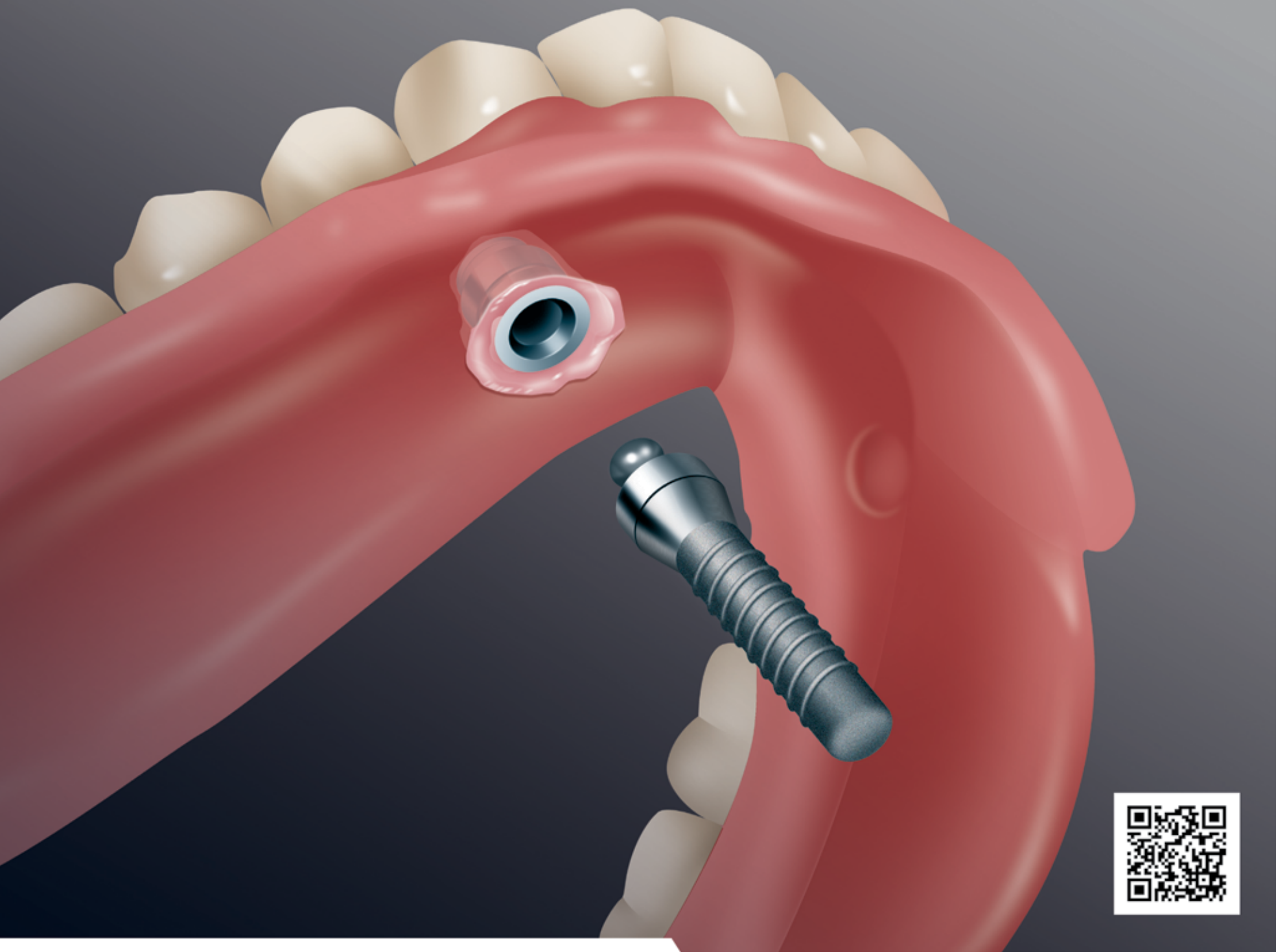
Visit Osstell at the  
Annual Meeting of the AAP  
Nov 12-15, Miami Beach, FL  
**booth #939**

US Customer Service 1-877-296-6177





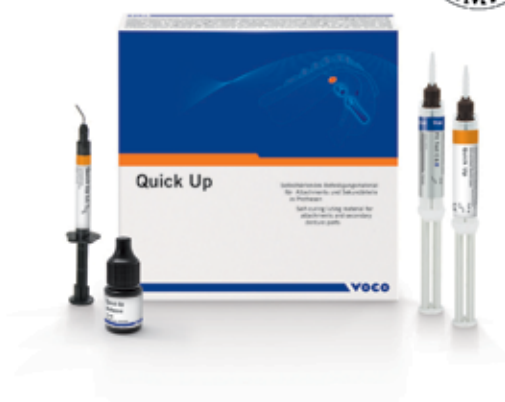# ELIMINATE INTERLOCKING WITH NEW QUICK UP METHOD



- Virtually eliminate the risk of interlocking with new Quick Up method: Work without vent holes and excess material removal; under fill with 2 min. fast setting self-cured material and finish with light-cured component
- 50% faster than classic method
- Complete system with checking and block out silicone – Fit Test
- Direct pick up results are more accurate compared to indirect method
- Low heat, self-curing material avoids tissue irritations
- Tasteless and odorless
- High bond strength to acrylic denture base

Call 1-888-658-2584

## Quick Up Implant Pick Up System





*‘Clinicians should always be open to learning new methods, but must do so with the responsibility to their patients in mind.’*

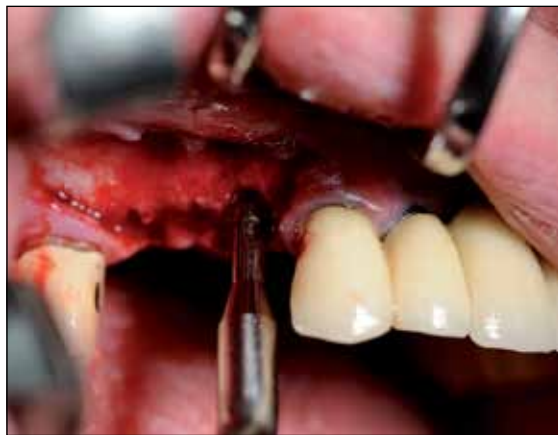

Fig. 9: Preparation of the implant cavity after pilot hole with bone-condensing instruments.

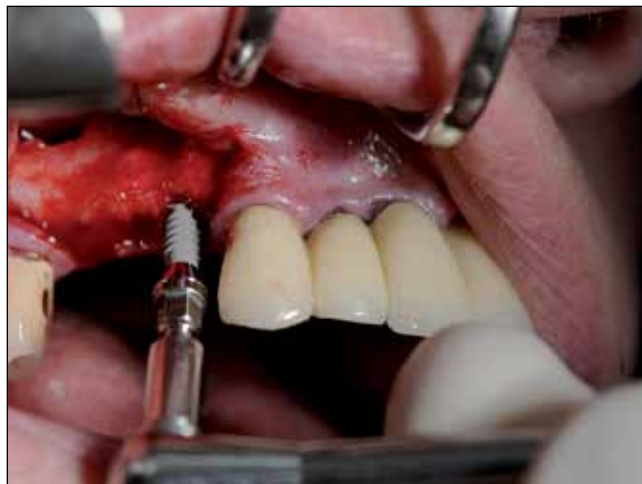

Fig. 10: Insertion of the implant in region #14.

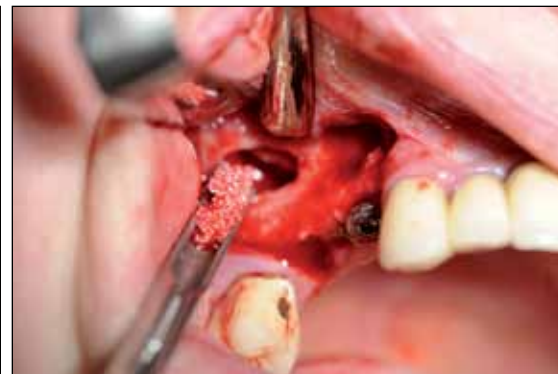

Fig. 11: After stabilization of the Schneiderian membrane, the Bio-Gide membrane is raised by the introduction of Bio-Oss granules (Geistlich), blood from the operation area and mixed with autologous bone chips of the patient.

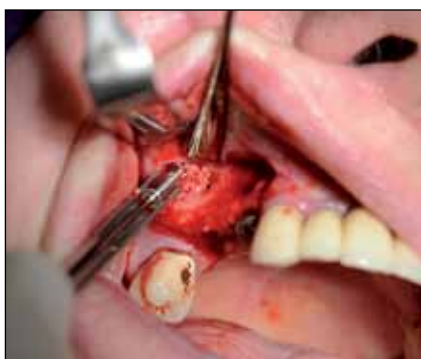

Fig. 12: Another gentle introduction of the augmentation in the Bio-Gide membrane before insertion of the dental implant in region #16.

← **ii** page 4

in the periosteal area is necessary. This method, however, is usually only necessary with simultaneous maxillary bone augmentation (for widening) because pure sinus floor augmentation does not change the ridge contour. The thread thickness can be specified from 4.0 to 6.0 mm with nonabsorbable monofilament.

**Summary**

It is generally in the interest of the patient to weigh the benefits of pure autologous grafts or some combination of autologous bone and the incorporation of synthetic bone materials and/or xenogeneic bone substitute materials. The use of foreign material leads to conservation of the patient’s own bone and avoids a second opening at a donor site, which creates an additional wound.

In principle, in treatment planning and advising clinicians must respect the patient’s desire that all surgical procedures proceed as smoothly, efficiently and, ultimately, as successfully as possible. It is through the combination of autologous bone grafts and foreign material, depending on the case and necessary use of membranes, that the long-term success of implant treatments is predictable. Clinicians should always be open to learning new methods, but must do so with the responsibility to their patients in mind.

→ **ii** page 9

AD

## Treat small spaces with confidence






Image courtesy of Michael Reddy, DDS      Image courtesy of Cary Shapoff, DDS

### Introducing the Laser-Lok® 3.0 implant

Laser-Lok 3.0 is the first 3mm implant that incorporates Laser-Lok technology to create a biologic seal and maintain crestal bone on the implant collar<sup>1</sup>. Designed specifically for limited spaces in the esthetic zone, the Laser-Lok 3.0 comes with a broad array of prosthetic options making it the perfect choice for high profile cases.

- Two-piece 3mm design offers restorative flexibility in narrow spaces
- Implant design is more than 20% stronger than competitor implant<sup>2</sup>
- 3mm threadform shown to be effective when immediately loaded<sup>3</sup>
- Laser-Lok microchannels create a physical connective tissue attachment (unlike Sharpey fibers)<sup>4</sup>



For more information, contact BioHorizons  
Customer Care: 888.246.8338 or  
shop online at [www.biohorizons.com](http://www.biohorizons.com)



**BIOHORIZONS**<sup>®</sup>  
SCIENCE • INNOVATION • SERVICE

<sup>1</sup> Radiographic Analysis of Crestal Bone Levels on Laser-Lok Collar Dental Implants. CA Shapoff, B Lahey, PA Wasserauf, DM Kim, IPRD, Vol 30, No 2, 2010.  
<sup>2</sup> Implant strength & fatigue testing done in accordance with ISO standard 14801.  
<sup>3</sup> Initial clinical efficacy of 3-mm implants immediately placed into function in conditions of limited spacing. Reddy MS, O’Neal SJ, Halgh S, Aporize-Wesson R, Geurs NC, Int J Oral Maxillofac Implants. 2008 Mar-Apr;23(2):281-288.  
<sup>4</sup> Human Histologic Evidence of a Connective Tissue Attachment to a Dental Implant. M Nevins, ML Nevins, M Carmelo, JL Hoyesen, DM Kim, International Journal of Periodontics & Restorative Dentistry, Vol. 28, No. 2, 2008.

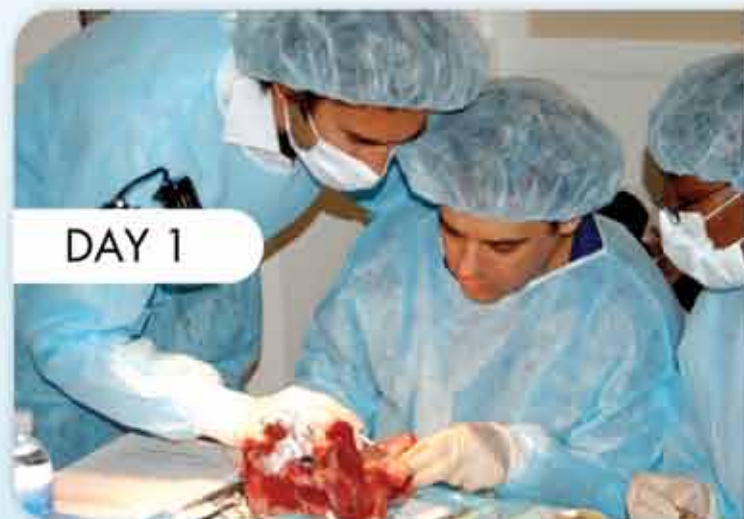SPMP10105 REV D SEP 2010



# gIDE TRAINING CENTER

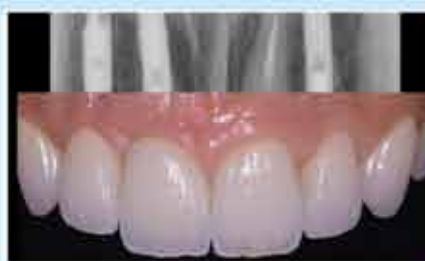## 4-Day Hands-On & Live Surgery in Los Angeles with Dr. Sascha A. Jovanovic

Learn the latest implant techniques. Each course has a didactic and a clinical hands-on and/or live patient surgery component. Courses can be taken separately or together as a comprehensive update program. This course is the best short-term implant program to get you to the next level in implant surgery and to improve your confidence level in hard and soft tissue grafting and the management of complications.



### SOFT TISSUE MANAGEMENT & GRAFTING AROUND DENTAL IMPLANTS

1-DAY LECTURE & HANDS-ON WORKSHOP

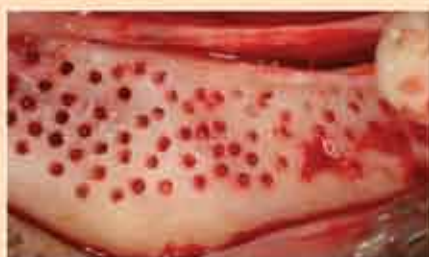

OCTOBER 25, 2011  
FEBRUARY 29, 2012  
MAY 30, 2012

Tuition: \$995

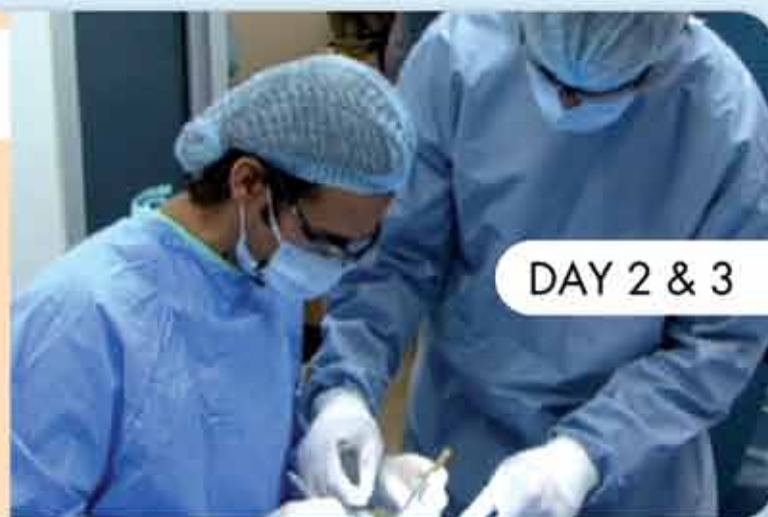### BONE, RIDGE & SOCKET GRAFTING

2-DAY LECTURE & HANDS-ON & LIVE SURGERY



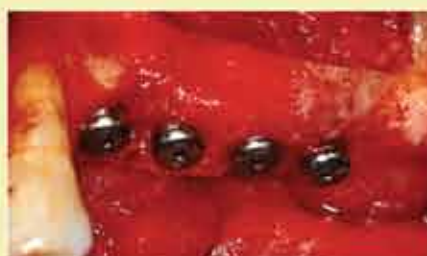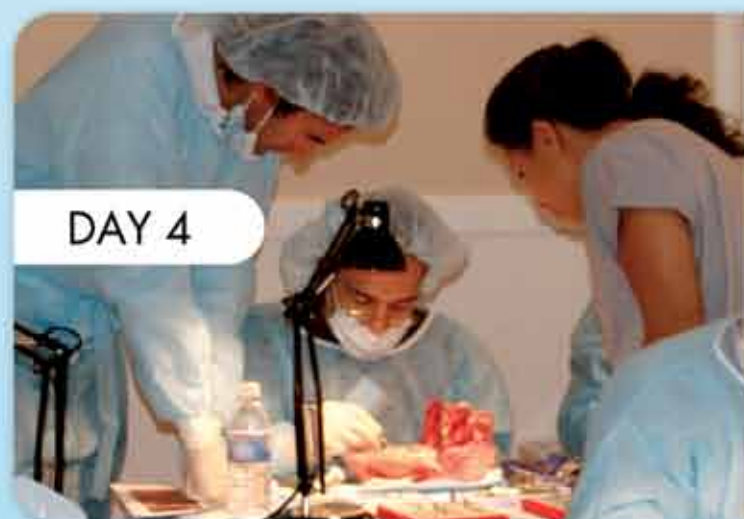OCTOBER 26 - 27, 2011  
MARCH 1 - 2, 2012  
MAY 31 - JUNE 1, 2012

Tuition: \$1995



### SINUS ELEVATION & GRAFTING

1-DAY LECTURE & HANDS-ON WORKSHOP



OCTOBER 28, 2011  
MARCH 3, 2012  
JUNE 2, 2012

Tuition: \$1195

4-day Tuition: \$4,185

4-day Tuition for Members: \$3,975.75

*"This one-of-a-kind sinus hands-on course raised my confidence level and success rate in sinus bone grafting and has expanded my overall expertise in these important procedures that I now perform regularly."*

- Dr. Phil Melnick, Periodontist, Cerritos, CA

Register Online at [www.gIEdental.com](http://www.gIEdental.com). Contact [info@gIEdental.com](mailto:info@gIEdental.com) or Call +1 310 696 9025



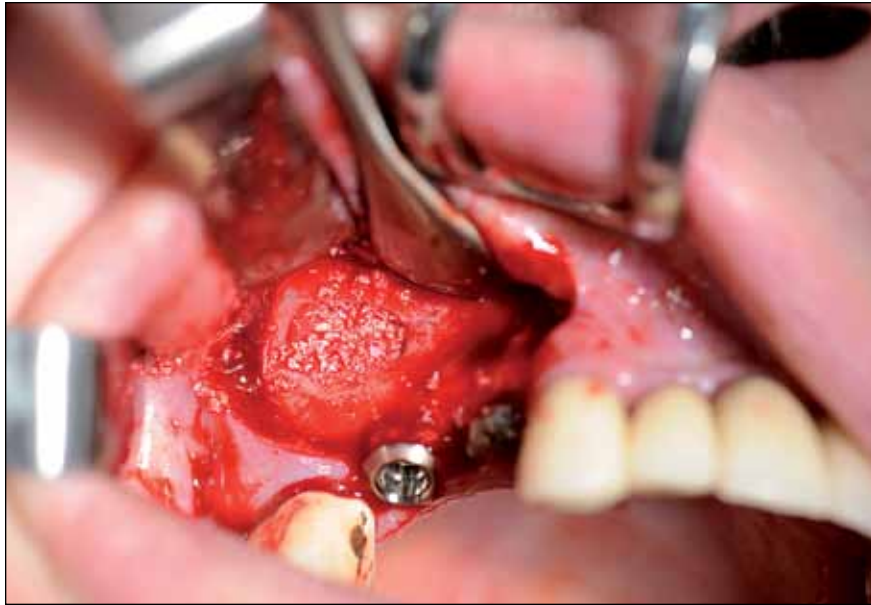

Fig. 13: After the insertion of the dental implant, loose filling with augmentation of the lateral side takes place.

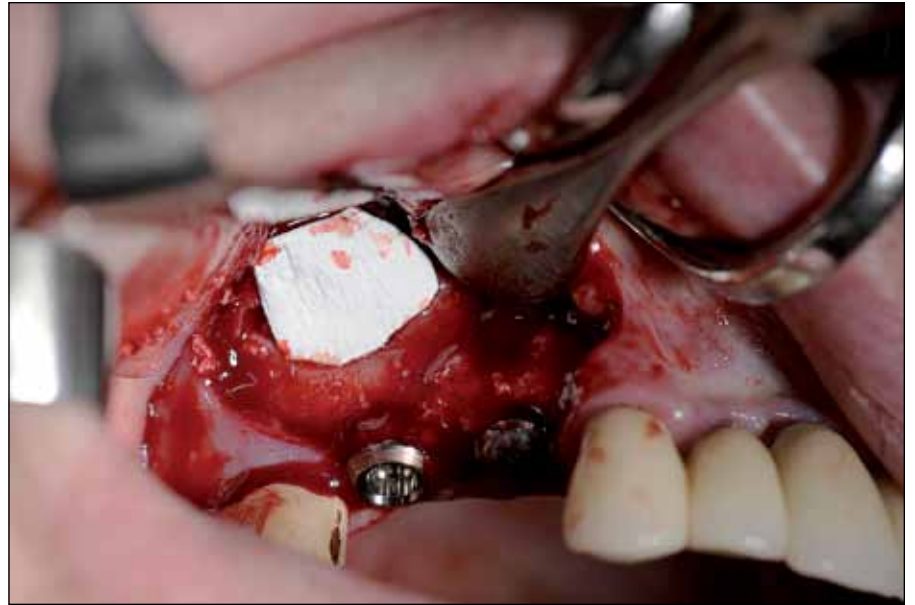

Fig. 14: Coverage of the facial bone defects with residual Bio-Gide membrane.

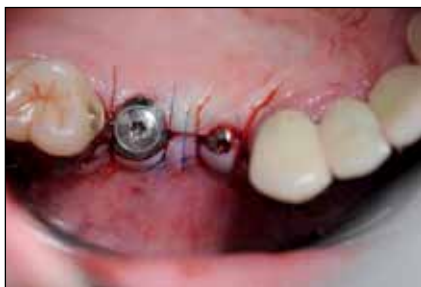

Fig. 15: State after wound closure and preparation of trans-mucosal healing of ITI-implants (Straumann Dental Implants).

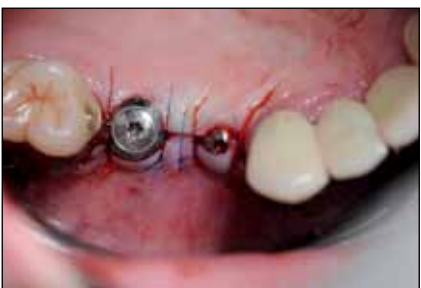

Fig. 16: X-ray after external sinus lift shows no displacement of the augmentation material in the maxillary sinus.

← **ii** page 7

The demands of today's patients are constantly growing and so the management of hard and soft tissues is of crucial importance for dental implantology. The current augmentation procedure provides a well-supported and physiologically shaped gingiva in the adjacent implant shoulder and super-structure area and thus provides an indispensable basis for esthetic long-term success.

Knowledge and mastery of augmentation is essential for ensuring long-term success and makes the use of endosseous implants possible in the first place. **ii**

**ii** Contact

Dr. Frank Liebaug  
 Arzbergstraße 30  
 98587 Steinbach-Hallenberg, Germany  
 Tel.: +49 36847 31788  
 frankliebaug@hotmail.com

AD

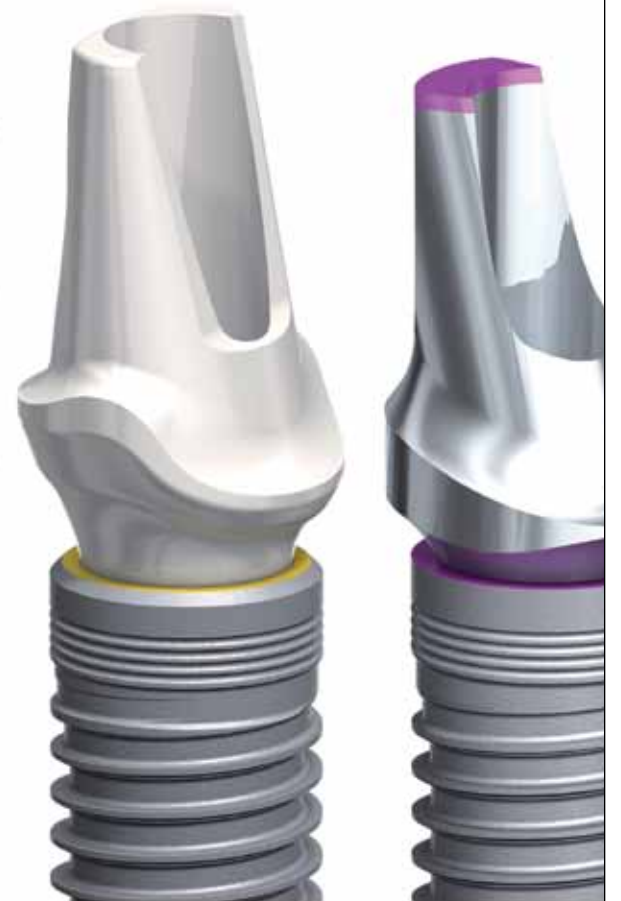More options,  
 same original body.

Two new connections  
 to choose from.

Designed to maximize  
 soft tissue volume.

Established and clinically proven  
 tapered implant body.

**NEW** With platform  
 shift and conical  
 connection



They're called NobelReplace Conical Connection and NobelReplace Platform Shift. Broaden your restorative options while keeping the benefits of the clinically proven NobelReplace Tapered implant, such as color-coded components and standardized step-by-step drill protocol for ease-of-use and predictable outcomes. Developed for restorations in the esthetic region, NobelReplace Conical Connection combines platform shifting with

a strong sealed connection, whereas NobelReplace Platform Shift offers platform shifting on the internal tri-channel connection with its unrivalled tactile feel. After 45 years as a dental innovator we have the experience to bring you future-proof and reliable technologies for effective patient treatment. **Their smile, your skill, our solutions.**



Call 800 322 5001 or visit  
 nobelbiocare.com/replaceccps



Nobel Biocare USA, LLC, 22715 Sawi Ranch Parkway, Yorba Linda, CA 92887, Phone 714 282 4800; Toll free 800 993 8100; Tech. support 888 725 7100; Fax 714 282 9023  
 Nobel Biocare Canada, Inc., 3133 Leslie Street, Unit 100, Richmond Hill, ON L4B 4N1; Phone 905 762 3500; Toll free 800 939 9394; Fax 905 762 3500  
 © Nobel Biocare Services AG, 2011. All rights reserved. Nobel Biocare, the Nobel Biocare logo and all other trademarks are, if nothing else is stated or is evident from the context in a certain case, trademarks of Nobel Biocare. Disclaimer: Some products may not be regulatory cleared/released for sale in all markets. Please contact the local Nobel Biocare sales office for current product assortment and availability. 1 Dental Product Shopper voted NobelReplace Tapered Best Product 2011. www.dentalproductshopper.com/nobelreplace