

cosmetic dentistry

— beauty & science

4²⁰¹¹

| **case report**

Cosmetic periodontal surgery

| **clinical technique**

Clinical application of a new flowable base material for direct and indirect restorations

| **industry report**

Professional in-office whitening of non-vital teeth

دانشگاه

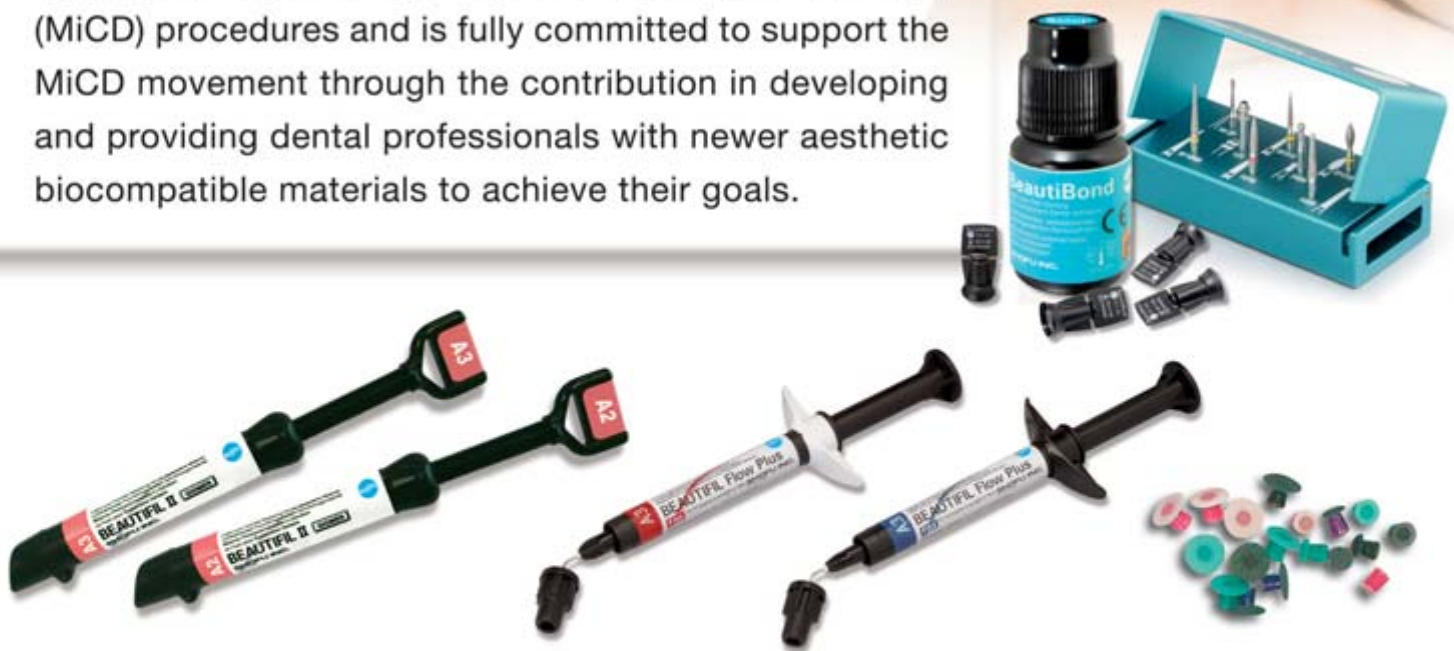

Adopt the trend...



Minimally Invasive
Cosmetic Dentistry

SHOFU recognizes the development of new clinical techniques in minimally invasive cosmetic dentistry (MiCD) procedures and is fully committed to support the MiCD movement through the contribution in developing and providing dental professionals with newer aesthetic biocompatible materials to achieve their goals.



For more information, simply contact your nearest **SHOFU** dealer.



SHOFU INC. SINGAPORE BRANCH

Tel (65) 6377 2722 Fax (65) 6377 1121 eMail mailbx@shofu.com.sg website www.shofu.com.sg

Dear Reader,

_Welcome to our fourth and final issue of 2011. I hope you have had a wonderful year in terms of your health, progress and prosperity!

The year 2011 was a very important one for aesthetic dentistry. The International Federation of Esthetic Dentistry, an apex body of aesthetic academies around the world, recently organised its seventh biennial scientific meeting in Rio de Janeiro in collaboration with the Brazilian Society of Aesthetic Dentistry. As executive council member and guest speaker at the meeting, I was excited to note the global trend towards cosmetic dentistry. With more than 1,100 registrations and delegates from all around the world, the meeting was very successful in sharing knowledge and experiences about the cosmetic dental practice in different parts of world. There were 42 oral presentations from the UK, Germany, Nepal, Greece, Korea, Japan, Italy, Israel, Belgium, Switzerland, the USA and host country Brazil. High quality clinical cases—many of them with a focus on excellence, precision and quality aesthetic case finishing—were presented by world-class clinicians.


As I have been advocating minimally invasive cosmetic dentistry for many years, it was quite exciting for me to note that almost all speakers mentioned the role of and their concern with the biological cost of the treatment they provide. Today, the Hollywood Smile concept is slowly fading. Aesthetic dentists are focusing on customised smile design with respect to naturo-mimetic dentistry and are applying minimally invasive approaches.

However, I have also noticed that while aesthetic case finishing and excellence in visual elements are in focus, invisible components, like occlusal forces, are not. Force finishing—balanced bite forces with harmonised teeth contact timing—is the missing link in cosmetic dentistry and must be incorporated to achieve long-term health, function and aesthetics of the cosmetic work that we perform.

I personally foresee that apart from aesthetic results, harmonised teeth, muscles and joints (TMJ) will become the major criteria in the future to evaluate clinical success in cosmetic dentistry. The value of function in achieving aesthetics will be better understood and slowly, the concept of TMJ harmony will be implemented in cosmetic dentistry for the true promotion of naturally pleasing, functionally balanced and healthy smiles for our patients.

In this issue, we have gathered various clinical articles related to your clinical practice and I hope you will enjoy them.

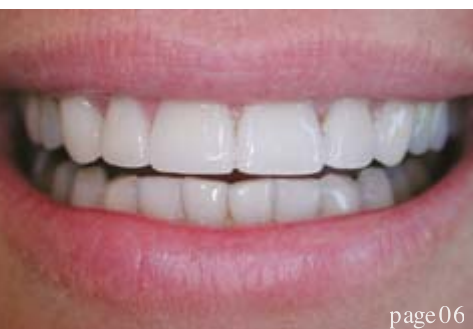Yours faithfully,



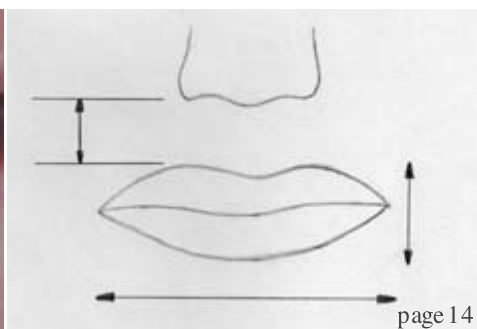
Dr Sushil Koirala
Editor-in-Chief
President Vedic Institute of Smile Aesthetics (VISA)
Kathmandu, Nepal



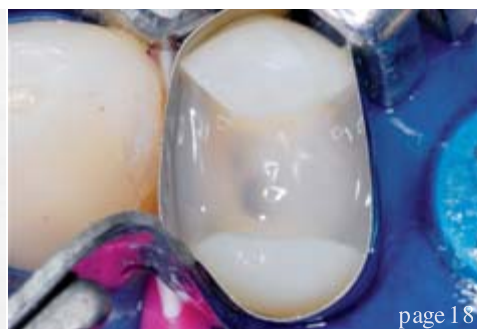Dr Sushil Koirala
Editor-in-Chief



page 06



page 14



page 18

| editorial

03 **Dear Reader**

| Dr Sushil Koirala, Editor-in-Chief

| case report

06 Making a **single veneer** blend so naturally that it's **undetectable**

| Dr L. Emery Karst

10 Cosmetic periodontal surgery: **Multiple gingival graft techniques (Part II)**

| Dr David L. Hoexter

| special

14 Aesthetic guidelines for **natural-looking dentures**

| Björn Maier

| clinical technique

18 Clinical application of a **new flowable base material** for direct and indirect restorations

| Prof Peet van der Vyver

| practice management

24 **Connectivity** in the **dental world**

| Shane Hebel

| industry report

28 **CLEARFILE ESTHETIC CEMENT** for crowns and bridges

| Dr Harry Denissen & Thomas Reiter

34 **Professional in-office whitening** of non-vital teeth

| Dr Ludwig Hermeler

36 **Anterior tooth restoration** — An exciting experience

| Dr David Hacmoun

38 **Simplifying direct composite resin restorations** in the aesthetic zone

| Dr Ian E. Shuman

| industry news

42 **The new PANA VIA POST** — Long-lasting and reliable

| Kuraray

| meetings

44 **DFCIC** — Where science meets the art of beauty

| Dr Dobrina Mollova

46 You really **don't have to** leave Europe!

| Dr Philip Lewis

48 **International Events**

| about the publisher

49 | submission guidelines

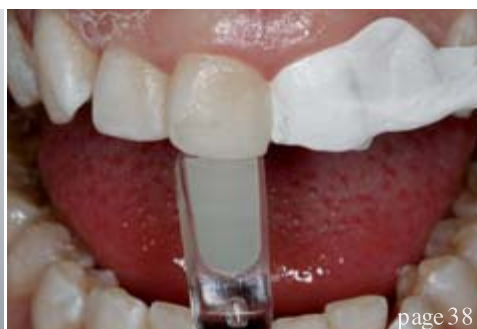50 | imprint



Cover image courtesy of Ekaterina Pokrovskaya.



page 28



page 38



page 44

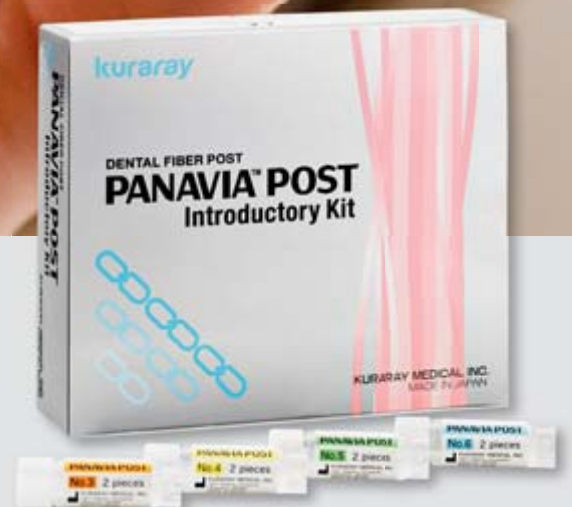Some things last forever.

PANAVIA™ POST

The new glass fiber post with excellent mechanical durability – your solution for long-lasting, reliable restorations.

PANAVIA™ POST is a fiber post made of resin reinforced glass fibers with high mechanical durability and an optimal elastic modulus for your reliable restorations. This effect is achieved thanks to Kuraray's unique monomer technology and surface treatment technology.

While other posts will lose their stability inside the post and might break, PANAVIA™ POST stays strong and stable – due to a strong adhesion between the glass fiber and the resin.

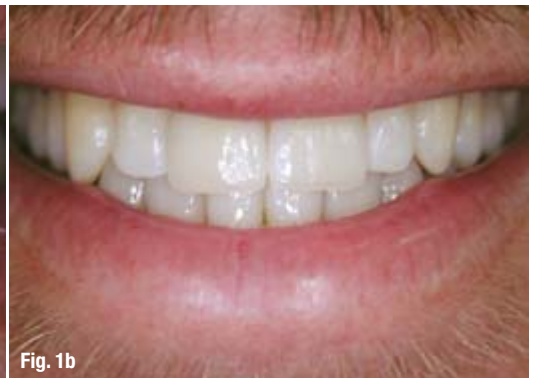
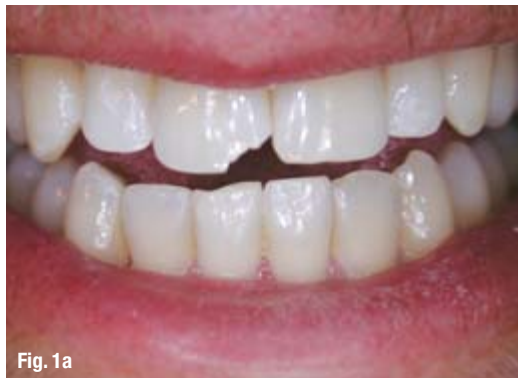
Your benefits:

- ✓ Excellent mechanical durability of long-term restoration
- ✓ Low risk of debonding and root fracture
- ✓ Esthetic restoration and ideal light-curing property

Making a **single veneer** blend so naturally that it's **undetectable**

Author_ Dr L. Emery Karst, USA

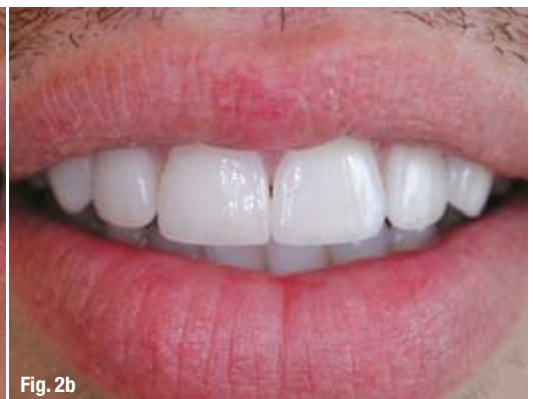
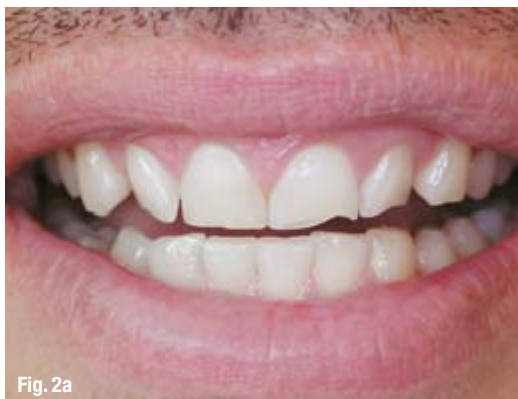
As patients get older, anterior teeth commonly show wear, chipping and discoloration. These changes are the result of a number of factors associated with ageing. There is increased awareness of these unattractive teeth and the desire to have a more youthful appearance. Because of the recent media attention on changing one's appearance with veneers, there is a much greater demand for cosmetic dentistry procedures.

Over the years in the practice of dentistry, I have developed products and techniques that

have improved my practice significantly. However, it was not until I took on an associate, who had been in practice for 18 years that I became aware that these were new and innovative ideas to him, as well as to other dentists he knew.

I have been placing veneers for more than 25 years and developed a technique that can make a single veneer blend so naturally with the other teeth that it is undetectable. Various nuances in technique make preparing and bonding veneers quick and easy.



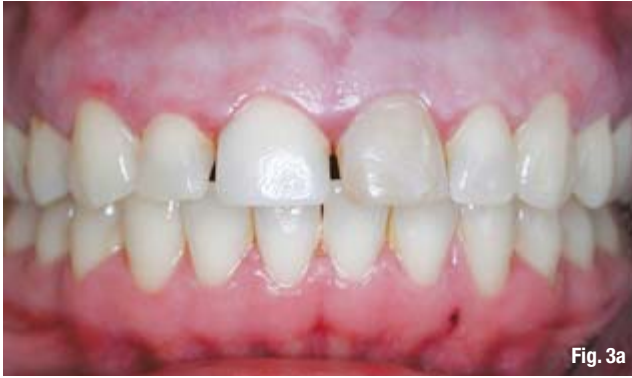

Fig. 3a

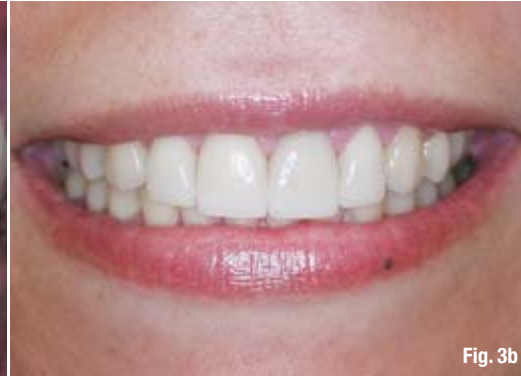

Fig. 3b

I have a CEREC machine that works especially well for a single veneer. Six or eight veneers can be done on the CEREC, but this is then rather time consuming. Two or three cases of the same number of teeth could have been prepared, impressions taken and sent to a laboratory in the same period. It is more cost effective to use a laboratory but you have to have the best laboratory available to you if you expect perfect results.

Feldspathic porcelain is the only material that will look natural. Pressed ceramics will look more opaque, somewhere between a porcelain-fused-to-metal restoration and a natural tooth. For patients requesting brilliant white, feldspathic porcelain can work well too and one can adjust the colour by the bonding composite used under the veneer.

Very little shade adjustment can be done under pressed ceramic porcelain. Flowable composites work the best and come in many shades, which makes shade adjustments easy. The flowable composite by Kerr has the right consistency for veneers and with OptiBond Solo the company offers the strongest bonding agent.

The preparation requires only a little more than 0.5 mm of reduction so that it does not go through the enamel, if possible. The bond is

the best on enamel. There should be the same reduction over the total facial surface for the laboratory to make a perfect veneer. Cut three or four depth grooves of 0.5 mm then remove the enamel to the grooves.

If instant orthodontics is the treatment plan, some teeth may need to be reduced more and others less. Run the preparation interproximally from gingival to incisal to hide the margin visually, but do not break the contact point.

The gingival margin should be at the gingival crest or a little below. It should have a chamfer for ease of finishing, precluding any chipping at the margin. Some dentine will show through at the gingival margin because the enamel is less thick there. If there is room, insert a thin piece of gingival braid, which can be left there during the impression. Reduce the incisal by approximately 1 mm so the finish line is on the lingual, and round the incisal-facial junction so that there are no potential fracture lines in the veneer.

When the veneers come back from an excellent laboratory there should be little or no adjustments necessary before bonding them to the teeth. Etch them with hydrofluoric acid gel for at least three minutes. Rinse them thoroughly, neutralise them with a baking-soda slurry and

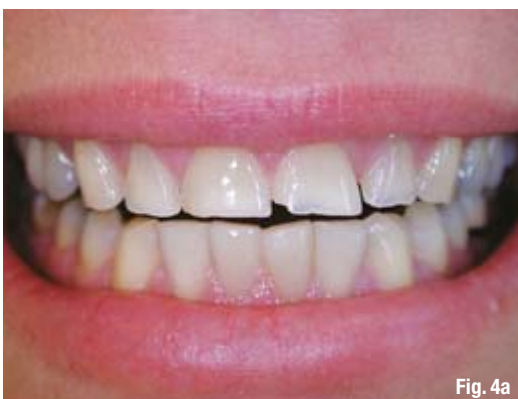

Fig. 4a

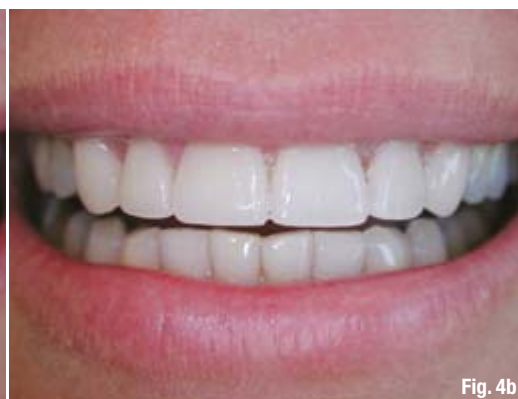

Fig. 4b

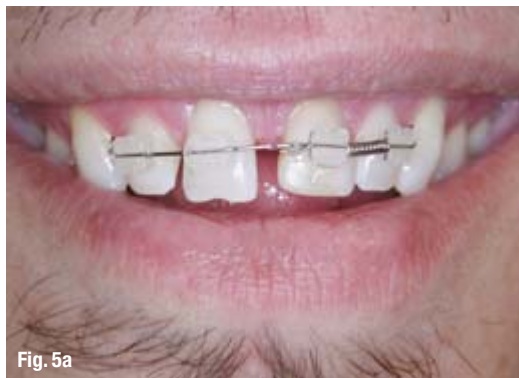

Fig. 5a

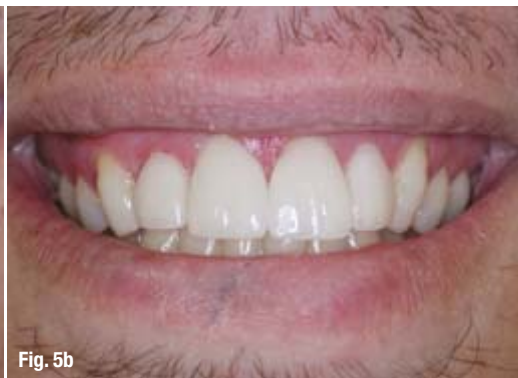

Fig. 5b

then rinse them thoroughly again. Dry them with a dry air source until a chalky appearance is visible on the interior of the veneer.

Ceramic primer is then applied for one minute. Dry until it is chalky again and apply another coat of ceramic primer. Leave the primer on while the teeth are etched with phosphoric acid gel for 30 seconds. Rinse thoroughly and dry the teeth and veneers until a chalky appearance shows on both.

Turn the operatory light off and then apply bonding to the teeth and the veneers. Place the flowable composite onto the veneers one at a time for placement. Place all of the veneers and ensure they are correctly situated.

With two hands, hold the distal two veneers (teeth #5 and 6) in place leaving a space only large enough for a curing light to shine in between. Shield the rest of the veneers with your hand so that the light will not set any of the other composite except the interproximal space between veneers #5 and 6. Cure for only two seconds. Now cure the distal of veneer #5 for two seconds.

Move your hands to veneers #6 and 7, shielding the rest of the veneers and holding veneer #5 and 6 in place, leave just enough room to cure the space between #5 and 6 for two seconds. Repeat the same process for the rest of the veneers, moving from #7 to 8 and so on, until all of the interproximal spaces have been cured for two seconds each, including the distal of the last veneer on the other side.

Now cure the centre of each veneer for two seconds and then the lingual incisal of each for two seconds too. If cured for longer than this, it is very difficult to remove the excess composite and much time is consumed in the process.

The first step in removing the excess composite is the use of a Bard-Parker #12 scalpel. With a palm grasp and your thumb resting on the incisal edge of a tooth, engage the flat side of the blade close to the incisal edge and push gingivally to loosen the interproximal composite.

Continue until most of the composite has been loosened and removed. Use a Wedelstadt chisel in the same fashion to loosen the gingival composite. To break the contact, a serrated interproximal strip is used in a cross-cut sawing fashion.

The Bard-Parker #12 scalpel is used again to remove more interproximal composite. Blue-tipped diamond strips are then used to remove any remaining composite and a yellow-tipped diamond strip is used to smooth. Adjust the bite, polish and you are done. Figures 1a to 5b demonstrate the good results of the technique described in this article.

_about the author

cosmetic
dentistry



Dr L. Emery Karst, a graduate of Loma Linda University's School of Dentistry, has been practising the art of cosmetic dentistry for more than 20 years. Although he enjoys cosmetic dentistry the most, he also regularly

undertakes work in endodontics, implants, crown and bridge and other techniques. Dr Karst's articles on endodontics and cosmetic techniques have been published in *Dentistry Today*. He also lectured on endodontics at the Oregon State Dental Convention in 2010.

Dental Tribune for iPad – Your weekly news selection

Our editors select the best articles and videos from around the world for you every week. Create your personal edition in your preferred language.

ipad.dental-tribune.com

