

cosmetic dentistry

— beauty & science

2²⁰¹¹

| **MICD**

Computer-guided occlusal
force management

| **research**

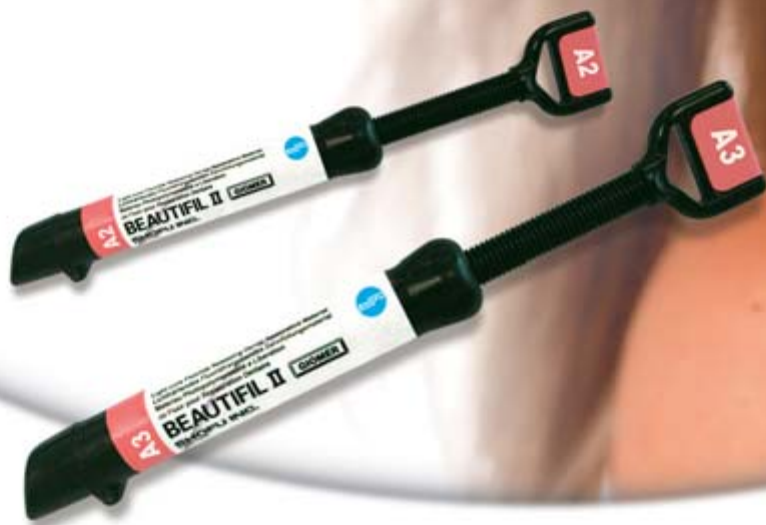Investigation of enamel
following bleaching

| **industry report**

Compobond: Evolution of a new
restorative dental material

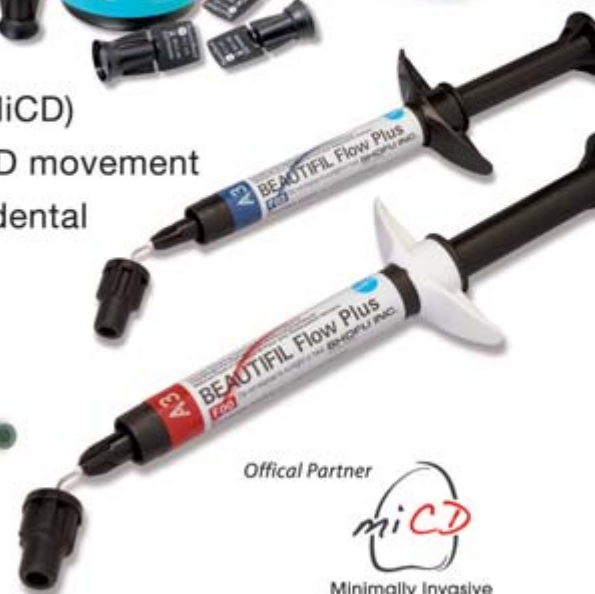0277113

Adopt the trend...



SHOFU recognizes the development of new clinical techniques in minimally invasive cosmetic dentistry (MiCD) procedures and is fully committed to support the MiCD movement through the contribution in developing and providing dental professionals with newer aesthetic biocompatible materials to achieve their goals.

For more information, simply contact your nearest SHOFU dealer.



Official Partner



SHOFU INC. SINGAPORE BRANCH

Tel (65) 6377 2722 Fax (65) 6377 1121 eMail mailbx@shofu.com.sg website www.shofu.com.sg

Dear Reader,


_Welcome to this year's second issue of **cosmetic dentistry**! I hope you enjoyed our first issue. All editions of **cosmetic dentistry** are available online at www.dental-tribune.com at no charge.

With the rapid development of global information technology, knowledge has become much more accessible to everyone keen to acquire it. Online continuing education (CE) programmes are quite popular now in most countries, as it is an easy-to-access and affordable mode for CE. Global online CE programmes are gaining popularity amongst young generations. However, CE accreditation systems have yet to become mandatory in most Asian countries. There are various online CE models, including text lectures, slide shows, recorded movies and live web seminars—webinars. Online study clubs, such as the Dental Tribune Study Club (www.dtstudyclub.com), and forums are very popular for sharing knowledge and skills in dentistry.

In February 2011, I travelled to Chicago to participate in the International Federation of Esthetic Dentistry (IFED) general assembly and executive council meeting. I am pleased to announce here that the general assembly unanimously passed the resolution of the executive committee to start a free e-learning system through the IFED website (www.ifed.org). Furthermore, I was nominated as project coordinator. Once the project has been completed, I believe it will help many young professionals to acquire quality aesthetic dentistry education free of charge. As the coordinator, I am now working at developing professional links amongst various aesthetics magazines and journals around the world, and am seeking quality articles/clinical cases from authors and clinicians for our e-learning section. I invite all of you to share your knowledge and skills for better patient care around the world.

For this issue of **cosmetic dentistry**, we have selected various clinical articles for you and hope they will help to advance your clinical excellence. Enjoy!

Yours faithfully,



Dr Sushil Koirala
Editor-in-Chief
President Vedic Institute of Smile Aesthetics (VISA)
Kathmandu, Nepal



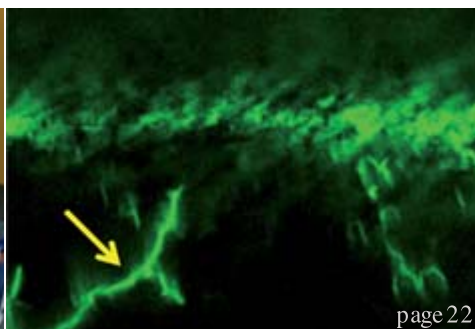
Dr Sushil Koirala
Editor-in-Chief



page 06



page 20



page 22

| editorial

03 **Dear Reader**
| Dr Sushil Koirala, Editor-in-Chief

| MICD

06 **Healthy and harmonised function** via computer-guided occlusal force management
| Dr Robert Kerstein

| case report

14 **A banker's bond: When less is more**
| Dr Sarah Kong

| news

18 **Wanted: Whiter, brighter teeth**
| American Academy of Cosmetic Dentistry

20 **iPad in business: Advancing digital dentistry**
| Apple Inc.

| research

22 **Confocal microscopy investigation** of enamel subsurface structure following bleaching
| Prof Daniel C. N. Chan *et al.*

| industry report

26 **Compobond: Evolution** of a new restorative dental material
| Dr Irfan Ahmad

38 **One step closer to nature: Imitating** natural optical properties using **lithium-disilicate restorations**
| Dr Bradley L. Jones

| industry news

42 **Happy Birthday Pola!**
| SDI

| meetings

44 **Record-breaking IDS 2011**
| Yvonne Bachmann

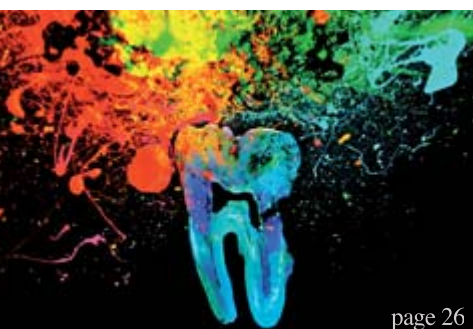
48 **International Events**

| about the publisher

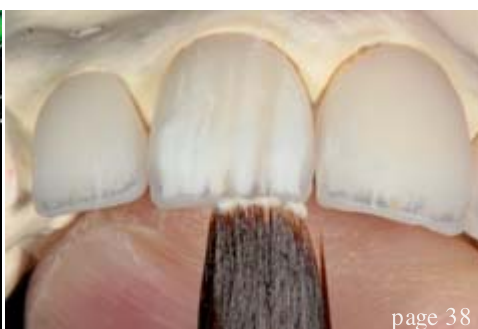49 | submission guidelines
50 | imprint



Cover image courtesy of Leonid and Anna Dedukh.



page 26



page 38



page 44



ANNUAL DENTAL TRIBUNE STUDY CLUB

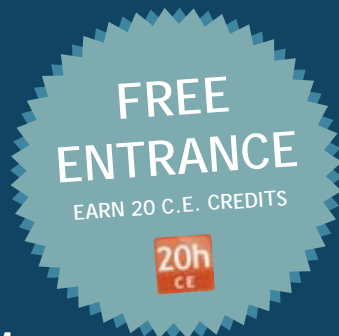SYMPOSIA AT THE GNYDM

NOVEMBER 27TH - 30TH, 2011, STARTING AT 10:00 AM DAILY



For the fourth year in a row, Dental Tribune Study Club hosts its annual C.E. Symposia at the GNYDM, offering four days of focused lectures in various areas of dentistry. Find us on the Exhibition Floor!

Each day will feature a variety of presentations on topics, which will be led by experts in that field. Participants will earn ADA CERP CE credits for each lecture they attend. DTSC is the official online education partner of GNYDM.



PLEASE SEE PROGRAM DETAILS UNDER WWW.DTSTUDYCLUB.COM/GNYDM

REGISTER NOW: WWW.GNYDM.COM

FREE FOR REGISTERED GNYDM ATTENDEES, BUT PRE-REGISTRATION IS RECOMMENDED.

For more information, please contact Julia E. Wehkamp, C.E. Director, Dental Tribune Study Club
Phone: (416) 907-9836, Fax: (212) 244-7185, E-mail: j.wehkamp@DTStudyClub.com



SUNDAY, NOVEMBER 27



10:00 - 11:00 DR. HOWARD GLAZER
GIOMERS: NEW GIANTS OF MI DENTISTRY



11:15 - 12:15 DR. SHAMSHUDIN KHERANI
COMPREHENSIVE DENTISTRY USING DIGITAL IMPRESSION TECHNOLOGY



12:45 - 1:45 DR. RON KAMINER
MINIMALLY INVASIVE DENTISTRY: TIPS AND TRICKS TO MAXIMIZE SUCCESS



2:00 - 3:00 DR. LOUIS MALCMACHER
THE HOTTEST TOPICS IN DENTISTRY



3:15 - 4:15 TBA
TECHNOLOGY TO IMPROVE YOUR CARIES MANAGEMENT



4:30 - 5:30 DR. GEORGE FREEDMAN
EVOLVING CONSERVATIVE RESTORATIONS

MONDAY, NOVEMBER 28



10:00 - 11:00 DR. FAY GOLDSTEP
WHAT PATIENTS WANT... WHAT DENTISTS WANT: EASY, HEALTHY DENTISTRY!



11:15 - 12:15 DR. SHAMSHUDIN KHERANI
LASER DENTISTRY OVERVIEW WITH AN UPDATE ON CLOSED FLAP OSSEOUS



12:45 - 1:45 DR. LARRY EMMOTT
REMEMBER WHEN "E" WAS JUST A LETTER? USE E-SERVICES TO IMPROVE PATIENT CARE AND INCREASE PROFITABILITY



2:00 - 3:00 DR. GEORGE FREEDMAN AND DR. FAY GOLDSTEP
DIODE LASERS AND RESTORATIVE DENTISTRY



3:15 - 4:15 DR. DAMIEN MULVANY
WHY VIEW YOUR 3D PATIENTS WITH 2D IMAGES? A COMMON SENSE APPROACH TO 3D IMAGING IN THE GENERAL PRACTICE



4:30 - 5:30 DR. MARTY JABLOW
UNDERSTANDING THE ADVANCES IN SELF-ADHESIVE TECHNOLOGY AND HOW TO INCORPORATE THEM INTO YOUR RESTORATIVE PRACTICE


TUESDAY, NOVEMBER 29



12:45 - 1:45 DR. GEORGE FREEDMAN AND DR. FAY GOLDSTEP
THE DIODE LASER: THE ESSENTIAL SOFT TISSUE HANDPIECE



11:20 - 12:20 DR. GEORGE FREEDMAN AND DR. PAT ROETZER
CEMENTING ALUMINA AND ZIRCONIA RESTORATIONS



12:30 - 5:00 **OSSEO SUMMIT**
DR. DAVID HOEXTER,
ALONG WITH VARIOUS IMPLANT EXPERTS
THE 2ND ANNUAL OSSEO UNIVERSITY SUMMIT: REVOLUTIONARY IMPLANT DESIGN UNVEILED

Healthy and harmonised function via computer-guided occlusal force management

Author _ Dr Robert Kerstein, USA

Fig. 1a _ A smile defect of discoloured teeth and presence of a diastema.

Fig. 1b _ Four anterior veneers placed to improve smile defects.

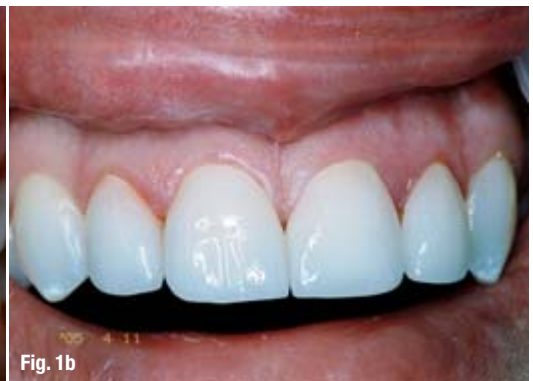
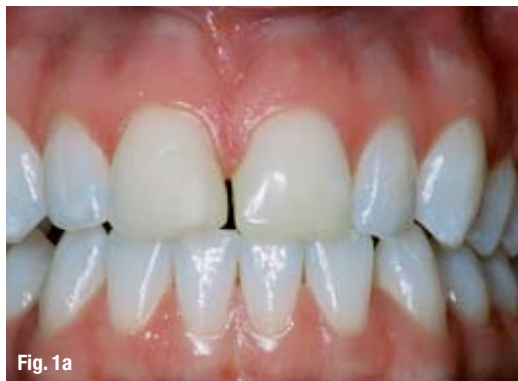
Fig. 2 _ Smile Design Wheel that incorporates patient psychology, health, function and aesthetics.

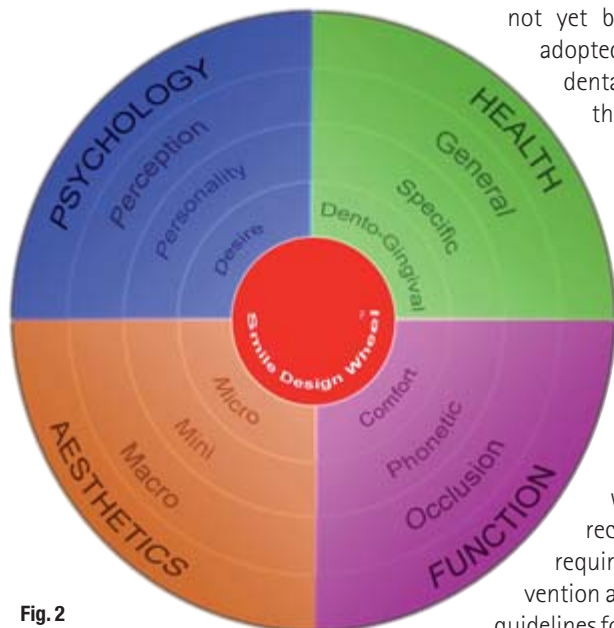


Fig. 2

The minimally invasive (MI) concept was initially introduced in physical medicine and adopted into dental medicine in the early 1970s with the application of diamine silver fluoride to teeth.¹ This was followed by the development of preventive resin restorations (sealants) in the 1980s² and the atraumatic restorative treatment (ART) approach³ with Carisolv (MediTeam) in the 1990s.⁴ Since its inception, the focus of MI dentistry has been caries detection and treatment.⁵ It has

not yet been comprehensively adopted in other fields of dental medicine; however, the comprehensive concept of minimally invasive cosmetic dentistry (MICD) and its treatment protocol were introduced in 2009 with the basic aim of a clinician effecting optimum clinical therapeutic improvements in smile enhancement, while performing corrective procedures that require as little clinical intervention as possible.⁶ Additional guidelines for MICD treatment are:

- _ the adoption of the "Do No Harm" philosophy to maximise possible preservation of healthy oral tissues;
- _ the proper selection of appropriate dental materials;
- _ the use of supportive procedure methodologies that offer clinicians an "evidence-based" treatment approach that will reliably improve treatment outcomes.

With respect to smile design, the intervention level of a selected MICD treatment will depend on the types of smile defects present, combined with the subjective perception of the patient's own pre-treatment smile condition (Figs. 1a & b). Some of the more common smile defects are:

- _ presence of diastemas;
- _ discoloured teeth;
- _ worn and flattened incisal edge contours;
- _ missing teeth;
- _ rotated and misaligned teeth;
- _ teeth internally stained by fluoride or through childhood disease;
- _ gingival absence, leading to visible "black triangles";
- _ uneven crestal gingival heights;
- _ maxillary and/or gingival excesses resulting from altered passive eruption;

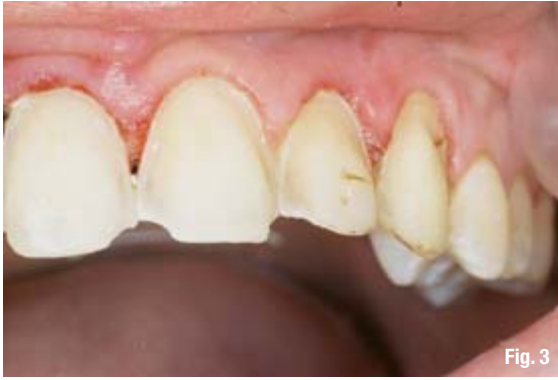

Fig. 3

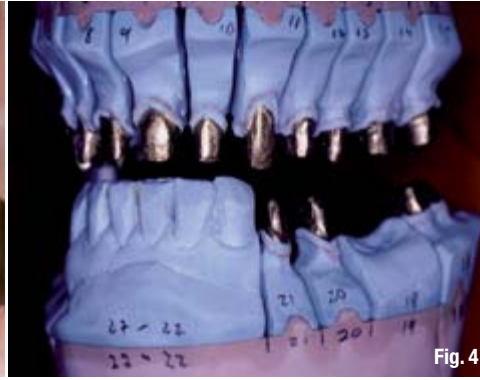


Fig. 4

Fig. 3 Veneer preparations conserve tooth structure compared with full coverage crowns.

Fig. 4 Articulated casts require remounting to ensure minimal spatial distortions at case delivery.

_malocclusion according to Angle's classification;
and
_reverse smile curve.

Contemporary aesthetic dentistry can correct most of these defects utilising a simple, comprehensive, MI approach that places equal emphasis on patient psychology, health, function and aesthetics. Each of these aspects of treatment consideration can be best analysed using the decision-making system of the Smile Design Wheel, which includes each individual aspect as a continuum (Fig. 2).⁶

Smile design with all-ceramic, partial coverage restorations

All-ceramic, partial coverage adhesive restoration (porcelain veneers, inlays and onlays) is considered one of the MI treatment options in MICD treatment as opposed to placing complete coverage restorations (full crowns) that require significantly more tooth preparation. In certain situations, no-preparation veneers may be placed but only if the final aesthetics will not be compromised by the added thickness of the labio-lingual restorative material that a no-preparation veneer creates.

Adhesive restorations conserve tooth structure because less tooth preparation is required for mechanical retention of the restoration when porcelain-enamel adhesion is employed (Fig. 3). Less

mechanical retention preparation is required to stabilise a bonded porcelain restoration in comparison with a non-bonded restoration. The chemical adhesion between etched porcelain and etched enamel provides increased retention. Less tooth preparation can minimise untoward pulpal responses that frequently result when a vital tooth is prepared for full coverage.

Another significant patient benefit of employing adhesive restorations is that treatment time is usually shortened to only two visits:

- _first visit: partial coverage preparation, provisionalisation that incorporates the desired smile design improvements, and one inter-occlusal registration;
- _second visit: porcelain try-in, enamel adhesion, occlusal adjustments and case finishing.

During the second visit, the clinician cannot perform any insertion occlusal adjustments prior to bonding these very brittle restorations in place, as they cannot safely withstand any occlusal alterations without introducing the possibility of restoration fracture.

Shortened treatment times can introduce occlusal errors

However beneficial these short treatment times may be for the patient, they may have two potentially problematic post-insertion results:

Fig. 5 Articulating paper markings do not measure occlusal force by paper mark appearance, regardless of their depth of colour, mark size or shape. Paper markings cannot determine tooth contact timing sequences either.

Fig. 6a T-Scan III recording handle with USB connection.

Fig. 6b T-Scan III desktop.

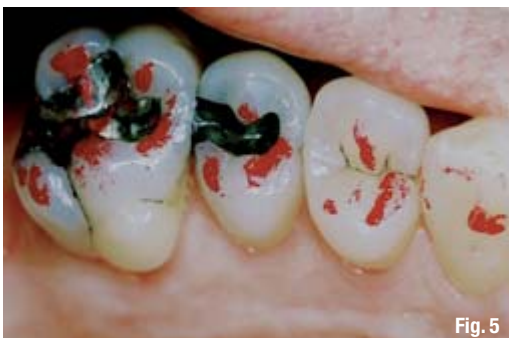

Fig. 5

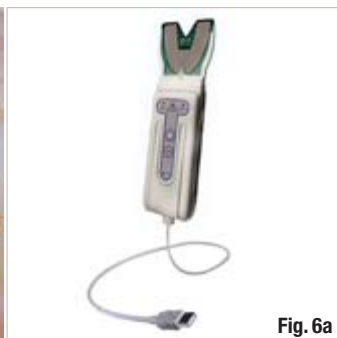

Fig. 6a

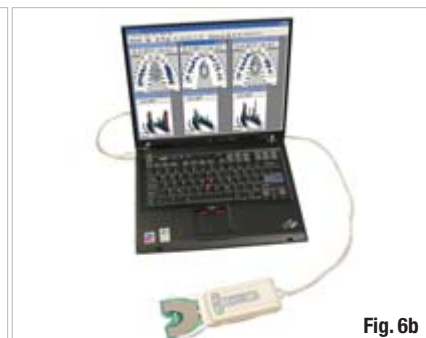

Fig. 6b

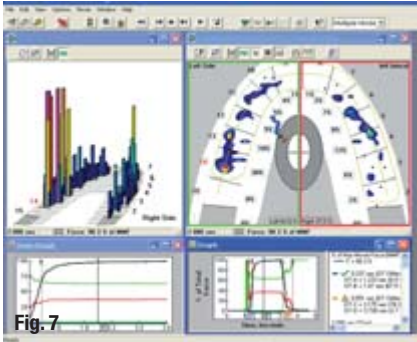


Fig. 7

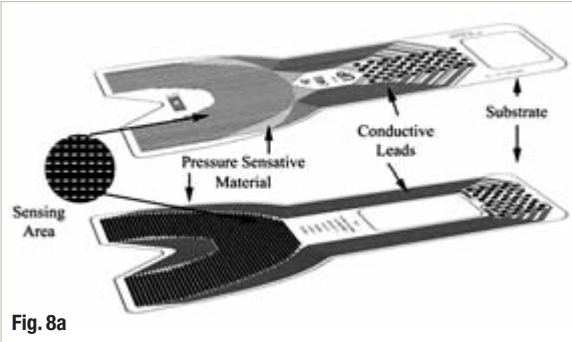


Fig. 8a



Fig. 8b

Fig. 7_T-Scan III graphical display illustrates excessive occlusal force in colour for simplified analyses by the clinician.

Fig. 8a_T-Scan III sensor schematic.

Fig. 8b_T-Scan III high definition recording sensor.

_patient discomfort owing to difficult occlusion initially post-insertion;
 _potentially shortened restoration lifespan.

These sequelae result from the lack of repeated inter-occlusal remounts, which conventional prosthodontic cases commonly undergo. Remounting at metal try-in, porcelain bisque try-in and possibly once more prior to prosthesis installation greatly improves the accuracy of the true maxillo-mandibular, inter-arch spatial relationships (Fig. 4). This reduces the number of occlusal adjustments required at insertion, thereby preserving restorative material thickness and restoration strength.

Adhesive restorations are almost incapable of being reliably remounted. Because of the minimal preparation configuration of partial coverage, non-bonded, all-ceramic restorations, they are unstable on their supporting teeth. Mousses, waxes, silicone putty, injected impression materials and impression tray seating can all easily dislodge the non-bonded restorations from their supporting teeth when taking inter-occlusal records. The movement of non-bonded restorations can also occur during a "pick-up" or transfer impression. The instability of non-bonded restorations complicates all aspects of any remounting procedure greatly.

Without the series of laboratory remounts that a cemented prosthesis often undergoes, the all-ceramic restoration is susceptible to significant spatial misalignment and excessive occlusal force that can go undetected clinically until after the insertion has been started. This lack of proper detection of the location of problematic force is worsened by the fact that articulating paper markings do not measure the occlusal forces or the occlusal contact timing sequence in any quantifiable way, regardless of the false and often-advocated paper marking beliefs (Fig. 5).⁷⁻¹⁶

Poor maxillo-mandibular spatial relationships and occlusal force detection can be reliably overcome when an MI clinician employs computer-guided occlusal analysis technology at restoration insertion (T-Scan III, Tekscan; Figs. 6a & b). When properly used after the completion of bonding procedures, this digital occlusal technology helps to locate regions of excessive occlusal force accurately within the occlusal surfaces and incisal edges of the newly placed restorations. The clinical reduction of these excessive forces leads to easier post-insertion acceptance of the new occlusion and increases the restoration's lifespan.

_Computer-guided occlusal analysis system

The T-Scan III Computerized Occlusal Analysis System offers precision technology that analyses occlusal contact force and time sequences in 0.003-second increments and graphically displays them in movie form.^{17,18} The system simplifies occlusal adjustments at aesthetic prosthesis insertion, as it quickly isolates excessive force concentrations and time-premature contacts, so their eradication is predictable and effective (Fig. 7). The preservation and longevity of ceramic restorations are enhanced, as any potentially destructive occlusal forces are isolated at delivery, and then removed prior to the patient's long-term use of the new smile design prosthesis.

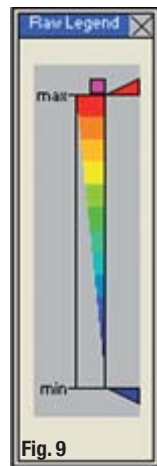


Fig. 9

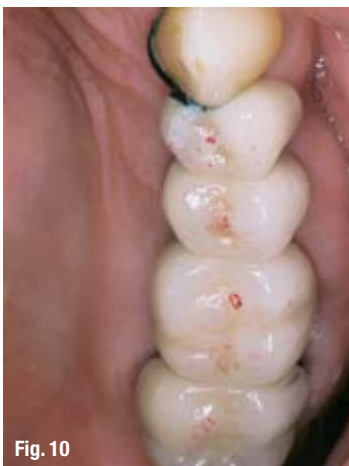

Fig. 10

Fig. 9_Legend of colour-coded occlusal force data.

Fig. 10_Doughnut-shaped paper mark supposedly indicates high force.

The occlusal force and time-sequence data are relayed to a PC through a high-definition recording sensor that measures contact-varying relative force sequentially as differing tooth contacts interact at the occlusal surfaces (Figs. 8a & b). During a turbo-mode recording, the sensor is scanned 3,000 times per second, resulting in a dynamic movie of changing occlusal forces that can be incrementally viewed in a slow-motion playback.

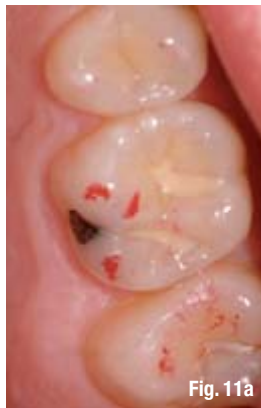

Fig. 11a

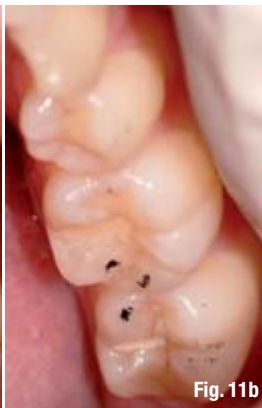

Fig. 11b

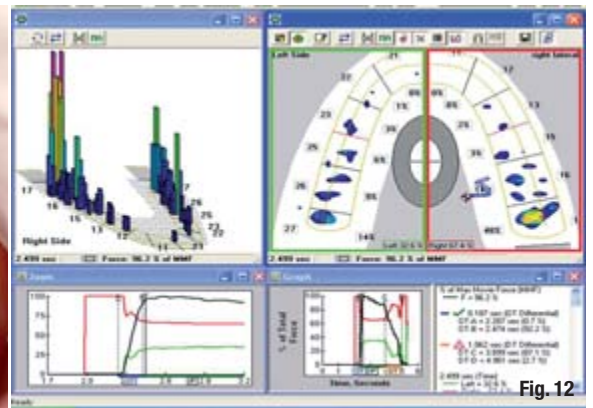


Fig. 12

This dynamic playback separates all the force variances into their contact order, while simultaneously grading their relative occlusal force, so that a clinician can observe them for diagnosis and possible treatment. In two or three dimensions, the contact timing sequence can be played forwards or backwards continuously or in 0.003-second increments, to reveal an occlusal "movie" that describes the occlusal condition.¹⁹ In the 3-D playback view, the force columns change both their height and colour designation. In the 2-D contour view, the colour-coded force concentration zones alter size, shape and colour as the occlusal forces change (Fig. 7). Warmer colours indicate forceful contacts, while darker colours indicate lower force contacts (Fig. 9).

Limitations of articulating paper markings

Clinicians routinely employ articulating paper to visualise the presence of occlusal contacts, their force and their time simultaneity. They determine whether contacts are forceful by subjective judgement of the paper markings for their supposed force content.

In dental medicine, it is strongly advocated and strongly believed by many clinicians that the characteristics of the paper markings indicate occlusal forces.^{10,12-16} The appearance characteristics of the paper markings are based upon:

- a) the size of the mark: large marks supposedly indicate higher forces; small, light markings indicate lesser forces;
- b) the relative colour depth and intensity of the ink mark: the darker the mark and/or its colour intensity, the higher the force content; the lighter the mark, the less force content present;
- c) the presence of doughnut and halo shape(s): these shapes indicate that the contact is forceful because these contacts do not have ink in the middle (Fig. 10).

Despite the persistence of the "clinical beliefs" listed above, there is no published scientific evidence that supports that these appearance characteristics actually indicate the relative force of occlusal contact.⁷⁻¹¹ Studies on articulating paper markings demonstrate consistently that occlusal forces cannot be reliably determined based upon their size or colour. Additionally, paper markings have never been shown in any study to be able to describe contact-timing sequences.⁷⁻¹¹

Figure 11a clearly illustrates the limitations of the articulating paper in describing force and that

Fig. 11a Upper first molar with three large paper marks and upper second molar with mesial scratchy paper markings.

Fig. 11b Opposing lower molars with large black paper marks on first molar and small, light marks on the second molar.

Fig. 12 T-Scan III data of upper right first and second molar occlusal forces.

Fig. 13 Pre-op fractured veneers.

Fig. 14 Replacement of broken veneers completed with six new veneers.

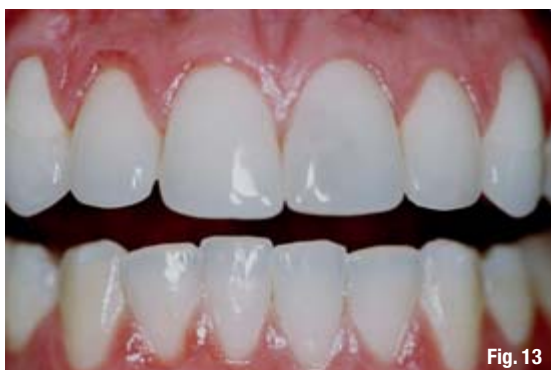

Fig. 13

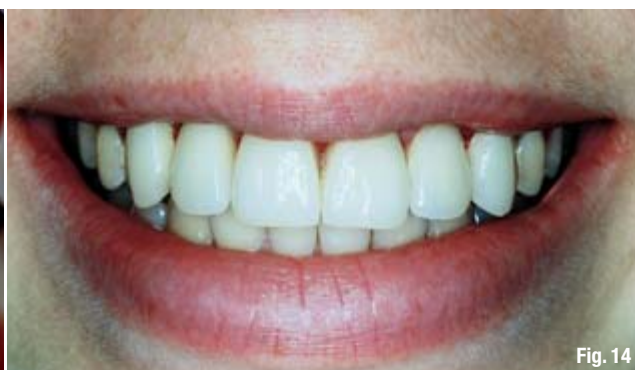

Fig. 14