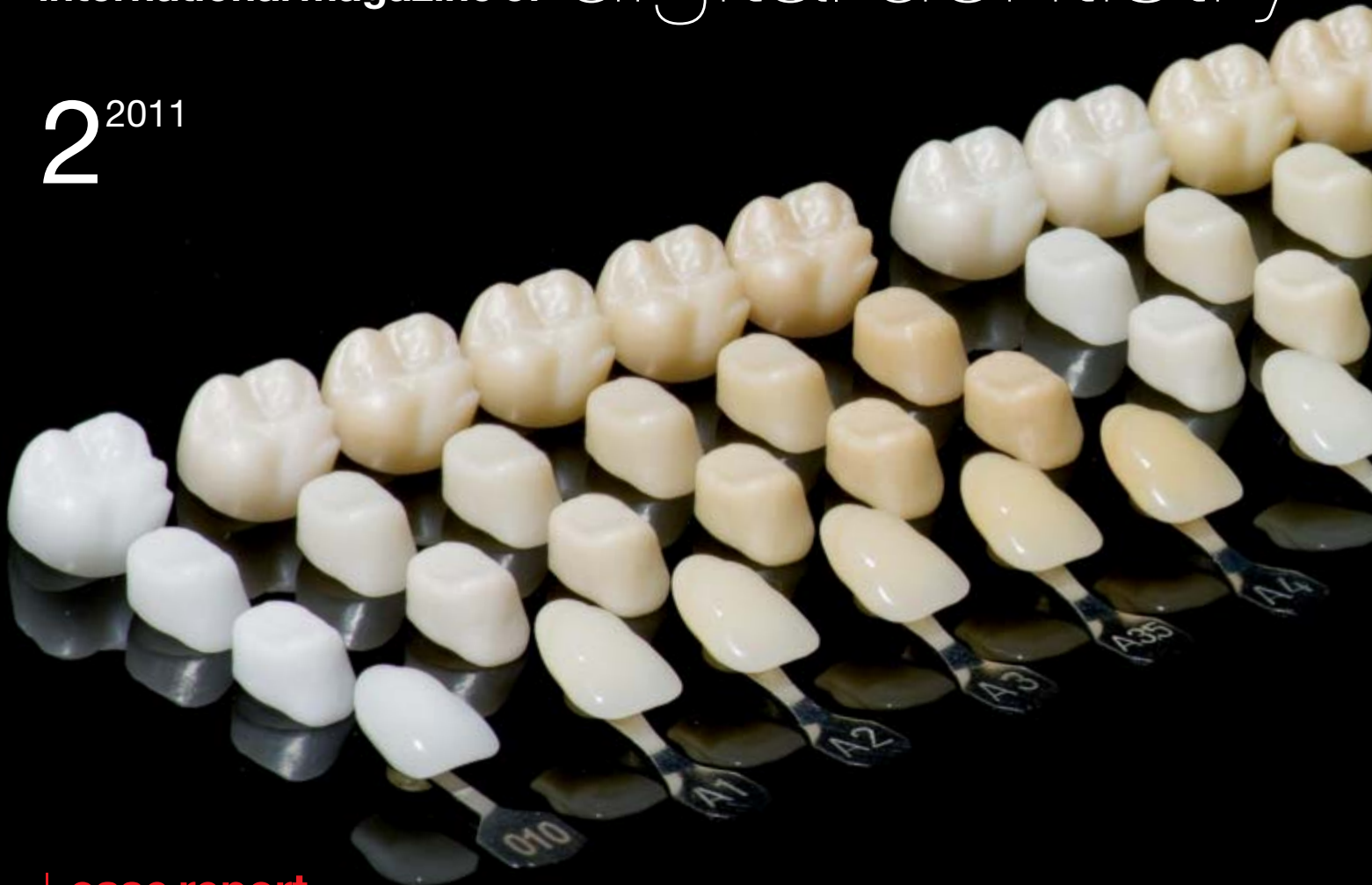

# CAD/CAM

international magazine of digital dentistry

2<sup>2011</sup>



## | case report

Reducing surgical morbidity with  
CBCT-guided implant surgery

## | feature

Moving the dental world from analogue  
to digital: 3Shape's success story continues

## | trends

Intraoral impression-taking:  
Digital datasets soon to catch on everywhere

WHITEPEAKS  
DENTAL SYSTEMS  
*...perfection for a lifetime*

dti] Dental  
Tribune  
International

# IPS e.max<sup>®</sup>

**“I’M TRULY IMPRESSED:  
IT WORKS. WHAT ELSE  
CAN I SAY!”**

August Bruguera, Dental Technician, Spain.

You will be amazed at the versatility of the IPS e.max system. The high-strength IPS e.max lithium disilicate can be processed using press or CAD/CAM techniques: The choice is yours, depending on the case at hand and the requirements.

all ceramic  
all you need



[www.ivoclarvivadent.com](http://www.ivoclarvivadent.com)

Ivoclar Vivadent AG

Bendererstr. 2 | FL-9494 Schaan | Principality of Liechtenstein | Tel.: +423 / 235 35 35 | Fax: +423 / 235 33 60

**ivoclar**  
**vivadent**<sup>®</sup>  
passion vision innovation

# Dear Reader,

At IDS 2009, we had already caught a glimpse of how dentistry would be changing in the future. This year's show affirmed what many were expecting: the digitisation of dentistry is in full swing or, as Daniel Wismeijer, Professor of Oral Implantology and Prosthetic Dentistry at the Academic Centre for Dentistry in Amsterdam, put it: "Digital dentistry is like a bullet train coming at us and its impact will be significant."

These developments are leading to substantial changes, affecting how dentists and dental technicians will carry out their profession in the future. It seems safe to say that intra-oral scanners, for example, are going to replace traditional impression-taking methods completely. With this scanning technology, patient data is gathered more comfortably and precisely, easily, faster and, as a result, at a lower cost. Diagnosis and treatment planning are now possible in 3-D, suggesting the real possibility of a virtual patient.

Since its launch in 2010, CAD/CAM has been committed to accompanying these developments by informing its readers about the latest treatment concepts and technologies and how these can be integrated into today's treatment concepts for the benefit of everyone involved—the patients and the dental professionals. It is absolutely essential that dentists and dental technicians become acquainted with these new technologies, and CAD/CAM thus strives to serve as a platform for information exchange.

In order for the magazine to achieve its full potential, we need your input and encourage you to participate in this exchange. Please feel welcome to submit scientific articles, case reports, industry reports, reviews (meetings, products, etc.) and news for publication.

We appreciate your feedback greatly and are eager to engage with you about your views on digital dentistry.

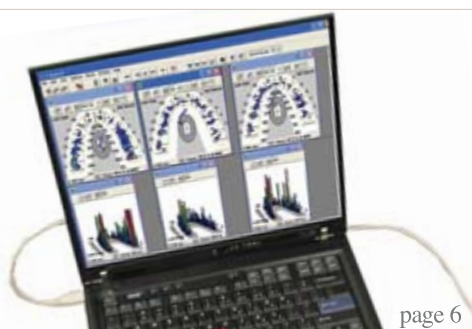Best wishes,



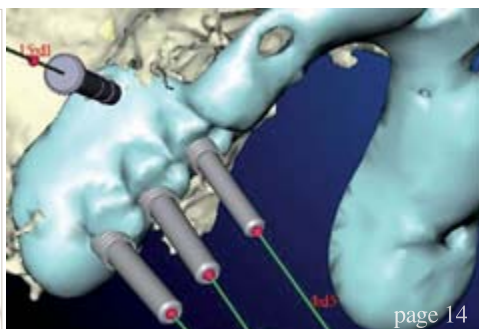
Claudia Salwiczek  
Managing Editor



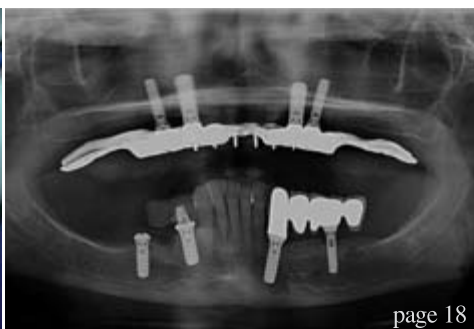Claudia Salwiczek



page 6



page 14



page 18

**| editorial**

03 **Dear Reader**

| Claudia Salwiczek, Managing Editor

**| case report**

06 **Healthy and harmonised function**  
via computer-guided occlusal force management

| Dr Robert Kerstein

14 **Reducing surgical morbidity** with CBCT-guided implant surgery

| Dr Daniel J. Velinsky

**| clinical technique**

18 **Implant-prosthetic troubleshooting** — When dental technicians and dentists break into a sweat!

| Dr Georg Bach & Christian Müller

**| feature**

26 An interview with **Dr Reena Gajjar, My Dental Hub**

30 An interview with **Mr Jost Fischer, Sirona**

34 **Moving the dental world** from analogue to digital: **3Shape's success story** continues

| Bernhard Moldenhauer & Matthias Diessner

**| trends**

38 **Intraoral impression-taking:**  
**Digital datasets soon to catch on everywhere**

| Manfred Kern

**| news**

42 **Dental Wings** collaborates with **absolute Ceramics**

43 **CEREC SW 4.0** now available

**| meetings**

44 **Record-breaking IDS 2011**

| Yvonne Bachmann

48 **International Events**

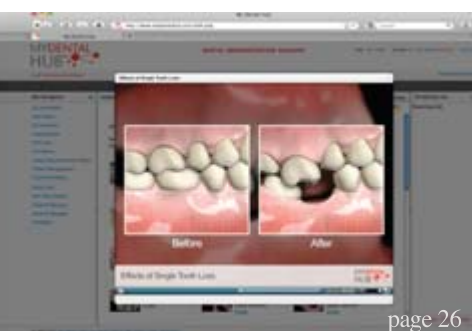**| about the publisher**

49 | submission guidelines

50 | imprint



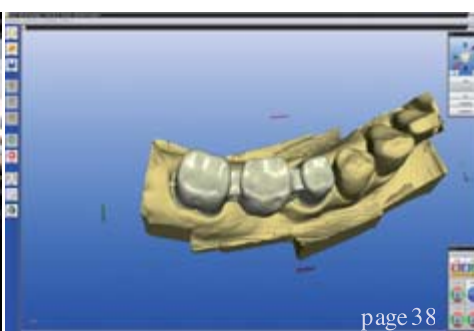
On the cover: CopranColor zirconium colouring system, courtesy of White Peaks Dental Systems GmbH & Co. KG, [www.white-peaks-dental.com](http://www.white-peaks-dental.com).



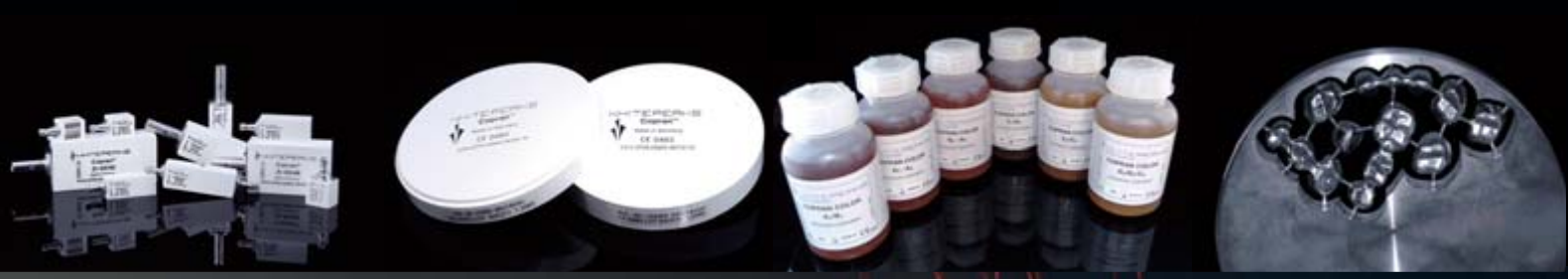page 26



page 30



page 38



# WHITE PEAKS

DENTAL SYSTEMS

*...perfection for a lifetime*

isostatic zirconium blanks  
Made in Germany  
exclusively made from  
raw materials of Tosoh - Japan

zirconium colouring liquids in 16 classic shades,  
chrome-cobalt, titanium, PMMA and wax blanks,  
Calidia series CAD/CAM milling systems,  
free CAM software and scanners.

we are certified to the highest standards of  
CE, US-FDA, IDENT CERAM and DIN EN ISO 13485

White Peaks Dental Systems GmbH & Co. KG  
Langeheide 9  
45239 Essen, Germany  
[www.white-peaks-dental.com](http://www.white-peaks-dental.com)  
[info@white-peaks-dental.com](mailto:info@white-peaks-dental.com)  
phone: +49 281 20 64 58-0

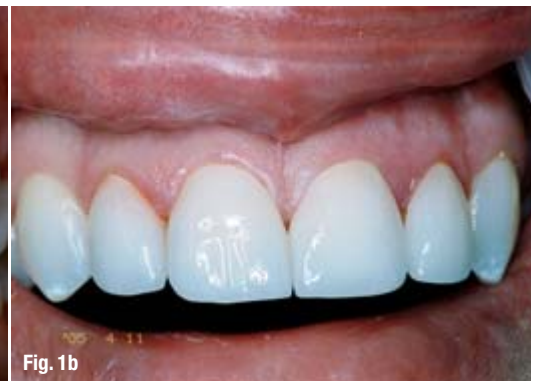
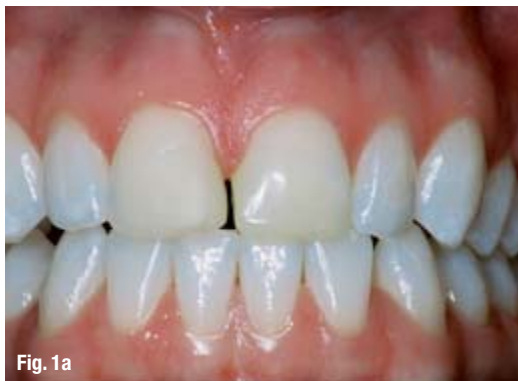
# Healthy and harmonised function via computer-guided occlusal force management

Author \_ Dr Robert Kerstein, USA

**Fig. 1a** \_ A smile defect of discoloured teeth and presence of a diastema.

**Fig. 1b** \_ Four anterior veneers placed to improve smile defects.



**Fig. 2** \_ Smile Design Wheel that incorporates patient psychology, health, function and aesthetics.

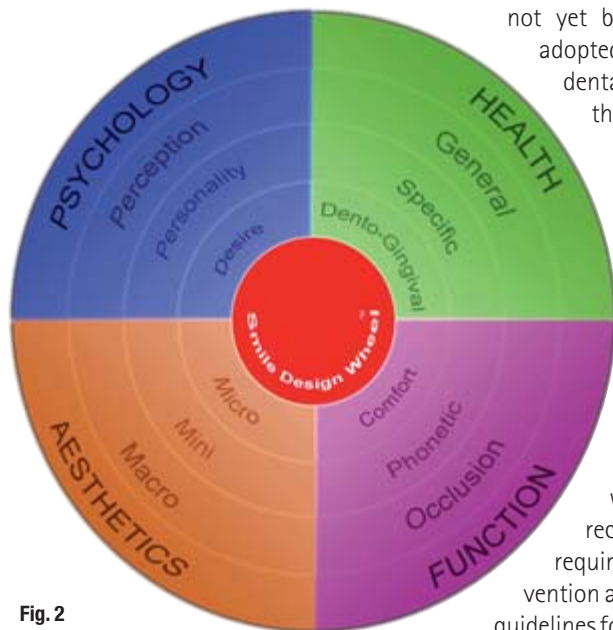


Fig. 2

The minimally invasive (MI) concept was initially introduced in physical medicine and adopted into dental medicine in the early 1970s with the application of diamine silver fluoride to teeth.<sup>1</sup> This was followed by the development of preventive resin restorations (sealants) in the 1980s<sup>2</sup> and the atraumatic restorative treatment (ART) approach<sup>3</sup> with Carisolv (MediTeam) in the 1990s.<sup>4</sup> Since its inception, the focus of MI dentistry has been caries detection and treatment.<sup>5</sup> It has

not yet been comprehensively adopted in other fields of dental medicine; however, the comprehensive concept of minimally invasive cosmetic dentistry (MICD) and its treatment protocol were introduced in 2009 with the basic aim of a clinician effecting optimum clinical therapeutic improvements in smile enhancement, while performing corrective procedures that require as little clinical intervention as possible.<sup>6</sup> Additional guidelines for MICD treatment are:

- \_ the adoption of the "Do No Harm" philosophy to maximise possible preservation of healthy oral tissues;
- \_ the proper selection of appropriate dental materials;
- \_ the use of supportive procedure methodologies that offer clinicians an "evidence-based" treatment approach that will reliably improve treatment outcomes.

With respect to smile design, the intervention level of a selected MICD treatment will depend on the types of smile defects present, combined with the subjective perception of the patient's own pre-treatment smile condition (Figs. 1a & b). Some of the more common smile defects are:

- \_ presence of diastemas;
- \_ discoloured teeth;
- \_ worn and flattened incisal edge contours;
- \_ missing teeth;
- \_ rotated and misaligned teeth;
- \_ teeth internally stained by fluoride or through childhood disease;
- \_ gingival absence, leading to visible "black triangles";
- \_ uneven crestal gingival heights;
- \_ maxillary and/or gingival excesses resulting from altered passive eruption;

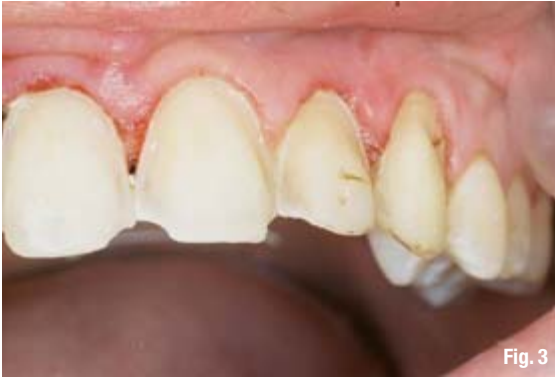

Fig. 3

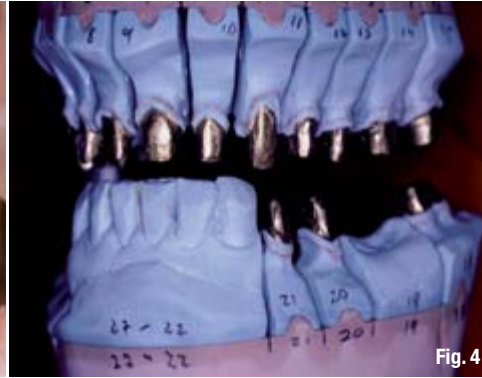


Fig. 4

**Fig. 3** Veneer preparations conserve tooth structure compared with full coverage crowns.

**Fig. 4** Articulated casts require remounting to ensure minimal spatial distortions at case delivery.

\_malocclusion according to Angle's classification;  
and  
\_reverse smile curve.

Contemporary aesthetic dentistry can correct most of these defects utilising a simple, comprehensive, MI approach that places equal emphasis on patient psychology, health, function and aesthetics. Each of these aspects of treatment consideration can be best analysed using the decision-making system of the Smile Design Wheel, which includes each individual aspect as a continuum (Fig. 2).<sup>6</sup>

### **Smile design with all-ceramic, partial coverage restorations**

All-ceramic, partial coverage adhesive restoration (porcelain veneers, inlays and onlays) is considered one of the MI treatment options in MICD treatment as opposed to placing complete coverage restorations (full crowns) that require significantly more tooth preparation. In certain situations, no-preparation veneers may be placed but only if the final aesthetics will not be compromised by the added thickness of the labio-lingual restorative material that a no-preparation veneer creates.

Adhesive restorations conserve tooth structure because less tooth preparation is required for mechanical retention of the restoration when porcelain-enamel adhesion is employed (Fig. 3). Less

mechanical retention preparation is required to stabilise a bonded porcelain restoration in comparison with a non-bonded restoration. The chemical adhesion between etched porcelain and etched enamel provides increased retention. Less tooth preparation can minimise untoward pulpal responses that frequently result when a vital tooth is prepared for full coverage.

Another significant patient benefit of employing adhesive restorations is that treatment time is usually shortened to only two visits:

- \_first visit: partial coverage preparation, provisionalisation that incorporates the desired smile design improvements, and one inter-occlusal registration;
- \_second visit: porcelain try-in, enamel adhesion, occlusal adjustments and case finishing.

During the second visit, the clinician cannot perform any insertion occlusal adjustments prior to bonding these very brittle restorations in place, as they cannot safely withstand any occlusal alterations without introducing the possibility of restoration fracture.

### **Shortened treatment times can introduce occlusal errors**

However beneficial these short treatment times may be for the patient, they may have two potentially problematic post-insertion results:

**Fig. 5** Articulating paper markings do not measure occlusal force by paper mark appearance, regardless of their depth of colour, mark size or shape. Paper markings cannot determine tooth contact timing sequences either.

**Fig. 6a** T-Scan III recording handle with USB connection.

**Fig. 6b** T-Scan III desktop.

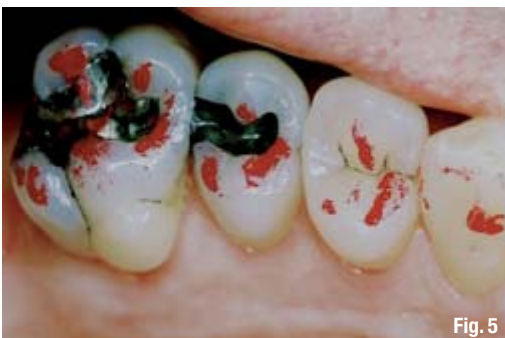

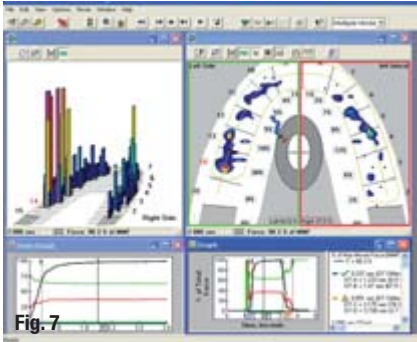
Fig. 5

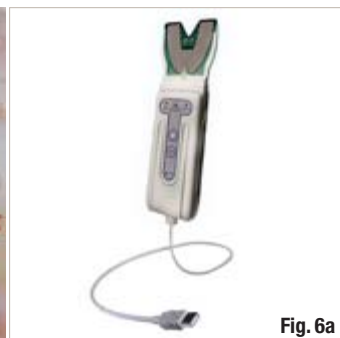

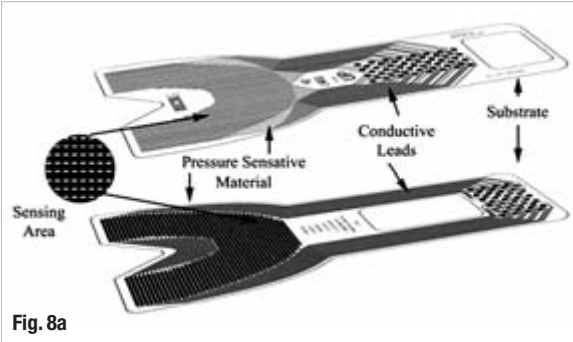
Fig. 6a

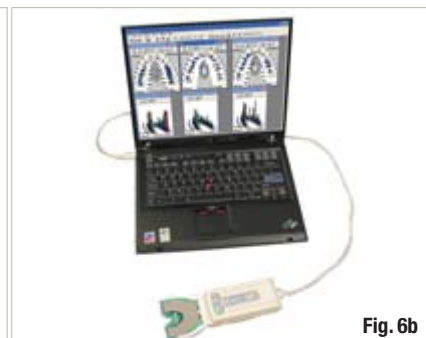

Fig. 6b



**Fig. 7** T-Scan III graphical display illustrates excessive occlusal force in colour for simplified analyses by the clinician.



**Fig. 8a**



**Fig. 8b**

**Fig. 8a** T-Scan III sensor schematic.  
**Fig. 8b** T-Scan III high definition recording sensor.

\_ patient discomfort owing to difficult occlusion initially post-insertion;  
\_ potentially shortened restoration lifespan.

These sequelae result from the lack of repeated inter-occlusal remounts, which conventional prosthodontic cases commonly undergo. Remounting at metal try-in, porcelain bisque try-in and possibly once more prior to prosthesis installation greatly improves the accuracy of the true maxillo-mandibular, inter-arch spatial relationships (Fig. 4). This reduces the number of occlusal adjustments required at insertion, thereby preserving restorative material thickness and restoration strength.

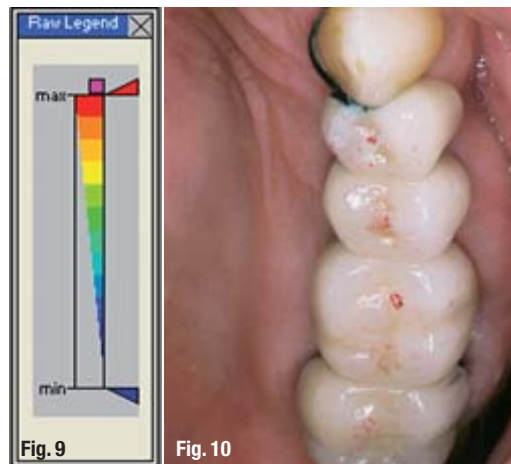
Adhesive restorations are almost incapable of being reliably remounted. Because of the minimal preparation configuration of partial coverage, non-bonded, all-ceramic restorations, they are unstable on their supporting teeth. Mousses, waxes, silicone putty, injected impression materials and impression tray seating can all easily dislodge the non-bonded restorations from their supporting teeth when taking inter-occlusal records. The movement of non-bonded restorations can also occur during a "pick-up" or transfer impression. The instability of non-bonded restorations complicates all aspects of any remounting procedure greatly.

Without the series of laboratory remounts that a cemented prosthesis often undergoes, the all-ceramic restoration is susceptible to significant spatial misalignment and excessive occlusal force that can go undetected clinically until after the insertion has been started. This lack of proper detection of the location of problematic force is worsened by the fact that articulating paper markings do not measure the occlusal forces or the occlusal contact timing sequence in any quantifiable way, regardless of the false and often-advocated paper marking beliefs (Fig. 5).<sup>7-16</sup>

Poor maxillo-mandibular spatial relationships and occlusal force detection can be reliably overcome when an MI clinician employs computer-guided occlusal analysis technology at restoration insertion (T-Scan III, Tekscan; Figs. 6a & b). When properly used after the completion of bonding procedures, this digital occlusal technology helps to locate regions of excessive occlusal force accurately within the occlusal surfaces and incisal edges of the newly placed restorations. The clinical reduction of these excessive forces leads to easier post-insertion acceptance of the new occlusion and increases the restoration's lifespan.

**\_Computer-guided occlusal analysis system**

The T-Scan III Computerized Occlusal Analysis System offers precision technology that analyses occlusal contact force and time sequences in 0.003-second increments and graphically displays them in movie form.<sup>17,18</sup> The system simplifies occlusal adjustments at aesthetic prosthesis insertion, as it quickly isolates excessive force concentrations and time-premature contacts, so their eradication is predictable and effective (Fig. 7). The preservation and longevity of ceramic restorations are enhanced, as any potentially destructive occlusal forces are isolated at delivery, and then removed prior to the patient's long-term use of the new smile design prosthesis.



**Fig. 9**

**Fig. 10**

**Fig. 9** Legend of colour-coded occlusal force data.  
**Fig. 10** Doughnut-shaped paper mark supposedly indicates high force.



The occlusal force and time-sequence data are relayed to a PC through a high-definition recording sensor that measures contact-varying relative force sequentially as differing tooth contacts interact at the occlusal surfaces (Figs. 8a & b). During a turbo-mode recording, the sensor is scanned 3,000 times per second, resulting in a dynamic movie of changing occlusal forces that can be incrementally viewed in a slow-motion playback.

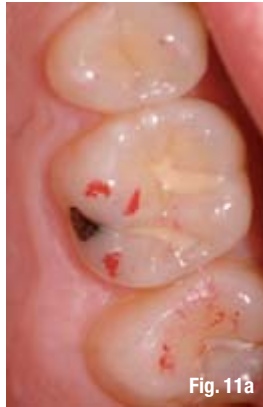

Fig. 11a

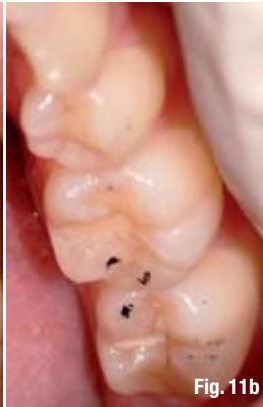

Fig. 11b

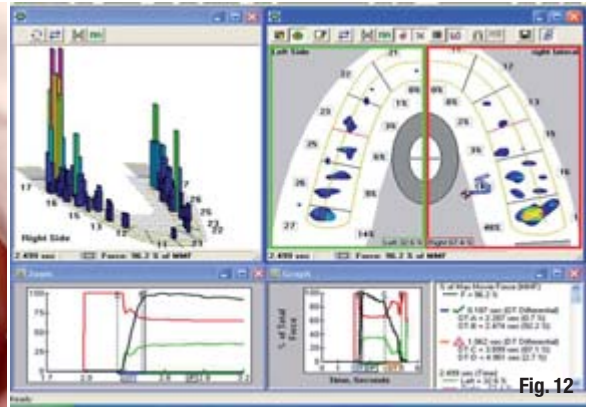


Fig. 12

This dynamic playback separates all the force variances into their contact order, while simultaneously grading their relative occlusal force, so that a clinician can observe them for diagnosis and possible treatment. In two or three dimensions, the contact timing sequence can be played forwards or backwards continuously or in 0.003-second increments, to reveal an occlusal "movie" that describes the occlusal condition.<sup>19</sup> In the 3-D playback view, the force columns change both their height and colour designation. In the 2-D contour view, the colour-coded force concentration zones alter size, shape and colour as the occlusal forces change (Fig. 7). Warmer colours indicate forceful contacts, while darker colours indicate lower force contacts (Fig. 9).

### Limitations of articulating paper markings

Clinicians routinely employ articulating paper to visualise the presence of occlusal contacts, their force and their time simultaneity. They determine whether contacts are forceful by subjective judgement of the paper markings for their supposed force content.

In dental medicine, it is strongly advocated and strongly believed by many clinicians that the characteristics of the paper markings indicate occlusal forces.<sup>10,12-16</sup> The appearance characteristics of the paper markings are based upon:

- a) the size of the mark: large marks supposedly indicate higher forces; small, light markings indicate lesser forces;
- b) the relative colour depth and intensity of the ink mark: the darker the mark and/or its colour intensity, the higher the force content; the lighter the mark, the less force content present;
- c) the presence of doughnut and halo shape(s): these shapes indicate that the contact is forceful because these contacts do not have ink in the middle (Fig. 10).

Despite the persistence of the "clinical beliefs" listed above, there is no published scientific evidence that supports that these appearance characteristics actually indicate the relative force of occlusal contact.<sup>7-11</sup> Studies on articulating paper markings demonstrate consistently that occlusal forces cannot be reliably determined based upon their size or colour. Additionally, paper markings have never been shown in any study to be able to describe contact-timing sequences.<sup>7-11</sup>

Figure 11a clearly illustrates the limitations of the articulating paper in describing force and that

**Fig. 11a** Upper first molar with three large paper marks and upper second molar with mesial scratchy paper markings.

**Fig. 11b** Opposing lower molars with large black paper marks on first molar and small, light marks on the second molar.

**Fig. 12** T-Scan III data of upper right first and second molar occlusal forces.

**Fig. 13** Pre-op fractured veneers.

**Fig. 14** Replacement of broken veneers completed with six new veneers.

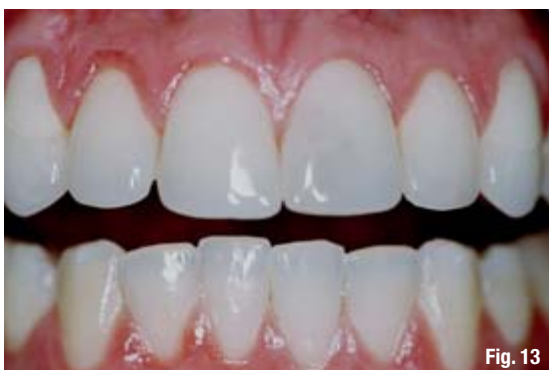

Fig. 13

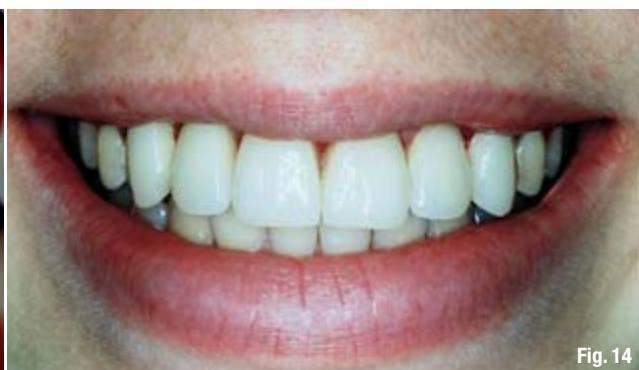

Fig. 14