

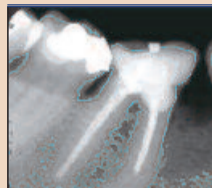
DENTAL TRIBUNE

— The World's Dental Newspaper • Middle East & Africa Edition —

PUBLISHED IN DUBAI

January, 2012

No. 1 Vol. 10




Trends & Applications
Dental X-rays can predict fractures

▶ Page 4



Media CME
Vital amputation of permanent teeth

▶ Page 6



Business
Dental practice in Japan goes Kitty-crazy

▶ Page 8

Researchers develop robot that performs brain surgery

BRUSSELS, Belgium: An EU-funded team of researchers has developed a robot able to help neurosurgeons in performing keyhole brain surgery. The robot was tested for its accurate performance during tests on dummies. The team believes it can be used to help physicians treat their patients for epilepsy, Tourette's syndrome and Parkinson's disease.

The robot is claimed to have incredible memory and accuracy in performance, especially because it has 13 types of movement compared with the four available to human hands, as well as haptic feedback—physical cues allowing physicians to assess tissue and perceive the amount of force applied during surgery.

The ROBOCAST (Robot and sensors integration as guidance for enhanced computer assisted surgery and therapy) project received €3.45 million under the "Information and communication technologies" theme of the EU's Seventh Framework Programme.

Led by the Politecnico di Milano university in Italy, the ROBOCAST partners developed hardware experts call mechatronics, which constructs the robot's body and nervous system, as

well as intelligence software. The software comprises a multiple robot system, an independent trajectory planner, an advanced controller and a set of field sensors.

The ROBOCAST consortium developed the mechatronic phase of the project as a modular system with two robots and one active biomimetic probe. These were integrated into a sensory motor framework to run as one unit.

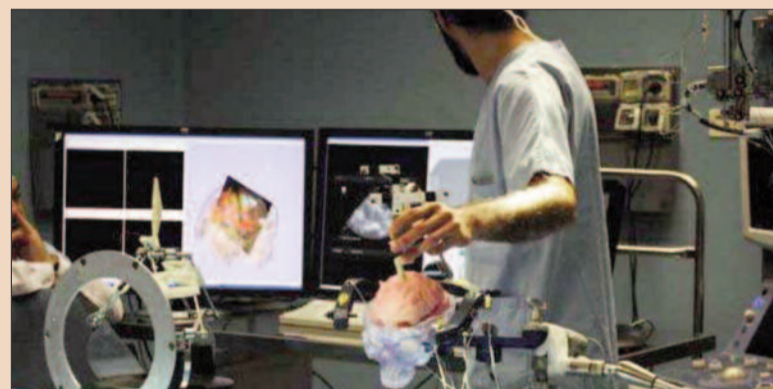The first robot has the ability to locate its miniature companion robot through six degrees of freedom, and moves from left to right, up and down, and backwards and forwards. It also has three rotational movements, namely forwards and backwards, side to side, or left to right. These all work together to locate the robot's companion anywhere in a 3-D space. The robot, say the researchers, can also ease the tremor of a surgeon's hands up to tenfold.

The miniature robot holds the probe that is used through the keyhole. According to the researchers, optical trackers are located at the end of the probe and on the patient. The force applied is managed by the robot, which also controls the position using a combination of sensors.

This allows it to determine the trajectory of the surgical work.

According to the developers, the path the robot follows inside the brain is determined on the basis of a risk atlas and the evaluation of preoperative diagnostic information.

The ROBOCAST team comprises experts from Germany, Is-



rael, Italy and the UK. Future research plans include investigating robotic neurosurgery for pa-

tients who would remain conscious during their surgery. [DT](#)

AD

Gulf's first ever mobile diabetes clinic prepares for tour launch

The Emirates Diabetes Society's 'Win Over Diabetes' mobile clinic is in its final preparations to begin its journey across the United Arab Emirates (UAE), with the first visit taking place in the rural area of Al Lusaily, between Dubai and Al Ain, on Saturday 28 January.



Inaugurated in Dubai last December at the prestigious Inter-

national Diabetes Federation-sponsored World Diabetes Congress, the mobile clinic patient initiative will act as an education, disease consultation and treat-

EUROPEAN UNIVERSITY COLLEGE كلية الأوروبية الجامعية
(formerly NICOLAS & ASP UNIVERSITY COLLEGE) (كلية نيكولا وأسب الجامعية سابقاً)

Dubai - Abu Dhabi

FIRST INTERNATIONAL POSTGRADUATE DENTAL INSTITUTION IN THE REGION

"All programs accredited by UAE Ministry of Higher Education & Scientific Research"

3-YEAR MASTER DEGREE IN ORTHODONTICS

In Cooperation with Malmö University - Sweden
Clinical, Theoretical & Research
3-years full time

1-YEAR HIGH DIPLOMA ORAL IMPLANTOLOGY

In Cooperation with Gothenburg University - Sweden
Clinical, Theoretical & Research
1-year full time

3-YEAR MASTER DEGREE IN PEDIATRIC DENTISTRY

3-years full time
Clinical, Theoretical & Research
Patient Care, GA Facilities, & Special Needs Care

2-YEAR DIPLOMA IN ADVANCED EDUCATION IN GENERAL DENTISTRY (AEGD)

2-years full time
Clinical, Theoretical & Research
Operating Microscope Facilities, Computerized Radiography

3-YEAR MASTER DEGREE IN ENDODONTICS

3-years full time
Clinical, Theoretical & Research
Operating Microscope Facilities, Computerized Radiography

Visit Us **AEEDC DUBAI 2012 - 31 January - 2 February - Stand No. 18**

2012 Admissions Currently Open

+97143624784 • candidate@nicolasasp.ae • www.dubai-postgraduate.com

ment facility, utilizing eminent medical specialists and offering services to patients in the remote areas of the nation, where access to specialized diabetes treatment is a challenge.

"AlLusaily is the first regional stop for the 'Win over Diabetes' mobile clinic, which will be providing hope for the country's diabetes sufferers. Controlling this debilitating disease is a matter that can be tackled through lifestyle changes, not only in

terms of diet and exercise but also through better compliance with prescribed medication - a shortfall here in the UAE. We are dedicated to providing an exemplary standard of care to patients that may not have access to any, due to their remote locations. Staffed with volunteer specialist including top physicians and disease educators, the mobile clinic aims to change that," said Dr. Abdul Razzaq Al Madani, Head of the Emirates Diabetes Society.

The day-trip will allow specialists on board to carry out diabetes screening, provide examinations and consultations for diabetic patients, and provide wider medical education to physicians, patients and nurses in the area to aid effective management of the disease and also reduce the staggering rate of diabetes in the local population.

The Win Over Diabetes mobile clinic is also fully equipped to provide screenings to the resi-

dents of Al Lusaily, which will involve blood glucose, blood pressure and lipid testing, together with the monitoring of other important vital signs.

Diabetes mellitus is the fourth leading cause of death by disease globally, and is the leading cause of blindness and visual impairment among adults in developed countries.

According to the World Health Organization, the prevalence of diabetes is highest

among member countries of the Gulf Cooperation Council (GCC), ranging from 11.5 to 30%, with more than 20% of the local population affected in the UAE. This makes diabetes management as the priority for all the stakeholders in UAE.

The 'Win Over Diabetes' mobile clinic campaign intends to cover all seven UAE emirates over a 12-month period, with specialist health care practitioners onboard making visits to the country's many hospitals, healthcare clinics, and community centres.

Organizers of the 'Win Over Diabetes' Mobile Clinic campaign also point out that the mobile clinic tour is not only intended to screen UAE residents for diabetes but also to offer treatment and care optimization in remote areas, including:

- Diabetic patients also suffering from complications such as hypoglycaemia
- Weight gain in diabetic patients due to a lack of effective management and even, in some cases, awareness of their illness
- Patients with diabetes-associated illnesses such as high blood pressure (hypertension) and abnormal levels of fats/cholesterol in the blood (dyslipidaemia)

The Win Over Diabetes mobile clinic is a joint patient service initiative between the Emirates Diabetes Society and Swiss pharmaceutical company, Novartis - one of the leading pharmaceutical companies worldwide, offering partnership in patient-oriented services beyond the innovative medications across different therapeutic areas. [\[1\]](#)

AD

MEDEXPO
Saudi Arabia
17 - 20 June 2012
Jeddah International Exhibition Centre

ميد إكسبو
المملكة العربية السعودية
١٧ - ٢٠ يونيو ٢٠١٢
مركز جدة الدولي للملتقيات و الفعاليات

Saudi Arabia's International Healthcare Exhibition

17 - 20 June 2012, Jeddah International Exhibition Centre

“US\$23.4 billion spend on healthcare in Saudi Arabia.”



Book your stand now

Contact: John Suzara, Project Manager

t: +971 4 4380355

e: johnsuzara@dmgevents.com

Supported by:

الهيئة العامة للغذاء والدواء
Saudi Food & Drug Authority

مجلس التأمين الصحي التعاوني
Council of Cooperative Health Insurance



In association with:

www.medexposaudi.com

DENTAL TRIBUNE

The World's Dental Newspaper - Middle East & Africa Edition

Published by Education Zone

in licence of Dental Tribune International GmbH

© 2012, Dental Tribune International GmbH. All rights reserved.

Dental Tribune makes every effort to report clinical information and manufacturer's product news accurately, but cannot assume responsibility for the validity of product claims, or for typographical errors. The publishers also do not assume responsibility for product names or claims, or statements made by advertisers. Opinions expressed by authors are their own and may not reflect those of Dental Tribune International.

Editorial Board

Prof. Abdullah Al-Shammary, Restorative Dentistry, KSA
Prof. Hussain F. Al Huwaizi, Endodontics, Iraq
Prof. Samar Burgan, Oral Medicine, Jordan
Dr. Abdel Salam Al Askary, Implantology, Egypt
Dr. Talal Al-Harbi, Orthodontist, Qatar
Dr. Mohammed H. Al Jishi, Bahrain
Dr. Lara Bakaeen, Prosthodontist, Jordan
Dr. Aisha Sultan, Periodontist, UAE
Dr. Kamal Balaghi Mobin Aesthetics, Iran

President/CEO

Yasir Allawi y.allawi@dental-tribune.ae

Director mCME:

Dr. D. Mollova info@cappmea.com

Marketing manager

Khawla Najib khawla@dental-tribune.ae

Production manager

Hussain Alvi dentalme@dental-tribune.ae

PO Box 214592, Dubai, UAE,

Tel + 971 4 391 0257

Fax + 971 4 366 4512

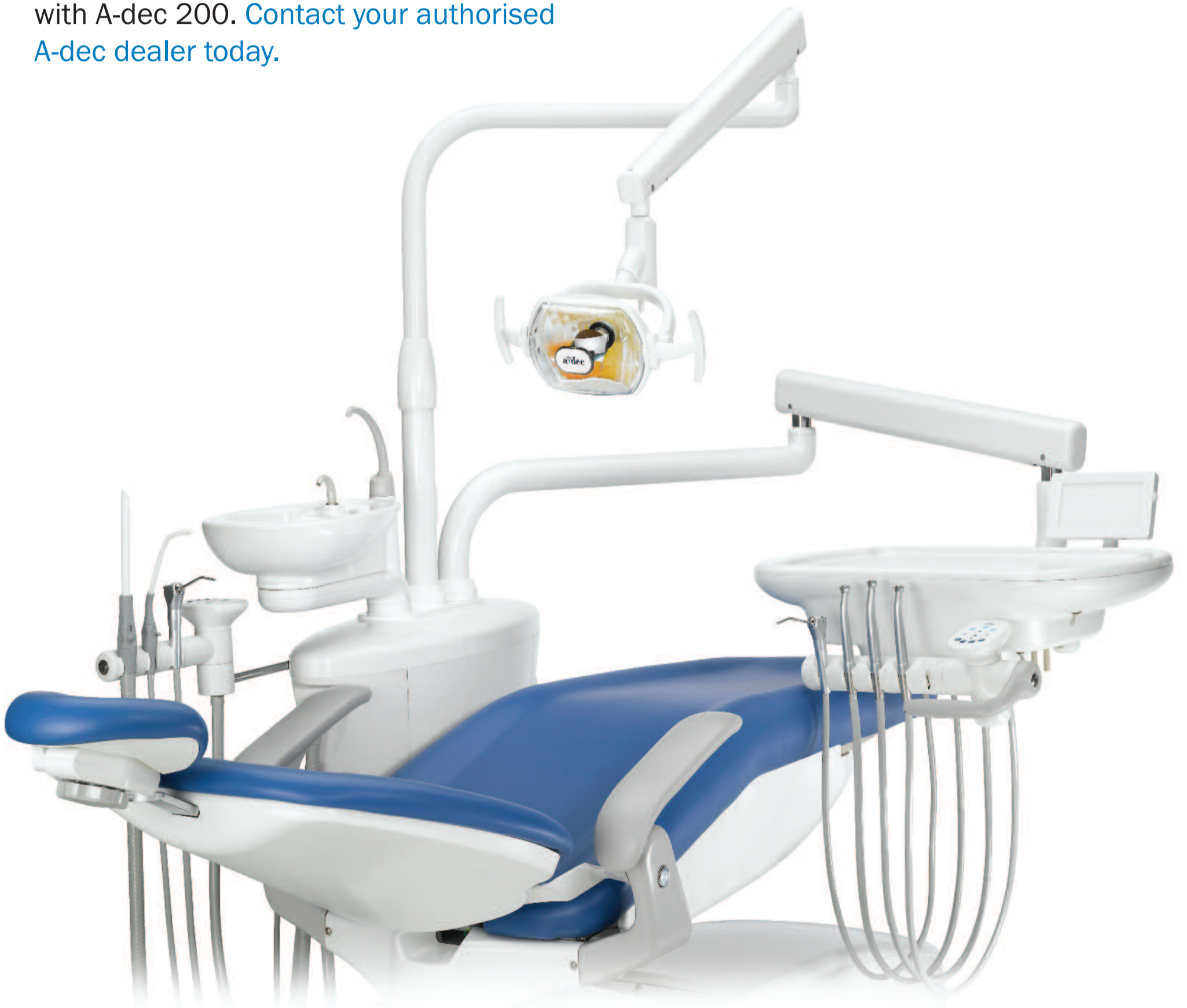www.dental-tribune.com

Assurance

Invest in reliability. Focus on the patient. Express your style. From the people who build the most dependable dental equipment in the world, A-dec 200™ provides you with a complete system to secure a successful future.

Discover how you can gain assurance with A-dec 200. [Contact your authorised A-dec dealer today.](#)

visit **A-dec**
at **AEEDC**
stand 230



Discover **A-dec 200**. Contact your local dealer

A-dec Inc.

2601 Crestview Drive, Newberg, Oregon 97132 USA

www.a-dec.com


reliablecreativesolutions

Dental X-rays can predict fractures

By using dental X-rays, the risk of fractures can now be predicted long before a fracture actually occurs, Swedish researchers at the University of Gothenburg's Sahlgrenska Academy have found.

In a previous study, researchers at the Academy and the

Public Dental Service of the Region Västra Götaland had demonstrated that a sparse bone structure in the trabecular bone in the mandible is linked to a greater probability of having previously had fractures in other parts of the body.

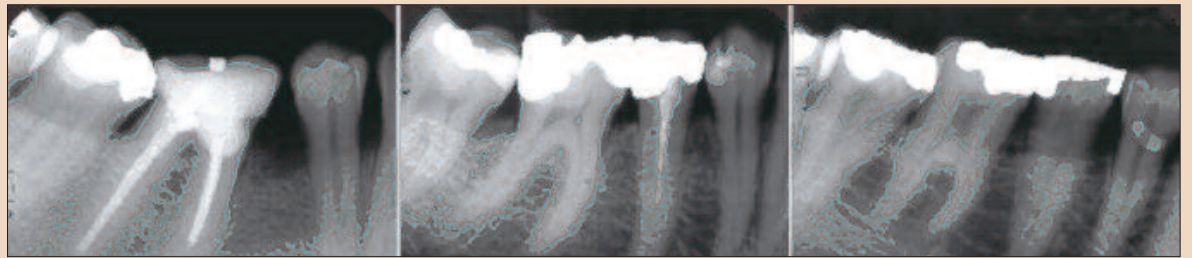


Fig. 1 Reference images presenting the trabecular pattern as dense trabeculation in a woman with small intertrabecular spaces ...

Fig. 2... mixed dense plus sparse trabeculation in a woman with small intertrabecular spaces cervically and larger spaces more apically ...

Fig. 3... and sparse trabeculation in a woman with large intertrabecular spaces.

The Gothenburg researchers followed this research with a new

study that demonstrates that it is possible to use dental X-rays to

investigate the bone structure in the lower jaw, which enables doctors to predict who is at greater risk of fractures in the future.

AD


The First Step to MSc Implantology



UAE - GBOI I

1st Session (1st - 2nd June 2012)

- 200 C.E. Hours (Continued Education)
- One Year Curriculum 2012-2013
- Certified by Implantology German Board
- Full accepted and part of the MSc Implantology at Münster University
- Total of 8 weekends



NOW IN U.A.E!!!

JOIN OUR TEAM!!!

VISIT US AT AEEDC BOOTH # 599

Please submit your application to:
International office of DGZI in Dubai
Att: Mr. Flavio Moscardo
Jafza View Lob 19 Of. 1301
Dubai - UAE - P.O. Box 261901
Tel: +971 (0) 48855404 Ext. 304/305
Fax: +971 (0) 48855405
Mob: +971 (0) 559250844
E-mail: flaviomoscardo@hotmail.com
www.dgzi-international.com

"We have discovered that sparse bone structure in the lower jaw in mid-life is directly linked to the risk of fractures in other parts of the body later in life," said Prof Lauren Lissner, researcher at the Institute of Medicine at the Sahlgrenska Academy.

The study draws on data from The prospective population study of women in Gothenburg, which was begun in 1968. "Given that this study has now been running for over 40 years, the material is globally unique," the Academy stated. The ongoing study includes 731 women, who have been examined on several occasions since 1968, when they were 58 to 60 years old. X-ray images of their jaw bone were analysed in 1968 and 1980 and the results related to the incidence of subsequent fractures. "The youngest cohort is now over 80 years old. Many of the cohorts, who were born earlier, have died. We regularly check the cohorts' status by monitoring the mortality and hospital registries,"

According to the Academy, for the first 12 years, fractures were self-reported during follow-up examinations. It is only since the 1980s that it has been possible to use medical registers to identify fractures. A total of 222 fractures were identified during the whole observation period.

The study found that the bone structure of the jaw was sparse in around 20 per cent of the participants aged 58 to 54 when the first examination was carried out, and that these participants were at a significantly greater risk of fractures.

The researchers also concluded that the older the person, the stronger the link between sparse bone structure in the jaw and fractures in other parts of the body. Although the study was carried out on women, the researchers believe that the findings could be generalised to men.

"Dental X-rays contain lots of information on bone structure," said Grethe Jonasson, researcher at the Research Centre of the Public Dental Service in Västra Götaland, who initiated the fractures study. "By analysing these images, dentists can identify people who are at greater risk of fractures long before the first fracture occurs."

The study A prospective study of mandibular trabecular bone to predict fracture incidence in women was published in the October issue of the Bone journal.

Cetylpyridinium Chloride, An innovative molecule

The use of physical and chemical components for oral hygiene dates back to approximately 3000 years before Christ. Throughout history, man has developed tools to take care of teeth and prevent bad odour¹. Later, with the emergence of microbiology, it was found that those responsible for bad breath and the most common oral diseases were bacteria, and removing them with antiseptics was proposed.

Until now, a series of compounds with the ability to eliminate microorganisms have been tested; however, it has been discovered that not all of them can be used in the oral cavity, because they can potentially damage soft tissues, mucosa or teeth, or because they have an unpleasant taste or smell. These difficulties still exist today and should be resolved in order to come up with effective oral hygiene tools.

A series of compounds that are capable of combating dental plaque exist and have been classified as follows:

Antiseptic agents that prevent proliferation and/or eliminate microorganisms that form plaque.

Antibiotics capable of inhibiting or killing specific bacterial groups.

Enzymes or enzyme combinations that can break up or disperse the extracellular matrix of the biofilm or act upon the community physiology.

Non-enzymatic, dispersing, denaturalising or modifying agents that can alter plaque structure or the metabolic activity of plaque.

Agents that can interfere with the adhesion of the acquired pellicle.

Currently, a great number of toothpastes and mouthwashes are available on the market that are efficient in maintaining optimal oral health. Different antigingivitis and antiplaque products are formulated with active ingredients such as triclosan (toothpastes), stannous fluoride (toothpastes), a combination of essential oils (mouthwashes), alcohol (mouthwashes), chlorhexidine (CHX) (mouthwashes and toothpastes) and cetylpyridinium chloride (CPC) (mouthwashes and toothpastes).

Pros and Cons of CHX, alcohol and CPC

Currently, the majority of mouthwashes use CHX, alcohol and CPC as their active ingredients or a mixture of these. However, different studies have found that alcohol can present some adverse effects, such as oral or oesophageal cancer and the deterioration of synthetic dental reconstruction materials and is contraindicated in patients with mucositis, immunocompromised patients, patients under-

going head and neck irradiation, sensitised patients and in children^{2,3}.

DIFFERENT STUDIES HAVE SHOWN THAT MOUTH-WASHES CONTAINING CHX, CPC AND A COMBINATION OF BOTH ACT EFFICIENTLY AS ANTIPLAQUE AGENTS ON HALITOSIS AND ON GINGIVITIS.

Different studies have shown that mouthwashes containing CHX, CPC and a combination of both act efficiently as antiplaque agents on halitosis and on gingivitis^{4,5,6}. CHX is probably the most frequently used molecule in different health disciplines due to its excellent antibacterial effect⁷. Particularly in the oral cavity, it shows the best results for treating periodontal disease. However, it is true that it does possess some adverse effects, such as promoting the formation of calculus, tooth staining and a bitter taste. Also, some clinical studies have described that it may cause mucosal irritation and desquamation¹. Because of CHX's side effects, certain molecules such as CPC have become very important. Currently, new formulations are being developed to improve the effectiveness of CPC either alone as the main active ingredient or in mouthwashes combined with CHX.

DIFFERENT STUDIES HAVE SHOWN THAT CPC IN DIFFERENT CONCENTRATIONS IS EFFECTIVE IN REDUCING SUPRA AND SUBGINGIVAL DENTAL BACTERIAL PLAQUE

Nowadays, CPC is being used in various applications in the food industry, since it is capable of eliminating pathogens such as Salmonella spp. and Campylobacter spp., as well as killing Staphylococcus spp. bacteria in proportions of 1:50000 in merely 10 minutes. It is also used in the pharmaceutical and cosmetic industries and as a cleaning and disinfecting agent^{9,10,11}.

Cetylpyridinium Chloride (CPC)

N-hexadecylpyridinium chloride or CPC is classified as a cationic quaternary ammonium surfactant, is soluble in alcohol and in aqueous solutions; it can act as a detergent and as an antiseptic, it is non-oxidizing and non-corrosive and has a neutral pH⁸. Its molecular structure is made up of a polar and a non-polar region, as shown in figure 1.

This molecule has bactericidal and bacteriostatic activity against Gram positive and Gram negative bacteria, although evidence suggests that it is more effective against the first ones. It is thought that its mechanism of

Halitosis?

fresh breath 24h

DENTAID
The Oral Health Experts
www.dentaid.com

HA LITA
The first scientific treatment for the control of oral halitosis



Vital amputation of permanent teeth

(mCME articles in Dental Tribune (always page 6) has been approved by HAAD as having educational content acceptable for (Category 1) CME credit hours. Term of approval covers issues published within one year from the distribution date (September, 2010). This (Volume/Issue) has been approved by HAAD for 2 CME credit hours.

Author: Dr Robert Teeuwen,
Germany

The vital amputation (VA) of deciduous teeth with the goal of maintaining their functionality for a limited period is a widely accepted measure. Vital amputation of permanent teeth, however, is only approved for limited indications. While therapeutic agents such as calcium hydroxide (Ca(OH)₂) and mineral trioxide aggregate (MTA) are recommended for VAs, formaldehyde (CH₂O) containing agents are a controversial subject.

The European Society of Endodontology (ESE) defines pulp amputation as a procedure during which part of the exposed vital pulp tissue is removed with the aim of maintaining vitality and function of the remaining parts of the pulp.¹ ESE recognises the following indications for VAs (i.e. pulpotomy):

1. treatment of deciduous teeth;
2. treatment of permanent teeth with incomplete root growth; and
3. emergency measure.

Indications 2 and 3 include the option of a later definitive root-canal treatment (RCT).

Seidler recommends VA for the accidentally opened pulp of young molars and extremely curved, narrow root canals.² Stern considers difficulty in opening the mouth an indication for VAs as well.³

McDougal et al. extend the indication for pulpotomy when there are economic concerns, as some patients are unable or unwilling to bear the expense of a RCT.⁴

According to Swift et al., a successful VA may be expected following traumatic or mechanical carious pulp exposure.⁵ We consider predictable success with the following prerequisites: non-inflamed pulp; bacteria-proof closure; and use of a pulp-compatible capping material.

Seidler states the following regarding the success of VA:²

A higher rate of success is observed in cases of iatrogenic pulp exposure.

Treatment success is reduced in cases of complete root growth.

Molars are more successfully treated than incisors.

For a pulpotomy with Ca(OH)₂, Jensen presupposes that there is no pain existing anamnestically.⁶

Teixeira et al. corroborate the significance of pain prior to VA.⁷ In their study of 41 Ca(OH)₂ vitally amputated permanent teeth, anamnestic pain existed in 12 cases. The pulpotomy of these aching teeth led to failure

after six to eight months in 50 % of the cases (n=6), while all other vitally amputated teeth were considered successfully treated.

McDougal et al. report on 73 eugenol pulpotomies on aching permanent molars and premolars.⁴ A clinical success rate of 90 % after six months and

78 % after 12 months was observed. The teeth, which were free of pain at check-up, were radiologically controlled and it was shown that 49 % of the teeth were free of pathological findings after six months and 42 % after 12 months.

According to Jensen, pulpotomy is an attempt to stimulate hard tissue healing at the area of amputation.⁶ Fountain and Camp point out that a pulpotomy may result in canal calcification, internal resorption or necrosis of the pulp.⁸ Kozlow and Massler refer to literature that reports the formation of a dentine bridge in rat teeth under non-calcium-containing materials, such as wax, amalgam, acrylic resin and zinc oxide eugenol.⁹ In human teeth, the bridging under Ca(OH)₂ was successful in 45 % of the cases and under antibiotics in 25 % of the cases. During their own tests on rat teeth, the authors assessed good reparative reactions with complete bridging following pulpotomy with Ca(OH)₂, zinc oxide eugenol, cortisone and silver amalgam.

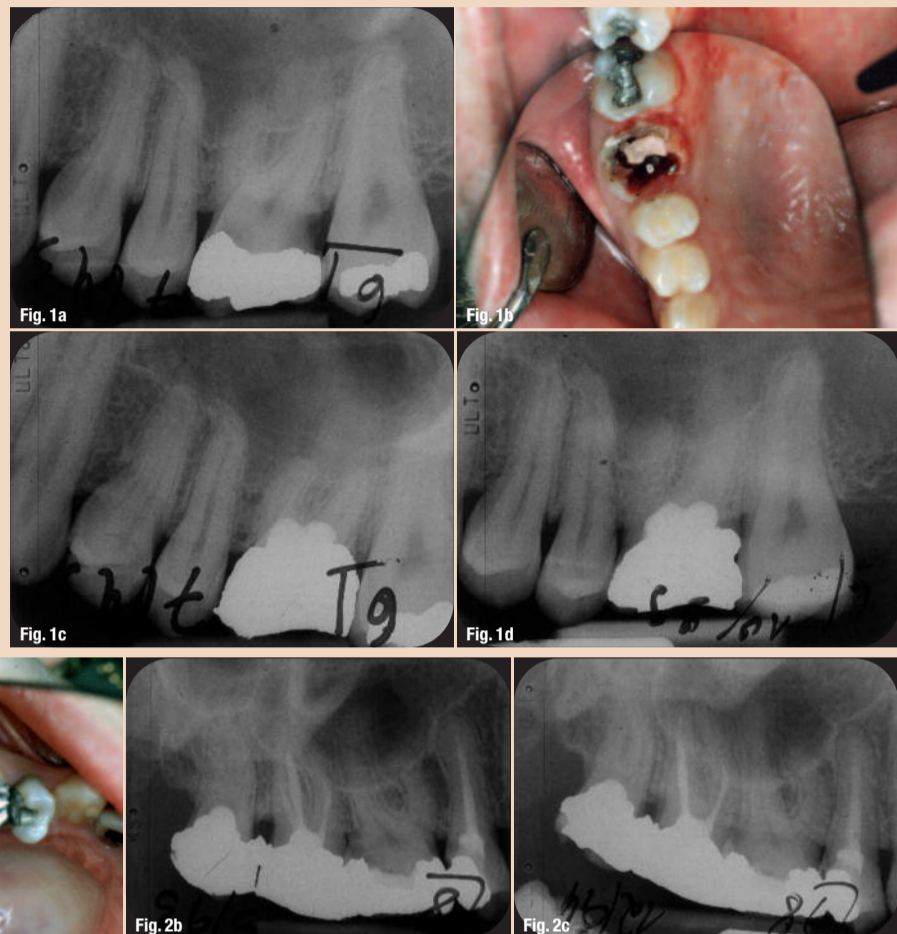
According to Alacam, various materials are recommended for pulpotomy: Ca(OH)₂, formocresol, glutaraldehyde, ferrous sulphate, zinc oxide eugenol and polycarboxylate cement.¹⁰ Salako et al. compared MTA, formocresol, ferrous sulphate and bio-active glass with regard to their pulpotomy compatibility and found MTA to be the ideal pulpotomy agent.¹¹

Agents that contain CH₂O and Ca(OH)₂ are historically established VA agents for deciduous and permanent teeth. Massler et al. report a clinical success rate of 92 % following VA with Ca(OH)₂.¹² Taking post-operative X-rays into account, the success rate was reduced to 75 % after one year and dropped to 65 % after two to five years. The

Figs. 1a-d 24-year-old patient, VA 16 (16 July 1993); before VA (a); heavy bleeding from the pulp after N2 VA, 16 July 1993 (b); after VA and amalgam filling (c); X-ray control, 29 September 1999 (d).

Figs. 2a-c 30-year-old patient, VA 28 (3 May 1993); prepared cavity (a); after VA and amalgam filling (b); X-ray control, 17 December 1994 (c).

Figs. 3a-d 53-year-old patient, VA 38 (31 October 1995); prepared cavity (a); N2 applied (b); after VA and amalgam filling (c); X-ray control after six years (d).



authors suggest several reasons for this failure:

- _pulp already heavily inflamed initially;
- _too much pressure applied during application; and
- _disposal of the blood coagulum via haemostatic agents.

Mejare and Cvek performed partial pulpotomies using Ca(OH)₂ on 57 permanent teeth (35 molars,

2 premolars).¹³ The patients were six to 15 years old

and their pulpotomy had to be performed at least two years prior to inclusion in the study. Check-ups were performed at an average of 56 months (24 to 140). The teeth were separated into two groups (Table I). Two failures occurred in the first group, in teeth with incomplete root growth (after ten days and 48 months). The other 29 teeth (95.5 %) were treated successfully. In the second group, two failures occurred (after

10 and 24 months) in teeth with periodontal gap enlargement (one tooth with complete

root growth and the other with incomplete root growth).

Molven states that there were no pathological findings in 1,591 root-filled roots in 51.6 % of the cases and in 236 pulpotomized roots in 65 % of the cases.¹⁴ Asgary and Eghbal report the successful use of a new VA agent called CEM, a cement mixture enriched with Ca, in 205 pulpotomies on molars.¹⁵

For comparison, 202 molars were extirpated vitally. The root-canal filling (RCF) was performed via lateral condensation with AH Plus (DENTSPLY DeTrey) as sealant. After seven days, 38 % of the pulpotomy-treated and 60 % of the root-canal-treated patients reported needing analgesics. After six months, 88.94 % of the patients underwent a radiological check-up. The pulpotomy patients revealed a significantly higher success rate (p < 0.001).

The most frequently used VA agent for deciduous teeth is formocresol, a mix of CH₂O, cresol, glycerine and water. A survey showed that formocresol pulpotomies on deciduous teeth were performed by general dentists in 73 % of the cases and by paediatric dentists in 98.2 % of the cases.¹⁶ The frequency of use on permanent teeth was lower: 18.9 % for general and 55.4 % for paediatric dentists.

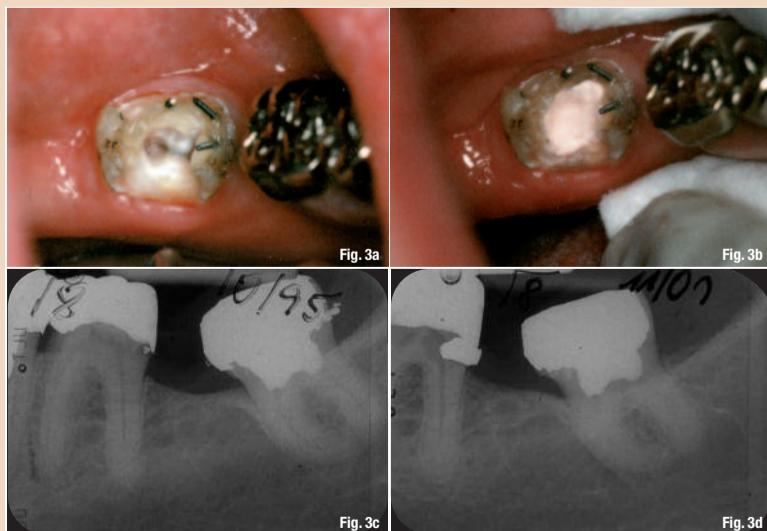
Fisch published the results of pulp amputations of 600 teeth, which were performed with the CH₂O-containing preparation Triopaste.¹⁷ Check-ups were done between six months and 18 years after amputation. Examination of the X-ray controls revealed a pathological apex in 9 %. Eleven teeth were histologi-

cally examined. Hard substance formation was observed in the form of apical foramen closures and apposition at the lateral canal walls, which partially led to obliteration of the canal lumen.

During an accelerated test lasting up to 2.5 months, Overdiek tested N2 as CH₂O-containing VA agent on human teeth. He observed that for several weeks following N2 application there was a possibility of a hard substance barrier forming.¹⁸

Over a period of 12 years, Stern³ carried out 175 N2 pulpotomies under relative isolation on teeth with complete root growth, regardless of possible anamnestic pain. Fifteen per cent of the patients experienced increased pain after treatment, which subsided within 48 hours. Four patients, however, developed pulpitis, which resulted in the extraction of three teeth and conservative RCT of one tooth. Stern was able to track the outcome of 35 vitally amputated teeth over a longer period. During the course of check-ups, two teeth were extracted, one of them due to a fracture. Five years after treatment, Stern observed advancing calcification of the nerve channels.

Frankl considers the advantage of pulpotomy compared with RCT as there being no instrument fractures or perforations during pulpotomy.¹⁹ A possible failure could always be countered with a RCT. He asserts that Ca(OH)₂ pulpotomies can be successful only if teeth are asymptomatic prior to treatment and for accidentally opened pulp and, therefore, bleeding from the pulp.



1 st group (31 teeth)	2 nd group (6 teeth)
(no pathological findings radiographically, no anamnestic pain) 17 teeth with complete root growth, 14 teeth with incomplete root growth	3 with periodontal gap enlargement – 2 of them with pain, 3 with apical ostitis, 5 teeth with complete root growth, 1 tooth with incomplete root growth.

Table I

Powder	Liquid
Zinc oxide 63.0 % Titanium dioxide 3.6 % Bismuth subcarbonate 10.0 % Bismuth subnitrate 15.0 % Paraformaldehyde 7.0 % Red lead (lead oxide) 1.4 %	Eugenol 77.0 % Rose oil 1.8 % Lavender oil 1.2 % Peanut oil 20.0 %

Table II

According to the literature, N2 VA on deciduous teeth renders significantly better results than Ca(OH)₂ pulpotomy. Therefore, Frankl performed N2 pulpotomies on permanent molars, as well.^{19,20} He selected only asymptomatic teeth whose pulp had been accidentally exposed for treatment. The treatment was performed under a rubber dam and thus pulp bleeding did not have any effect. Two hundred and fifty cases were re-examined for up to 15 years. The age of the patients ranged between 22 and 55 years. Failures manifested by pain within 48 hours amounted to 2 %. The aim of the following study was to analyse the success and failure rates of N2 VAs on permanent molars, and to compare these rates with vital molar extirpations done within the same period.

Material and method

The study was conducted in my dental practice, which is located in a rural area. Between 1992 and 1998, 795 VAs and 945 vital extirpations (VEs) were performed on molars. After treatment, 85 VA and 95 VE patients did not return to the practice and were thus excluded from the study, leaving 710 VAs and 852 VE for analysis.

During the treatment period, only N2, which was approved by the district president of Düsseldorf, Germany, on 8 February 1990, was used as therapeutic agent (see Table II for composition).

The root canals were prepared according to the N2 method: relative isolation, no root-canal rinsing and root-canal preparation with reamers only.²¹ For the RCF, N2 mixed to a creamy consistency was applied with a lentulo spiral. The VA cavities were prepared 1 to 2 mm into the canals. N2 mixed to a paste was inserted into the cavity with a filling instrument and lightly pressed with cotton. Minor bleeding was irrelevant. In cases of heavier bleeding, the inserted N2 was removed after a few minutes and then replaced with freshly mixed N2. A synthetic closure of the cavity performed within the same sitting required a lining, which is not necessary for an amalgam closure. X-ray controls were later viewed at double and sevenfold magnification. The apical condition was differentiated as follows: apically without pathological findings, apically uncertain and apically pathological. The root with the worst apical findings was evaluated. This was also applicable for the classification of RCF levels.

Failures without accompanying X-rays were termed Mi1 and failures with accompanying X-rays were termed Mi2. The total failure percentage was not determined by simply adding Mi1 and

Mi2, but by adding the number of Mi1s to the number of X-rays taken. The percentage of failures was then determined from this sum. The statistical analysis was performed using SPSS (version 18).

Results

Of the VA patients 47.6 % were male and of the VE patients 52.4 % were male. The practice owner treated

70.1 % (n = 498) of the VA patients and 49.1 % (n = 418) of the VE patients and all the rest were treated by an assistant. The average age of VA patients was 34.6 years and that of VE patients was 30.6 years. The average observation period was 55.8 months (max. 165) for VAs and 49.4 months (max. 169) for VEs. Of the 710 VA cases

504 (71 %) and of the 852 VE cases 496 (58.1 %) were subject to follow-up X-ray controls.

A total of 61 VA and 77 VE failures were registered and classified as without accompanying X-ray (Mi1) or with accompanying X-ray (Mi2). Fifty-one of the 61 VA failures were followed-up with X-rays. Not all of the accompanying X-rays of the Mi2 failures revealed a failure.

Two VA failure X-rays and ten VE failure X-rays were wrongly evaluated as negative. Ten VA Mi1 cases were removed because of pain, three of them within a few hours after VA.

In two cases, a granuloma at an extracted root was indicated in the patient files. In two additional cases, the extraction followed after six and 11 days. In 12 of the 16 VE cases, extractions were performed because of pain (one day to 21 months after VE). Patients who visited the practice after pulpotomy made positive a negative reference to anamnestic symptomatic pain

241 times and 157 times, respectively. Subsequently, the

failure rate was 10.8 % (n = 26) in the first case and

7.0 % (n = 11) in the latter case. The difference was insignificant statistically (p = 0.114).

The failure diagnosis after VA was most frequently made for the lower second molar (18.5 %) and after VE for the lower first molar (19 %). The lower wisdom teeth were conspicuous because the failure rate was only 4.7 % after VA, and no failure at all was observed after VE. Not every failure diagnosis led to therapeutic consequences such as extractions.

Altogether, 206 (28.6 %) VA and 123 (14.4 %) VE teeth were extracted during the follow-up phase (very statistically significant difference; p = 0.000). The largest number of extractions, namely 51.9 % (n = 107) of the VAs and 46.3 % (n = 57) of the VEs, were performed because the teeth had been destroyed or fractured. The lower wisdom teeth were the most frequently affected in the case of pulpotomy (61.8 %; n = 21) and the upper second molars in the case of VE (64 %; n = 16).

A failure was decisive for the removal of 23.3 % (n = 48) of the extracted VA teeth and 36.6 % (n = 45) of the extracted VE teeth. Most frequently extracted due to failure were the vitally amputated upper second molars (34.8 %; n = 8), and the vitally extirpated lower second molars (54.2 %; n = 13). The lower wisdom teeth (34 extractions (n = 3; 8.8 %) in the pulpotomy group) and the upper second molars (42 extractions (n = 13; 31 %) in the VE group) were extracted least often. The VE and VA results are shown in Tables III and IV.

Furthermore, the question of whether the RCF level following VE had any significance with regard to the failure rate was pursued. The RCF levels were di-

vided into three levels. The total failures of these three groups were calculated as described under material and method (Table V).

Without considering the indication range, anamnestic symptoms, tooth position and RCF level, the total failure rate was 11.9 % for VAs and 15 % for VEs (statistically insignificant; p = 0.644). The VE failure rate of the RCF level of -4, -3 corresponded exactly to the VA failure rate of 11.9 %. There was no statistically significant difference (p = 0.226) in failure between RCF levels -4, -3 and -2, -1, 0. The RCF level of -5 showed significantly more failures compared with the RCF levels of -4, -3 (p = 0.020) and -2, -1, 0 (p = 0.002).

Discussion

A direct comparison between VAs and VEs, especially as regards incomplete root fillings, was only possible within limits, as the number of VAs consisted mainly of a negative selection, which otherwise would have been entrusted to the pliers. The twice as high extraction frequency of vitally amputated teeth compared with that of vitally extirpated teeth (28.6% versus 14.4 %) may be attributed to the adverse baseline situation. Fractured or destroyed teeth were the reason for extraction for 51.9 % of all extractions in the case of VAs. For VEs, this rate was 46.3 %. However, the extraction reason “endodontic failure” was attributed in 36.6 % of the extractions to the VA teeth and in 23.3 % of the VE teeth.

Anamnestic pain causing an increased frequency of failure in VA cases, which was also observed by Teixeira et al. following Ca(OH)₂ treatment,⁷ was statistically insignificant. Stern⁵ and Frankl^{19,20} also point out increased pain following VA. This was observable during our study as well. Nevertheless, the total failure rate for vitally amputated teeth was lower (11.9 %) than the average rate of 15.1 % for vitally extirpated teeth.

The evaluation of pulpotomy cases only with accompanying X-rays revealed a failure rate of 10.1 %, which is comparable to the 9 % Fisch encountered with the Triopaste.¹⁷ Frankl reports only 2 % of failures after N2 VA, although he had done stringent case selection.^{19,20} In contrast, the radiological-pathological findings concerning eugenol pulpotomies in pain-free teeth amounted to 58 % after 12 months.⁴ Fifty per cent of all Ca(OH)₂ pulpotomies of aching teeth resulted in failure after six to eight months.⁷ Massler et al. observed a total failure of 65 %, two to five years after Ca(OH)₂ VAs.¹²

The correlation between failure and RCF level following

VEs was investigated. Adequately filled teeth (-2,-1 adapicem) showed a failure rate of 8.9 %, heavily underfilled teeth a rate of 22.1 %. Hence, the conclusion may be drawn that the success rate of VAs corresponds to the one of properly performed root fillings following VEs, and is far superior to a noticeably underfilled root filling. Molven attributes a more favourable peri-apical situation to pulpotomized than to root-filled roots.¹⁴

In their study, Asgary and Eghbal do not explain the technical performance of the RCF.¹⁵ However, they establish that pulpotomies are statistically significantly superior to RCTs of vital molars, although radiological failure is neither defined nor numerically expressed. Additionally, the follow-up time of six months is considered very brief.

Summary

A comparison of 710 N2 VAs and 852 N2 root-filled molars after VE was done. The average follow-up period was 55.8 months for VAs and 49.4 for VEs. The total failure rate (radiological and clinical) was 11.9 % following VAs, which is equivalent to that of VEs with slight underfilling (RCF level -4, -3). Adequately filled root canals led to fewer failures (8.9 %) than VAs. With a failure rate of approximately 19 %, the lower first VE- and second VAmolars were most frequently affected.

During the follow-up period, 28.6 % of all VA and

14.4 % of VE teeth were extracted. Fractured or destroyed teeth were the reason for extraction in 51.9% of all VA and in 46.3 % of all VE cases. The extraction reason “endodontic failure” occurred less frequently after VA (23.3 %) than VE (36.6 %).

For the practice

The patient should be advised of possible pain following the subsiding anaesthetic effect. Analgesics are indicated after VA. An N2 VA is more successful than an insufficient root filling after VE. Vital amputation is indicated in cases of almost inaccessible canal systems, open apical foramina and for economic reasons.

Instead of an extraction or the impossibility of a VE with adequate root filling, it is possible to consider— besides a full pulpotomy, which was the subject of the present study—a partial pulpotomy on:

- upper molars: VA of the buccal canals, filling of the palatal root;
- lower molars: VA of the mesial canals, filling of the distal root; and
- deep crown margin caries, partial removal of the pulp cavum.

Table IV. Summarised VA results.

Tooth	Σ	I		II		III		Failure IV			V	VI	
		Recall		Extraction		X-ray post VA		IV a Mi 1	IV b Mi 2	IV c Mi 3			X-ray + Mi 1
	n	n	%	n	%	n	%	n	n	%	n	n	%
16/26	109	98	89.9	23	23.5	73	74.5	1	7	9.6	8	74	10.8
17/27	202	179	88.6	45	25.1	127	70.9	3	9	7.1	12	130	9.2
18/28	112	100	89.3	41	41.0	72	72.0	2	9	12.5	11	74	14.9
36/46	118	111	93.2	28	27.0	78	70.3	2	8	10.3	10	80	12.5
37/47	140	123	87.6	35	37.8	90	73.2	2	15	16.7	17	92	18.5
38/48	114	99	86.8	34	34.3	64	64.6	-	3	4.7	3	64	4.7
	795	710	89.3	206	28.6	504	71.0	10	51	10.1	61	514	11.9

Table III. Summarised VE results.

Tooth	Σ	I		II		III		Failure IV			V	VI	
		Recall		Extraction		X-ray post VE		IV a Mi 1	IV b Mi 2	IV c Mi 3			X-ray + Mi 1
	n	n	%	n	%	n	%	n	n	%	n	n	%
16/26	269	241	89.6	42	17.4	142	58.9	3	22	15.5	25	145	17.2
17/27	168	152	90.5	25	16.4	89	58.6	4	7	7.9	11	93	11.8
18/28	5	5	100	1	20.0	2	40.0	-	-	-	-	2	-
36/46	274	249	90.9	24	9.6	148	59.4	4	25	16.9	29	152	19.0
37/47	201	177	88.1	25	14.1	97	54.8	3	9	9.3	12	100	12.0
38/48	28	28	100	6	21.4	18	64.3	-	-	-	-	18	0.0
	945	852	90.2	123	14.4	496	58.2	14	63	12.7	77	510	15.1

RCF level	X-ray + Mi 1		Failures	
	n	%	n	%
-5	195	22.1	43	22.1
-4,-3	194	11.9	23	11.9
-2,-1,0	124	8.9	11	8.9

Table V. VE failures of molars according to RCF levels.

Dental practice in Japan goes Kitty-crazy

TOKYO, Japan: With Hello Kitty, the Japanese wholesale company Sanrio created a trademark that is recognised by consumers worldwide. Last week, the first dental practice fully branded with the white cat's head and characteristic red bow was opened in the capital Tokyo

Bought by dentist Koshika Masanori in November, the facility has been completely renovated over the past two months, featuring pink examination rooms, heart-shaped waiting chairs and chandeliers. According to its website, the practice is currently offering a wide range of dental procedures, including implants, cosmetic dentistry, prophylaxis, and

periodontal and paediatric treatment. Media reports said that the unique project has received full support by Sanrio, whose Japanese headquarters is only 20 minutes away from the practice.

The company introduced its iconic logo modelled on a Japanese bobtail cat in 1974. Nowadays, it can be found on almost any retail



AD


GENGIGEL®
 High molecular weight
 hyaluronic acid (Hyaluronan)
 BIO-TECHnologically manufactured

RICERFARMA S.R.L.
 HUMAN AND VETERINARY

product, including toys, clothing, cellphones and even tooth caps used in orthodontics.

Last year, the brand was reported to have generated over ¥80 billion (US\$1.04 billion) revenues in Japan only

Osteoporosis drug ingredient found useful against periodontitis



BANGALORE, India/CHICAGO, Ill, USA: Certain kinds of bisphosphonates may have potential in treating severe forms of gum disease, a clinical study conducted by Indian researchers has revealed. Clinical specialists from the Government Dental College and Research Institute in Bangalore are reporting that a solution containing Alendronate acid was found to stimulate an increase of probing depth reduction as well as bone fill in patients suffering from aggressive periodontitis.

During a six-month clinical trial, the researchers treated over 50 intrabony defects with a solution made of 1% Alendronate and a polyacrylic acid-distilled water mixture. Other patients with the same conditions were treated with a placebo gel. The results showed an improvement of clinical parameters such as probing depth reduction, clinical attachment level and bone fill in patients treated with the Alendronate solution.

Preparations based on Alendronate are available on the market since 1995. They are used to treat common bone diseases like osteoporosis. Data derived from clinical studies with these drugs has demonstrated a reduction of fracture risks and normalisation of bone turnover rate in postmenopausal women, amongst other benefits.

Exclusive Distributor:
Pharmapal Drug Store
 Tel +971 4 2675001,
 PO Box 37345 Dubai, United Arab Emirates
 www.pharmapaluae.com

Belmont Launches new CP-ONE PLUS

TAKARA BELMONT is known as a world leading manufacturer of dental equipment of high durability and reliability as it has been thoroughly committed to pursuing advanced technologies to manufacture safe, high quality products since 1921.

The CP-ONE PLUS is the latest addition to the dental unit range from TEKARA BELMONT. The CP-ONE PLUS succeeds in taking the concept of the CP-ONE and improving it with advanced technology and comfort. Think of communication, patient comfort and operator comfort.

The CP-ONE PLUS was designed by incorporating dentists' requirements and desires one by one, from the treatment space all the way down to minute details that will be recognized through dentists' fingertips. An ideal treatment environment, the CP-ONE PLUS is a "thinking of all" dental chair and unit, the answer to dentists' aspirations, made possible only through the fusion of the expertise and technological leadership of TAKARA BELMONT.

able cuspidor bowl, the optional electrically-motorized rotatable cuspidor bowl is available to facilitate patient access. The movement of the hydraulic powered head-rest causes the mouth to naturally open wide, decreasing the burden of the patient. Additionally, the newly-designed arm-rest and optional leg-rest heater offer luxury and relaxation for patients.

Thinking of Operator Comfort

The CP-ONE PLUS not only addresses operator's daily requirements, but also meets your unfulfilled demands. The arc delivery system that is inherited from the CP-ONE allows effort-less transfer of instruments and smooth positioning adjustment of the doctor

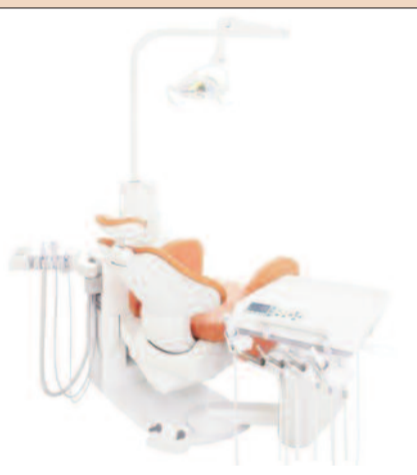table providing the optimum position anywhere from 8 to 2 o'clock, that give you an unprecedented operating style. The redesigned instruments holder is adjustable horizontally and vertically, which ensures that the dentist always has his tools within easy reach. Two types of instruments storage are available, holder, and place type. Both types are detachable and autoclavable to enhance hygiene.

The newly developed foot controller (electric control) is controlled by either pressing and/or

turning the disk, which provides precise instruments control. The assistant instrument holders are detachable and autoclavable. In addition, various types of cups (paper, plastic, stainless) can be used due to the new cup-filler sensor.

Upholstery is available from an extensive selection of 18 colours. Furthermore the newly-developed LED dental light equipped with 10 white LED modules is coming soon as an extra option. [\[1\]](#)

AD




Thinking of Communication

The CP-ONE PLUS is a comfort ergonomically designed folding leg-rest chair and base-mounted unit enabling patients to access to the chair either from front or from side with ease. It can be put in a 6-o'clock face-to-face treatment. Standing directly in front of the patient gives the doctor an accurate picture of the patient's jaw and bite. CP-ONE PLUS provides a 90 degree eye-contact position that is conducive to a natural, stress-free atmosphere for discussion, and provides for relaxed, thorough communication. The patient perfectly communicates what they are feeling, and the doctor communicates what they intend to do.

Thinking of Patient Comfort

To provide true comfort for all patients including children, the elderly and those with limited mobility, the CP-ONE PLUS is designed with abundance of new innovative features. The folding leg-rest chair with low initial height of 40mm secures easy access.

The new shock-less hydraulic system eliminates any jarring movements of the chair, keeping patients calm and comfortable ensuring a stress-free treatment. Besides the standard manually rotat-



Belmont leads the way with a totally new generation of dental treatment centre.

CLESTA II

Belmont has combined cutting edge technology with traditional values for a dental treatment centre that offers sophistication, performance, flexibility and above all durability.

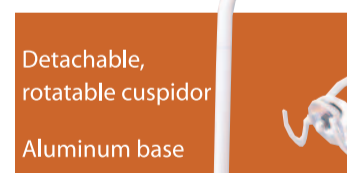The Clesta II epitomizes Belmont's reputation for innovation, style, practicality and reliability. Technologically advanced and superbly engineered it represents a new generation of dental systems.



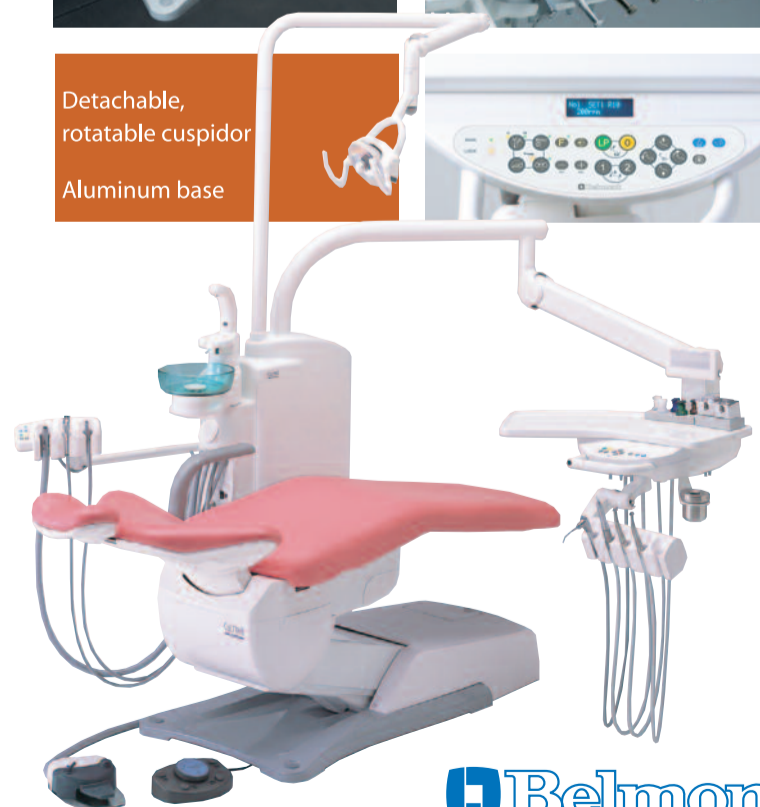Clesta-II E Rod type



Clesta-II E Holder type



Detachable, rotatable cuspidor
Aluminum base



TAKARA BELMONT CORPORATION
Tel. +81 (0)6 6213 5945 Fax. +81 (0)6 6212 3680

e-mail : belmont-7@belmont-corp.co.jp <http://www.takara-net.com>