

cosmetic

dentistry beauty & science

1 2016

trends & applications

An innovative adhesive luting protocol

case report

Between BOPT and BTA:
Shaping the gingival contour

practice management

Eleven tips for success
in your dental clinic

dti] Dental
Tribune
International

B1 GUARANTEED WHITENING

THE ONLY WHITENING SYSTEM IN
THE WORLD TO GUARANTEE RESULTS



ENLIGHTEN®

OVER 200,000 TREATMENTS
WITH 98% SUCCESS RATE
TO VITA SHADE B1

Contact us to arrange a skype meeting.
Distributors Wanted

Email:
international@enlightensmiles.com



Dear Reader,

It is interesting to note the trends in cosmetic dentistry training these days. Cosmetic dentists are spending time and money learning various smile design techniques and protocols. In recent years, the use of computer-guided digital devices (hardware and software) in smile design has become quite popular and many clinicians are already trained in different kinds of digital smile design protocols.

If we carefully analyse digital smile design techniques or protocols, it can be established that they generally follow three steps: photography, digital analysis (calculation) and digital wax-up (drawing, cut and paste). After these clinical steps, dentists have two choices for achieving the final trial smile. The first and most popular one is a laboratory-fabricated acrylic or composite restoration and the other one is CAD/CAM fabricated. For the manual approach, the laboratory technician has to manually wax up the digital design. Even though digital smile design uses computer-guided techniques and protocols, the entire design process is not that as fast as many clinicians may think. This is because the dentist needs to develop specific computer graphic skills, be involved in digital communication with the laboratory, as well as pursue emotional counselling and marketing tactics.

Several months ago, I asked some of my close Asian, American and European friends who have completed various digital smile design courses about the use of digital smile design protocols in their daily practice. It was surprising to learn that none of these popular cosmetic dentists regularly use digital smile design in their practice. They frankly informed me that such techniques are time-consuming and computer design is not as easy as the day-to-day restorations that they do. I was also told that they use digital smile design protocols only when they need to present clinical cases for conferences or seminars.

I was quite pleased with their candid comments, as I rarely use digital smile design myself, because I do not want to give stock smiles to my patients based on universal design formulas. I apply art more than science when designing new smiles for my patients. I respect my patients' personal desires and needs and guide them in achieving natural and realistic smiles with low biological cost. I have never sold cosmetic dentistry using the emotional counselling tactics of digital smile design, because I firmly believe that exploiting emotions to sell cosmetic dentistry actually constitutes emotional blackmailing of patients.

Keeping all of the above in mind, I have recently developed a simple "Quick Smile Design" concept, which is not new but a logical modification of the age-old direct composite mock-up technique. The beauty of this simple technique is that it is fast, realistic and predictable. You do not need to open your computer and spend time using Photoshop. Your patients will instantly be able to give their comments about the aesthetics and level of comfort of your smile design. You do not need to acquire computer graphic skills. Moreover, this technique indirectly enhances the dentist's direct cosmetic restoration skills. I hope you will have the opportunity to learn about it in the upcoming issue of the **cosmetic dentistry** magazine.

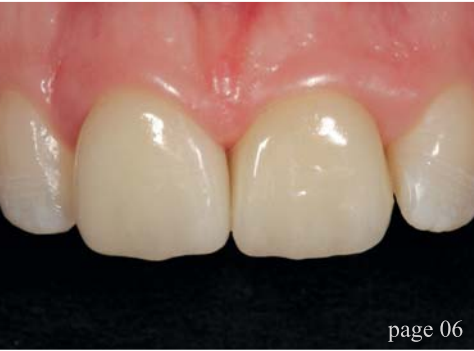In this issue, we have also selected some articles on smile design and cosmetic restorations. I hope you will enjoy reading them.

Sincerely,

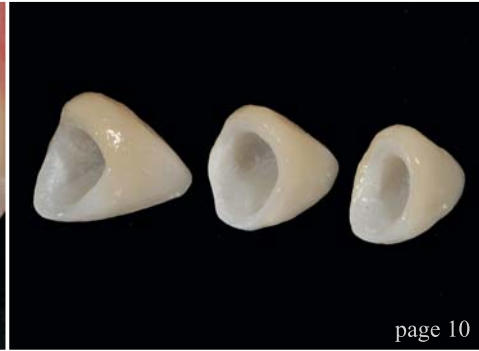Dr Sushil Koirala
Editor-in-Chief



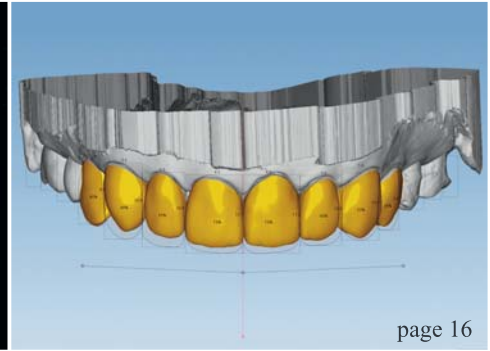

Dr Sushil Koirala



page 06



page 10



page 16

| editorial

03 **Dear Reader**
Dr Sushil Koirala, Editor-in-Chief

| opinion

32 **What do our teeth betray about us?—Part II**
Dr Stanislav Cícha

| trends & applications

06 **An innovative adhesive luting protocol**
Prof. Claus-Peter Ernst

| practice management

36 **Eleven tips for success in your dental clinic—Part I**
Dr Anna Maria Yiannikos

| case report

10 **Between BOPT and BTA: A case report on shaping the gingival contour**
Dr Feng Liu

| news

16 **Utilising smile design software and CAD/CAM for creating a mock-up and final restorations**
Aki Lindén

| meetings

44 **Roots Summit 2016**
Premier global forum for endodontics takes place in Dubai

20 **Conservative smile design for the general dentist**
Dr Rami Chayah

46 **Where innovation comes to life**
Nobel Biocare Global Symposium

48 **International Events**

| feature

24 **“We will be able to treat pretty much everything in the future”**
Interview with Dr Graham Gardner, EAS President

| about the publisher

49 submission guidelines
50 imprint

28 **Light and the biological clock**
Antonín Fuksa



Cover image courtesy of Enlighten.



page 20

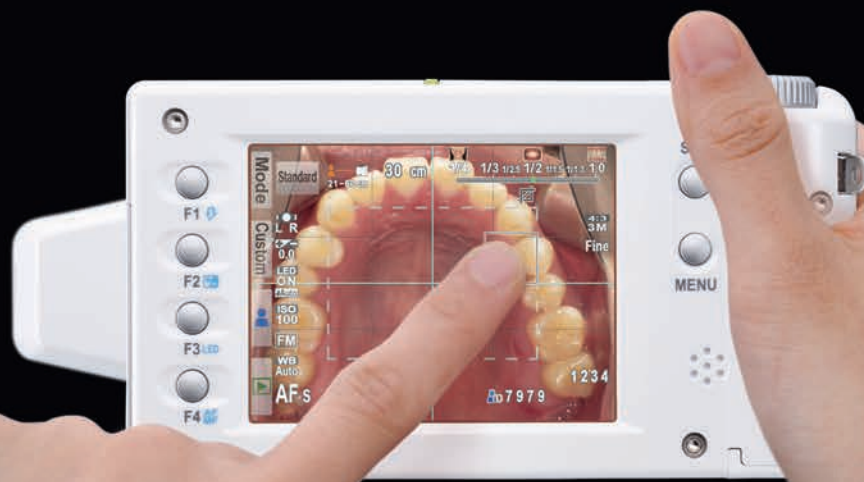

page 36



page 46

Now, everyone in your dental team can *SHOOT!*



Ultra-Light
SIMPLE Compact
Accurate
Intuitive

SHOFU Smart Digital *EyeSpecial C-II*

- The only one true dental camera
- 8 automated pre-set dental modes
- Intuitive one-touch operation with built-in anti-shake
- Large LCD touchscreen with on-screen guide
- Fast auto-focusing capability and excellent depth of field
- Water and chemical resistance
- Registration and imprinting of patient ID
- Uncomplicated photo management system



For more information, simply contact us or your nearest **SHOFU** dealer.



SHOFU DENTAL ASIA-PACIFIC PTE. LTD.

10 Science Park Road, #03-12 The Alpha Science Park II, Singapore 117684

Tel (65) 6377 2722 Fax (65) 6377 1121 eMail mailbx@shofu.com.sg website www.shofu.com.sg

An innovative adhesive luting protocol

All-ceramic anterior crowns (IPS e.max Press lithium disilicate) placed with Monobond Etch & Prime

Author: Prof. Claus-Peter Ernst, Germany

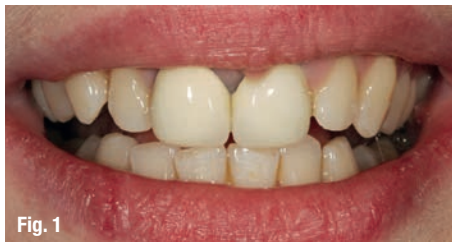

Fig. 1

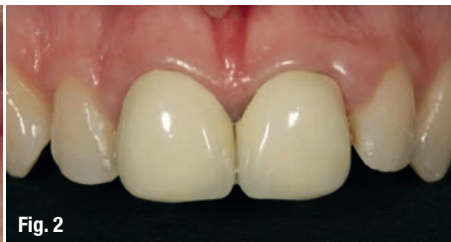

Fig. 2

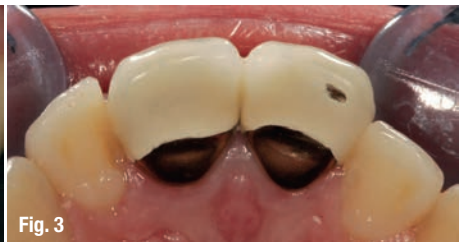

Fig. 3

Fig. 1: Unattractive, old porcelain-fused-to-metal restorations on teeth #11 and 21 in a 20-year-old patient.

Fig. 2: Close-up photograph of the functionally intact anterior crowns showing unattractive PFM work due to the metal framework showing through.

Fig. 3: Incisal view of the existing crowns.

Fig. 4: The self-conditioning ceramic primer Monobond Etch & Prime is scrubbed in for 20 seconds.

Fig. 5: Additional reaction time of Monobond Etch & Prime of 40 seconds.

Fig. 6: Apical view of the IPS e.max Press lithium disilicate crown after Monobond Etch & Prime had been rinsed off.

Anterior crowns come in many different variations, from purely functional to highly aesthetic, depending on the requirements and means of the patient, the skill of the dental technician, availability of materials, and preparation and cementation procedures used. Many anterior crowns considered to be aesthetic in the past no longer meet the demands of today's patients. The example detailed in this article is a case in point.

When she presented to our practice, the 20-year-old high school graduate wished to have the crowns on her two central incisors replaced (Fig. 1). At the age of 14, she had sustained anterior tooth trauma that apparently damaged the mesio-incisal part of the incisal edges of both teeth. The dentist she had consulted at that time restored her teeth with porcelain-fused-to-metal (PFM) crowns. Even though

the extent of the trauma can no longer be assessed, today's alternative—in light of the patient's young age in particular—would most probably have been a direct composite restoration.

Figure 2 shows the two central incisors in detail from the labial aspect and Figure 3 shows an incisal view. The crowns did not exhibit any functional defects. As a result, the main treatment aim was to improve the aesthetic appearance of the anterior teeth as requested. Subsequently, the patient was informed about the treatment procedure, in particular about any possible additional preparation requiring the removal of tooth structure, as well as the cost involved.

The treatment was begun at a separate appointment. The restorations were fabricated by the dental

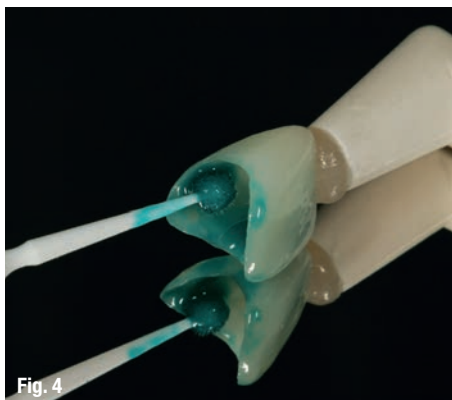


Fig. 4

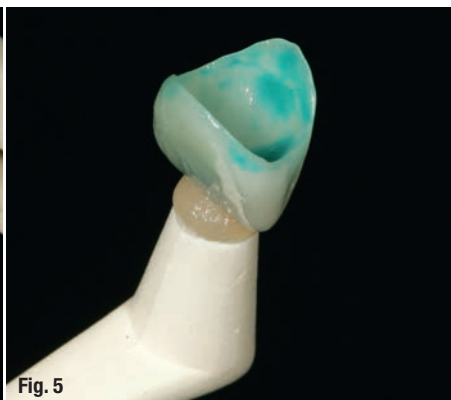

Fig. 5

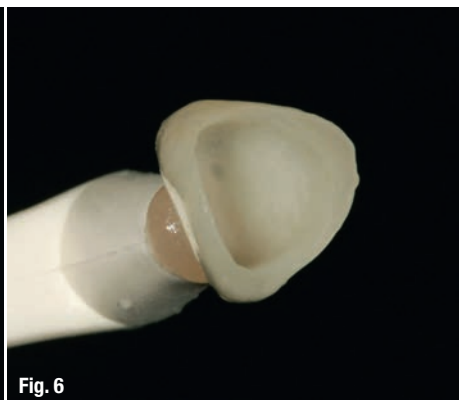
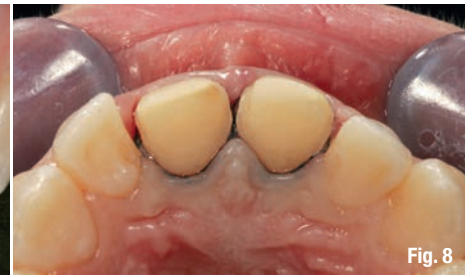
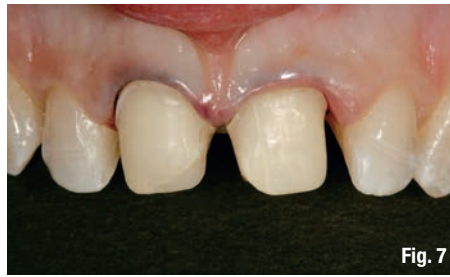Fig. 6

laboratory of Hildegard Hofmann (Mainz, Germany). Pressed all-ceramic IPS e.max lithium disilicate (Ivoclar Vivadent) crowns were selected for this case, since they are the first choice for this type of indication. This has been confirmed by numerous clinical studies, including the recently published German S3 Clinical Practice Guideline on ceramic restorations.



The teeth were anaesthetised at the placement appointment. The crowns were removed and the bonding surfaces were carefully cleaned with ultrasound and a fluoride-free cleaning paste. Since the new Variolink Esthetic DC (Ivoclar Vivadent) had been chosen as the luting material, the crowns were tried in with the corresponding try-in pastes. An immediate match to the adjacent and the mandibular anterior teeth was achieved with the Neutral shade. No adjustments were necessary with regard to a lighter (Light) or darker (Warm) shade of the luting composite. We attributed this excellent match to the dental technician having selected the shade at the chairside. The extra expense of this step far outweighs the inconvenience of having to make numerous adjustments or new restorations because of a shade mismatch.

Conditioning of the crown

Saliva and residue of the try-in paste were removed (Ivoclean, Ivoclar Vivadent) from the crowns before they were conditioned. It is advisable to fabricate a "handle" to allow the inner crown surfaces to be conditioned without having to touch the crown with the fingers. In this case, the crowns were attached to a brush holder with a light-curing provisional composite. This handle also allowed the crowns to be placed with ease during the luting procedure. As an alternative, an OptraStick (Ivoclar Vivadent) could have been used. Hydrofluoric acid etching of glass-based ceramics and subsequent silanisation has been an accepted conditioning method for decades. The newest studies confirm its effectiveness. It even generates a strong bond on state-of-the-art ceramic materials such as hybrid ceramics. An acid concentration of 5 per cent has been established, which represents

a reasonable compromise according to the latest research.

The new Monobond Etch & Prime (Ivoclar Vivadent), which was introduced at the 2015 International Dental Show, is a conditioning material based on ammonium polyfluoride. The product is actively scrubbed on the bonding surface (Fig. 4) for 20 seconds, thereby removing any contamination with saliva or silicone. After another 40 seconds (Fig. 5), the ammonium polyfluoride reacts with the ceramic surface and produces a rough etching pattern. Even though this pattern is not as pronounced as that of conventional 20 seconds etching with 5 per cent hydrofluoric acid, the bonding results achieved in both cases are comparable. The enlarged surface created in this way helps to activate the ceramic bonding surface.

The restoration is subsequently rinsed to remove the ammonium polyfluoride and its reaction products. The reaction of the silane and the activated glass-ceramic then begins. A thin layer of chemically bonded silane remains on the ceramic after its distribution with blown air. This product, therefore, combines the steps of hydrofluoric acid etching and silanisation and it even appears to render cleaning with Ivoclean superfluous. The currently available *in vitro* data justifies using this new product with due care to replace the hydrofluoric acid etching and silanising method. Even though it has not been shown to improve the bonding values in relation to the established references, no negative effects on the adhesive bond have been found to date either. Moreover, since the adhesive bond to glass-ceramics is considered to be the most unproblematic interface in the bonding process of indirect restorations, no clinical irregularities are to be expected.

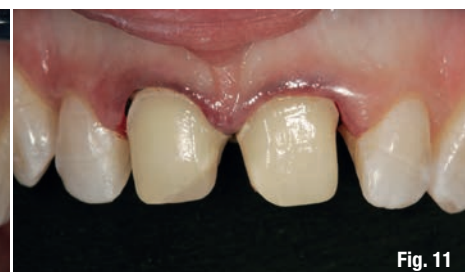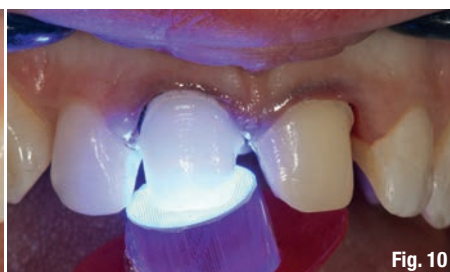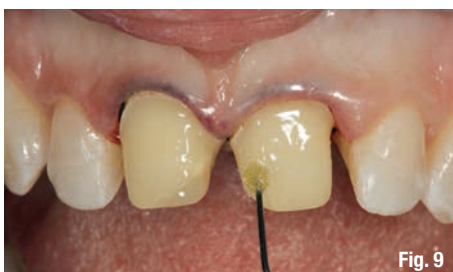Fig. 7: Conditioning of the prepared teeth for the adhesive cementation of the restorations under cotton roll isolation. Retraction cords were placed in the sulcus to prevent any contamination with sulcular fluids.

Fig. 8: Incisal view of the prepared teeth.

Fig. 9: Application of Adhese Universal adhesive with the pen applicator.

Fig. 10: Light polymerisation of the adhesive after careful distribution with blown air.

Fig. 11: The polymerised adhesive layer on teeth #11 and 21.



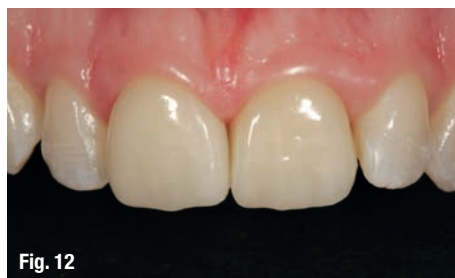

Fig. 12

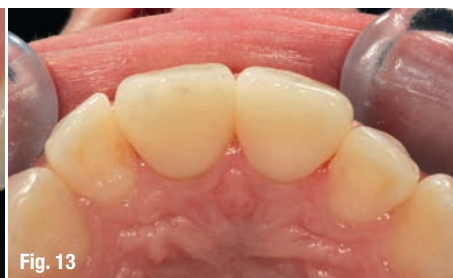

Fig. 13

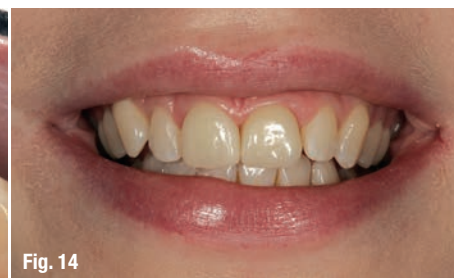

Fig. 14

Fig. 12: The IPS e.max Press lithium disilicate crowns, cemented with Variolink Esthetic DC, at the follow-up examination after four weeks.

Fig. 13: Incisal view of the crowns at the follow-up examination after four weeks.

Fig. 14: Frontal view of the anterior teeth. A significant aesthetic improvement over the initial situation was achieved.

In the case presented, the crowns could even have been placed by conventional or self-adhesive means. The loss of retention would have been as unlikely as the occurrence of a ceramic fracture due to inadequate adhesive support. Figure 6 shows one of the two crowns after Monobond Etch & Prime had been rinsed off and the surface dried with blown air.

Cementation of the crowns

Variolink Esthetic DC was used for the adhesive cementation of the crowns. As this luting system is a full adhesive, sufficient moisture control must be ensured. Owing to the equi-gingival preparation margin, the healthy condition of the gingiva and the excellent cooperation of the patient, the placement of a rubber dam was not essential. Therefore, cotton roll isolation was used to seat the crowns. Two retraction cords (Ultradent Products) were placed to prevent any contamination with sulcular fluids (Figs. 7 & 8).

The bonding surfaces were cleaned with a fluoride-free prophylaxis paste. Next, Adhese Universal adhesive (Ivoclar Vivadent) was applied from the pen applicator (Fig. 9). The remaining thin enamel margin was not etched, in order to prevent any gingival bleeding. Adhese Universal was scrubbed into the conditioned tooth surface for >20 seconds as stated in the directions for use. According to the manufacturer, this time should not be reduced, as it is not sufficient to simply paint the adhesive on to the tooth surface. Next, the adhesive was dried with blown air until an immobile, glossy film was left. The adhesive was then light cured for 10 seconds (Fig. 10).

Since the universally compatible adhesive forms a considerably thinner film than does Heliobond (Ivoclar Vivadent), for example, it can be light cured without encountering any subsequent problems of fit or bite elevation. The polymerised adhesive layer on teeth #11 and 21 is visible in Figure 11. Figures 12 and 13 show the adhesively cemented IPS e.max lithium disilicate crowns at the final follow-up appointment, four weeks after the treatment. The gingiva was free from any irritation and the crowns

blended in smoothly with the surrounding teeth. The tremendous improvement in the appearance of the anterior teeth achieved with the all-ceramic restorations on teeth #11 and 21 is visible in the close-up photograph shown in Figure 14. For the first time in many years, the patient dared to smile again (Fig. 15).

Conclusion

It takes quite a bit of courage to use innovative products and procedures, such as those described in this article. Adequate clinical data is not yet available, let alone the much-needed long-term studies. Nonetheless, a start must be made somewhere. For those dental practitioners who would like to be rid of hydrofluoric acid sooner rather than later, the described self-conditioning glass-ceramic primer may offer a viable option.

Since the etching time has a significant influence on the strength of the ceramic when hydrofluoric acid is used to condition ceramic restorations, the specifications of the manufacturer must be strictly observed. IPS e.max Press lithium disilicate should be etched for 20 seconds if 5 per cent hydrofluoric acid is used. Other conventional glass-ceramics require 60 seconds of etching. DeguDent (DENTSPLY) recommends that its material CELTRA be etched for 30 seconds. The reaction time of Monobond Etch & Prime is 60 seconds on all types of ceramics. Thus, it offers a first step in the direction of error prevention. It remains to be seen whether external studies can confirm the effectiveness of the product in establishing an adhesive bond on ceramics other than those from Ivoclar Vivadent.



Fig. 15

Fig. 15: Photograph of the satisfied patient.

contact



Prof. Claus-Peter Ernst works at the Johannes Gutenberg University of Mainz Medical Center's polyclinic for restorative dentistry in Mainz in Germany. He can be contacted at ernst@uni-mainz.de.

ROOTS SUMMIT

30 NOVEMBER - 3 DECEMBER, 2016

THE MASTERS OF ENDODONTICS



Antonis Chaniotis
Greece



David E. Jaramillo
USA



Freddy Belliard
Dominican Republic/Spain



Oscar von Stetten
Germany



Rafaël Michiels
Belgium



Enrico DiVito
USA



Sergio Rosler
Argentina



Imran Cassim
South Africa



Siju Jacob
India



Bojidar Kafelov
Bulgaria



Mile Churlinov
Bulgaria



**Roberto Cristian
Cristescu**
Romania/Netherlands



**Luis Chávez
de Paz**
Peru/Sweden



**Ronald Ordinola
Zapata**
Peru



**Carlos Aznar
Portoles**
Spain/Netherlands



**Ahmed Abdel
Rahman Hashem**
Egypt

ARE MEETING IN DUBAI
WITH THE ROOTS COMMUNITY

DATE: 30 NOV - 3 DEC
LOCATION: CROWNE PLAZA, DUBAI

ROOTS
SUMMIT

30 NOVEMBER - 3 DECEMBER, 2016

EARLY BIRD 20% OFF
REGISTER AT WWW.ROOTS-SUMMIT.COM