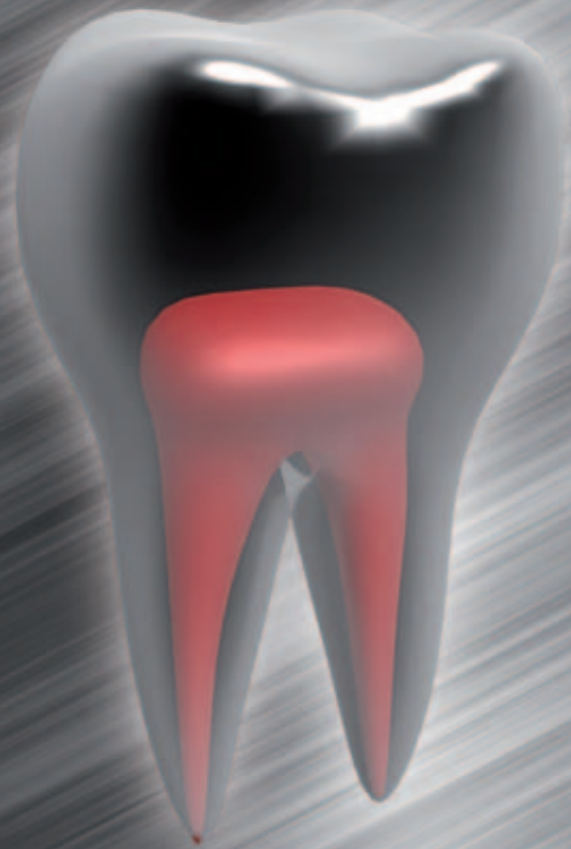


roots

international magazine of endodontology

3²⁰¹²



| **special**

Endodontic retreatment:
Achieving success the second time around

| **technique**

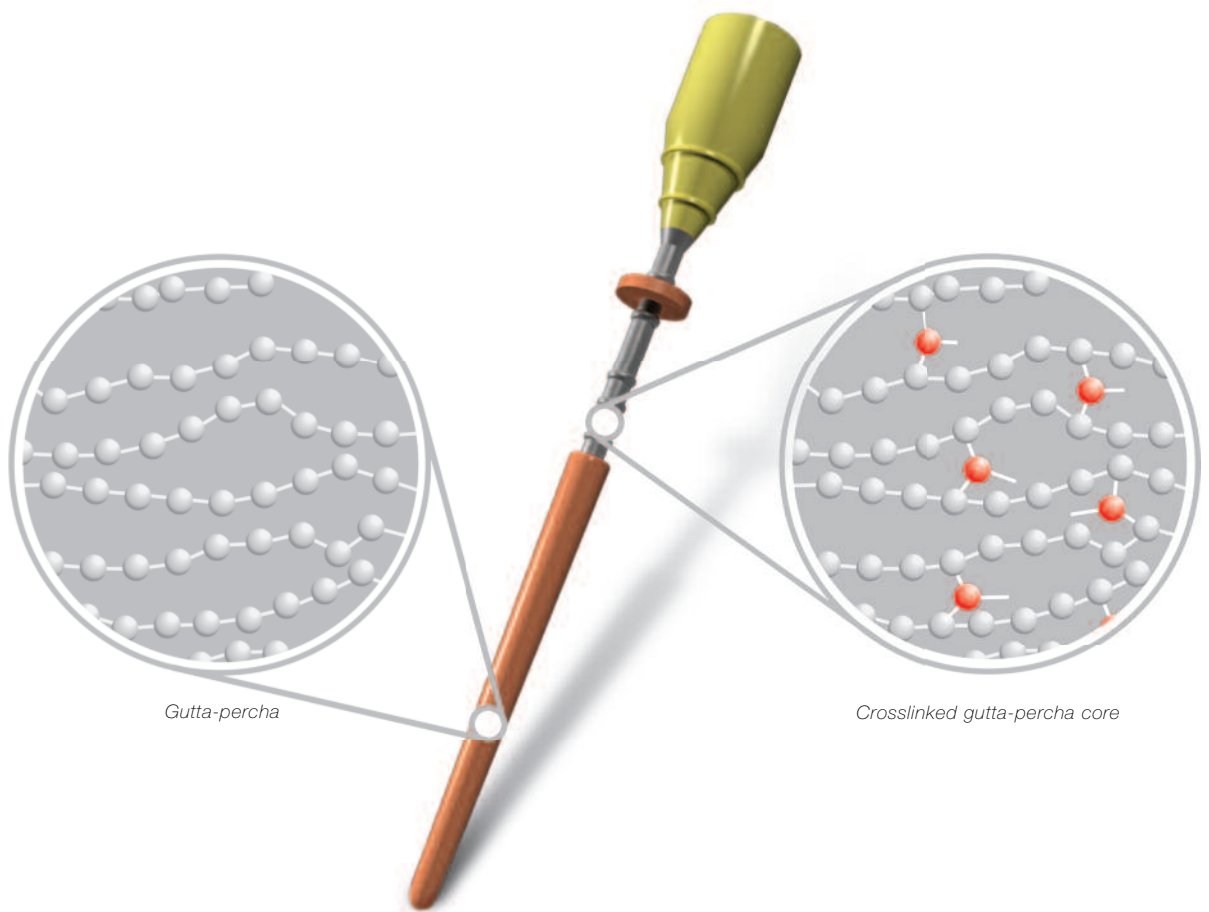
Positive versus negative pressure irrigation

| **research**

Dentine thickness in buccal roots
of maxillary first premolars following
preparation with three techniques

gutta•core™

crosslinked gutta-percha core obturator



- superior 3D fills
- ease of retreatment
- post space simplified

Dear Reader,



Bogdan Dimitriu, DDS, PhD

As a professor and international speaker, every year I meet hundreds of young people full of enthusiasm, pursuing their goal to conquer the endodontic world. This is beautiful, but even more beautiful is when I meet my former students, after ten or 15 years, and they still have the same passion as before. Unfortunately, it rarely happens. Why is that? What happened to their enthusiasm all these years later? Why do recent developments and trends in endodontics no longer appear to fascinate them?

On the one hand, industry is overwhelming dentists with innovative materials and technologies, which have developed rapidly in recent years. On the other hand, there is a lack of information and evidence-based literature on when and how to use them correctly. It is confusing; thus, many dentists prefer to follow traditional procedures instead of pursuing new solutions and knowledge. This leads to a routine which is very well known to kill any previous passion that could have existed.

I therefore consider to be of paramount importance to undertake continuing professional development by attending congresses, following courses and reading literature. It is only in this way that you will remain up to date and as enthusiastic as before, I hope.

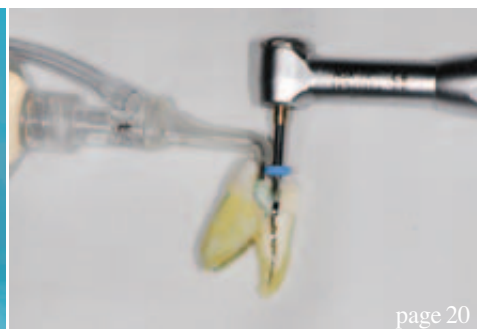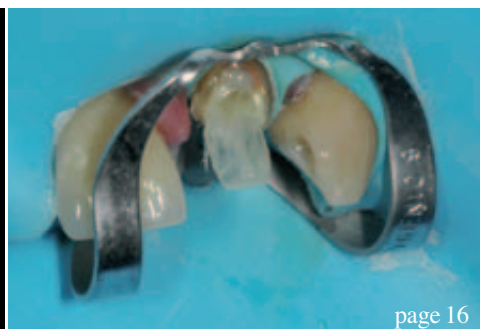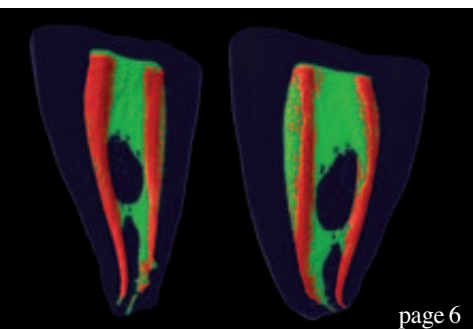
One year from now, in September 2013, a beautiful Lisbon will host the largest endodontics meeting in Europe: the 16th Biennial Congress of the European Society of Endodontology, organised in collaboration with the Portuguese Society of Endodontology. I encourage you to put this event in your schedule today already, as there will be a lot to learn at the congress.

Continuing professional education together with the exchange of experiences will keep us moving forward with passion that both, us and our patients really need.

Yours faithfully,



Bogdan Dimitriu, DDS, PhD
Professor and Chair, Department of Endodontics
Deputy Dean, Faculty of Dental Medicine „Carol Davila“ University
Bucharest, Romania



| editorial

03 **Dear Reader**
| Prof Bogdan Dimitriu

| special

- 06 **Endodontic retreatment:** Achieving success the second time around
| Dr Brett E. Gilbert
- 10 **Non-surgical retreatment** following failed apicoectomy with re-use of intra-radicular restoration
| Dr Imran Cassim

| case report

16 **The use of direct FRC posts** in the restoration of endodontically treated anterior and premolar teeth
| Dr Ian Kerr

| technique

- 20 **Positive versus negative pressure irrigation**
| Dr Gregori M. Kurtzman
- 26 **Determining working length**
| Dr Chris J. Lampert

| feature

28 **The right to be pain free**
| Dr Michael Sultan

| research

30 **Dentine thickness** in buccal roots of maxillary first premolars following preparation with three techniques
| Dr Paola Adriana Lammertyn et al.

| industry news

- 36 **Moisture-activated temporary filling** and sealing material
| Centrix
- RAYPEX 6**— State-of-the-art technology
| VDW

| meetings

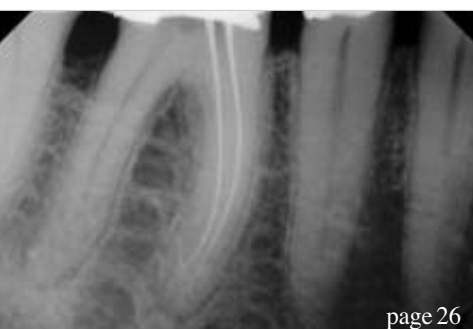
- 38 **IDS 2013:** Organisers expect successful exhibition
- 40 **International Events**

| about the publisher

- 41 | submission guidelines
- 42 | imprint



Cover image courtesy of © Sgame (image) and © Gilmanshin (background).





No Pre-Registration Fee

**The Largest
Dental Meeting/
Exhibition/Congress
in the United States**

MARK YOUR CALENDAR

**Scientific Meeting:
Friday - Wednesday,
November 23 - 28**

**Exhibit Dates:
Sunday - Wednesday,
November 25 - 28**

ATTEND AT NO COST
Never a pre-registration fee at the
Greater New York Dental Meeting

MORE THAN 600 EXHIBITORS
Jacob K. Javits Convention Center 11th Ave.
between 34-39th Streets (Manhattan)

HEADQUARTERS HOTEL
New York Marriott Marquis Hotel

LIVE DENTISTRY ARENA - NO TUITION

**LATEST DENTAL TECHNOLOGY
& SCIENTIFIC ADVANCES**

MORE THAN 350 SCIENTIFIC PROGRAMS
Seminars, Hands-on Workshops, Essays
& Scientific Poster Sessions as well as
Specialty and Auxiliary Programs

**EDUCATIONAL PROGRAMS
IN VARIOUS LANGUAGES**

SOCIAL PROGRAMS FOR THE ENTIRE FAMILY

**ENJOY NEW YORK CITY AT ITS BEST
DURING THE MOST FESTIVE TIME
OF THE YEAR!**

FOR MORE INFORMATION:
Greater New York Dental Meeting®
570 Seventh Avenue - Suite 800
New York, NY 10018 USA
Tel: (212) 398-6922 / Fax: (212) 398-6934
E-mail: victoria@gnydm.com

**GREATER
N.Y.
DENTAL MEETING**

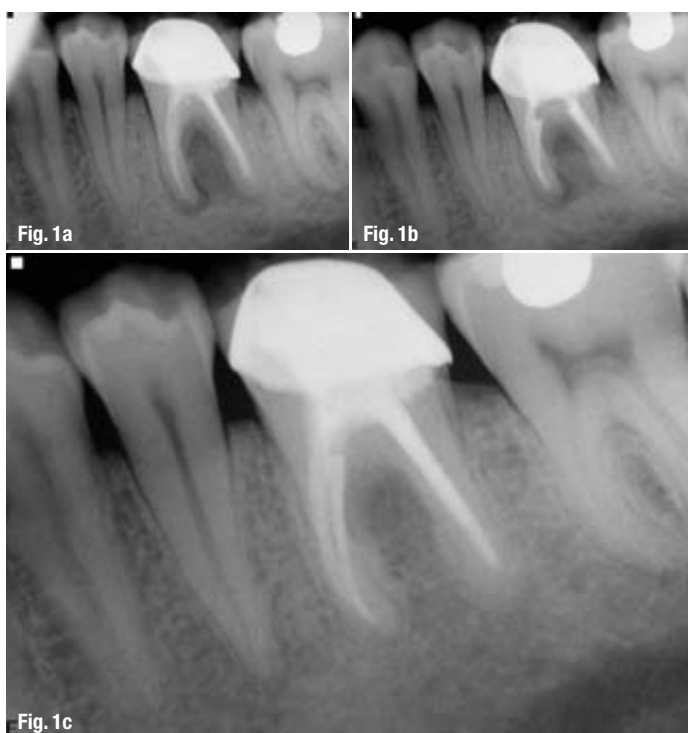
WWW.GNYDM.COM

Sponsored by the New York County Dental Society and the Second District Dental Society

2 0 1 2

Endodontic retreatment: Achieving success the second time around

Author_ Dr Brett E. Gilbert, USA



strictest of criteria for determining that a tooth has healed, and includes many studies that were completed prior to the clinical use of dental operating microscopes and other advanced armamentaria.

When considering treatment for a tooth that has not healed successfully with root-canal therapy, there are significant challenges to address to be able to attain complete healing of the diseased tooth. The armamentarium and techniques available today allow us the ability to disinfect the root-canal system properly after initial treatment has led to post-treatment disease.

The success rate of retreatment has been shown to be in the range of 80% healing. Phases III and IV of the Toronto Study showed such a healing rate four to six years after non-surgical retreatment.³ In a systematic review by Torabinejad et al. comparing non-surgical retreatment to endodontic surgery, it was demonstrated that non-surgical retreatment had a success rate of 83% versus 71.8% for endodontic surgery after four to six years.⁴

The presence of pretreatment apical periodontitis is one factor that has been shown to decrease the success rate. Without apical periodontitis, a ten-year success rate of 92 to 98% has been shown for both initial and retreatment root-canal therapy. With the preoperative presence of apical periodontitis, there is a decrease in the success rate to 74 to 86% over the ten years.⁵ From this, it is evident that endodontic healing is attainable through retreatment procedures, allowing us to maintain our patients' natural teeth (Figs. 1a–c). Although the alternative clinical treatment option of implant placement can provide an effective method for replacing a missing tooth, healthy maintenance of the natural tooth should remain the overall goal.

_Root-canal treatment has been shown to have a success rate of 92%.¹ However, as research methodologies move towards higher levels of substantiation, clinicians must rely on the best current evidence available to gain insight into the expected outcomes of their treatment. The highest level and best current evidence we have on the clinical success of endodontic treatment comes from a meta-analysis of the literature.

A meta-analysis done in 2007 by Ng et al. provides a thorough review of endodontic success rates from a variety of classical outcome studies. They found a weighted pooled success rate of 68 to 85%, with at least one year of follow-up.² This review considers the

Fig. 1a_Pre-operative image.
Fig. 1b_Post-operative image.
Fig. 1c_12 month follow-up image.
(Case by Dr. Brett Gilbert)

Post-treatment disease is, inevitably, a result of bacteria and the host response of the patient to the bacteria. These micro-organisms are the most critical aetiology of post-treatment disease, as they are present within the root-canal system of a previously endodontically treated tooth owing to a combination of substandard endodontic techniques, iatrogenic treatment issues and restorative failure.

Intra-radicular bacteria are the primary aetiology of post-treatment disease⁶ and eradication of these bacteria is the primary goal of retreatment procedures. The intra-radicular bacteria present in the previously treated tooth are persistent and resist removal methods. Bacteria are able to hide and survive in canal ramifications, deltas, irregularities (fins) and dentinal tubules.⁷

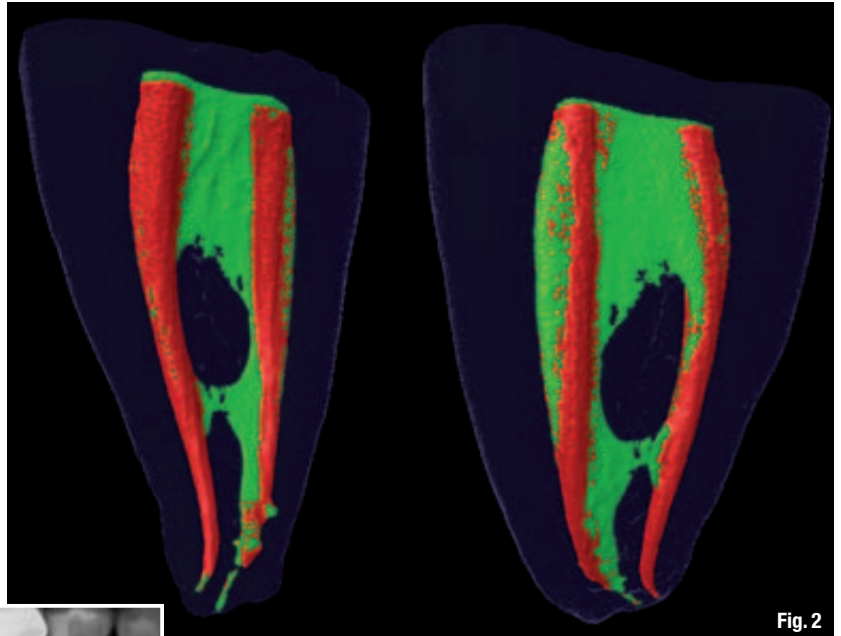


Fig. 2

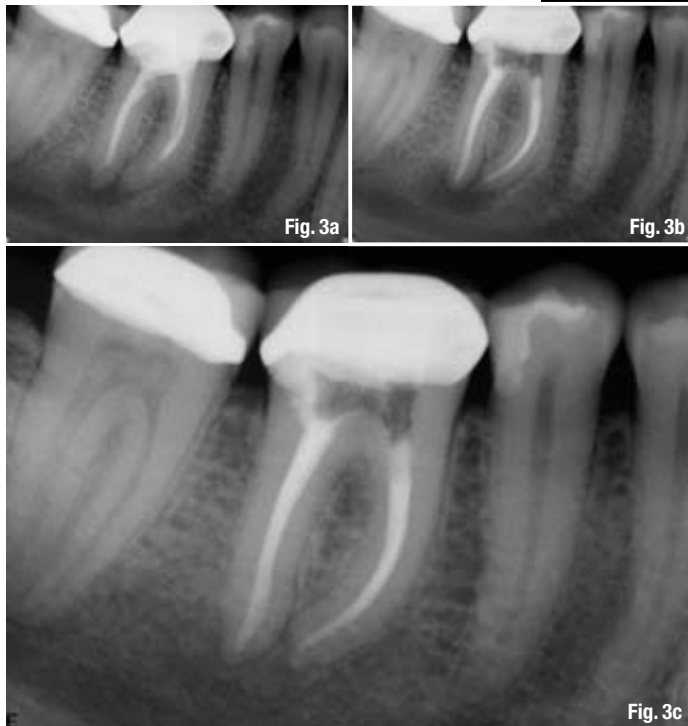

Fig. 3a

Fig. 3b

Fig. 3c

Figure 2⁸ shows the complex root-canal anatomy preoperatively (green areas) and the minimal amount of canal-wall cleansing that was accomplished during canal instrumentation (red areas). The remaining green areas illustrate the space that might be left untreated, thereby providing a source of bacteria and supporting substrate for intra-canal infection. The potential substrates that are found inside the canal and help the bacteria survive can include untreated pulpal tissue, the presence of a biofilm and tissue fluid. This may be present in the canal owing to a poor coronal or radicular seal and microbial proliferation. The presence of a poor seal, bacteria and substrate for their growth results in ideal conditions for persistent inflammation and disease.⁹

The bacteria present in the initial infection of a root canal differ markedly from the bacteria infecting a previously treated tooth. Pre-treatment flora is polymicrobial with equal numbers of Gram-negative and -positive bacteria. Post-treatment bacteria are predominantly Gram-positive¹⁰ and they have been shown to be able to survive in harsh environments and to be resistant to many treatment methods.

Fig. 2 Image displays the unprepared pulpal tissue (in green) and the post-operative prepared or instrumented areas (in red), which is evidence of the complexity of root canal anatomy. (Image courtesy of <http://rootcanalanatomy.blogspot.com>.)

Fig. 3a Pre-operative image.
Fig. 3b Post-operative image.
Fig. 3c 13-month follow-up image. (Case by Dr. Brett Gilbert)

There are high numbers of *Enterococcus* species.¹¹ *Enterococcus faecalis*, for example, has been shown to be a common isolate in 27 to 77% of teeth with post-treatment disease.¹² A contaminated canal space may result from incomplete cleansing initially or

subsequent leakage into root-canal spaces following root-canal treatment. Once present inside the canals, *E. faecalis* has a variety of characteristics that allow it to evade our best efforts to eradicate it from the root-canal system, including the ability to invade dentinal tubules and adhere to collagen.¹³ It is also resistant to calcium hydroxide application inside the canal system, which is an inter-appointment treatment technique used to help remove micro-organisms and their by-products, such as lipopolysaccharides, from the canal space.^{14,15} *E. faecalis*'s resistance of calcium hydroxide action arises from its ability to pump hydrogen ions from a proton pump. The hydrogen combines with the hydroxyl ions of calcium hydroxide and neutralises the high pH value.¹⁶

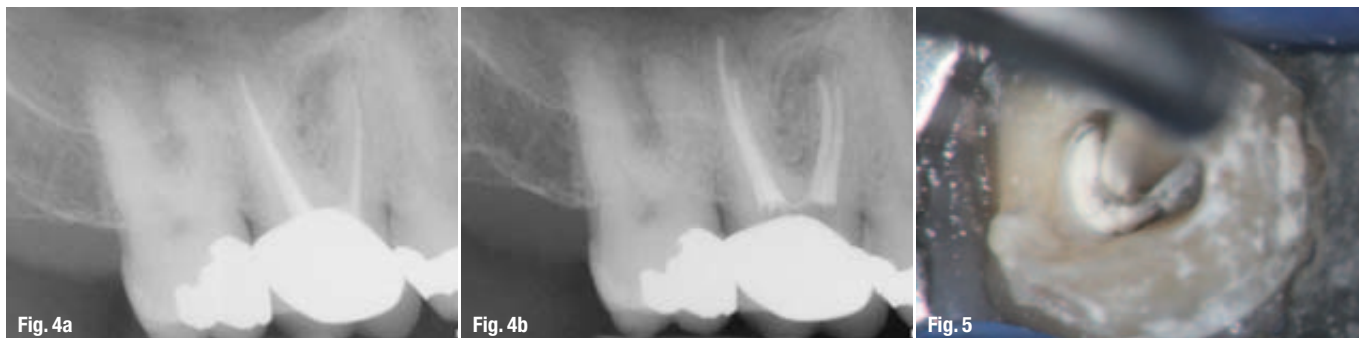

Fig. 4a_Tooth #3 with a radiolucent periapical lesion on the MB root apex.

Fig. 4b_Post- operative image showing treatment of MB2 and appropriate lengths on retreatment of DB and P canals. (Case by Dr. Brett Gilbert)

Fig. 5_Photograph displays excellent visibility and magnification of the pulp chamber with use of an ultra-sonic tip. (Photograph courtesy of Dr. Scott Bentkover)

E. faecalis also able to resist calcium hydroxide by being part of a biofilm. The protection of bacteria within a biofilm matrix prevents the contact of the bacteria with irrigants and medicaments, and allows communication between bacteria to aid in survival capabilities.^{17,18} The presence of *E. faecalis* is well documented; however, its role in post-treatment disease has yet to be proven definitively.¹⁹ Its survival mechanisms, however, shine a light on the persistent capabilities of these bacteria, and our clinical techniques must be focused on the challenge of eliminating them.

Iatrogenic issues encountered during the initial root-canal treatment may be the cause of intra-canal bacterial infection. These issues may include perforation, incomplete cleansing and shaping, inadequate canal enlargement, missed canals, ledging, canal transportation, over-instrumentation, as well as obstruction of the canal by debris or separation of instruments. Failure to use or using too small a volume of an appropriate irrigant solution, such as sodium hypochlorite, is an iatrogenic error.

Full-strength 6% sodium hypochlorite been shown to be highly antimicrobial and able to dissolve tissue and disrupt bacterial biofilm.^{20,21} These qualities in an irrigant are ideal for the debridement of residual bacteria and tissue debris. The use of a rubber dam to isolate the treatment field is the standard of care for endodontic treatment. Failure to use a rubber dam may be a fundamental contributor to post-treatment disease. The following case illustrates the ability to overcome prior incomplete treatment to achieve successful healing (Figs. 3a–c).

_Clinical example

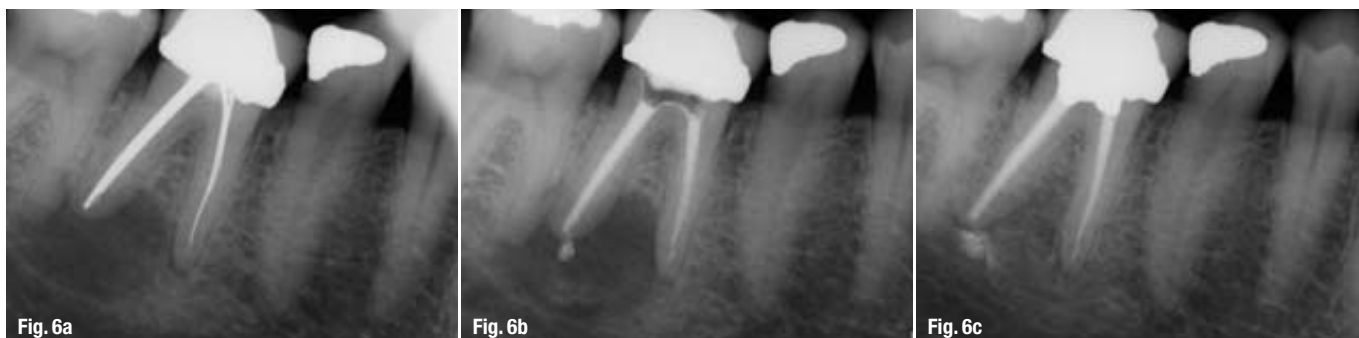Restorative failure is a common cause of post-treatment disease. Failure to place an effective permanent access restoration in a timely manner can allow for bacterial entry into the root-canal system by coronal leakage. Submarginal leakage on a crowned tooth can also allow bacterial entry to occur.

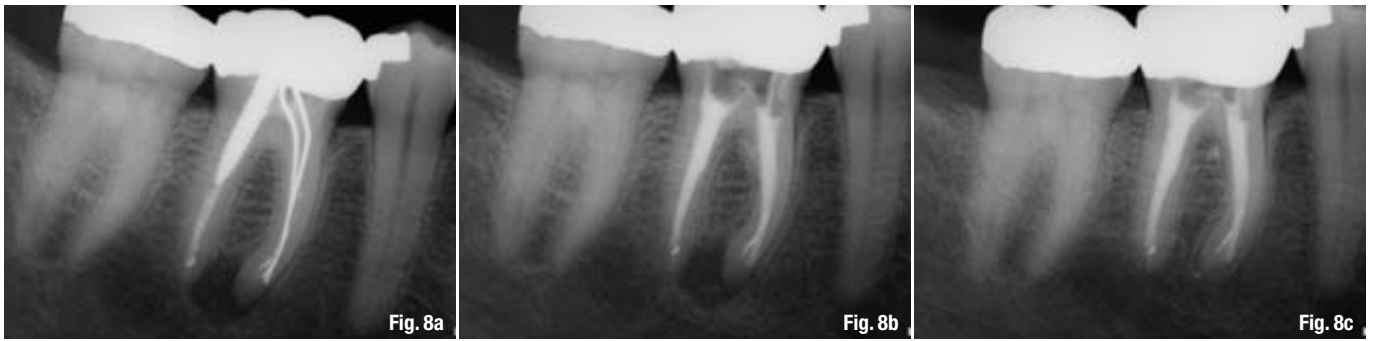
Decay in a previously treated tooth is another source of bacterial contamination. Structural damage to a tooth by trauma, cracking or fracture may provide an entry point for bacterial contamination of the canals. Our patients are responsible for their own oral health and must commit to effective oral hygiene techniques. Failure of the patient to perform effective oral hygiene can result in the failure of even the most well executed root-canal and restorative treatments.

With the bacterial challenges clinicians have to face, retreatment techniques must be capable of effective elimination of bacteria and their substrates. The use of a dental operating microscope and ultra-sonic instruments allows clinicians to uncover all existing canal anatomy properly to ensure that they are able to cleanse the root-canal system completely. The following clinical case (Figs. 4a & b) illustrates the extent of the canal space left untreated in the initial root-canal therapy by not opening the mesiobuccal canal adequately and not locating and cleansing the hidden second mesiobuccal canal.

Endodontic ultrasonic tips are highly efficient at removing core build-up material, paste fills, posts and

Fig. 6a_Pre-operative image.
Fig. 6b_Post-operative image.
Fig. 6c_13-month follow up image.





silver-point fillings, as demonstrated in Figure 5. These instruments allow clinicians to conserve root dentine by providing excellent visibility under a dental operating microscope, thereby greatly improving the ability to retreat canals (Figs. 6a–c). A heat source such as a System B tip (Axis, SybronEndo) is efficient for the removal of gutta-percha and resin materials from the coronal third. Hand and rotary files can remove root fillings and shape canals to appropriate working lengths. Current NiTi rotary files are highly flexible and resistant to separation and allow us to mechanically enlarge the apical third of root canals safely and efficiently without alteration of the natural canal morphology, which allows effective irrigation to reach the complex apical root-canal anatomy where bacteria are able to hide and resist debridement.

Once the canals have been located and instrumented, the ability to irrigate becomes essential to successful treatment. The irrigant solutions target the bacteria we are trying to eliminate. While sodium hypochlorite is a potent and proven antimicrobial and tissue dissolver,²² 2% chlorhexidine has been shown to prevent the adhesion of *E. faecalis* to dentine.²³ EDTA 17% is often used as an effective smear-layer removal agent.²⁴ Therefore, mechanical debridement and canal instrumentation provide a pathway for copious chemical irrigation deep into the canal.

Passive ultrasonic irrigation allows clinicians to place an irrigant solution into the pulp chamber and activate it as it is carried down to the apical end of the root canal. The IrriSafe tip (Acteon Group; Fig. 7) is a non-cutting ultrasonic file that is placed into each canal and is moved up and down in the canal for three cycles of 20 seconds. Passive ultrasonic irrigation has been shown to irrigate lateral canals better at 4.5 and 2 mm from the working length of canals as compared with needle irrigation alone.²⁵ It has been demonstrated that passive ultrasonic irrigation can remove dentine debris in a canal up to 3 mm in front of where the tip extends apically in straight or curved canals.²⁶ This evidence shows that an effective flow of irrigation can assist in the cleansing of teeth in which canal alteration occurred during the initial root-canal treatment.

The following silver-point case (Figs. 8a–c), with a large distal post and apical transportation in the mesial root, demonstrates the successful healing of post-treatment disease when proper disinfection has been accomplished. This case illustrates the reason that retreatment is the primary treatment option for post-treatment disease.

Once debridement and disinfection have been completed, appropriate obturation methods are used to seal the canal spaces. The warm vertical technique using gutta-percha or resin with an appropriate sealing agent provides a thorough seal of the well-cleansed and shaped canal spaces. The final restoration must provide a proper seal of the pulp chamber to prevent coronal micro-leakage.

Current evidence has demonstrated that we can retreat previously endodontically treated teeth properly and successfully. The literature has also shown that specific bacteria, such as *E. faecalis*, are able to survive inside a previously filled canal. The use of a dental operating microscope, ultrasonic instruments, irrigants, rotary NiTi files and appropriate obturation materials increases our ability to attain healing after retreatment. As we continue to strive to maintain healthy natural teeth for our patients, endodontic retreatment should be the primary option for patients with post-treatment disease.

Editorial note: A complete list of references is available from the publisher.

Fig. 8a Pre-operative image.
Fig. 8b Post-operative image.
Fig. 8c 15-month follow up image.
(Case by Dr. Brett Gilbert)

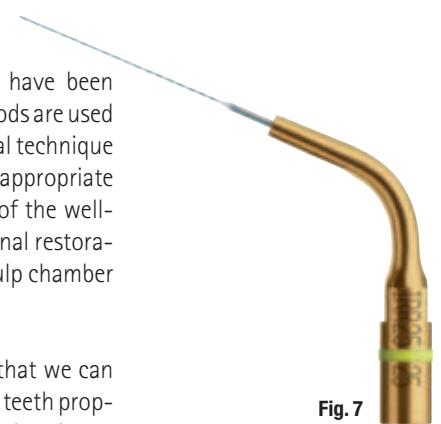


Fig. 7 IrriSafe tip by Satelec/Acteon.

_about the author

roots



Dr Brett Gilbert received his D.D.S. and Certificate of Endodontics from the University of Maryland. Dr. Gilbert has a private practice limited to Endodontics in Niles, Illinois. He is currently on faculty in the Department of Endodontics at the University of Illinois at Chicago, College of Dentistry and on staff at Resurrection Medical Center in Chicago. Dr. Gilbert is a Diplomate of the American Board of Endodontics and lectures nationally and internationally on clinical endodontics.