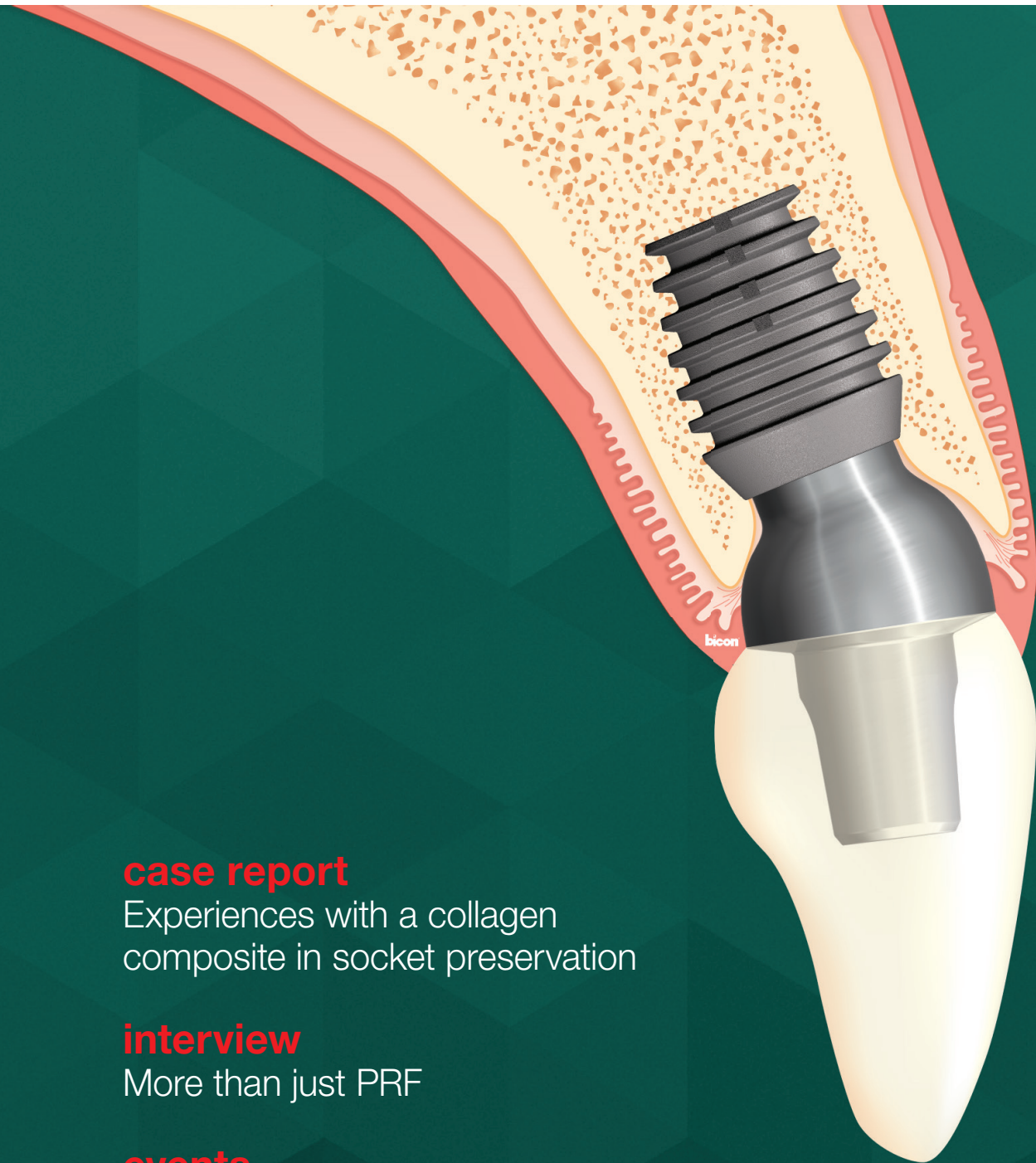


implants

international magazine of oral implantology



case report

Experiences with a collagen composite in socket preservation

interview

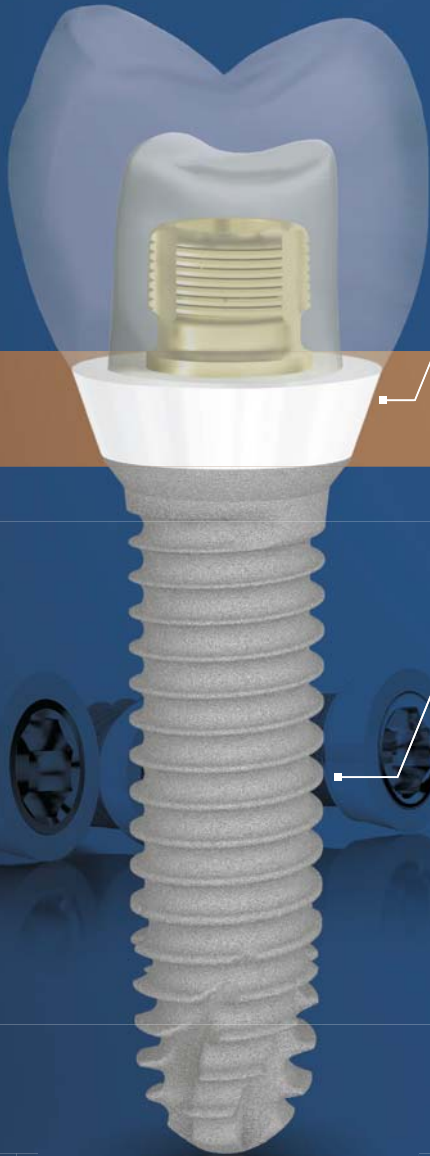More than just PRF

events

The future of implantology within grasp in Munich



The unique Tissue Level Implant with Zirconia Collar



Aesthetic gingival area

Zirconia collar

Gingival integration & Osseointegration

Bone area

Pure Titanium body

Z1[®] Implant Giving you confidence in implantology.

Proven Technology

- ✓ 98.6%* success rate
- ✓ Pure Titanium and Y-TZP Zirconia
- ✓ Suitable for all prosthetic solutions

Proven clinical outcomes for patient safety

- ✓ Anti-bacterial shield
- ✓ Ideal in fresh extraction sockets
- ✓ Immediate aesthetic result

Proven economics for a profitable implant practice

- ✓ Reduced chairtime
- ✓ Practice development
- ✓ Patient satisfaction

Proven surgical protocols for a simplified workflow

- ✓ Only 1 surgery
- ✓ No healing abutment
- ✓ Visibility of the connection



Find us online
www.tbr.dental



Unique, like your smile

*Z1 implants are medical devices of class IIb registered by SUDIMPLANT SAS. Information taken from the data of the Sudeinquiry@ program based on 15,534 patients with Z1 implants from 01/2011 to 01/2016.

Dr Georg Bach

President of the DGZI



Visions of the future

Dear friends and colleagues,

Behind us lies an extremely successful dental weekend of noteworthy accomplishments: the second Future Congress for Dental Implantology of the German Association of Dental Implantology (DGZI), which was held in early October in Munich, not only was informative and appealing to clinicians from Germany and abroad, but also proved that our visionary Future Congress concept is gaining ground. This concept, which we presented for the first time in Düsseldorf in 2018, represents a radical turnaround from the conventional parliamentary congress format through the introduction of fresh, interactive elements. In this context, the table clinics and the digital poster presentation are particularly worth a mention.

The fact that our new format is growing in acceptance is reflected in the significantly increased number of participants compared with previous years, but even more so in the fact that about half of the participants in Munich were under the age of 40—which we are very pleased about! We take this not only as a complement but also as a clear responsibility towards the younger generations that represent our future. The future concept runs like a thread through all our work at DGZI, including further training and curricula, and collaboration with dental technicians, always with an overriding focus on the practice of implant dentistry. I can confidently say

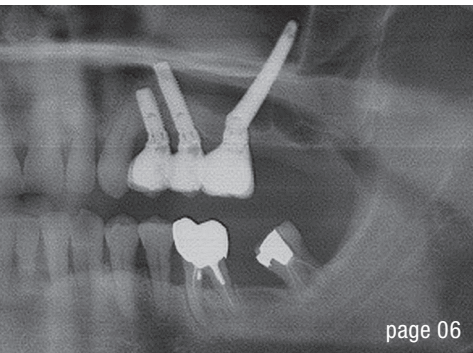
that, at the beginning of October, we succeeded in presenting oral implantology not as it is today, but as it will be in five to ten years from now.

I am personally very happy and utterly grateful that I was elected new DGZI President at this year's general meeting, which was held in Munich one day ahead of the congress. Embracing the responsibility that my new role as President entails, I will accompany and support our DGZI and lead it into its anniversary year in 2020, when we will celebrate half a century of DGZI. This will truly be a worthy event and we will celebrate it duly. It will not only be the anniversary of the oldest expert society for oral implantology in Europe but also an anniversary of German implantology itself, since the courageous and visionary founders of DGZI have contributed a great deal to establishing this dental discipline and to eventually developing its wider application. We are looking forward to our anniversary year!

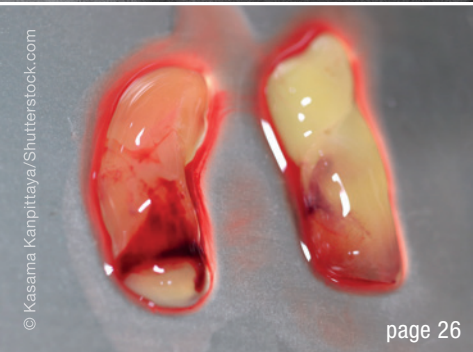Yours,

A stylized, handwritten signature in black ink, consisting of a large, sweeping 'G' followed by a few loops and a short horizontal stroke.

Dr Georg Bach



page 06

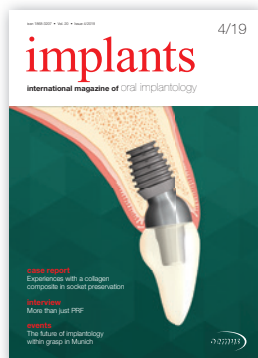

page 26



page 36

Cover image courtesy of Bicon
www.bicon.com



editorial

Visions of the future 03
Dr Georg Bach

case report

Rehabilitation of **maxillary** unilateral posterior **edentulism** 06
Drs Jean-Baptiste Verdino, Sepehr Zarrine,
Thierry Louvet & David Mardenalom

Two-stage implant therapy for single-tooth **restoration** 12
Simon Lehner

Experiences with a collagen composite in **socket preservation** 14
Prof. Frank Palm, Dr Jan Rupp & Prof. Werner Götz

industry

What's your favourite **colour**? 20

interview

Going digital with the Heron IOS 22

More than just **PRF** 26

events

The **future of implantology** within grasp in Munich 36

Dentsply Sirona World 2019 in **Las Vegas** 42

The 2020 Oral Reconstruction Global Symposium in **New York City** 44

news

manufacturer news 30

news 46

about the publisher

imprint 50

MAKE NO BONES ABOUT IT.

CONFIDENCE IN ALL BONE QUALITIES:
PROGRESSIVE-LINE



SPECIALIST IN SOFT BONE:

- Apical conical area for high primary stability in soft bone
- Thread up to the apex, ideal for immediate implantation
- Thread design with deeply engaging thread flanks
- Flexible drill protocol for preferred stability

WWW.CAMLOG.COM

a perfect fit™

camlog

Rehabilitation of maxillary unilateral posterior edentulism

Drs Jean-Baptiste Verdino, Sepehr Zarrine, Thierry Louvet & David Mardenalom, France

There are two options for treating partially edentulous maxillae: a removable partial denture or an implant-supported fixed partial denture. The resorption of the upper jaw, in association with maxillary sinus pneumatization, often requires pre-implant surgery, such as inlay/onlay grafting or crestal/lateral sinus lift to allow the insertion of regular implants. A graftless approach including tilted implants,¹ such as zygomatic implants, has been proposed to avoid long-lasting treatment sequences.

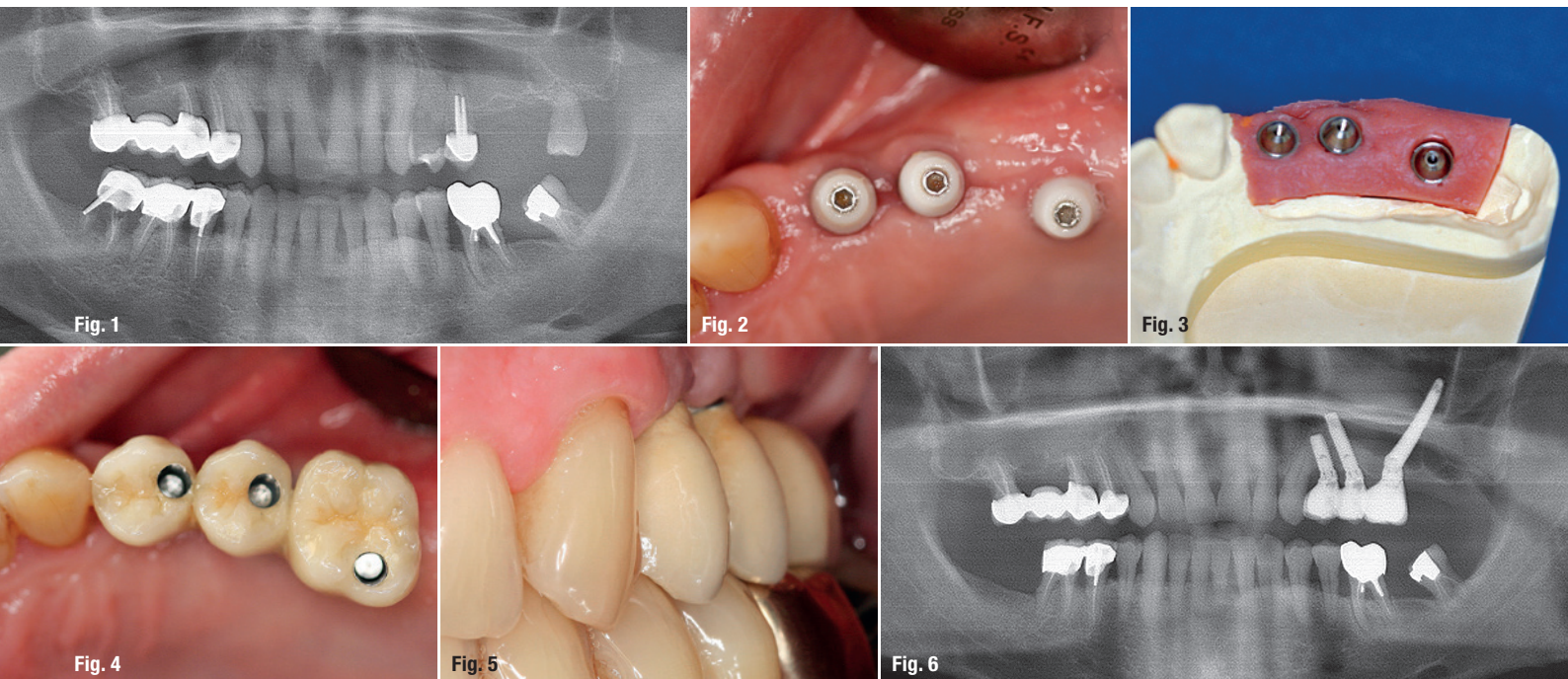
Zygomatic implants

Introduced by P.-I. Brånemark in the 1980s, the zygomatic anchorage was developed to treat patients after a complete or partial maxillectomy.²⁻⁴ The development of this technique allowed the rehabilitation of completely edentulous atrophied maxillae. The process was then

described as an alternative to a sinus lift.⁵ This procedure requires the insertion of a 30.0–52.5 mm long titanium implant (NobelZygoma, Nobel Biocare) from the maxillary edentulous ridge to the zygomatic bone, with an intra- or extra-sinus path (ZAGA classification⁶). The diameter of the apical part is 3.9 mm, while the maxillary part is 4.1 mm. The platform is a 4.2 mm external hexagon with a 45° angle to allow for the prosthetic restoration.

Completely and partially edentulous maxillae

The original protocol for treating completely edentulous maxillae was carried out using two zygomatic implants and two or four regular implants inserted in the anterior maxilla.⁷ In the case of terminal atrophied maxillae, a quadruple zygomatic implant placement can currently be



Case 1—Fig. 1: Pre-op radiograph: the two premolars and the third molar of the left maxilla would have to be extracted, and there was insufficient bone quantity under the sinus to allow for implant placement. **Fig. 2:** The impression was taken after a healing period of four months. **Fig. 3:** Master model, in which the emergence of the zygomatic implant is in the region of the palatal root of the first molar. **Fig. 4:** A porcelain-fused-to-metal fixed partial denture (ceramic on titanium) was screwed on. **Fig. 5:** Buccal view of the fixed partial denture. **Fig. 6:** Control radiograph: the treatment of the case was completed in five months.

achieved: a traditional molar zygomatic implant and an additional canine zygomatic implant are inserted on each side of the maxilla.^{8,9} The treatment of unilateral posterior edentulism must be considered as a high priority considering the loss of masticatory efficiency. There is rapid resorption of bone of the alveolar ridge immediately after tooth extraction. The insertion of a zygomatic implant in this situation is not available considering the biomechanical aspect. The zygomatic implant has to be used with other implants to allow the stabilisation of the restoration. This solution can then be considered only in the case of extractions of the molars in association with avulsion of the premolars.

Case reports

All the patients were healthy non-smokers with satisfying oral hygiene and no general diseases. They desired improvement in comfort, aesthetics and quality of life with a fixed solution. The remaining teeth were not sufficient to support a fixed partial denture. For the treatment of the unilateral posterior edentulous area of their maxillae, two approaches were presented to each patient. On the one hand, a reconstructive option would entail the extraction of the hopeless teeth, the insertion of immediate implants if possible and the achievement of a lateral sinus lift during the same surgery. After six months of healing with a removable partial denture, the remaining implants could be inserted to complete the implant treatment. On the other hand, a graftless solution was proposed, which would involve placing two regular implants in the premolar region and a zygomatic implant in the molar area or a regular implant associated with one zygomatic implant and one pterygoid implant. These three implants connected to healing abutments could be loaded after a four-month period of healing or loaded immediately with a provisional screw-retained fixed partial denture. All the risks of the two options were explained to the patients before they made the final decision. In these three reported cases, the graftless approach was selected because of the shorter duration of the treatment and fewer number of surgeries required. The cost of each treatment was similar for the two options.

Case 1

A 56-year-old male patient presented for the rehabilitation of his partially edentulous left maxilla, complaining of low masticatory efficiency. Teeth #26 and 27 had been extracted and had not been restored, while teeth #28 and 24 were mobile. Tooth #25 was endodontically infected. These three teeth were under a high level of occlusal load. They presented a low level of surrounding bone and were diagnosed as hopeless teeth. We noted a generalised but stable periodontitis (Fig. 1). Two cylindrical self-tapping implants (Brånemark System Mk IV TiUnite regular platform [RP], Nobel Biocare) of 10 and

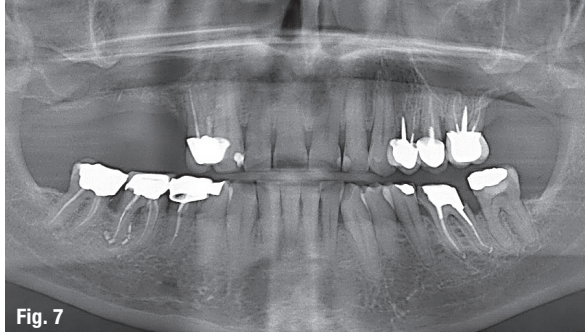


Fig. 7

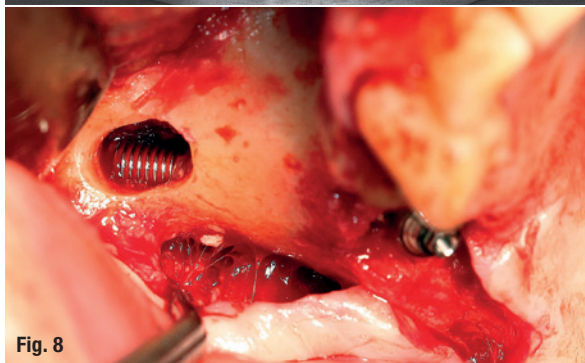


Fig. 8

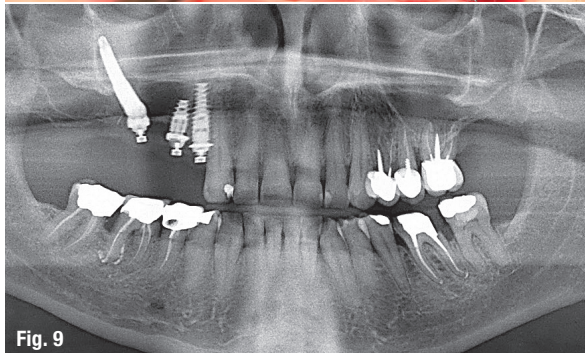


Fig. 9

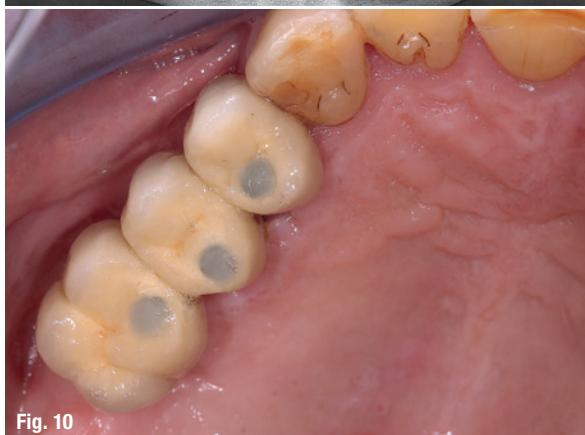

Fig. 10

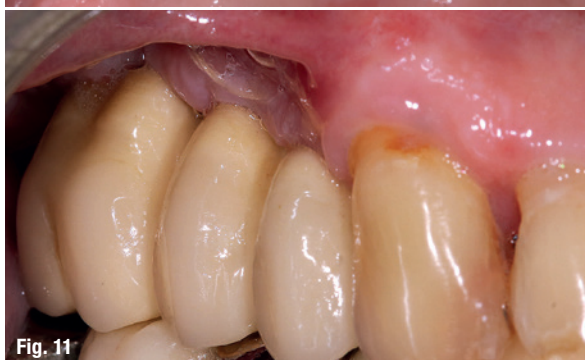

Fig. 11

Case 2—Fig. 7: Pre-op radiograph: the first premolar would have to be removed and there was insufficient bone under the sinus. **Fig. 8:** A zygomatic implant was placed across the sinus. **Fig. 9:** Two regular implants were inserted in positions #14 and 15 (implant #14 was immediately placed after extraction), and a machined 45 mm Brånemark zygomatic implant was placed into position #14. **Fig. 10:** Full-zirconia fixed partial denture. **Fig. 11:** Buccal view.

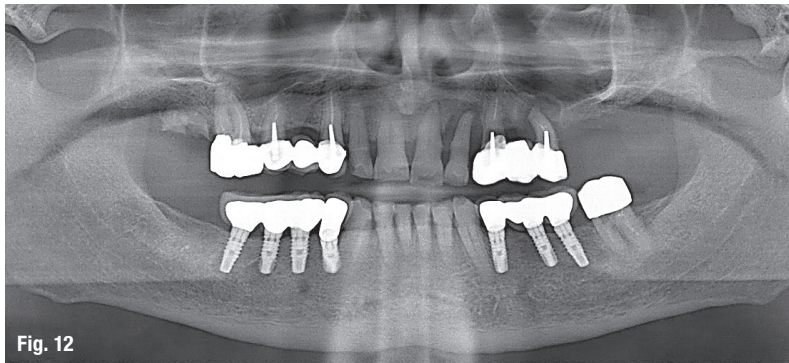


Fig. 12

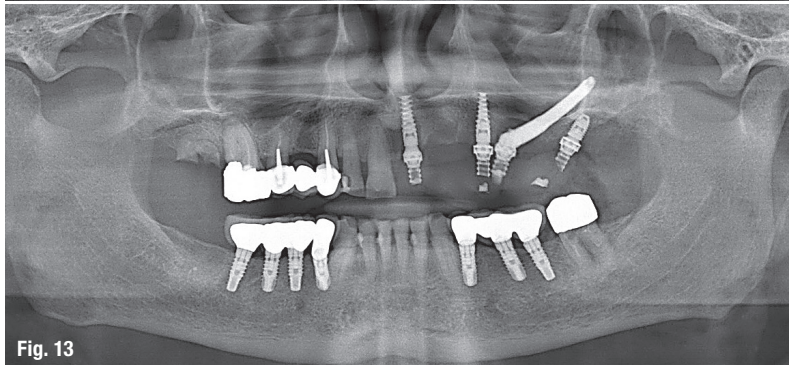


Fig. 13

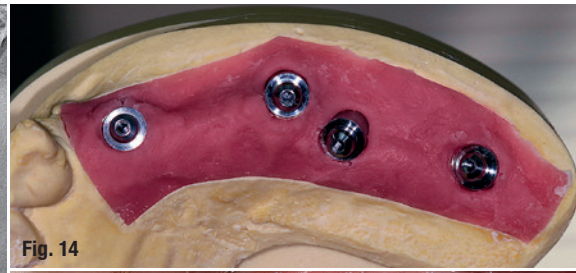


Fig. 14

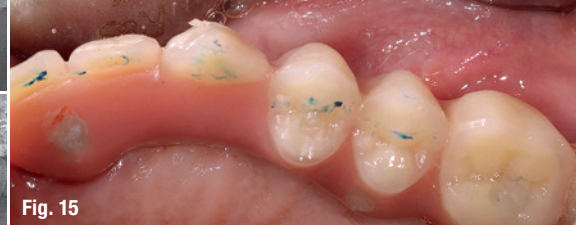

Fig. 15

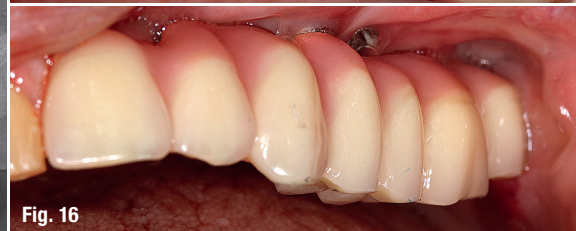

Fig. 16

Case 3—Fig. 12: Pre-op radiograph: all the teeth of the left maxilla would have to be removed owing to periodontal disease. **Fig. 13:** Three implants were placed into the remaining bone, completed by a 42.5 mm zygomatic implant. **Fig. 14:** Master model, in which the emergence of the zygomatic implant is slightly palatal. **Fig. 15:** Titanium screw-retained fixed partial denture with pink acrylic and composite teeth. **Fig. 16:** Buccal view.

15 mm in length and 4 mm in diameter were inserted as replacements for teeth #24 and 25, respectively, while a 35 mm long zygomatic implant was inserted in position #26. A provisional non-functional screw-retained fixed partial denture was immediately connected to the three implants, considering their sufficient insertion torque. A 3 mm 17°, a 2 mm 17° and a 3 mm straight RP multi-unit abutment (MUA, Nobel Biocare) were used for the screw-retained fixed partial denture. The final fixed partial denture was connected after four months of healing (Figs. 2–6).

Case 2

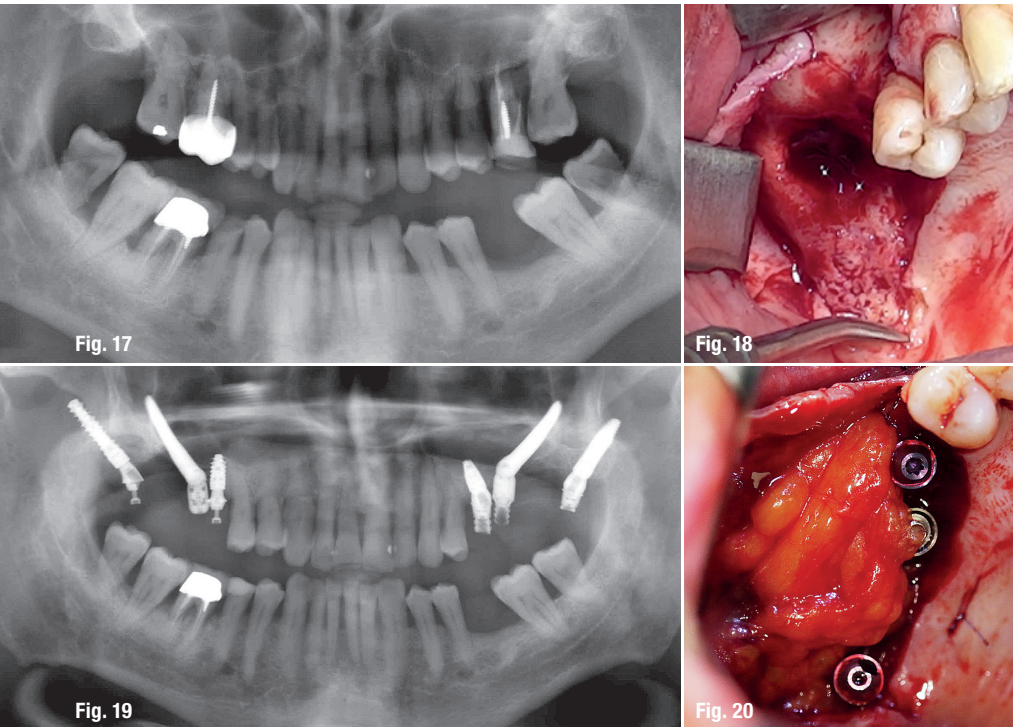
A 40-year-old male patient presented for rehabilitation of his right maxilla. Tooth #14 was infected by an abscess due to root fracture (Fig. 7). At the time of the extraction of tooth #14, teeth #14 and 15 were replaced by a 10 mm long and an 8 mm long NobelActive RP straight implant (Nobel Biocare), respectively, while a 40 mm long zygomatic implant was inserted in position #16 (Figs. 8 & 9). These three implants were connected to a screw-retained fixed partial denture by the use of a 1.5 mm MUA and a 2.5 mm 17° MUA for implants #14 and 15 and a 1 mm straight MUA for the zygomatic implant after four months of healing (Figs. 10 & 11). Note that the use of a machined zygomatic implant allows the use of a larger range of MUAs, which is not possible with TiUnite zygomatic implants (only 3 and 5 mm MUAs are available).

Case 3

A 70-year-old male patient presented for the treatment of his left maxilla. He presented with a fixed partial denture extending from tooth #23 to tooth #25. Tooth #24 presented a vertical fracture, due to occlusal overload. Teeth #21 and 22 presented a high degree of mobility (Fig. 12). Three NobelActive narrow-platform implants were inserted into the remaining bone: tooth #21 was extracted and immediately replaced with an implant, while two other implants were placed, one in position #23 and one in the tuberosity. Three MUAs (Nobel Biocare) with a diameter of 1.5 mm were immediately screwed on. A 42.5 mm long zygomatic implant was placed between tooth #25 and tooth #26, and received a 1 mm MUA (Fig. 13). Immediate loading was performed with a screw-retained full-acrylic fixed partial denture. After a healing period of four months, a seven-unit fixed partial denture of acrylic on a titanium frame (NobelProcera, Nobel Biocare) was inserted (Figs. 14–16).

Case 4

A 65-year-old patient with periodontal disease had an infection of the posterior maxillary area and tooth mobility involving a lack of alveolar bone in the molar area (Fig. 17). The radiographic examinations, panoramic radiograph and 3D imaging, showed sinus infection



Case 4—Fig. 17: Initial situation with periodontal disease, infection of the posterior maxillary area and lack of alveolar bone. **Fig. 18:** Right sinus with an oroantral communication. **Fig. 19:** Immediate loading on both sides with regular, zygomatic and pterygoid implants. **Fig. 20:** The machined zygomatic implant partially closed the oroantral communication and the rest was closed by the pedicled buccal fat pad.

linked with the teeth. Firstly, teeth #16, 17, 25, 26 and 27 were extracted. The left sinus quickly became healthy, while the right sinus developed a new phase of purulent sinusitis. The left side was implanted with a Straumann BLT implant of 8.0mm in length and 4.1mm in diameter in position #25, with a straight screw-retained abutment. In position #28, a Straumann BLT implant of 16mm in length and 4.1mm in diameter was anchored in the pterygoid notch, and a 25° angulation screw-retained abutment was screwed on. A 40mm long zygomatic implant (Nobel Biocare) was inserted in position #26. In the same surgery, the right sinus was drained by an existing unhealed oroantral communication. On the same day, a provisional non-functional fixed partial denture was screwed on to the three implants. The right side was implanted after six weeks in order to work with a healthy maxillary sinus, but there was still an oroantral communication (Fig. 18).

After locating the pterygoid hamulus, which helps to avoid the descending

palatine artery, a pterygoid implant was inserted in position #18. A Straumann BLX implant of 3.75mm in diameter and 18.00mm in length was placed and a 25° angulation screw-retained abutment was used to achieve the axis correction of this implant. In position #16, with low bone height, another BLX implant (3.75mm in diameter and 8.00mm in length), with an extensive self-drilling capacity, provided high primary stability and a straight screw-retained abutment was screwed on at 35Ncm. A 40mm long Neodent zygomatic implant was strongly anchored in the zygomatic bone (Fig. 19). The machined surface of this implant allowed partial closure of the oroantral communication, the rest of which was covered by the pedicled buccal fat pad (Fig. 20). The implants were loaded immediately with a provisional screw-retained fixed partial denture. After five weeks, the two sinuses were perfectly healthy (Fig. 21). The final screw-retained fixed partial dentures were connected on both sides after four months of osseointegration (Figs. 22–24).



Shortest Implants – Longest History.

Think Short!

For more than 30 years Bicon® short implants are unchanged in clinical use.

According to the 11th European Consensus Conference (EuCC) 2016 in Cologne, provided the specific treatment parameters are observed, the use of short, angulated or diameter-reduced implants in sites with reduced bone volume can be a reliable treatment option, given the risks associated with the use of standard-dimension implants in combination with augmentation procedures.

For more Information:

Bicon Europe Ltd.

Dietrichshoehe 2

55491 Buechenbeuren

Germany

Phone +49 (0)6543 818200

germany@bicon.com

www.bicon.de



bicon
DENTAL IMPLANTS