

implants



the journal of oral implantology

1 2013

| **user report**

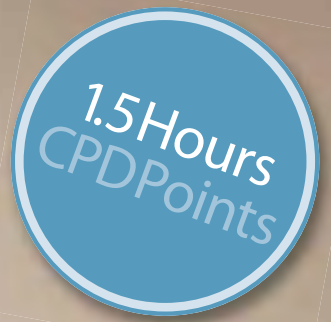Camlog case studies

| **case report**

Tapered implants and overdentures

| **research**

Single molar restoration



DENTAL WEBINARS

Learn from the comfort of your own home



Over the last four years we have built a solid reputation as the original and best dental webinar provider. The webinars are live and interactive to give a unique

learning experience. Interact with some of the industry's leading experts as they present the very latest in clinical practice.

UPCOMING WEBINARS:

- | | |
|----------|---|
| 15/05/13 | Photography is the most powerful part of practice |
| 16/05/13 | An Introduction to the uses of CEREC Technology for the GDP |
| 11/06/13 | Six Month Smiles: Leading the way in short term Ortho for GDP's |
| 12/06/13 | In Surgery Home Care for Implants |

Sign up for free

Join the Dental Webinar club – sign up for free:
www.dentalwebinars.co.uk



Dear Reader,

_Hello and welcome to the latest issue of *Implants*! I hope you find it both interesting and informative.

This week I've been catching up on the recently published Cochrane review on the impact of loading times on the success rates of implants (Esposito M, Grusovin MG, Maghaireh H, Worthington HV. Interventions for replacing missing teeth: different times for loading dental implants. Cochrane Database of Systematic Reviews 2013, Issue 3. Art. No.: CD003878. DOI: 10.1002/14651858.CD003878.pub5). The researchers looked at a number of Random Controlled Trials that looked at loading implants immediately, after six weeks (early) and at three months (conventionally).

According to the authors, *Overall there was no convincing evidence of a clinically important difference in prosthesis failure, implant failure, or bone loss associated with different loading times of implants.* This I find most interesting, as there are many who would lean very heavily on the evidence that you should always wait three months before loading and would be very reticent to change that view; or am I being unfair?

If you would like to read the full review, go to <http://onlinelibrary.wiley.com/doi/10.1002/14651858.CD003878.pub5/full> and let me know your thoughts.

Until next time

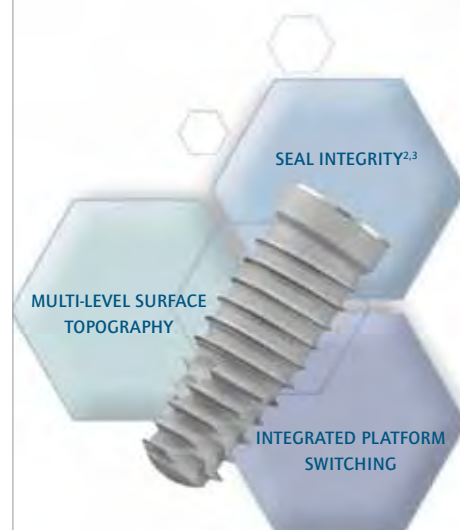Lisa Townshend

Group Editor, *Implants*

lisa@healthcare-learning.com

Introducing the **3i T3 IMPLANT™**

The 3i T3™ Implant* is designed to deliver aesthetic results through tissue preservation.



PRESERVATION BY DESIGN™



Contemporary hybrid surface design with multi-level topography; media-blasted on the threaded region and dual-acid etched on the collar region



Optimized aesthetics with as little as 0.37mm of bone recession¹



Higher seal strength as compared to the competitive average^{2,3}

Seal integrity test was performed by BIOMET 3i on December 2011. Testing was done under testing standard ISO 14801. Five (5) BIOMET 3i PREVAIL™ Implant Systems and five (5) of three (3) competitors' Implant systems were tested. Bench test results are not necessarily indicative of clinical performance.

**Please contact your local BIOMET 3i
Sales Representative or visit us online at
www.biomet3i.com to learn more.**

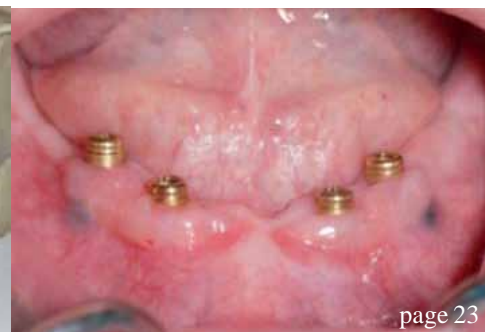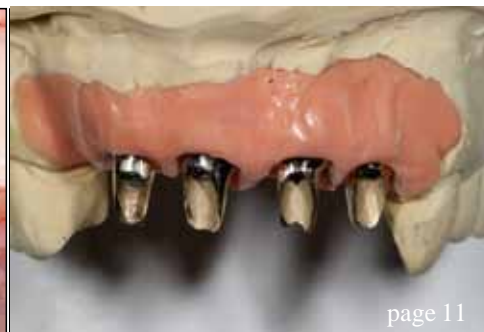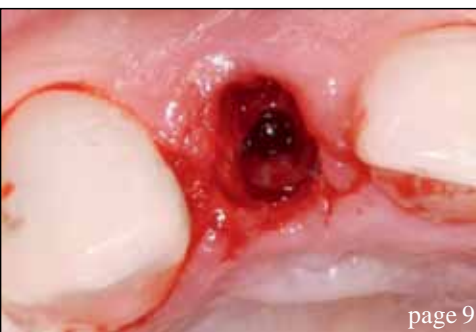*The 3i T3 Implant is not yet available for sale in the U.S.

1. Odman PO, Wennerberg A, Albrektsson T. Immediate Occlusal Loading Of Nanotite Preval Implants: A Prospective 1-Year Clinical And Radiographic Study. Clin Implant Dent Rel Res. 2010 Mar;12(1):39-47.
2. Lazzara RV. Dental Implant System Design and the Potential Impact on Long-Term Aesthetics: A Review of the 3i T3™ Tapered Implant. ART1193EU 3i T3 White Paper. BIOMET 3i, Palm Beach Gardens, Florida, USA.
3. Suttin Z, Tosses R, Cruz J. A Novel Method for Assessing Implant-Abutment Connection Seal Robustness. BIOMET 3i, Palm Beach Gardens, Florida, USA. Poster Presentation, Academy of Osseointegration, 27th Annual Meeting, March 2012; Phoenix, AZ. http://biomet3i.com/Pdf/Posters/Poster_Seal%20Study_ZS_AO2012_no%20logo.pdf. Testing done by BIOMET 3i, Palm Beach Gardens, FL; n = 20.

[†]Aforementioned have financial relationships with BIOMET 3i LLC resulting from speaking engagements, consulting engagements and other retained services.

PREVAIL is a registered trademark of BIOMET 3i LLC. 3i T3, 3i T3 Implant design, Preservation By Design and Providing Solutions - One Patient At A Time are trademarks of BIOMET 3i LLC. ©2012 BIOMET 3i LLC.

BIOMET 3i
PROVIDING SOLUTIONS - ONE PATIENT AT A TIME™



| editorial

- 03 **Dear Reader**
_Lisa Townshend

| news

- 06 **News**

| events

- 07 Speaker announced **for CIC 2013**

| case report

- 08 **Immediate loading with a Straumann Bone Level Implant** after a horizontal tooth fracture in the aesthetic zone
_Albert Barroso

| user report

- 11 **Implantology** – The Camlog way
_Sunny Kaushal

| case report

- 22 **Immediate functional loading of** the edentulous mandible
_Suheil M Boutros

| research

- 26 **Single molar restoration – wide implant versus two conventional**
_Amr Azim, Amani Zaki, Mohamed El-Anwar

- 32 Impression and registration for **full-arch implant dentures**
_Gregory-George Zafiropoulos

| industry report

- 38 **Fixed full arch metal-free prosthesis on four SHORT implants**
_Mauro Marincola, Vincent Morgan, Angelo Pertuini, Stefano Lapucci

| product spotlight

- 43 Broaden your **BioHorizons**
_Maurice Salama

| manufacturer news

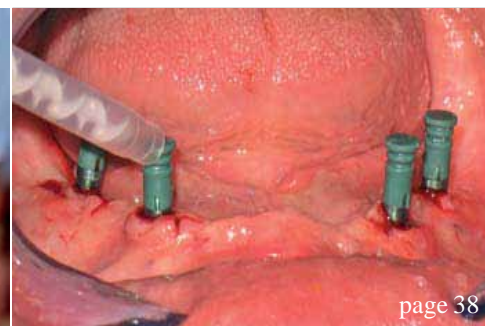
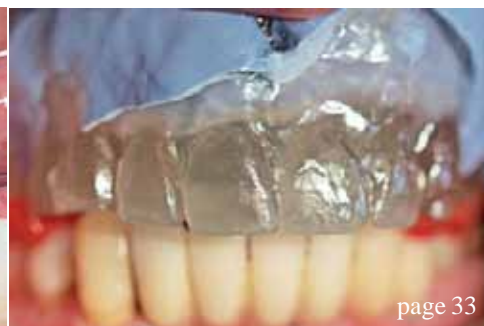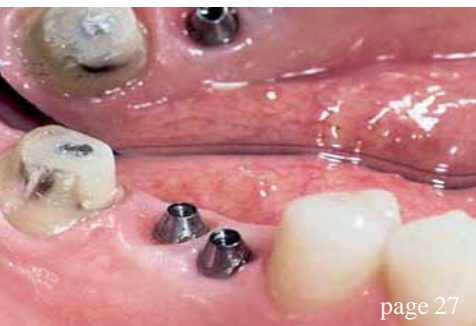- 44 Manufacturers news

| diary dates

- 48 2013/International/UK

| about the publisher

- 49 _Guidelines for submission
50 _Imprint



Brilliant imaging quality from Sirona.



With the ORTHOPHOS XG family you can achieve

- Highest level of image quality for panoramic, cephalometric & 3D images
- Crystal clear 2D images due to caesium iodide scintillator material
- Reduction of metal artifacts with innovative MARS software
- HD 3D-sensor and smaller field of view for endodontics
- Low noise and high contrast for a reliable diagnosis
- Easy patient positioning
- Guided surgery

Enjoy every day. With Sirona

Sirona Dental Systems, Lakeside House, 1 Furzeground Way, Stockley Park, Heathrow, London UB11 1BD

sirona.com    YouTube

0845 0715040

info@sironadental.co.uk

The Dental Company

sirona.

Dental nurses to benefit from ADI training

The Association of Dental Implantology Dental Nurses' Courses have been developed in response to the increased role played by dental nurses in supporting implant clinicians.

Attendees begin with the Original Dental Nurses' Course, which aims to increase the understanding of dental implantology to dental nurses. This course provides dental nurses knowledge and confidence to support the operator with surgical implant placement and subsequent restorative appointments.

Delegates who move onto the Advanced Dental Nurses' Course have the chance to learn complex surgical nursing techniques involved in implant placement including, sinus lifts, bone grafting, socket preservation and soft tissue augmentation. The course has been designed to en-

courage confidence in their ability to assist throughout implant procedures, allowing the clinician to focus on the task in hand.

Dr Simon Wright, Director of Education at the ADI says, "We feel it is crucial that dental nurses are highly trained to ensure that implant patients receive expert treatment. Clinicians are giving them more responsibility in many dental practices and the ADI Dental Nurses' Courses are the ideal way to help them develop their skills."

Both courses are priced at a competitive £150. The Original course takes place on Saturday 28 September 2013. The Advanced course takes place on and Saturday 23 November 2013. Visit www.adi.org.uk/nurses_courses or call the Association on 020 8487 5555.

Established ridge-split procedure offers new application in dental implant surgery

Dental techniques to modify the alveolar ridge have been around for many years, often as a means of support for dentures. As dental implants have now become common procedures, so has pre-implant preparation of the bone. The ridge-split procedure is one such method of widening and augmenting the alveolar ridge that is finding renewed interest.

The *Journal of Oral Implantology* presents a detailed description of the alveolar ridge-split procedure, supplemented by photographs. The alveolar ridge is the bony ridge on both the upper and lower jaws that contains the sockets of the teeth. Establishing an alveolar ridge of proper dimensions has become essential with the advent of root-form endosseous dental implants, the most common type of implants.

The ridge-split procedure described in this article is a form of ridge widening or augmentation. In cases of narrow alveolar ridges, it has proven to be consistently successful. Use of this minimally invasive technique has many advantages in the pre-prosthetic stage of dental implants. Low risk of inferior alveolar nerve injury, less pain and swelling, and no need for a second surgical site as donor are among

the benefits.

Because of differences in bone density, the ridge-split technique requires a single surgical stage in the maxilla, or upper jaw, and a two-stage approach in the mandible. The two stages of mandible surgery consist of corticotomy, a bone-cutting procedure, followed by splitting and grafting performed three-five weeks later. The staged approach of the ridge-split procedure has shown a higher implant success rate and better buccal cortical bone preservation.

A practitioner's experience is an important component of this technique. This form of surgery modifies the configuration of the bone and is usually performed in a closed fashion and uses a tactile sense. The authors emphasise the need for careful manipulation of the thin ridge, knowledge of precise surgical principles, and specialised training.

Full text of the article, "*Horizontal Augmentation Through the Ridge-Split Procedure: A Predictable Surgical Modality in Implant Reconstruction*," *Journal of Oral Implantology*, Vol. 39, No.1, 2013, is available at www.joionline.org/doi/full/10.1563/AID-JOI-D-12-00112.

Speaker Announced for Clinical Innovations Conference 2013

17th and 18th May 2013, Millennium Gloucester Hotel, London



_On 17th and 18th May 2013, Healthcare Learning; Smile-on will be presenting the 10th Clinical Innovations Conference, in conjunction

with The Dental Directory and the AOG. The widely anticipated event will be held in the Millennium Gloucester Hotel in Kensington, London, attracting hundreds of dental professionals in their quest to remain abreast of the very latest developments in the industry.

A selection of world-class speakers has been confirmed to attend this year's event, taking delegates to the very cutting-edge of the profession.

One of these is Dr Shakeel Shahdad (*pictured*). Dr Shahdad is a registered specialist in Restorative Dentistry, Periodontics, Prosthodontics and Endodontics, as well as a consultant and Honorary Clinical Senior Lecturer in Restorative Dentistry at The Royal London Dental Hospital and Queen Mary University, Barts and The London School of Medicine and Dentistry. In addition, Dr Shahdad is a Fellow of the International Team for Implantology (ITI) and a Diplomat of the British Society of Oral Implantology, all the while running a multi-specialist referral practice in the West End of London.

Dr Shahdad will be speaking on behalf of Straumann at the event, discussing "Beauty or the Beast? Tissue-level implants in aesthetic zone".

"Osseo-integration of implants has become a well established technique, and the focus is now on achieving ideal aesthetics," explains Dr Shahdad. "Long-term maintenance of soft tissue aesthetics around implants is a challenge, and we are only now coming to understand it better. Factors that influence peri-implant bone remodelling and timing of implant placement have a profound affect on labial bone maintenance.

"My presentation at CIC 2013 will be based on current research findings, and will aim to demonstrate and highlight the important surgical and restorative dimensions for predictably achieving and maintaining aesthetically optimised implant restorations. Emphasis will be placed on integration of biological principles into planning and decision-making in aesthetic implant dentistry. I will also present the arguments for Tissue or Bone level, Immediate or Delayed placement." _

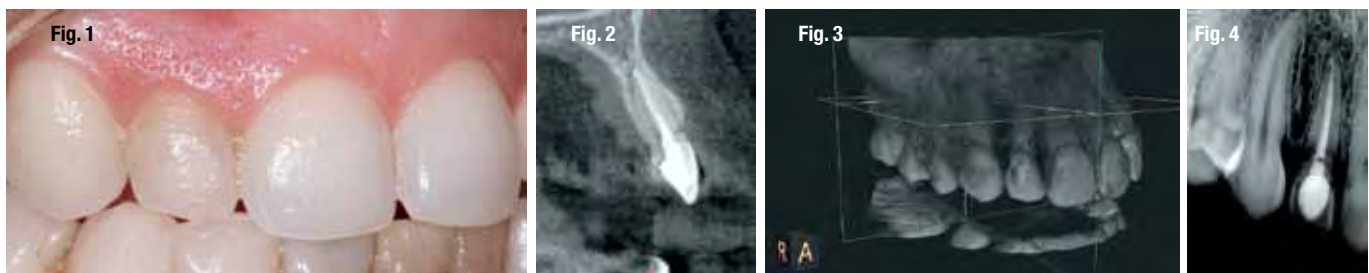
_contact

implants

For more information about Clinical Innovations Conference 2013 and to book your place call 020 7400 8989, email info@healthcare-learning.com or go to www.clinicalinnovations.co.uk

Immediate loading with a Straumann® Bone Level Implant after a horizontal tooth fracture in the aesthetic zone

Author_Albert Barroso



_Patient history

A 38 year-old non-smoking woman, in good general health and with high aesthetic demands, presented at our dental office with mobility of tooth #12 (Fig 1). After clinical and radiological examination a horizontal fracture near CEJ (cement enamel junction) was detected (Figs 1-4). Clinical examination showed class III mobility of the crown of #12. Aesthetic parameters were not altered. The buccal bone plate was not affected (Fig 2). The patient's plaque control was adequate and no periodontal disease or periapical infection was detected (Fig 4).

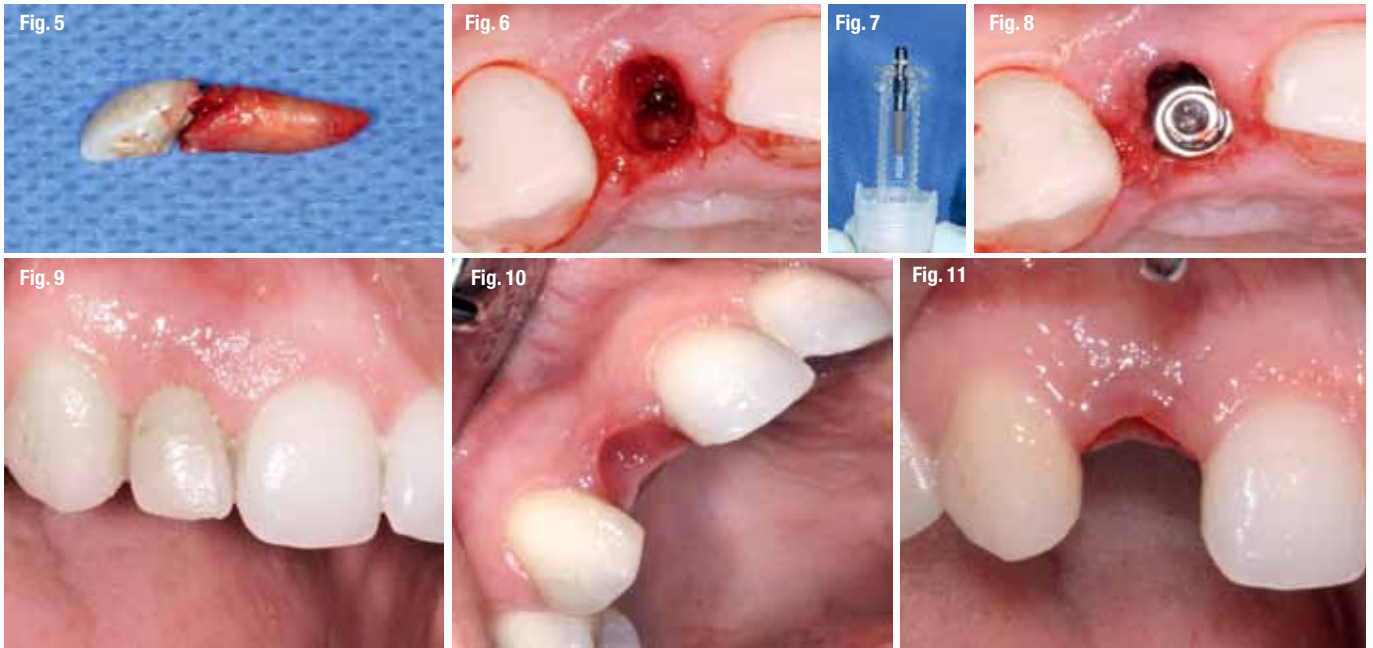
_Treatment planning

It was not possible to prepare the tooth for restoration with a single crown due to the absence of ferrule. The short length of the root would lead to an unsatisfactory crown-root ratio in case of orthodontic extrusion, and crown lengthening was not indicated in this case because of aesthetic concerns. For

these reasons tooth #12 was considered hopeless. According to the options proposed by the ITI group in terms of implant placement timing after tooth extraction, the present situation would correspond to the "Type I" classification. Though the lip line is high, a medium-thick biotype, the lack of infection and a width of 1mm or more of the buccal bone wall (as revealed by computerised tomography) permits placing the implant immediately after tooth extraction.

_Surgical procedure

A very accurate root extraction was performed to keep the buccal plate intact (Fig 5). After verifying the integrity of the socket walls, the implant bed was prepared without flap elevation (Fig 6). We know that this approach - leaving the periosteum attached to the bone - minimises the remodelling of the alveolar ridge. A Straumann® Bone Level Implant with SLActive® surface (Fig 7) was palatally positioned. The filling of the vestibular gap was



done with Straumann® BoneCeramic which helps to preserve the horizontal dimension of the ridge and, to some degree, the vertical dimension (Fig 8).

Immediate temporary restoration

An immediate provisionalisation was done by an adhesive-fixed provisional with the crown of the recently extracted tooth #12 used as a Maryland bridge. Seven days after the extraction and immediate implant placement the tissues around the zone look completely healthy (Fig 9). This not only permitted providing the patient with an immediate aesthetic fixed provisional but also to maintain the adequate gingival architecture during the osseointegration period.

Final restoration

After a healing period of six to seven weeks an adequate gingival architec-

ture was already achieved by the adhesive immediate provisionalisation (Figs 10&11). At this time a Straumann® NC Cementable Abutment with a minimally invasive approach is connected and screwed in at 20Ncm torque (Figs 12&13). By applying this protocol the abutment will not be disconnected, allowing the soft tissue to accommodate to the ideal apico-coronal position and minimising its possible future recession.

With a periapical radiograph we checked the adequate fit of the abutment to the implant connection and confirmed maintaining of the mesial and distal bone around the implant (Fig 14). The preparation of the definitive abutment was done intraorally (Fig.15) and after this the definitive impression was taken. A new provisional was cemented to the definitive abutment to maintain adequate soft tissue aesthetics (Figs 16&17). A metal-ceramic crown was prepared by the laboratory

