

implants

international magazine of oral implantology

2²⁰¹⁰

| **case report**

Immediate implant placement and temporisation
in the aesthetic zone

| **user report**

Use of an X-ray phantom in dental
3-D diagnostics in digital volume tomographs

| **meetings**

6th Arab-German Implantology Meeting of DGZI

0277113

PEOPLE HAVE PRIORITY



Intelligent design
shows in the details.

120 Years W&H.
Help us support SOS Children's Villages!



A program menu that covers all stages of implantation and is easy to use.
A motor with sensitive power control that feels supremely comfortable in the hand.
An aesthetic design with attractive clear shapes. A price / performance ratio that will give you a pleasant surprise.
An additional feature: the new endodontics function allows retrograde root apex resections of the root canal to be prepared in an orthograde manner – without having to change to an endodontic device. That's rather intelligent, isn't it?

People have Priority! W&H supports the humanitarian organization SOS Children's Villages.
Get involved! Further information at wh.com

implantmed

Straight forward or backward planning?



Dr Rolf Vollmer

I am seeing more and more misadventures dealing with complex implant cases. In particular, in the last several months I have seen numerous loading problems dealing with full arch restorations. By and large, the vast majority of these issues relate to a failure in the initial diagnosis. We know from our experience in continuing education courses that diagnosis and decision-making are always the most difficult things to teach and convey. Implant dentistry is now an integral part of many dental practices, however most dentists receive their education in implant dentistry after graduation, with little emphasis on the identification of the complexity and risks of treatment.

I recently became interested in a concept called the SAC classification. SAC stands for Straightforward, Advanced, and Complex. The SAC classification was first described by Sailer and Pajarola in 1999 as a method to categorize degrees of difficulty in oral surgery. In 2003 SAC underwent extensive review and was adapted for implant dentistry; it was also the topic of the ITI Consensus Conference in 2007 to standardize their application.

The basis of the SAC classification is that clinical situations in implant dentistry present with varying degrees of complexity. The SAC classification has applications in esthetical, restorative and surgical situations but can also be helpful in all forms of implant dentistry. Knowing in advance how complex an implant case is can ensure there are no surprises in the course of treatment, or if necessary, can allow you to refer the case to someone who is better able to perform the risky portion and return the case to you for the easy treatment. Usage of the SAC classification can assist practitioners in avoiding difficulties in implant and prosthetic cases as well.

It is, therefore, vitally important that we as practitioners are willing to acknowledge that some cases are more complex or difficult than others, and that we may need experts to deal with such cases. Finding an appropriately qualified colleague to manage a particularly complex case can prevent the case developing catastrophic complications and can avert a poor outcome.

Complex cases simply cannot be treated with a straightforward approach of "open the flap and see what we can do". For these types of cases more of a "reverse planning" approach is recommended—i.e. determine the plan of treatment by starting at the end-point. Generally, working forward from today incorporates neither resource implications nor integration needs. We are mentally so accustomed to the traditional form of thinking that we overlook important items and needs, and make subconscious assumptions that are not necessarily valid. Instead, periodic "reality checks" of the content of our plan of action and its implementation should occur. Regardless of how well planned cases are, 'things' never work out quite as envisaged—all too often real-time developments lead to detours. To minimise such occurrences, modern implantology diagnostic tools like DVT and computer assisted planning are very helpful in complex cases.

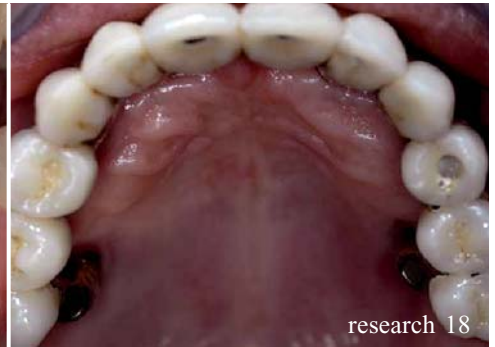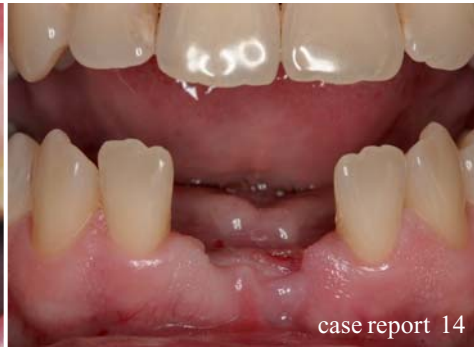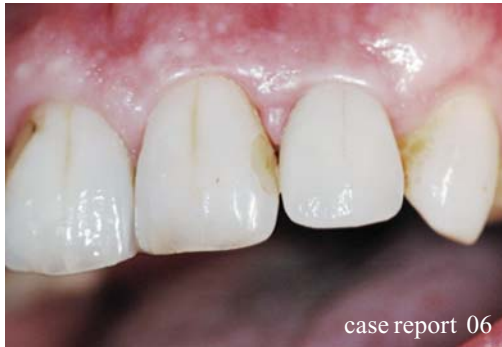Establish the goal, begin at the end and work backward! If done correctly, we will have an ever-evolving, reality-based, integrated plan that will actually work to achieve our patients' aims.

Currently we, as an expert scientific implant association, are happy to offer our colleagues the possibility of undertaking company-independent implant training courses including masters programs at universities. Many dentists involved in the surgical or restorative aspects of implant care obtain continuing education in implant dentistry and belong to professional implant organizations like the German Association of Dental Implantology (DGZI). Our continuing education programs (e.g. our basic curriculum and our Annual Meetings) are some of the best I have ever attended, nationally or internationally.

I hope to see many of you later this year in Berlin from the 1st to 2nd of October to celebrate our fortieth anniversary with an outstanding scientific and social program.

Sincerely

Dr Rolf Vollmer



| editorial

- 03 **Straight forward or backward planning?**
| Dr Rolf Vollmer

| case report

- 06 **Immediate implant placement and temporisation in the aesthetic zone**
| Dr Philip J. Friel
- 14 **Bone Harvesting—nice and easy**
| Dr Steffen Hohl & Dr Anne Sophie Brandt Petersen

| research

- 18 **The concept of “platform switching” in implant dentistry—Part II**
| Dr Virgil Koszegi Stoianov
- 24 **Rehabilitation of atrophic maxillas using zygomatic implants**
| Joan Pi-Urgell, Javier Mir-Mari, Rui Figueiredo & Cosme Gay-Escoda

| user report

- 10 **Use of an X-ray phantom in dental 3-D diagnostics in digital volume tomographs**
| Dr Georg Bach, Christian Müller & Alexander Rottler

| meetings

- 32 **International events 2010/2011**
- 34 **25th Anniversary of the Academy of Osseointegration**
| Dr Rolf Vollmer & Dr Rainer Valentin
- 36 **6th Arab-German Implantology Meeting of DGZI**
- 41 **ITI World Symposium 2010**
- 42 **Interdisciplinary insights from theory to practice**

| implants

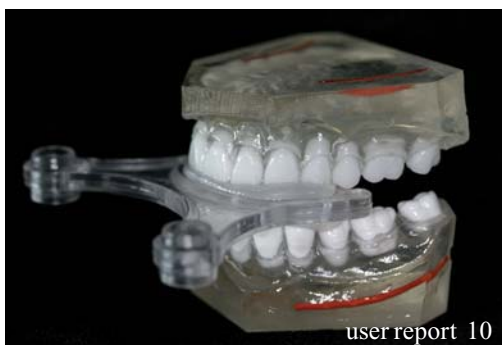- 33 **DGZI's anatomy weekend a full success!**
| Dr Christian Ehrensberger

| news

- 44 **Manufacturer news**
- 48 **Congratulations and Happy Birthday to all DGZI-members around the world**

| about the publisher

- 50 | imprint




NobelReplace™

The world's most used implant system.*

Internal tri-channel connection for accurate and secure prosthetic restorations.

TiUnite® surface and Groovy™ to enhance osseointegration.

Implant design that replicates the shape of natural tooth roots.



Color-coded system for accurate and fast component identification and ease of use.

Color-coding: step-by-step drilling protocol for predictable surgical procedures.

10 YEARS WITH
TIUNITE® SURFACE
New data confirm
long-term stability.

* Source: Millennium Research Group

Versatility, ease-of-use and predictability have made NobelReplace Tapered the most widely used implant design in the world.* NobelReplace Tapered is a general use, two-piece implant system that performs both in soft and hard bone, one- and two-stage surgical procedures, while consistently delivering

optimal initial stability. NobelReplace Tapered is a system that grows to meet the surgical and restorative needs of clinicians and their patients – from single-tooth restorations to more advanced multi-unit solutions. Whether clinicians are just starting or are experienced implant users, they will benefit from a system that

is unique in flexibility and breadth of application. Nobel Biocare is the world leader in innovative and evidence-based dental solutions. For more information, visit our website.

www.nobelbiocare.com

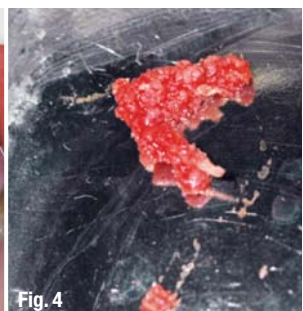
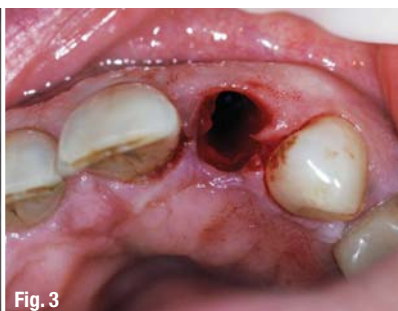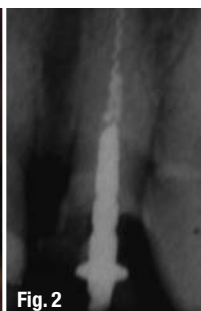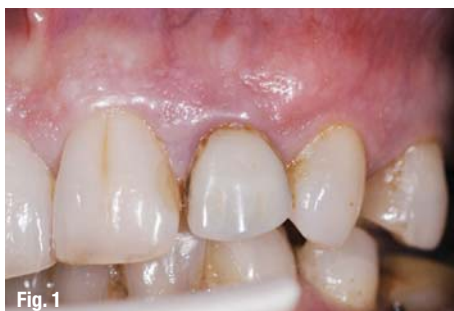Immediate implant placement and temporisation in the aesthetic zone

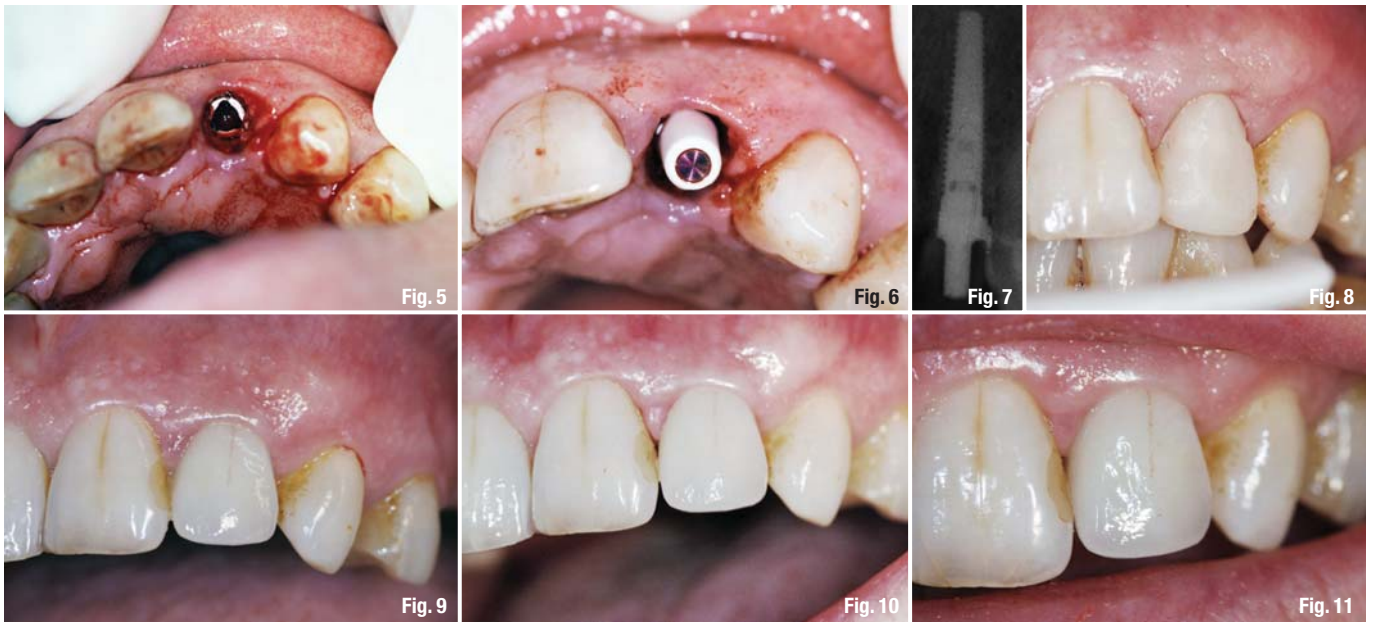
Author_ Dr Phillip J. Friel, Great Britain

The success of dental restorations can be measured in terms of biological stability over time. With regards to dental implantology, the challenge is no longer one of integration, more long term aesthetic stability of the final restoration. Nowhere is this biological and aesthetic stability more important than in the aesthetic zone.

Teeth and their roots have a supportive role to the alveolar bone in which they are retained. This bone in turn gives support to the gingival tissue overlying it, and the level of this bone directly affects the position of this gingival tissue.¹ Following tooth loss, this support is lost, and both the hard and soft tissue begin a process of remodelling. This process invariably results in the loss of bone, and an alteration in the gingival position. While it is possible to replace this support with the use of bone grafting or collagen plug techniques, this can involve a number of surgical procedures in order to achieve the final result. Original protocols in implantology required that implants be placed into healed edentulous ridges. Implants can, however, be placed at the time of tooth extraction.² Such techniques can be used with simultaneous augmentation to

preserve ridge width, decreasing total treatment time. This paper, and its case presentation, outline a technique which allows, in the right conditions, the replacement of the support of a lost root, and consequently prevents major bone remodelling and subsequent alteration of soft tissue position. The following case is one of many completed, ranging from the single tooth to multiple units, all of which have a minimum of twelve months follow-up, and the results of which will be collectively published in the near future. The illustrated case involves a 63 year old, retired female patient who was referred to the clinic timeously by her general dental practitioner following root fracture affecting the upper left lateral incisor. Her chief complaint was one of poor aesthetics affecting this tooth (Fig. 1). The condition of this tooth had declined gradually, following placement of a composite crown three years previously. The composite crown had been placed, retained by a temporary post, following failed root canal therapy during which an endodontic instrument was fractured in the tooth (Fig. 2). The patient was in good health, a regular dental attendee with an adequate oral hygiene regime. A full dental assessment was undertaken to include assessment of

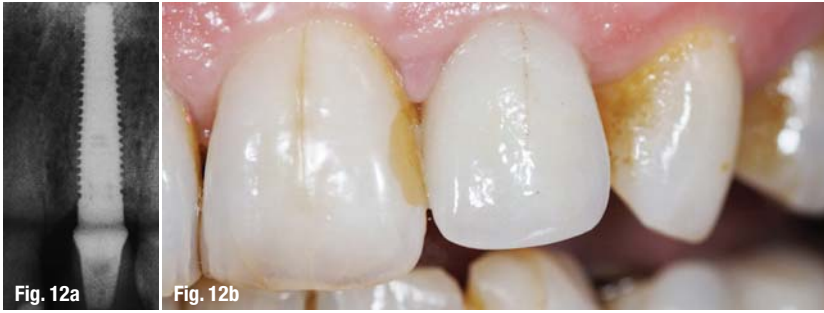



soft and hard tissue, remaining dentition, occlusion and parafunction, current and required oral hygiene and maintenance. The patient was noted to have a high smile line, clearly showing the dentogingival complex in function. A full discussion outlined the options available to the patient, who after consideration, elected a fixed option, with implant restoration being her solution of choice. The patient was fully aware of the risks and alternatives to the procedure, and given her very recent root fracture affecting the tooth, surgery was scheduled for the same week. Mounted study models were produced, upon which, two vacuum formed stents were made over the tooth in question. Full radiographic assessment was undertaken to determine the condition of the remaining root, adjacent teeth and roots, while assessing the area dimensionally for implant placement. The patient was prepared for surgery following pre operative consent and antibiotics together with repeated pre operative rinsing with chlorhexidine gluconate 0.2%. Standard surgical scrub and drapes were employed. The upper left lateral incisor tooth was carefully extracted using periostomes to preserve both hard and soft tissue around the socket.³ This technique facilitates tooth removal without traumatising the alveolar bone of the socket or surrounding gingival tissue. The technique can be performed for any extraction, but it is of particular importance when the subsequent placement of dental implants is envisaged.

Following atraumatic tooth removal, the socket was thoroughly irrigated, debrided and fully assessed (Fig. 3). The socket was found to be intact, stable and formed from solid bone. The

buccal crestal bone was found to be intact, at a good level and supporting the thick gingival genotype overlying it. Having fully assessed the socket, the implant osteotomy was undertaken, following a flapless surgery protocol with both external and internal irrigation, and using the surgical stent as a guide to the final required position. Bone removed during the procedure was harvested (Fig. 4). The osteotomy was prepared and the fixture placed slightly towards the palatal plane. The implant was seated to the desired vertical position to allow ideal soft tissue position after healing. The implant (Nobel Biocare RST 16 mm NP) was inserted and torqued to 35 Ncm (Fig. 5). After implant placement, the socket was then reassessed. As expected there was found to be a slight void between implant and buccal plate. The harvested bone was packed into this defect, as an adjunctive graft, in order to support the buccal plate and its overlying gingivae.⁴ Having placed the implant and harvest graft, the bony socket was now supporting its overlying hard and soft tissues once more. Attention then turns towards gaining support for the crestal soft tissues. An immediate temporary abutment was torqued on to the implant again to 35 Ncm, and a Teflon cap placed over this (Fig. 6). Using the second vacuum formed stent, a temporary crown was constructed using a flowable composite resin, and light cured before being removed. Following removal, the crown is added to and carefully polished, especially in the cervical area, to give a highly polished, ergonomic temporary restoration which is adequately supportive to the cervical gingival tissues, providing a circumferential seal around the marginal area. Following final polishing, the



temporary crown is luted to the temporary abutment using a temporary cement. The post operative radiograph (Fig. 7) shows this situation and highlights a small excess of temporary cement which can be easily removed with floss. The temporary restoration is kept clear of the occlusion. Given the implant is placed directly into the extraction socket, and that the adequately supportive temporary crown provides an excellent crestal gingival seal, no flap is required and consequently, no sutures are used in this procedure. Standard post operative protocols are followed. As a result of this flapless approach, the trauma of surgery is lessened, and review one week post surgery shows an excellent recovery (Fig. 8), with very little sign of any trauma, swelling or alteration of the surrounding gingival tissue, which largely remains unchanged. After a five to six month healing period, during which regular review is undertaken, the temporary crown is removed using a crown remover. The temporary abutment is removed and the socket irrigated. A standard open tray impression technique is used to record the position of the implant, and the temporary abutment and crown replaced. The subsequently produced model is used to construct an abutment and crown, replicating the exact support given by the temporary set up. The case is completed by final abutment placement and torque to 35 Ncm. Following trial fit, and approval of the definitive restoration, the occlusion is checked and adjusted as required. The Zirconia crown is cemented using a resin cement, with care being taken to minimally load the cement and remove any excess prior to and after cure. Occlusion is again assessed and adjusted as required. The success of the restoration is evident immediately after cementation (Fig. 9), at 3 month (Fig. 10), six month (Fig. 11) and 18 month review (Fig. 12 a & b). In order to successfully perform the procedure outlined above, timing is essential, particularly in the case of the root fractured tooth. In these cases, if such treatment is not initiated in good time, the area can become infected with corresponding sinus formation and inevitable loss of the buccal plate of bone. This would entail re-assessment and treatment using a multi-staged, delayed placement regime. In order to perform

flapless surgery, the operator must have suitable experience, and be competent in the procedure. Added to this, as with any surgery, a full knowledge and appreciation of the anatomy surrounding the surgical site is essential to ensure a successful outcome. It is sometimes necessary to carry out further special tests or procedures during the planning stages, to ascertain further information prior to commencement of treatment. These may include CT scanning or ridge mapping of the proposed surgical site. Following atraumatic tooth extraction and socket assessment it may, occasionally, not be possible to proceed with immediate implant placement for a number of reasons. In such cases proper planning is essential to ensure that an alternative treatment option may be undertaken. While flapless surgery incurs decreased trauma and faster healing, during any flapless procedure, it must be remembered that the operator can, at any time, raise a flap, if at all concerned with regards to surgical progress. Biological stability has been maintained from removal of the damaged root right through to cementation of the definitive restoration. By respecting and understanding the natural tissues in this way, predictably excellent results can be achieved time after time.

The clinical photographs and case discussion are included with the expressed permission of the patient involved. All of the laboratory stages for the case were completed by Lincoln Ceramics, Glasgow.

References

1. Gargiulo et al J.Periodontol,1961,31:261–267.
2. Lazzara R J. Immediate implant placement into extraction sites: surgical and restorative advantages. Int J Periodont Rest Dent 1989;9:332–343.
3. Quayle A. Atraumatic removal of teeth and root fragments in Dental Implantology. Int J Oral Maxillofac Implants 1990;5:293–296.
4. Botticelli et al. The jumping distance revisited : An experimental study in the dog. Clin Oral Implants Res 2003;14(1):35–42.

First published in Scottish Dentist March-April 2008.

_contact	implants
<p>Dr Philip J. Friel Philip Friel Advanced Dentistry 170 Hyndland Road G12 9HZ Glasgow, Great Britain</p>	



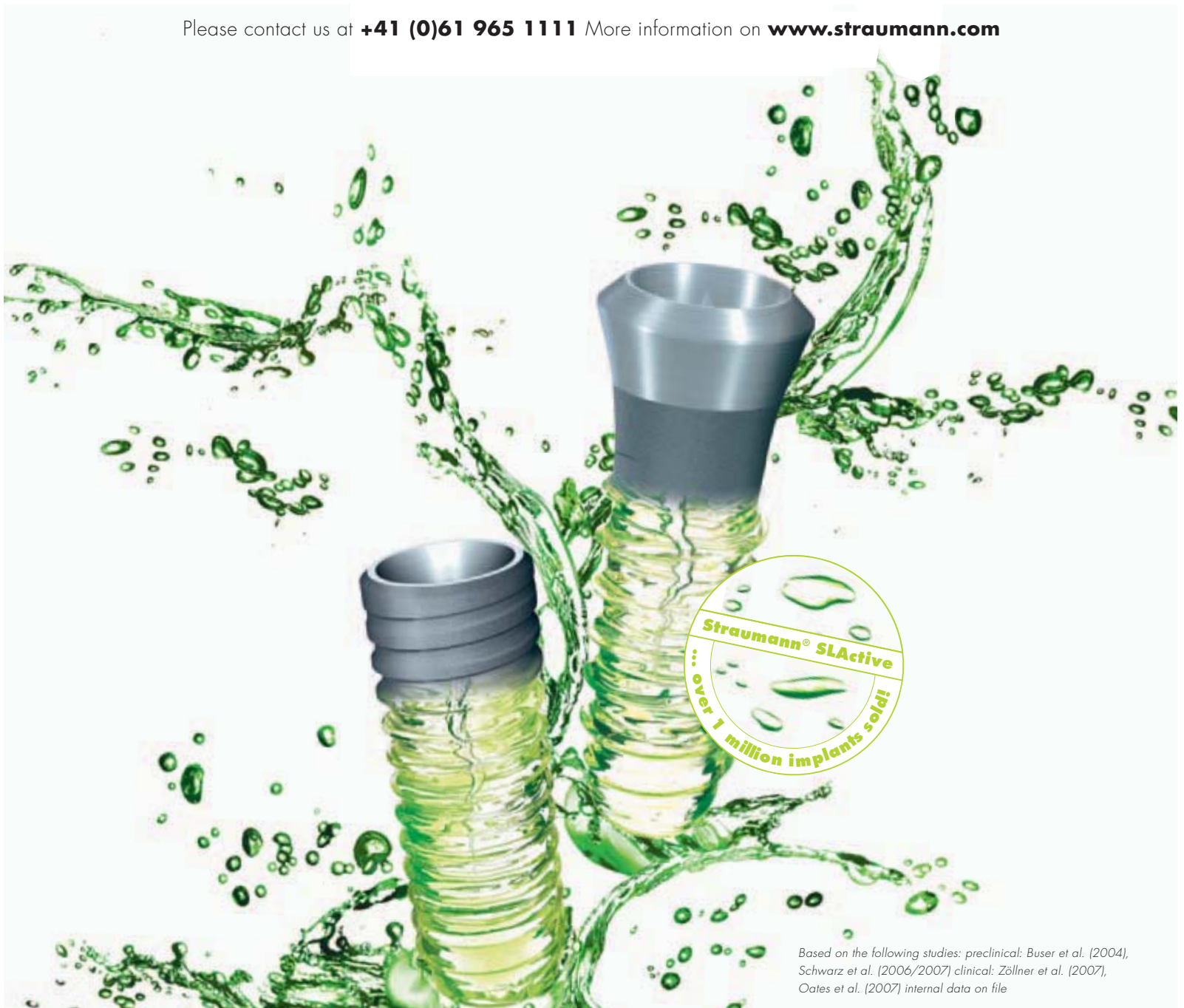SIMPLY BETTER

STRAUMANN® SLActive

Straumann® SLActive – The next generation in surface technology

- Higher security and faster osseointegration for every indication
- Reduced healing times from 6–8 weeks down to 3–4 weeks
- Increased treatment predictability in critical protocols

Please contact us at **+41 (0)61 965 1111** More information on **www.straumann.com**



COMMITTED TO
SIMPLY DOING MORE
FOR DENTAL PROFESSIONALS