

roots

international magazine of endodontics

case report


Retreatment of a tooth
with a double curvature


trends & applications

Testing a novel endodontic sealer

meetings

ROOTS SUMMIT: New dates





VDW.ROTATE™ NiTi Root Canal File

The remix taking rotary preparation to the next level

VERSATILITY

VDW.ROTATE™ includes an intuitive 3 file basic sequence plus a wide range of larger files for various clinical cases with matching paper points and obturators.

Be virtuoso!

RESPECT OF THE NATURAL CANAL ANATOMY

The instruments follow the natural canal anatomy smoothly thanks to its specific heat treatment making the file more flexible without compromising its cutting efficiency.*

Get in the swing!

EFFICIENT DEBRIS REMOVAL

The adapted S cross section gives more space for debris removal and provides control of the instrument for a swift, thorough and safe preparation.**

Set the beat!

*compared to other VDW continuous rotary instruments
**compared to a centred rotary cross section

Dr David E. Jaramillo

Guest editor
Scientific director of ROOTS SUMMIT



Dear readers,

It is difficult to believe that nearly two years have passed since the last extremely successful ROOTS SUMMIT in Berlin. It is also difficult to believe that it will be one more year until we will meet due to the current issues surrounding the COVID-19 pandemic. The safety and security of all was our primary consideration when the decision was taken to postpone the live ROOTS SUMMIT until 20 to 23 May 2021. As that is far too long to get together and share the numerous scientific and clinical information that has been generated, we will be having an online ROOTS SUMMIT which will take place on 22 and 23 May 2020.

It is an honour to be the scientific director of the event again. As with all ROOTS SUMMITs, we have an outstanding line-up and combination of clinicians and researchers ready to share their results in both areas. We are certain that attendees and viewers will be pleased with and surprised at the advanced surgical techniques and research that will be shared at both events.

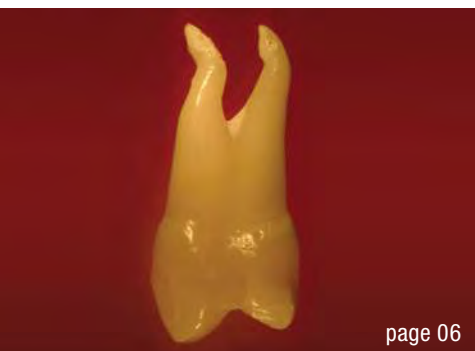I am also pleased to announce that **roots magazine** is launching a new section containing the latest clinical

research—more than worthy of inclusion in any peer-reviewed journal. The first paper is about the importance of knowledge of the root canal anatomy to avoid iatrogenic failures in a two-rooted maxillary premolar. A world-renowned expert on this topic and vertical root fractures, Dr Aviad Tamse, professor emeritus at Tel Aviv University, was gracious enough to submit this paper, and you will not want to miss it.

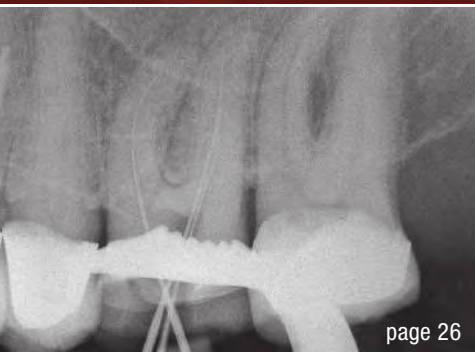We hope that you will enjoy this issue of **roots**. We also hope that you will join us in Prague for our unique online meeting, where all participants see the same presentation and where the camaraderie of our global membership will create yet another outstanding endodontic and social experience.

I look forward to seeing you at the online ROOTS SUMMIT this May, and in person in Prague in May 2021.


Dr David E. Jaramillo
Guest editor
Scientific director of ROOTS SUMMIT



page 06



page 26



page 46

Cover image courtesy of Henry Schein
www.henryschein.com



editorial

Dear **readers** 03
Dr David E. Jaramillo

study

Buccal root of the **bifurcated maxillary** premolar—**a danger zone** during root canal therapy 06
Drs David E. Jaramillo & Aviad Tamse

research

Innovative endodontics using **SWEEPS** technology 10
Drs Giovanni Olivi & Matteo Olivi

case report

Treatment of the result of chronic activation of **substance P** 16
Prof. Philippe Sleiman, Dr Pamela Kassabian, Dr Valerie Batrouni & Dr Alexey Volokitin

Root canal **therapy with a modular NiTi system**: A case report 20
Dr Vishal P. Gandhi

Retreatment of a tooth with a **double curvature** 24
Dr Gaizka Loroño

trends & applications

Testing a **novel endodontic** sealer 26
Drs Paolo Generali & Francesca Cerutti

manufacturer news 30

practice management

Successful **communication** in your **daily practice**
Part X: How to improve your own punctuality 32
Dr Anna Maria Yiannikos

“As dental coaches, **we are servants in a noble profession**” 34
An interview with Kirk Behrendt

feature

“**Diets rich in plant foods** are increasingly associated with **longevity and healthy ageing**” 36

“**We aim to prepare dentists** for care of the **ageing population**” 40

meetings

AAE announces its 2020 **award winners** 42

ROOTS SUMMIT: **New dates** 44

AAE considerations for dental care during COVID-19 crisis 46

about the publisher

submission guidelines 48

international imprint 50

HyFlex™ CM & EDM

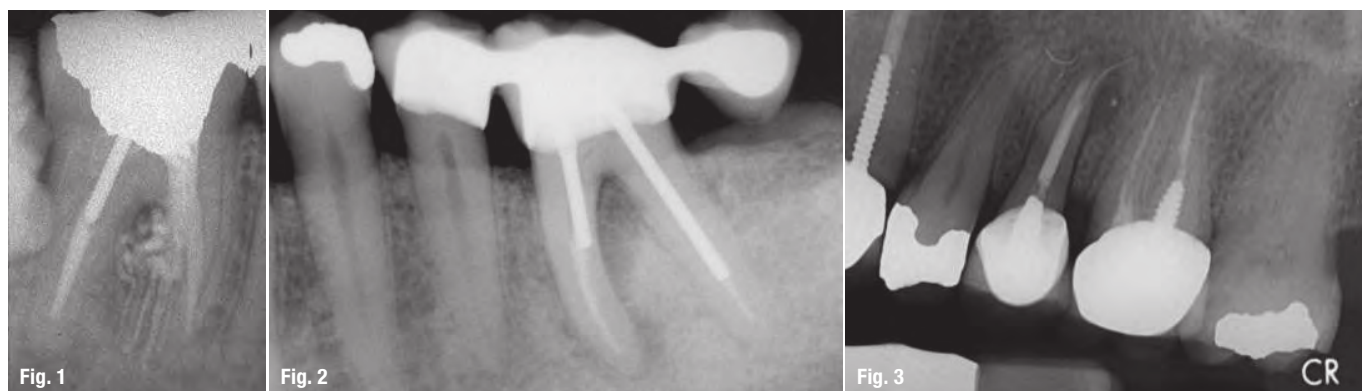
STAYS ON TRACK



- Safer use
- Preparation following the anatomy
- Regeneration for reuse

Buccal root of the bifurcated maxillary premolar—a danger zone during root canal therapy

Dr David E. Jaramillo, USA & Dr Aviad Tamse, Israel

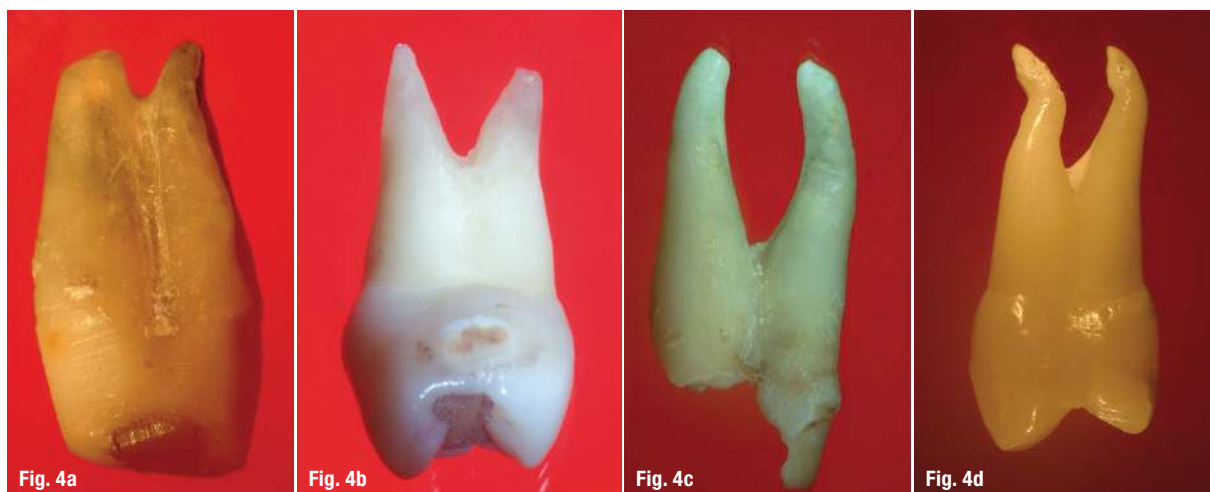

The purpose of this study is to describe the depression in the buccal root of the bifurcated maxillary premolar as a danger zone during and after endodontic treatment and to recommend clinical modalities to prevent root fractures and perforations in this root.

There are a known number of reasons for complications during and after root canal preparation.¹ Curved roots such as the mesial root of the mandibular molar are a challenge to prepare and clean, and this was especially the case during the era of stainless-steel instruments.^{2,3} The curvature in the middle part of the mesial root is still considered a danger zone where either strip

perforations (Fig. 1) or perforations from a post can still occur (Fig. 2).

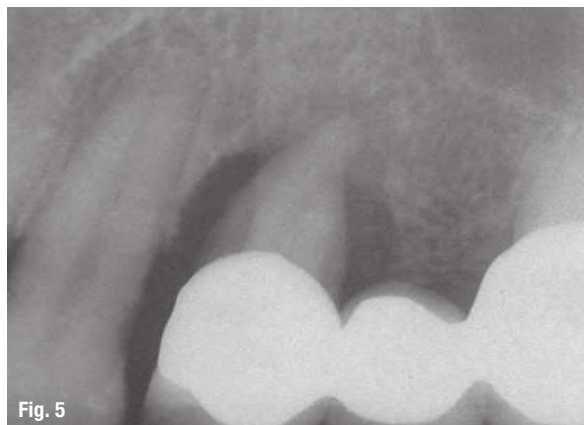
Almost half of maxillary premolars are two-rooted. These roots present a variety of morphological and anatomical appearances, such as roots spreading apart and a variety of locations of bifurcation from the coronopical direction (Figs. 4a–d). Curved and divergent roots and root canals are difficult to treat endodontically. One major reason for the operator's frustration is the fact that, in bifurcated maxillary premolars, it is extremely difficult to determine the aetiology when a poor outcome is diagnosed.



Maxillary premolars are among the teeth most susceptible to vertical root fractures in endodontic treatment.^{4,5} This is a common complication of endodontic treatment and most often leads to the extraction of the tooth or root (Fig. 3).^{4,5} Although the American Association of Endodontists stated that the combination of a deep probing defect and a sinus tract in the endodontically treated tooth is pathognomonic for a vertical root fracture,⁶ only some vertical root fracture cases manifest these signs and symptoms at the same time. This occurs for a variety of reasons. The signs, symptoms and radiographic features often mimic those of a poor endodontic outcome or periodontal disease, and it may be difficult to correlate the clinical findings to the radiographic manifestations. In a systematic review on this topic, it was concluded that there is a conflict between the clinical importance of timely and accurate diagnosis of vertical root fractures in the endodontically treated tooth and a lack of evidence-based data supporting the usefulness of common clinical and radiographic evaluation methods.⁷

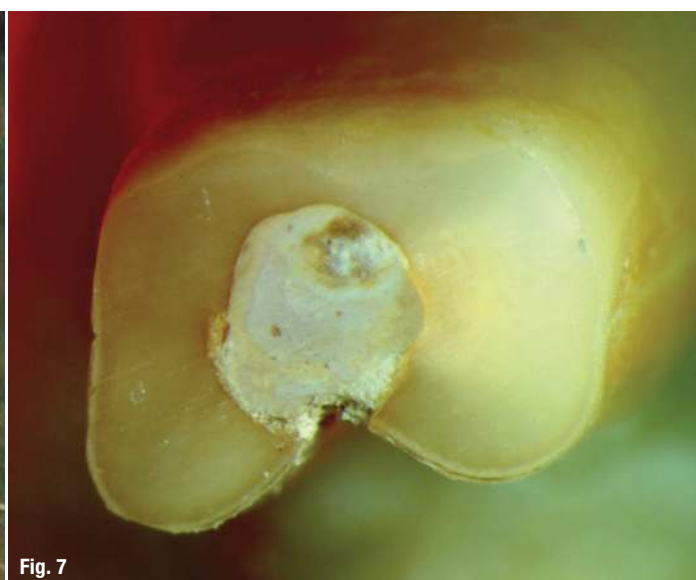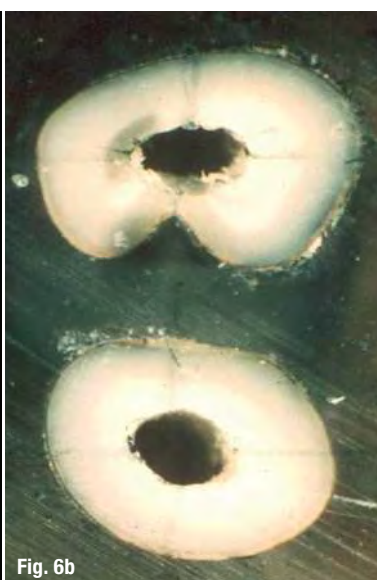
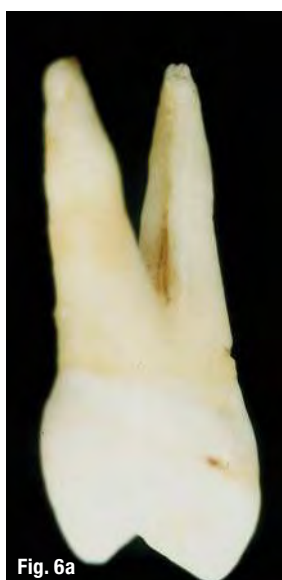The findings mentioned are especially true in bifurcated maxillary premolars. The major reason is the unfavourable position of the bifurcated premolar in the jaw. The buccopalatal roots are positioned buccopalatally in the maxilla, and if an endodontic complication occurs in one of the roots, whether a vertical root fracture, perforation or even just a poor outcome of an endodontic treatment, it can be extremely difficult at times to establish the reason on a routine periapical radiograph.

This unfavourable position of the roots at times causes a periodontal problem around the tooth. A mesiodistal bifurcation is very difficult for the patient to clean, and if a periodontal pocket occurs, the periodontal disease will advance very rapidly (Fig. 5).



The bifurcated maxillary premolar has a complex anatomy and morphology as described in the endodontic textbooks and atlases. In the buccal root of the maxillary premolar, there is a unique anatomical feature: a depression (called also a concavity or furcation groove) in the bifurcation (palatal) aspect of the root, located mostly in the middle (Figs. 6a & b). The morphometric characteristics of this depression have previously been described and found to occur in between 78 and 100 per cent of cases.⁸⁻¹² Booker and Loughlin claimed that the original thickness in this area is extremely thin.¹³ Gher and Vernino speculated that the depression represents a tendency of the buccal root to form two separate buccal roots during tooth development.¹²

In a study of 35 bifurcated maxillary premolars, this depression in the buccal root was found in 97 per cent of the cases.⁸ Most of the root canals had a kidney shape, and the mean width of the distance from the deepest areas of the invagination to the canal wall was 0.81 mm. Li et al. found the same results using computed tomography.¹¹ Therefore, it is thus understandable that it is



risky (in terms of fracture or perforation) to remove too much dentine in this area, whether with hand instrumentation or in preparing circular flaring to fit a post (Fig. 7).

A recent study by Chai and Tamse again demonstrated the necessity of trying to maintain the original shape and size of the buccal root canal during endodontic treatment in order to avoid vertical root fractures in endodontically treated teeth.¹⁴ This study looked at the issue of vertical root fracture from the stress and force aspect. The results showed that, although vertical root fracture can occur in the palatal root as well, it was mostly limited to the buccal root. Using a finite element analysis technique, it was shown that, when force from lateral condensation was applied to this root, the stress concentrated at the deepest point of the depression and from this initiation point, the fracture propagated either in a straight line to the canal wall or as two or more curved fractures to the canal walls (Figs. 8a–d).

According to Mamede-Neto et al., no file system is able to achieve perfectly centred root canal preparation, so care should be taken especially when using a reciprocating system.¹⁵ This system presents the most mesiodistal and buccolingual transportations compared with a rotary instrumentation system.

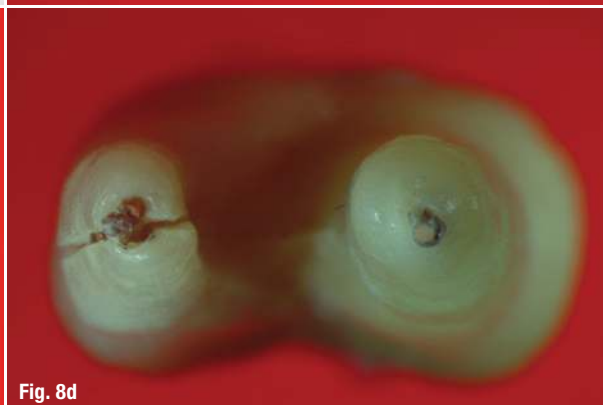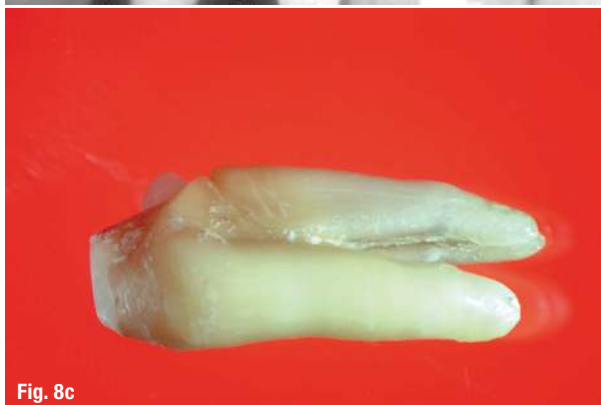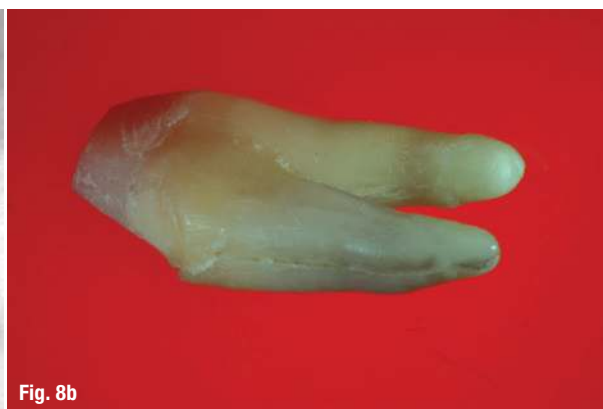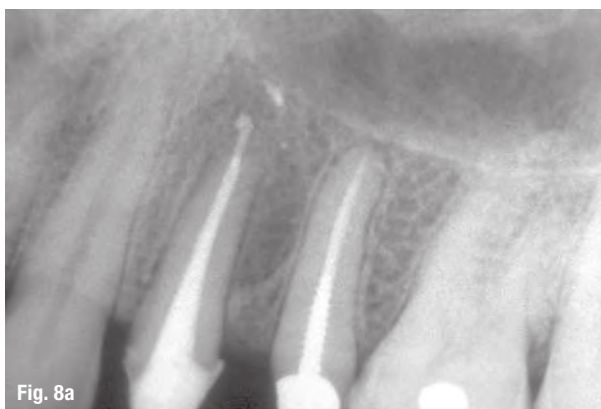
In his histological evaluation, Walton compared instruments and techniques and found that none were able to achieve complete debridement of pulp tissue from

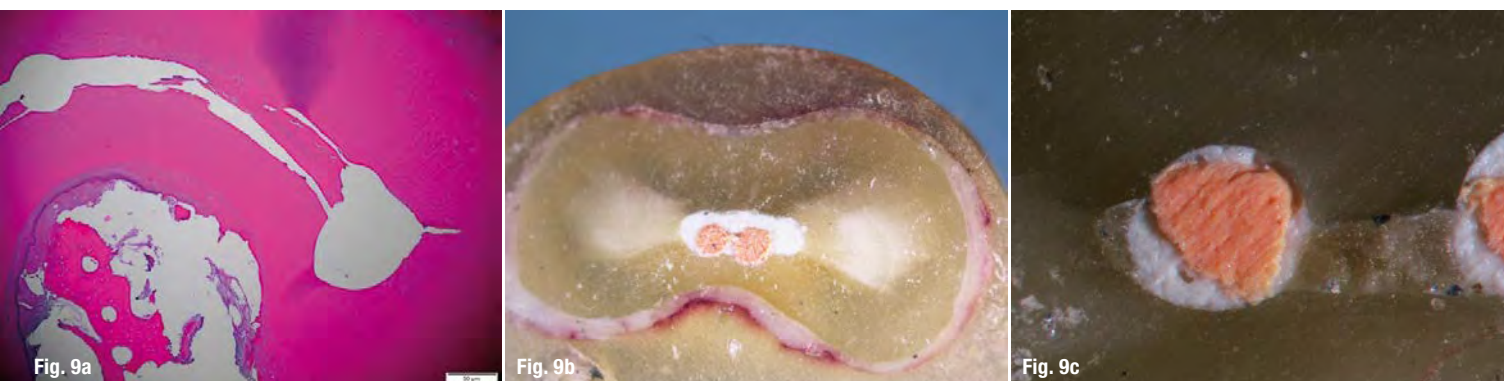inside the root canal system.¹⁶ This is in agreement with Gutiérrez and Garcíá, who were the first authors to report the lack of effectiveness of any instrumentation technique in obtaining root canals completely free of pulp tissue.¹⁷ Owing to the impossibility of obtaining complete pulpal debridement, root canal enlargement is the main purpose of the general dentist and endodontist.

Kerekes and Tronstad published a morphometric evaluation on the different root canal sizes of anterior teeth, premolars and molars.^{18–20} They found large diameters in all thirds of the root canals of maxillary first and second premolars. These findings may suggest to the operator to enlarge the width of the root canal in order to obtain cleaner and better pulpal debridement of the root canal system. As a result of the excessive reduction of dentine in the most critical areas, strip perforation may occur.

All these findings lead us in the direction of a better knowledge and understanding of root canal shapes and sizes in the various canal locations, in order to prevent over-instrumentation that could lead to weakness of the root and possible root fracture.

The problem of effective cleaning of the root canal system is especially true in those root canals which are not round in cross section, that is, oval root canals in those roots which are also susceptible to fracture, such as the maxillary premolars, the mandibular premolars and the mandibular incisors.²¹ In a series of studies, it was





demonstrated that long oval canals are impossible to instrument and clean completely, leaving many areas of the canal walls uncleared and with debris.^{22–24} Extra care should be taken in instrumentation and cleaning in order not to perforate such canals¹⁶ and in order to ensure proper obturation.^{23,24}

Weller et al. compared ultrasonic instrumentation and hand instrumentation with ultrasonic irrigation.²⁵ Their findings were that there was no difference in the debridement efficiency between hand and ultrasonic instrumentation compared with ultrasonic irrigation alone. But when they added ultrasonic irrigation to both (hand and ultrasonic) instrumentation groups, they obtained better results. In summary, the ultrasonic instrumentation technique does not improve root canal debridement. This is only improved when there is a combination of any instrumentation technique and ultrasonic irrigation.

Langeland et al. found hand, sonic and ultrasonic instrumentation to be ineffective in the complete debridement of the curved roots of mandibular molars.²⁶ Van der Vyver et al. found, independent of the nickel-titanium alloy phase or heat treatment, that all rotary and reciprocating systems produce root canal transportation in all three root canal thirds.²⁷

The introduction of newer technology such as the GentleWave system (Sonendo) allows minimal instrumentation of the root canal system with excellent debridement parameters (Fig. 9a) by producing multi-sonication in a de-gassed liquid and closed system. The closed system allows the propagation of multi-sonication waves that reach all areas of the complex root canal anatomy.²⁸

Minimally invasive instrumentation of the root canal system will increase the possibility of less reduction of tooth structure, thus decreasing the possibility of weakening of the root canal walls. Reducing the risk of file separation, canal perforation and fractures is a further benefit of minimally invasive instrumentation, which results in significantly less presence of debris (Fig. 9b) compared with conventional methods (Fig. 9c).

Editorial note: A list of references is available from the publisher.

about



Dr David E. Jaramillo, DDS, is Professor in the Department of Endodontics at The University of Texas Health Science Center School of Dentistry at Houston. Former clinical assistant professor of endodontics at the University of Southern California (USC) in Los Angeles (2004–2006). He was an associate professor at Loma Linda University School of Dentistry in California (2004–2014). Actively participated in research at the Center for Biofilms under the direct supervision of Dr William Costerton at USC School of Dentistry and the Department of Electrical Engineering/Electrophysics at USC Viterbi School of Engineering. Dr Jaramillo is scientific director for ROOTS SUMMIT meetings. Former president of Houston Academy of Endodontists, Chair IFEA Grant Research Committee and new member of the International College of Dentists USA Section. He has 2 patents in the US.



Dr Aviad Tamse received his DMD degree from the Hebrew University and Hadassah Faculty of Dental Medicine in 1969, and from 1971 to 1973, he attended the Harvard School of Dental Medicine, Boston, Massachusetts, where he received his endodontic training. Dr Tamse was twice President of the Israel Endodontic Society, Chair of the Endodontic Board Examiners Committee of the Israel Dental Association Scientific Committee, and Chair of the Accreditation Committee of Graduate Dental Programs of the Israel Dental Association. Dr Tamse served as chair of the department of Endodontology Tel-Aviv University School of Dental Medicine from 2000–2008, and in 1982 was a co-founder of the European Society of Endodontology. Currently Dr Tamse is Professor Emeritus at the Department of Endodontology, School of Dental Medicine, and Tel-Aviv University.

contact

Dr David E. Jaramillo

Scientific director
ROOTS SUMMIT
dejarami@mac.com