

DENTAL TRIBUNE

The World's Dental Newspaper • Pakistan Edition



PUBLISHED IN PAKISTAN

www.dental-tribune.com.pk

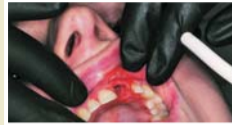JANUARY, 2019 - Issue No. 01 Vol.6



An exclusive interview with Dr Arif Alvi

INTERVIEW

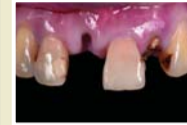► Page 4



Fast, functional aesthetic solution for anterior ...

CONVOCAATION

► Page 6



Immediate implantation with CAD/CAM and functional ...

CLINICAL IMPLANTOLOGY

► Page 8

Hamdan Bin Rashid inaugurates Dubai Dental Hospital at Arab Health 2019

DT Pakistan Correspondent

DUBAI- H.H. Sheikh Hamdan bin Rashid Al Maktoum, Deputy Ruler of Dubai, Minister of Finance and President of the Dubai Health Authority, inaugurated the Dubai Dental Hospital, the first and largest dental hospital in Dubai, on the opening day of Arab Health.

The hospital, which started out as Dubai Dental Clinic in 2008, has increased its capacity by 125 percent with eight specialties under one roof with a fully-equipped dental lab, post-surgery rooms, and an in-house sterilisation department. Accredited by Joint

Commission International, the Dubai Dental Hospital is equipped with state-of-the-art technologies, the hospital has its own imaging department with 3D radiology, Computer-aided Design/Computer-aided Manufacturing, CAD/CAM, an Intra Oral Scanner and a dental laboratory and digital teeth scanning.

The revamped hospital includes 63 dental chairs, making it the largest specialised dental facility in Dubai. With more than 100 qualified healthcare professionals, it strives to provide greater access to specialised oral treatment for patients of all ages, meeting the growing demand for

dental care in the region. "As an urban healthcare landmark and the largest healthcare free zone in the world, the Dubai Healthcare City is committed to advancing healthcare in the UAE and the wider region. The launch of the Dubai Dental Hospital is the latest initiative that reinforces our commitment and dedication in helping to drive and build world-class healthcare facilities," Dr Amer Al Zarooni, CEO, Dubai Healthcare City Medical. Under the direction of a highly-skilled team of oral healthcare professionals, the hospital will continue to deliver patient-specific



Image Photo: UrduPoint

healthcare in compliance with international best practices. The dental hospital provides treatment across eight specialist areas: general dentistry, dental hygiene, paediatric dentistry, cosmetic dentistry, oral surgery, orthodontics, prosthodontics, endodontics periodontal treatment and dental implantology.

"This day is the culmination of the hard work and efforts of everyone at DDH and is a testament to their commitment that we can mark this milestone in our mission to provide greater

access to specialised oral treatment for patients of all ages, meeting the growing demand for dental care in the region," said Dr Khawla Belhouli, Director, Dubai Dental Hospital.

In addition to providing patients unrivalled access to specialist treatment and expert advice, the hospital is the clinical partner of the Mohammed Bin Rashid University of Medicine and Health Sciences, providing clinical training for the university's Hamdan Bin Mohammed College of Dental Medicine residents.

Tenure of members cut to three years: PMDC ordinance

DT Pakistan Report

ISLAMABAD - In a first, the federal government has decided to revise the tenures of members of the country's top medical education regulator apart from ending the representation of elected lawmakers on the board's table. This is contained in the new Pakistan Medical and Dental Council (PMDC) Ordinance 2019 which was approved by President Arif Alvi recently. According to the ordinance documents, the federal government has

reduced the tenure of the council's members from four years to just three years.

The membership of federal and provincial health ministers, federal secretaries including senate and national assembly members, has also been withdrawn, making the council free of political interference.

According to the ordinance, the new council will now comprise 17 members; of these, three members will be nominated by the prime minister. These members shall be prominent members of civil society.



(Image: DT Pakistan)

Other members of the council will include a professor and an associate professor from each public medical college as per their rank and experience. They will be nominated by their respective provincial governments. Two members of the council will be from private medical colleges who will be nominated by the prime minister. Moreover, there will be two members from the clinical faculty of dental colleges who will be taken from the four provinces

on a rotation basis. In this regard, one of these members will be chosen from either Punjab or Khyber-Pakhtunkhwa while the second member will be nominated from either Sindh or Balochistan. Another member of the council will be nominated by the surgeon general of the armed forces medical services group. The president of the College of Physicians and Surgeons of Pakistan (FCPS) will nominate one member.

Continued on Page 14

FMH College of Dentistry bags top positions

DT Pakistan Report

LAHORE - FMH College of Dentistry has achieved first position among all dental colleges in Punjab. The students achieved outstanding distinctions by bagging first three positions in the First Professional BDS Annual Examination held in November/December 2018 by the University of Health Sciences. Names of position holders are; 1st Position - Mr. Hassaan Hafeez Sheikh and Ms. IrhaWajahat, 2nd Position - Ms. Neha Feyyaz, and Ms. Zarish Iqbal, 3rd Position - Mr. Muhammad HamizAftab.

PM Khan stresses over accessible quality healthcare



(Photograph: MOIB, Govt.Pk)

DT Pakistan Report

ISLAMABAD - Prime Minister Imran Khan has asked the concerned officials to spot the bottlenecks related to administrative and legislative matters in reforming the health sector. He has stressed on the need to remove those practices that have resulted in the decay of health services and have hindered the provision of quality healthcare to the ordinary people.

The PM recently chaired a briefing on health reforms being undertaken in Islamabad Capital Territory, Punjab and KP, at the Prime Minister Office (PMO). He highlighted the significance of state-of-the-art laboratories and a comprehensive mechanism to check for, food contamination leading to stunted growth and other health hazards, in coordination with the concerned authorities at the federal and provincial levels.

The meeting was informed that Islamabad Public Health Management Authority is being

established according to the recommendation of Task Force on Health. The PM observed that health management has remained a neglected area in the country, and said that there was a need to ensure effective and robust health management mechanism across the country and to ensure access to quality healthcare for citizens. Federal Minister for Health Amir Mehmood Kiani, Adviser to Prime Minister Muhammad Shahzad Arbab, Minister for Health Punjab Dr Yasmin Rashid, Minister for Health KP Dr Hisham Inamullah Khan, federal & provincial secretaries from health department, and other senior government officials were present during the meeting.

Federal Secretary Health briefed the meeting on the National Action Plan for NHSR&C (2019-23), and Islamabad Capital Health Strategy NHSR&C Strategic Plan in the backdrop of abolition of CADD and transferred health service delivery in ICT area to Ministry of NHSR&C.

The main objective of the National Action Plan is to identify strategic areas and actions to overcome health challenges through holistic initiatives in health governance, financing, access to essential package of health services, expansion and capacity building of human resources for health, quality of health, adherence to international health regulations and ensuring continuous research and innovation in the healthcare.

For the last 55 years, the hospital beds capacity in the ICT hospitals had remained stagnant at 2000 beds only; under the new Capital Health Strategy, this capacity is being doubled to 4000 beds in a span of five years in the ICT area.

Moreover, a state-of-the-art Cancer Hospital with 200 beds in ICT, a General Hospital at Tarlai having 200 beds, three Mother Child Hospitals with total 120 beds capacity at Bhara Kahu, Rawat and Tarnol are being established and upgraded while refurbishment & upgradation of all

Continued on Page 15

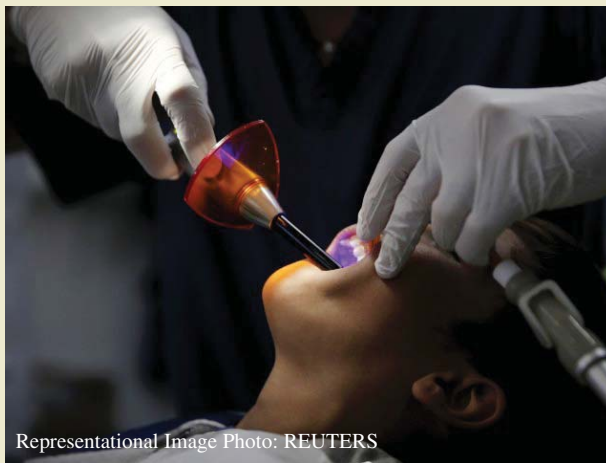KCD to offer FCPS training in periodontology

DT Pakistan Report

PESHAWAR - The Khyber College of Dentistry has become the first public sector institute of the country to offer offering training in Periodontology after securing accreditation from the College of Physicians and Surgeons Pakistan (CPSP) for FCPS part-II training.

The Periodontology Department of Khyber College of Dentistry (KCD) has been fully accredited by the CPSP for Fellow of College of Physicians and Surgeons (FCPS) part II training. Associate Professor Dr Tariq Ali Khan has been approved as a supervisor for training in Periodontology.

The Periodontology Department was established in KCD around 39 years ago. It has now been equipped with lasers, microsurgical instruments and Cone-beam computed tomographic (CBCT) equipment. This department provides basic periodontal treatments along with some advanced procedures such as implants, periodontal plastic surgeries, gummy smile corrections and guided tissue regeneration. In 2018, after a series of visits of the Pakistan Medical and Dental Council (PMDC) teams to the KCD medical teaching institute (MTI), its seats were enhanced from 50 to 80.



Representational Image Photo: REUTERS

DENTAL TRIBUNE

The World's Dental Newspaper - Pakistan Edition

Publisher/CEO

Syed Hashim A. Hasan
hashim@dental-tribune.com.pk

Editor Clinical Research

Dr. Inayatullah Padhiar

Editors Research & Public Health

Prof. Dr. Ayyaz Ali Khan

Editor - Online

Haseeb Uddin

Designing & Layout

Sh. M. Sadiq Ali

Dental Tribune Pakistan

3rd floor, Mahmood Centre, BC-11, Block-9
Clifton, Karachi, Pakistan.
Tel.: +92 21 35378440-2 | Fax: +92 21 35836940
www.dental-tribune.com.pk
info@dental-tribune.com.pk

Dental Tribune Pakistan cannot assume responsibility for the validity of product claims or for typographical errors. The publisher also does not assume responsibility for product names or statements made by advertisers. Opinions expressed by authors are their own and may not reflect of **Dental Tribune Pakistan.**

International Imprint

| | |
|--|--|
| Publisher/Chief Executive Officer | Torsten R. Oemus |
| Chief Financial Officer | Dan Wunderlich |
| Director of Content | Claudia Duschek |
| Senior Editors | Jeremy Booth Michelle Hodas |
| Clinical Editors | Nathalie Schüller Magda Wojtkiewicz |
| Editor & Social Media Manager | Monique Mehler |
| Editors | Franziska Beier Brendan Day Luke Gribble Kasper Mussche |
| Assistant Editor | Iveta Ramonaite |
| Copy Editors | Ann-Katrin Paulick Sabrina Raaff |
| Business Development & Marketing Manager | Alyson Buchenau |
| Digital Production Managers | Tom Carvalho Hannes Kuschick |
| Project Manager Online | Chao Tong |
| IT & Development | Serban Veres |
| Graphic Designer | Maria Macedo |
| E-Learning Manager | Lars Hoffmann |
| Education & Event Manager | Sarah Schubert |
| Product Manager Surgical Tribune & DDS.WORLD | Joachim Tabler |
| Sales & Production Support | Puja Daya Hajir Shubbar Madleen Zoch |
| Executive Assistant | Doreen Haferkorn |
| Accounting | Karen Hamatschek Anita Majtenyi Manuela Wachtel |
| Database Management & CRM | Annachiara Sorbo |

Media Sales Managers
Melissa Brown (International)
Hélène Carpentier (Western Europe)
Matthias Diessner (Key Accounts)
Maria Kaiser (North America)
Weridiana Mageswki (Latin America)
Barbora Solarova (Eastern Europe)
Peter Witteczek (Asia Pacific)

Executive Producer **Gernot Meyer**

Advertising Disposition **Marius Mezger**

Dental Tribune International GmbH

Holbeinstr. 29, 04229 Leipzig, Germany
 Tel.: +49 341 48 474 302 | Fax: +49 341 48 474 173
 info@dental-tribune.com | www.dental-tribune.com

©2019, Dental Tribune International GmbH. All rights reserved. Dental Tribune International makes every effort to report clinical information and manufacturer's product news accurately, but cannot assume responsibility for the validity of product claims, or for typographical errors. The publishers also do not assume responsibility for product names, claims, or statements made by advertisers. Opinions expressed by authors are their own and may not reflect those of Dental Tribune International.

Raho totally tayyar zindagi ke liye



12 Hour Mouth Protection?

With whole mouth health protection

✓ TEETH ✓ TONGUE ✓ CHEEKS ✓ GUMS

With an ordinary fluoride toothpaste, patients can only get fluoride protection for teeth, which are just 20% of mouth surfaces.¹

Significant bacterial reduction on
100% of mouth surface, in 100% of patients^{2,3}

- Bacteria reduced by 50% on teeth, tongue, cheeks and gums
- Results shown 12 hours after brushing

Help all your patients achieve Whole Mouth Health with **Colgate Total**[®]

References: 1. Collins LMC, Dawes C. *J Dent Res.* 1987;66:1300-1302. 2. Fine DH, Sreenivasan PK, McKiernan M, et al. *J Clin Periodontol.* 2012;39:1056-1064. 3. Data on file. Data analysis from reference 2: analysis of antimicrobial effect of 3 toothpastes on teeth, tongue, cheeks and gums. Reductions shown represent ≥ 50% bacterial reduction on 100% of mouth surfaces.



Colgate[®]



(Photograph: Arsalan A. Shaikh)

An Exclusive Interview

I thought that I might have to change from dentistry to some other profession: Dr Arif Alvi

By Syed Hashim Hasan

Dr Arif Alvi was recently interviewed by *Dental Tribune Pakistan*, and the excerpts of the exclusive talk with him are as under:-

Syed Hashim Hasan: Let's begin with a topic that is of interest to the masses, which is that you have a bullet in your arm. Why did you decide to keep it?

President Dr Arif Alvi: (laughs) I didn't decide to keep it. I was injured in the late 1960's- I think it was 1969. It was a struggle for democracy against Ayub Khan. I got shot, and was transported to the hospital by a cyclist, who took me to Mayo Hospital from Mall Road. The doctors there were more concerned about establishing broken nerve contact and blood supply, and therefore, they said that to fish around for the bullet was not possible. The damage was so severe that for about 8 to 9 months I was not able to move fingers. The motor neurons had not recovered. Even today, the sensory supply to two or three of my fingers is relatively poor. For example, I am not able to count pages or money. So that is a good point. I still can't count money with my right hand. All the bad things come into the left hand to count. I think that was the reason why the doctors at that time decided not to probe for two bullets in the arm, and so they are still there.

HH: So there are two and not one bullet in your arm?

AA: Yes, one can be felt but the other one.

HH: Dentistry is a skill where hands play a pivotal role so how come it did not affect your practice?

AA: No, it has not affected my practice. My motor neuron situation recovered

in about a year. Back then, for about four to five months I had thought that I might have to change from dentistry to some other profession. That was during the final year of BDS, so it was very disappointing.

HH: Belonging to a family of dental surgeons, what exactly led you into politics?

AA: Actually, I was always interested in anti-corruption; I was always interested in the history of Pakistan; and I was always frustrated when I looked at the deprived people of our society. Then there was the fact that my father was also a politician and a dentist; he was dentist to Jawaharlal Nehru. So because he was a politician, there was good discussion in the family about politics. The third reason was that my mother was a very well-read lady, and she exposed to me a variety of reading material. In the college days, on her recommendation and her insistence, I used to read philosophy, Marxian theories, and Maulana Maududi and his Islamic Law and constitution. This was all at the time of my intermediate. As she persisted, my interest in reading increased, and it still continues. I must pray for her forgiveness from Allah (SWT).

HH: So along the way what was the role of your family and friends?

AA: In politics, the family was very supportive. I think what I am today, the family has a lot to do with that. And it's not being said as a cliché. I believe very strongly that without the support of the family, I would not have been where I am. For example, in the management of my Alvi Dental Hospital, my wife has played such a big and tremendous role that I never knew what was the income of the

hospital, who was being employed, and all the other decisions that were made. So I was free in my mind to look at other things. The family's support is tremendous.

HH: Was there ever a phase when you thought you had hit rock bottom in politics?

AA: Every time I lost an election I felt that I'd hit rock bottom, but the struggle continued. Every day I would open a newspaper, my frustration would increase, but the recovery was fast as well. I needed to do something. My frustration is still there. Every time I read a newspaper, every day, the frustration is still there. There are so many things that have to be done, and even being the President of Pakistan I am unable to reach out everywhere and do it. Therefore, this government has been, and should be focusing on systems, rather than reactions to individual issues. Sometimes, I have seen and I have disliked the fact-for example, it appears in the media that a certain poor man or a poor child was seen on the streets and because the pictures made it to the newspapers, the Chief Minister of the province or the Prime Minister solved that issue. I believe that there should be an institutional response. Maybe, those who come in the newspapers are probably 0.001%, and much more people are there who need an institutional response. So I think that is where institutions are important.

HH: Being a very distinguished dentist and an educationist and now the President of Pakistan, what kind of plans should be expected with your insight about the system and its loopholes?

AA: I am very sorry to state that I find

my own professional field lacking in its organizational capabilities. I believe that they should be dragging themselves up and functioning better, because unless the organizations and associations of the profession think of improvement in the profession, nothing can happen. Dentistry as a profession is not purely related to knowledge and delivery, it is also related to an organizational aspect, where, for example, if you want to handle quackery or prevention, you have to look at these things in an organizational manner. That is what associations are for. Presently, I am disappointed in the organizational aspect of dentistry in Pakistan. Therefore, I feel limited in my ability to lift them up. It has to come from the profession, and only then I can help.

HH: So the professionals need to come in and suggest things?

AA: Of course, and not only suggest things you know, the organizational capabilities should increase. Dentistry as a profession has a different role than dentistry in education. Universities and colleges are there, they impart education. Dentistry as a profession can then look at the education standards. Maybe they can also suggest to PMDC on how to improve. Dentistry as an association can look at the aspect of continuing education, rather than all continuing education being in the realm of the industry. Dentistry associations can play a big part. As an association, the biggest part that dentistry can play is in prevention because, sure, the colleges can teach prevention, but at the level of society a professional goes out and says that this is how you brush your teeth, this is how you wash your hands, for example, to avoid

Continued on Page 13

SENSODYNE
RAPID ACTION



**BEAT
SENSITIVITY
PAIN
FAST**



**Clinically proven relief in just
60 SECONDS**



Fast, functional aesthetic solution for anterior tooth trauma

By Dr. Martin Weber

CEREC and oral surgery? In times when patients go to a practice to receive complete, aesthetic, state-of-the-art treatment as quickly as possible, I think they go together very well. I did not always think so. Certainly, CEREC was always interesting; I have used it since 2003, but I did not always find the results convincing. In 2014, I had a closer look at an event in Salzburg, Austria, and learnt two things: the system had been further developed, and in particular, the precision had been improved considerably. It fits well in my practice; I use it almost

CAD, Ivoclar Vivadent; and Celtra Duo, Dentsply Sirona) to treat my patients. The possibility of using implants in the premolar and molar region with screw-retained all-ceramic crowns is especially interesting. Sintering or crystallisation in the CEREC SpeedFire furnace is fast and fits smoothly into the workflow.

The advantage for my practice, where I also employ two other dentists, is obvious. We produce laboratory tasks right in the practice and have the entire workflow under control, and our patients are satisfied. They are still really impressed by the technology today. They are treated immediately,

posttraumatic resorption of the root, and the tooth could therefore not be preserved (Figs. 1 & 2). The tooth was to be replaced by an implant with an all-ceramic crown immediately after extraction. To plan the procedure, a 3-D radiograph (Orthophos XG 3D, Dentsply Sirona) was taken. It was important to assess the available horizontal and vertical bone and evaluate apical osteolytic processes after the failure of endodontic treatment and in the region of the crestal bone due to progressive dentinal resorption. The integrity of the vestibular lamina was preserved, and there was sufficient apical bone to allow immediate

When extracting tooth #21, it was important to preserve the vestibular lamina to allow immediate implantation. For this reason, the Sharpey's fibres were carefully severed with a periosteal elevator, and the tooth was gently removed (Fig. 7). The tooth had pronounced dentinal resorption, confirming the previously made diagnosis (Fig. 8). The SiroLaser Blue (Dentsply Sirona) with a wavelength of 970 nm was used to disinfect the alveolus. An OsseoSpeed EV 4.8–15 mm implant (Astra Tech Implant System, Dentsply Sirona) was inserted immediately using a surgical guide (SICAT OPTIGUIDE, SICAT; Fig. 9).

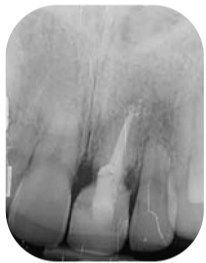


Fig. 1: Single-tooth exposure of tooth #21 after recurrent marginal gingivitis. Owing to the initial diagnosis of extensive resorption, the tooth could not be preserved.

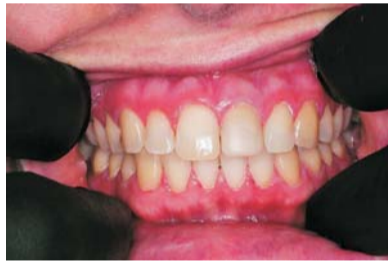

Fig. 2: Single-tooth exposure of tooth #21 after recurrent marginal gingivitis. Owing to the initial diagnosis of extensive resorption, the tooth could not be preserved.

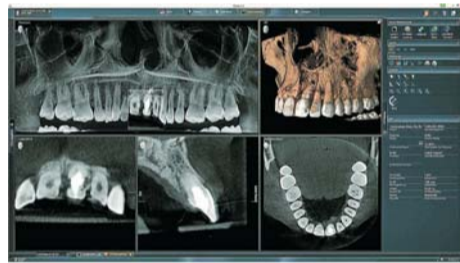

Fig. 3: The initial situation in 3-D in the Sidexis 4 imaging software (Dentsply Sirona) showed good apical bone substance with the possibility of immediate implantation.

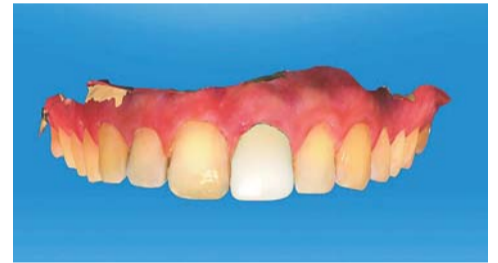

Fig. 4: Tooth #21 was deleted in CEREC to simulate the initial post-op situation.

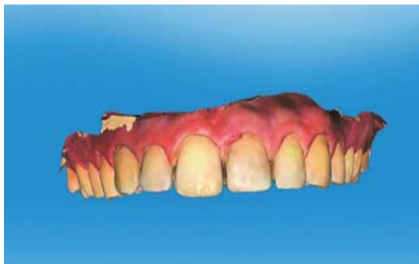

Fig. 5: The prosthetic proposal was also used as the basic file for producing the surgical guide with the gap at position #21.

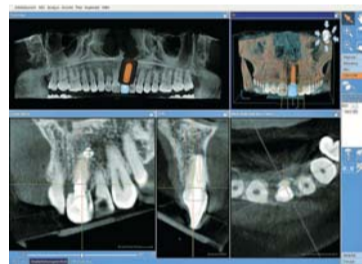

Fig. 6: The intraoral CEREC scan superimposed over 3-D image data for optimal positioning of the implant in the Galileos Implant planning software.

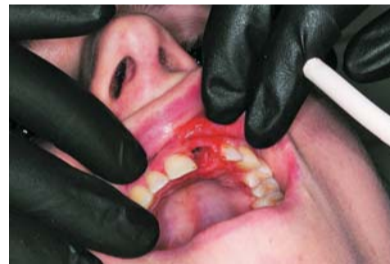

Fig. 7: Gentle extraction preserving the vestibular lamina.

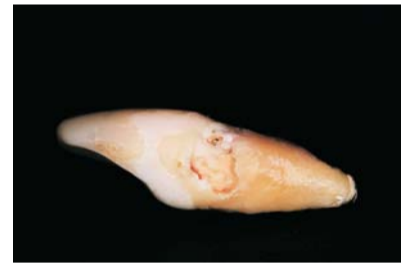

Fig. 8: The resorption of tooth #21, external view. This confirmed the accuracy of the diagnosis from the imaging procedure.

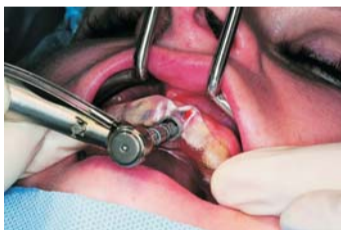

Fig. 9: Preparing the implant bed according to the recommended drill sequence, insertion of the implant using the SICAT surgical guide.

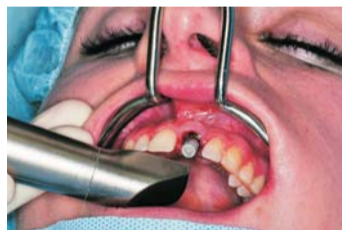

Fig. 10: Intra-op CEREC scanning with a ScanPost.

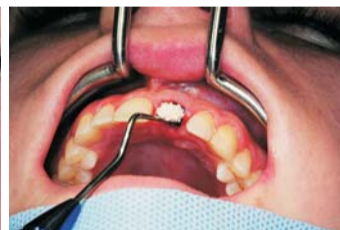

Fig. 11: Augmentation of the vestibular alveolus.



Fig. 12: The screw-retained crown as a finished polished temporary.

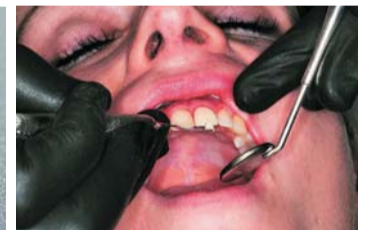

Fig. 13: Sealing the screw channel with composite.

every day because I have many patients who have busy jobs and do not have much time. I experience a great workflow in the practice that gives me maximum flexibility. Depending on the indication and the patient's wishes, I can decide whether to make the restoration myself or outsource it to a laboratory, which I often do for more elaborate bridges. Then, I send the scan directly to my partner laboratory via Sirona Connect—that is very reliable.

I mainly use conventional ceramic materials (VITA ENAMIC, VITA Zahnfabrik; CEREC Blocs C PC, Dentsply Sirona; IPS e-max and Telio

have no problems thanks to the precise fit, and feel like they are involved because they can watch us create the design and view the planning process live in CEREC. And yes, patients do talk about that with their friends and family. This case study shows how the digital processes, including implant planning, with CEREC work. Treatment of an anterior tooth trauma with an immediate implant

The female patient, born in 1989, came to my practice with problems at tooth #21 caused by a childhood trauma. The gingival margins were reddened and bled when probed. The intraoral radiograph showed

implantation with immediate loading (Fig. 3).

After scanning the upper jaw, tooth #21 was deleted in CEREC to simulate the initial postoperative situation. The prosthetic proposal for tooth #21 was used to optimise implant planning and to produce the surgical guide (Figs. 4 & 5). In the implant planning software (Galileos Implant, Dentsply Sirona), the prosthetic proposal was superimposed over the CBCT data for the optimal positioning of the implant. In this way, sufficient vestibular distance was ensured, and the correct size of the implant for optimal primary stability could be selected (Fig. 6).

At > 35 Ncm, sufficient primary stability was achieved.

After the intraoperative scan with a ScanPost (Dentsply Sirona) to complete the temporary restoration, the vestibular alveolus was filled with a bone substitute material (Figs. 10 & 11).

Designing the temporary screw-retained crown included processing the composite crown (Telio CAD) produced with CEREC and extraorally attaching the TiBase (Telio CAD, Ivoclar Vivadent on Dentsply Sirona TiBase). The crown was screwed in situ, and the screw channel was sealed

Continued on Page 10



HELP KEEP YOUR PATIENTS ON A JOURNEY TO HEALTHY GUMS

PARODONTAX® TOOTHPASTE IS CLINICALLY PROVEN TO REDUCE PLAQUE, BLEEDING GUMS AND INFLAMMATION

4X

greater plaque removal*¹

48%

greater reduction in bleeding gums*¹

Recommend parodontax® toothpaste to help patients maintain their optimal gum health between dental visits.

DAILY FLUORIDE TOOTHPASTE FOR HEALTHY GUMS & STRONG TEETH

parodontax®

EXTRA FRESH



Helps stop and prevent bleeding gums

GlaxoSmithKline Consumer Healthcare Pakistan Ltd.
35-Dockyard Road, West Wharf, Karachi - 74000

GSK is committed to the effective collection and management of human safety information relating to our products and we encourage healthcare professionals to report adverse events to us on +92 (21) 111-475-725 or pk_pharmasafety@gsk.com

* Compared to a regular toothpaste and professional clean and 24 weeks' twice-daily brushing.

Immediate implantation with CAD/CAM and functional restoration in the aesthetic zone

By Dr. Martin Weber

The aesthetics are always a significant challenge during implant restoration, especially in the aesthetic zone, in addition to the full consideration required regarding function. In this article, we present a case of multiple tooth fractures due to trauma. After tooth extraction, immediate implantation and guided bone regeneration (GBR) were performed. During the prosthetic procedure, the design and transfer of the emergence profile of the soft tissue, functional design and occlusal adjustment, as well as the CAD/CAM process, were satisfactorily realised to achieve the aesthetic and functional goals.

Case report

Dental history

A 40-year-old female patient had sustained trauma to her anterior teeth caused by accidental syncope three weeks before. The clinical examination found that tooth #11 had been luxated; the crowns of teeth #12 and 21 had fractured, with the residual margin extending 3–5 mm below the gingiva and the teeth affected by Grade III mobility; and the crown of tooth #22 had fractured, with the residual margin at gingival level. There were no obvious abnormalities in the remaining teeth (Figs. 1–4). After excluding major systemic diseases, it was decided that she required fixed implant restoration with high demands regarding aesthetics and function.

Treatment procedure

Teeth #12, 21 and 22 were extracted. Tooth #11 underwent early implantation and tooth #22 immediate implantation with GBR (Figs. 5 & 6). After three months of healing, osseointegration had taken place. An implant level impression was taken for fabricating a provisional bridge supported by temporary abutments for teeth #12–22. The technician modified the shape of the artificial gingiva on the model in order to form the proper gingival curve and emergence profile, then finished the provisional bridge, while the dentist modified the gingival shape using an olive-shaped bur intraorally (Figs. 7–18).

The aesthetic and functional outcomes of the provisional restoration were checked. The tip of tooth #13 was too low to achieve a good smile line. When checking the intercuspal position (ICP) and lateral excursion using 80 μ m occluding paper, tooth #13 was found to be out of contact. After reshaping the labial contour and filling the lingual surface with resin, tooth #13 had good contact and guidance during ICP and lateral excursion (Figs. 19–23).

Once the aesthetic and functional outcomes had been confirmed, the anterior guidance of the provisional restoration was recorded on an articulator (Artex, Amann Girrbach) and its individual incisal guide table

(Figs. 24–27). Next, the emergence profile of the provisional restoration was transferred and the cast model was made and mounted on the articulator (Figs. 28–33).

The cast model was scanned step by step to obtain a digital model and this was integrated with a virtual articulator. The anterior guidance of the virtual articulator was set according to the data from the provisional restoration. Next, the design was completed on computer and the titanium-based zirconia abutment and fixed zirconia bridge produced via CAM. After staining and glazing, the final restoration was completed (Figs. 34–41). The final restoration demonstrated a good outcome, both aesthetically and functionally (Figs. 42–50).

Discussion

This patient came to the clinic just after the trauma, and according to the intraoral condition, immediate implantation could have been carried out. However, owing to the unexplained accidental syncope, diseases of the central neural system were to be excluded first, so delayed dental treatment was suggested.

Three weeks later, after a general physical check-up, implantation was begun. Usually, operation within 48 hours after tooth extraction is considered as immediate implantation, while operation within the first six weeks after tooth extraction is

considered as early implantation. Therefore, in this case, implant #11 was early implantation and implant #22 immediate implantation. The preoperative CT analysis showed that the labial side of the alveolar ridge of teeth #12, 11 and 22 was deficient; thus, GBR was needed in order to obtain sufficient bone quantity.

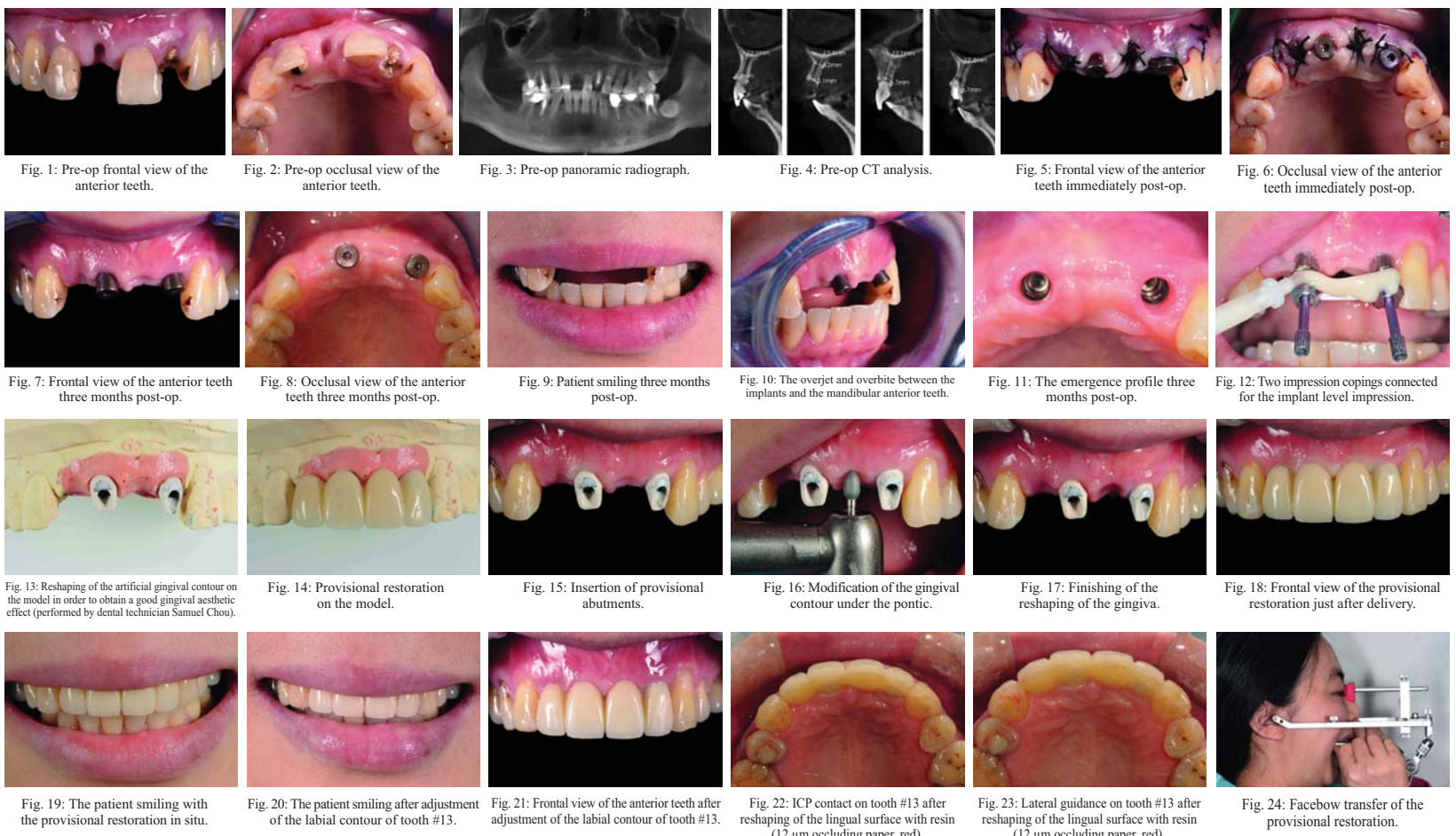
After three months of healing, both hard and soft tissue around the implants had been well maintained, providing a sufficient foundation for the maxillary restoration. In order to form a good gingival shape, either the provisional restoration can be adjusted step by step or the shape of the soft tissue can be designed first, the provisional restoration manufactured to meet the aesthetic demand directly, then the soft tissue intraorally adjusted and reshaped.

In this case, we followed the second option. After using an olive-shaped bur to adjust the form of the gingiva under the pontic, making it match the provisional restoration, which had already been well designed and manufactured, a perfect soft-tissue outcome was achieved.

By means of regular methods to transfer the emergence profile, it was copied to the final restoration, which is the foundation for the good soft-tissue effect of the final prosthesis.

It was also very important to obtain the proper anterior guidance during

Continued on Page 14



Nanodiamonds might aid recovery from root canal treatment

LOS ANGELES, U.S. - California-based researchers have recently been working on a tiny, but powerful ally that could help prevent infection after root canal treatment. In a clinical trial it was found that nanodiamonds protected disinfected root canals after the nerve and pulp were removed, thereby improving the likelihood of a full recovery. The findings are considered a milestone for the use of nanodiamonds in humans.

Nanodiamonds are particles made of carbon and are so small that millions of them could fit on the head of a pin. The particles resemble soccer balls, but have faceted

surfaces-similar to actual diamonds-that enable the particles to deliver a wide range of drugs and imaging agents.

"Harnessing the unique properties of nanodiamonds in the clinic may help scientists, doctors and dentists overcome key challenges that confront several areas of health care, including improving lesion healing in oral health," said Dr. Dean Ho, professor of oral biology at the UCLA School of Dentistry and co-corresponding author of the study.

The researchers tested nanodiamond-embedded gutta percha (NDGP) in three patients who were undergoing root canal procedures. Tests



In a clinical trial, a UCLA-led team used biomaterials embedded with nanodiamonds—tiny gems to help tissue heal. (Image: designleo/Shutterstock)

of the implanted material confirmed that the NDGP was more resistant to buckling and breaking than conventional gutta percha. All three patients healed properly, without any unusual pain and without infection.

"This trial confirms the

immense promise of using nanodiamonds to overcome barriers for a range of procedures, from particularly challenging endodontics cases to orthopedics, tissue engineering, and others," said Prof. Mo Kang, co-author and endodontics professor at

UCLA.

The study, titled "Clinical validation of a nanodiamond-embedded thermoplastic biomaterial," was published in Proceedings of the National Academy of Sciences on Oct. 23, 2018 ahead of print. - *Dental Tribune International*

ADA releases statement regarding research on opioid prescriptions

NEW YORK, U.S. - Recent papers on opioids and their use within the dental industry have drawn increased attention. In response to research related to opioid prescriptions for some dental procedures, the American Dental Association (ADA) has recently released a statement clarifying their position on the broader issue.

In the statement, the ADA said: "In order to combat opioid abuse among adolescents, and across all ages, the ADA has urged all 161,000 member dentists to double down on their efforts to prevent opioids from harming patients and their families."

According to the ADA, the growing body of research supports their policy that dentists should prescribe non-steroidal anti-inflammatory drugs (NSAIDs) alone or in combination with acetaminophen over opioids as first-line therapy. Stating that the ADA is "dedicated to raising awareness and taking action on the opioid public health crisis."

In March 2018, the ADA adopted a policy related to opioid prescription by dentists for acute pain. The policy supports mandatory continuing



Instead of prescribing opioids, the American Dental Association believes that dentists should consider non-steroidal anti-inflammatory drugs as the first-line of therapy for acute pain management. (Photograph: KieferPix/Shutterstock)

education regarding the prescription of opioids and other controlled substances, imposes statutory limits on opioid dosage and a duration of no more than seven days for the treatment of acute pain. The guidelines are consistent with the Centers for Disease Control and Prevention's evidence-based guidelines and requires dentists to register with and use Prescription Drug Monitoring Programs to promote the appropriate use of opioids to deter misuse and abuse.

In further support of the ADA's position, in April researchers from the ADA Science Institute, Case Western Reserve University and the

University of Pittsburgh published a scientific review of studies in the Journal of the American Dental Association. The study concluded that NSAIDs alone or in combination with acetaminophen are generally more effective and are associated with fewer side effects than opioids.

"Working together with physicians, pharmacies, policymakers and the public, the ADA believes it is possible to end this tragic and preventable public health crisis that has been devastating our families and communities," the statement concluded. - *Dental Tribune International*.

German report shows the frequency of dental check-ups has increased

BERLIN, GERMANY - In a new study, researchers from the Robert Koch Institut (RKI) have examined, among other subjects, the prevalence, determinants and trends of tooth brushing frequency and utilisation of dental check-ups in children and adolescents in Germany. The reports are based on



In a recent study, researchers in Germany have found, since a previous 2003-2006 report, the frequency of dental check-ups has increased. (Photograph: Pressmaster/Shutterstock)

the data collected from the second wave of the German Health Interview and Examination Survey for Children and Adolescents (KiGGS Wave 2, 2014-2017).

According to the study, around 80 per cent of children and adolescents meet the recommended tooth brushing frequency and dental check-ups. However, around one-fifth of children and adolescents do not, with 14- to 17-year-old adolescents, as well as those with low socio-economic status and or migrant backgrounds being particularly at risk.

Additionally, the results also showed that the utilisation of dental check-ups has increased compared to the

Continued on Page 14