


today

11
12
13

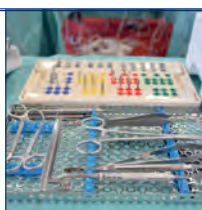
EAO 27th Annual Scientific Meeting Vienna • 11-13 October 2018



Survey

In short interviews, EAO attendees explain why they are enjoying the congress and its programme.

» page 3



Congress news

Implant sessions offer the opportunity to follow each step, from treatment planning to live surgery and follow-up.

» page 4



Travel

Vienna offers much to do. Find out about the best events, food and more in the Austrian capital.

» page 18

“The first experience of implant placement is unforgettable for every clinician”

■ As a member of the EAO Junior Committee since 2013, Dr Ferruccio Torsello was one of the tutors in yesterday's hands-on workshop, “My first implant: GBR”. He completed a master's programme in periodontics and implant dentistry at the Eastman dental hospital in Rome in Italy, where he is still involved in research activities. In this interview, the widely published implantologist told Dental Tribune International about the hands-on course, as well as the responsibilities of the EAO Junior Committee and its vision for the future of implant dentistry.

Dr Torsello, yesterday the EAO Junior Committee held an introductory workshop on implantology. During the workshop, which theoretical aspects were discussed with the participants?

The first part was dedicated to a theoretical overview of osseointegration, of implant surfaces, designs and connections, and of the most critical surgical and prosthetic factors that influence the treatment outcome. You can imagine that the extent of information was huge compared with the limited time of the session! The speakers gave an overview of the basic concepts with the aim of inspiring and stimulating the participants to further study this field of dentistry.

Which hands-on exercises were practised with the attendees?

The hands-on workshop allowed the 35 participants to place one or more implants in porcine jaws. Various companies had provided implants and the EAO had provided sur-



▲ Dr Ferruccio Torsello assists an attendee of the workshop.

gical materials. Via the tell-show-do approach, two tutors for each implant system explained the surgical steps and demonstrated the correct implant placement. Afterwards, the attendees were able to place implants in the porcine jaws themselves, giving each participant the opportunity to practise with at least two different implant systems.

Who was the target audience of the workshop?

Our target group consisted of young clinicians or clinicians who up until now had dedicated their time to other dental fields and wanted to have their first contact with implant dentistry. This workshop allowed them to place their first implants under the supervision of experienced clinicians. The first experience of implant placement is unforgettable for every clinician. As the EAO Junior Committee, we wanted to give young clinicians this opportunity in the EAO

environment, and we aimed to leave them with a positive memory of their first experience and of our association.

As material for the workshop you used porcine jaws. Why?

Porcine jaws are useful and widely used in hands-on exercises mainly because they are quite easily obtainable and managed and they present naturally edentulous areas where implants can be placed. Drill-

ing into porcine jawbone allows the experience of natural bone consistency, which resembles that of human bone, and this makes the whole experience much more realistic than with plastic models.

Aside from activities like presenting hands-on workshops, what are the main responsibilities of the EAO Junior Committee?

The aim of the EAO Junior Committee is to assist and support the EAO board in achieving its mission. Our tasks are to suggest and develop new ideas, to lead projects suggested by the EAO board and encourage enthusiastic participation by young researchers in the EAO.

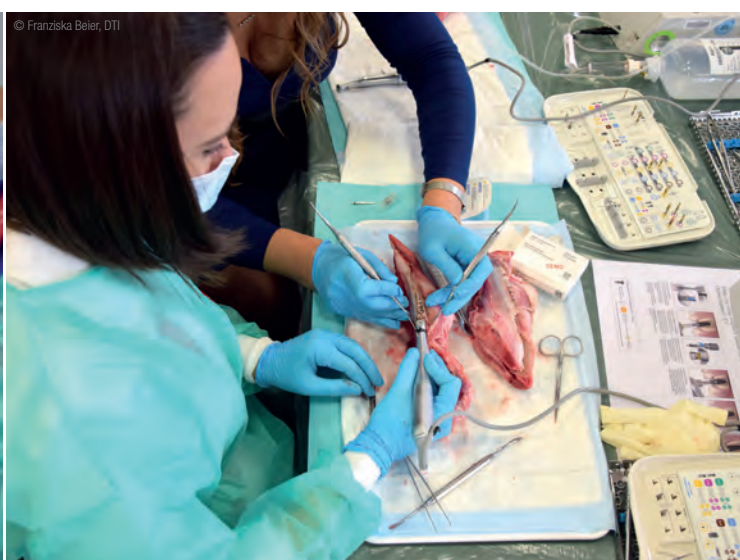We are working with national dental associations to implement EAO projects at national level. For example, we will be contributing to the next congress of the Italian Academy of Prosthetic Dentistry (AIOP) with a joint session of the EAO and AIOP, which will take place in November.

One of our major projects for 2019 is the summer camp for young clinicians, which will take place in Lisbon in Portugal. It will be a fantastic opportunity for young dentists to receive top-level training in a friendly atmosphere.

You have contributed to a recent research paper titled “Guidelines for development of implant dentistry in the next 10 years regarding innovation, education, certification, and associations”. Would you please list some of the main conclusions and guidelines established?

The manuscript you mentioned arose from the previous EAO Junior Committee summer camp. The participants, who came from several European countries and the US, analysed the situation related to innovation, education, certification and associations in implant dentistry. The outcome was presented in the manuscript, which highlighted a number of aspects in each area that need improvement. For example, the conclusions call for the accreditation of structured training programmes in order to have an improved and standardised level of care in implant dentistry.

Thank you very much for the interview. ◀



Nobel Biocare further extends its product portfolio at EAO

■ At its press conference on Thursday morning, Switzerland-based company Nobel Biocare announced the next step in its digital workflow with a new option for same-day guided surgery made possible by DTX Studio Implant and the X-Guide dental navigation system. In addition, the company is introducing creos mucogain, a resorbable collagen matrix for soft-tissue regeneration, as well as the NobelPro Line, in order to highlight the possibilities of Nobel Biocare's comprehensive range of edentulous treatment solutions.

With X-Guide, being demonstrated at the fully equipped Nobel Biocare lounge by Dr Pascal Kunz, clinicians have a new treatment option for same-day surgery. DTX Studio Implant empowers this innovative system for dynamic 3-D navigation. With the software officially being launched for European markets at the EAO congress, treatment plans from DTX Studio Implant (formerly NobelClinician) can now be instantly delivered to the patient, providing a workflow for diagnostics, implant planning and dynamically navigated implant surgeries, even during emergency interventions where computer-assisted surgeries until now could not be fully applied.

Using DTX Studio Implant and X-Guide, clinicians can achieve high precision, shorter time-to-teeth treatments, including screw-retained provisionalisation with full 3-D control of their implant site preparation and dynamically monitored implant insertion. The procedure only takes minutes from the CBCT scanning to the start of the surgery. Similar to a GPS in a car, X-Guide provides stable, lag-free, real-time 3-D intraoral guidance of the drill and implant position in relation to patient anatomy. X-Guide is manufactured by X-Nav Technologies, a North America-based innovator in dental 3-D navigation who has exclusively partnered with Nobel Biocare.

Extending Nobel Biocare's range of solutions for guided bone and tissue



▲ Hans Geiselhöringer, President of Nobel Biocare, welcomed media and industry partners to the company's press conference on 11 October 2018.

regeneration, the new creos mucogain resorbable collagen matrix is intended to be used as an alternative for autologous soft-tissue grafts in various soft-tissue indications, such as soft-tissue volume augmentation and root coverage in submerged healing. Composed of highly purified porcine collagen and elastin fibres, it has an open interconnecting porous structure designed to promote soft-tissue regeneration through the migration of cells and blood vessels into the matrix.^{1,2}

The matrix offers high stress resistance and suture retention² that is sufficient for the tunnelling technique.³ Owing to a memory effect, it retains its initial volume when hydrated.² creos mucogain is available in different sizes (15×20 mm and 25×30 mm) and thicknesses (3 mm and 5 mm). According to Nobel Biocare, it offers excellent handling, as it can be used directly out of the packaging and trimmed to precisely fit the surgical site.³

Highlighting its range of edentulous treatment solutions, Nobel Biocare is further announcing the NobelPro Line to showcase the benefits of immediate function, along with the latest advancements in minimally invasive care. With an assortment of clinically successful and proven treatment options, including NobelSpeedy and NobelZygoma, clinicians can take the All-on-4 treatment concept to new heights and treat even the most challenging max-

illary cases with moderate up to severe resorption.

At the press conference, President of Nobel Biocare Hans Geiselhöringer said, "Nobel Biocare has once again shown that it is a leading force in bringing cutting-edge technology and solutions to clinicians worldwide. With the addition of dynamic navigation to its digital workflow, Nobel Biocare looks forward to helping more clinicians leverage the latest in implant treatment technology. Together with forward-looking regenerative solutions like creos mucogain, as well as the NobelPro Line, they now have better treatment options available to lead more patients to immediate function and excellent aesthetics."

Clinical insights on X-Guide, creos mucogain and the NobelPro Line will be given during clinical lectures and hands-on courses presented by Nobel Biocare in Vienna. More information is available at Booth D-02 and online at <http://www.nobelbiocare.com/eao>. ◀

References

¹ Boekema BK, Vlig M, Olde Damink L, Middelkoop E, Eummelen L, Bühren AV, Ulrich MM. Effect of pore size and cross-linking of a novel collagen-elastin dermal substitute on wound healing. *J Mater Sci Mater Med.* 2014 Feb;25(2):423-33.

² Olde Damink L, Heschel I, Leemhuis H, Tortorici M, Wessing B. Soft tissue volume augmentation in the oral cavity with a collagen-based 3D matrix with orientated open pore structure. *CDBME.* 2018 Sep;4(1):237-41.

³ Wessing B, Vasilic N. Soft tissue augmentation with a new regenerative collagen 3-D matrix with oriented open pores as a potential alternative to autologous connective tissue grafts. *Clin Oral Implants Res.* 2014;25(10 Suppl):342. Available from: www.dentalcongressposters.com/eao2014/wessing.pdf



▲ Tinne Van Delm (left), Head Global Product Management Software at Nobel Biocare, and Dr Kunz showcased the multiple software solutions that the company offers in its extensive portfolio.



▲ Together with Dr Kunz (left), X-Nav Co-Founder, President and CEO Ed Marandola demonstrated the X-Guide.

Dreams in implant dentistry turn into reality at EAO 2018

■ EAO President Dr Alberto Sicilia Felechosa took the stage at the opening ceremony of the 27th Annual Scientific Meeting of the EAO and welcomed the attendees, many of whom have travelled from far to Vienna to attend the congress. "We worked very hard to make this happen and are more than happy to see you here," he said in officially announcing the start of the congress.

Following this, the induction of Prof. Christoph Hämmerle as an EAO honorary member took place. The honorary membership is the highest award that the EAO can bestow on individuals who have contributed greatly both to the science of implant dentistry and to the association. Only five individuals have received this recognition. Felechosa said that he was "delighted to present this award" to Hämmerle in acknowledgement of his outstanding efforts. "The EAO is close to my heart. I have great memories with great people," Hämmerle



▲ Dr Felechosa officially opened the 27th EAO congress.

said as he accepted his award to a standing ovation.

Afterwards, the moderator of the main scientific programme, Steward

Freeman, was introduced to the audience. He then gave an overview of

the programme and highlights for the next three days.

A "time machine video", as Freeman called it, introduced the EAO congress scientific committee, who took the viewers through the culturally rich and eventful history of Vienna. Chairman Prof. Ronald Jung and Co-Chairmen Prof. Georg Mailath-Pokorny, and Dr Michael Payer then entered the stage for their addresses. In conveying their experience of compiling the programme, Jung said, "The three of us started with one dream: making the most successful and most amazing congress happen."

Mailath-Pokorny and Payer ended the ceremony with short speeches, before continuing with the opening session for the live treatment sessions. These will stretch over the course of the next three days and include live surgeries and follow-up care as a major highlight of the EAO 2018 scientific programme. ◀

Survey: “What made you come to the EAO congress this year?”

Nearly 4,000 dental professionals have found their way to this year's EAO congress. In conversation with Dental Tribune International, conference-goers explained what attracted them to the event.

Urte Marija Sakalauskaite, Lithuania



“I heard about the EAO from my colleagues who attended the event in Madrid last year. They told me the congress offers great lectures and informs about trending topics. It is my first time here and I came to gain more knowledge in implantology because I am currently in my final year

at the Lithuanian University of Health Sciences. Therefore, I attended the hands-on workshop “My first implant: GBR”, which was actually a birthday present from my family. I liked that we were informed about the theoretical aspects and could apply our newly gained knowledge directly afterwards. Previously, I had placed an implant in a plastic model, but owing to the porcine jaws, this experience was much more helpful and informative.”

Dr Harshit Jain, India



“I studied in the US and now I have a dental surgery and implant practice in India. This is my first time at the EAO and I would like to come back with colleagues in the future. Vienna is a very special and beautiful city and I am here in order to learn about implantology from the European perspective. I went to the opening ceremony and I look forward to attending most of the other sessions. Since I am currently studying prosthetics, I am focusing on this field during the congress.”

“This is not my first time at the EAO. I think I started to attend four years ago. I am a maxillofacial surgeon with my own practice in Bucharest. The EAO offers participants the opportunity to stay in touch with the latest news in implantology, to get in contact with colleagues, and to learn about new trends and products. I will definitely continue to visit the EAO because it has become a kind of tradition.”

Dr Raluca Rosca, Romania



“This is not my first time at the EAO. I think I started to attend four years ago. I am a maxillofacial surgeon with my own practice in Bucharest. The EAO offers participants the opportunity to stay in touch with the latest news in implantology, to get in contact with colleagues, and to learn about new trends and products. I will definitely continue to visit the EAO because it has become a kind of tradition.”

“Since this year, I have been an EAO member and this is my first EAO congress. Before, I had been a member of the Academy of Osseointegration for 15 years. I am a general dentist and have my own practice in North Carolina. This is actually my first congress outside of the US and I thought Vienna is

Dr Daniel Turnbull, US



“Since this year, I have been an EAO member and this is my first EAO congress. Before, I had been a member of the Academy of Osseointegration for 15 years. I am a general dentist and have my own practice in North Carolina. This is actually my first congress outside of the US and I thought Vienna is

a very nice city, so did my wife [laughed]. She agreed to accompany me to Austria. I will probably come back next year when the EAO takes place in Lisbon. So far, I am very impressed with the programme and all lectures have been very good.”

prosthetic.line

Abutments4life

Aesthetics simplified and predictable.
Implantology has never been easier.

EAO booth B43



Live treatment sessions offer practical insight into implant placement

■ The EAO scientific meeting offers an extensive programme of lectures, industry symposia, poster sessions and workshops. This year, for the first time, the event has introduced live surgery sessions broadcast to an audience in the main auditorium. The implant sessions offer dental professionals the opportunity to follow each step first-hand, from discussing treatment planning to observing live surgeries and finally viewing the results in follow-up presentations of the patients.

The first congress day started with an introduction of the three dental teams, who presented their patients and the planned treatment.

The first team comes from the Vienna dental school, which is the largest in Austria with its 800 students and 100 dentists. The surgical team presented their patient, a 64-year-old man, a non-smoker with Type 2 diabetes who has suffered from mandibular and maxillary edentulism for 12 years. The patient now wishes to receive fixed restoration supported by implants.

Second up was the academy of oral implantology of Vienna, who presented two patients. Christina will be undergoing guided immediate implant placement to replace her maxillary incisors and immediate provisional restoration necessitated by a dental trauma caused by a bicycle accident, in order to stabilise her teeth. "I didn't wish to get an implant at first, but my doctor advised me to do so," she explained.

The academy has a private clinic with 800 dentists who focus on im-



plant treatment and provide 20,000 consultations per year. This is also where the second patient, Michael, will be operated on. According to him, the team explained the upcoming procedure in detail to him, which resolved his fear. "It is a great team and I am sure it will work out fine," he continued.

Finally, the Graz dental school, which treats about 25,000 patients each year, presented their patient, Hannah, who suffered a dental trauma in 2010 while playing sport. She will be undergoing a guided delayed single-tooth

implant placement in the aesthetic zone. "My teeth were always an issue; meeting boys and falling in love was never easy. It is time to get an implant now," she said in expressing her excitement about how a new tooth will bring great changes.

Via the interactive feature of the congress app, conference-goers were able to directly participate in the session by posing questions and these were then answered during the session by the dental teams.

On the second day of the congress, the surgical treatment day, the live surgeries will be broadcast from 11.00 to 12.30 in the Wien room. The patients treated during these sessions will be presented one day after their surgeries, on the last day of the congress, with their new restorations. Each session will include a surgical follow-up and live interviews with the patients. ◀



Straumann launches string of new products

■ At this year's EAO congress, Straumann has announced the launch of several new products, including a new two-piece ceramic implant and a mini-implant system. The company has also presented initial results from the preclinical and clinical programme that is underway on its innovative fully tapered implant BLX.

The Straumann PURE Ceramic Implant range is designed for highly aesthetic tooth replacement. Made from a high-performance ceramic with the colour and translucency of natural tooth roots, the implants have a ZLA surface to provide highly predictable osseointegration.

To complement the existing PURE monotype design, Straumann is launching a two-piece solution that adds prosthetic flexibility, considerably facilitates handling and is suitable for guided implant placement.

The PURE range is included in Straumann's Lifetime Plus Guarantee programme and will be released in a limited number of markets initially. The full market release is expected to follow in the course of next year.

Straumann has developed a premium mini-implant that is just 2.4mm in diameter. Like the company's BLT implant, it has a tapered design to achieve the high primary stability needed for immediate replacement protocols. In addition, the

implant has a specially designed thread, which reduces the drilling protocol. The Mini Implant is made of Roxolid and has an SLA surface to enhance reliable osseointegration. It also features a Optiloc connection, which uses a combination of amorphous diamond-like carbon coating

and PEEK inserts to achieve low friction between the implant and the matrix, resulting in favourable wear resistance, long-term performance and low maintenance.

Straumann estimates that as many as one in ten implant procedures globally are for full-arch

reconstructions. Very small-diameter monotype dental implants offer a cost-effective, immediate and minimally invasive solution for edentulous patients with reduced horizontal bone. More than a million mini-implants were placed in 2017 and their popularity is growing rapidly, as their

use can avoid bone grafting procedures, which would otherwise be necessary to support wider implants.

In order to address the fully tapered implant segment, which is growing the fastest and now accounts for one in every four implants placed, Straumann has been collaborating with the world's leading experts in the field in developing its advanced BLX fully tapered implant system.

According to the company, this next-generation system, which also features Straumann's proven Roxolid and SLActive technologies, was designed to optimise primary stability in all bone classes, to simplify restorative workflows and to achieve predictable outcomes—even in complex cases.

Yesterday, during Straumann's corporate forum at EAO, prominent experts presented the latest preclinical and clinical evidence on the new implant, including data on its osseointegration and bone maintenance properties and the implant's broad spectrum of indications.

In addition, Straumann hosted two workshops with distinguished experts to provide dentists with hands-on experience with the BLX and to promote new techniques. Both workshops were quickly booked out.

For more information, EAO attendees are invited to visit the Straumann booth D-04. ◀



*Among other products, Straumann is exhibiting models of its premium mini-implant.



KNOWLEDGE



CHANGES




EVERYTHING



Nobel Biocare Global Symposium

June 27–29, 2019, Las Vegas, USA



A bold, new and exciting event is coming. It is fueled by the power of knowledge and the positive impact it can have on your daily practice and your patients – through new solutions that will change the course of innovation forever.

Join us for three future-focused days in Las Vegas, featuring expert speakers, master classes, hands-on training, innovative new solutions and the chance to connect with the best minds from around the world.

nobelbiocare.com/global-symposium-2019

GMT 57627 © Nobel Biocare Services AG, 2018. All rights reserved. Distributed by: Nobel Biocare. Nobel Biocare, the Nobel Biocare logotype and all other trademarks are, if nothing else is stated or is evident from the context in a certain case, trademarks of Nobel Biocare. Please refer to nobelbiocare.com/trademarks for more information. Product images are not necessarily to scale. Disclaimer: Some products may not be regulatory cleared/released for sale in all markets. Please contact the local Nobel Biocare sales office for current product assortment and availability. For prescription use only. Caution: Federal (United States) law restricts this device to sale by or on the order of a licensed dentist. See Instructions For Use for full prescribing information, including indications, contraindications, warnings and precautions.



Minimally invasive implant dentistry with short or narrow implants

Ridge splitting and crestal and internal sinus lift

Prof. Mauro Marincola¹, Dr Daniel Hernández-González¹, Dr Jaime Guzmán-De Ávila¹ & Dr Miguel Simancas-Pallares¹, Colombia

¹ Dental Implant Unit, Faculty of Dentistry, University of Cartagena, Colombia

Introduction

Dental implants have been advocated as the treatment of choice for missing teeth and tooth replacements. Scientific evidence demonstrates their high success rates and therefore their clinical applicability. However, in some circumstances due to premature posterior tooth loss leading to severe sinus pneumatization or a congenitally missed tooth causing alveolar bone collapse, implant placement can still remain challenging for clinicians. These circumstances could be present in one surgical target area at the same time, thus increasing treatment complexity. In such cases, available options such as short implants, ridge splitting, and internal and crestal sinus lifts have been proposed to minimise treatment cost and time, as well as co-morbidities but preserve treatment success rates.

In order to address clinical-related sinus pneumatization issues, two main surgical approaches have been suggested: internal and lateral sinus lift techniques. The internal sinus lift approach is indicated whenever the residual bone height (RBH) is 4 to 7 mm. First proposed by Summers, it entails performing a cortical greenstick fracture using osteotomes, allowing the Schneiderian membrane to be easily lifted.¹ This technique has the advantage of allowing immediate implant insertion. The lateral sinus lift approach is suggested when the RBH is less than 4 mm. With this skill-dependent technique, a bony lateral window has to be created, exposing the cortical bone. Once this has been achieved, membrane detachment with the use of currettes is performed, and an alloplastic material is injected as a bone graft. After a graft healing period of five to six months, the implants can be inserted. In order to address alveolar collapse issues, ridge splitting was proposed as a surgical approach, wherein the cortical plates are separated to allow the insertion of implants into the artificially created space.

All these options are of high clinical value when facing such scenarios. However, implant length is considered one of the most important predictors in treatment efficacy when performing these techniques. Likewise, short implants have been proposed, since they have marked clinical advantages, such as minimising the amount of sinus membrane to be lifted and grafting material to be injected, thus introducing the concept of minimally invasive implant dentistry. Short implants are widely discussed because of their increased use in recent years. Historically, long implants (>13 mm) in combination with sinus lift procedures were recommended to restore function and aesthetics. Nowadays, improvement on implant design and scientific evidence have shown high success/sur-

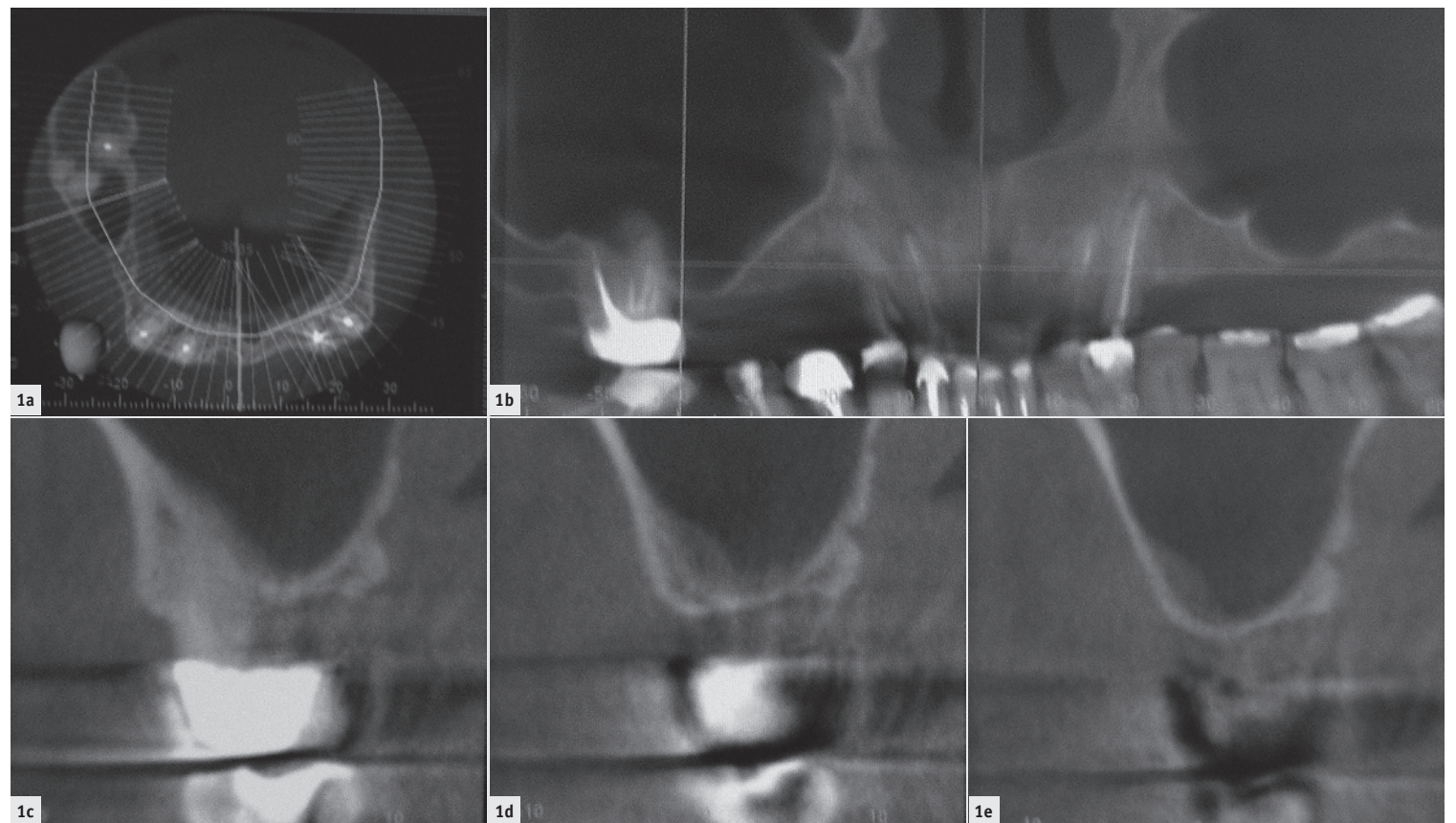


Fig. 1a-e: CT scan analysis of the targeted surgical area: **a)** Coronal view of the maxilla showing the limited width and **b)** panoramic view of the maxilla depicting the reduced vertical bone height in the right quadrant. **c-e)** Sagittal views of the molar area with the diminished residual bone height as little as 1 mm.

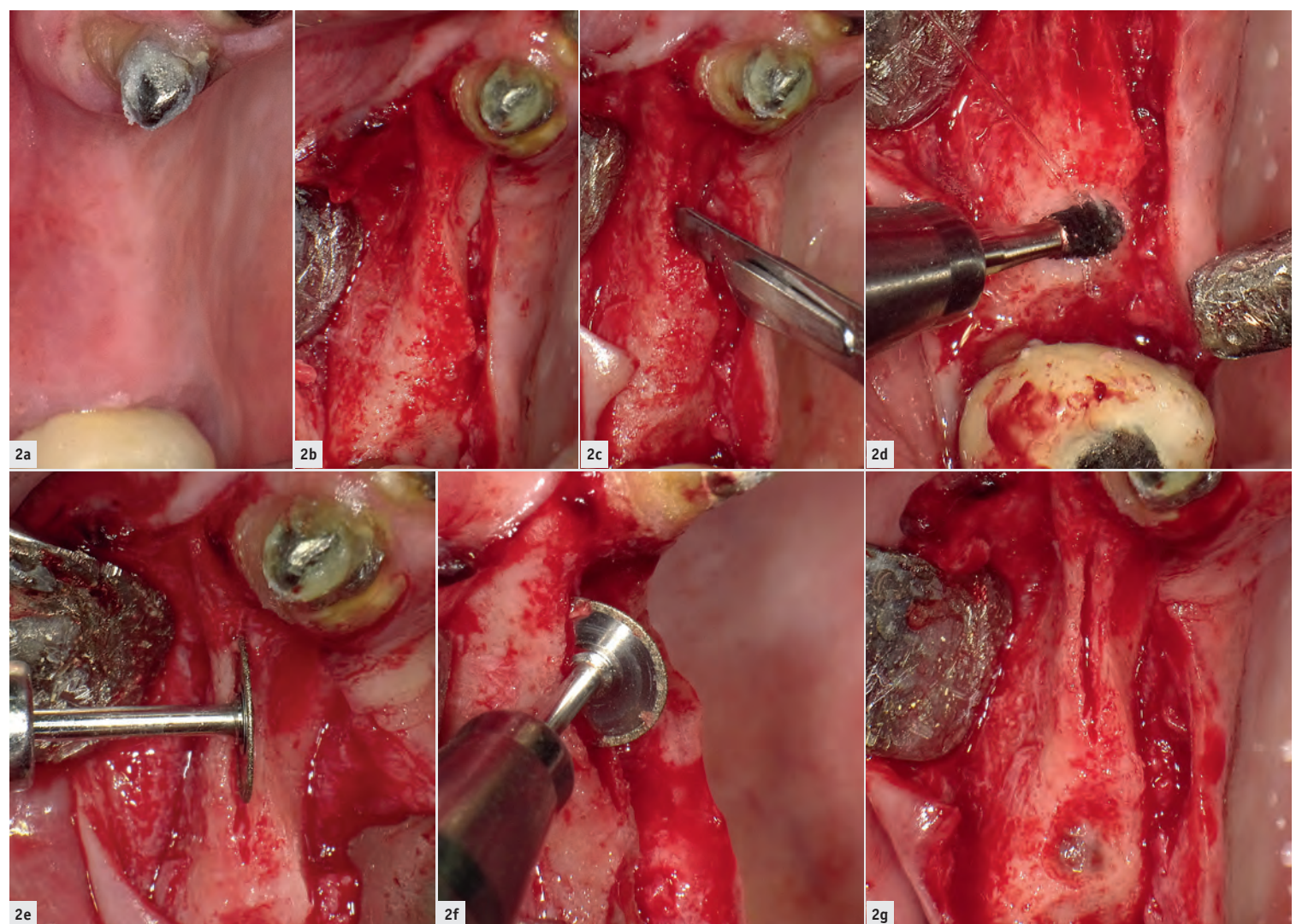


Fig. 2a: Pre-op view of the targeted surgical area. **Fig. 2b:** Targeted surgical area once the full-thickness flap was obtained. **Fig. 2c:** Cortical perforations to generate initial split. **Fig. 2d:** Crestal perforation in order to expose the sinus cortical bone and perform a sinus lift. **Figs. 2e & f:** Cortical deepening by use of a diamond-covered disc under continuous irrigation. **Fig. 2g:** Surgical view of the split area in the premolar zone and the crestal perforation in the molar area.

vival rates of short implants, thus indicating them to be among the most valuable approaches in modern dentistry.

Having all these concepts in mind, the objective of this case report was to demonstrate the use of short implants in combination with ridge

splitting and internal and crestal sinus lift in the same surgical area, thus applying a minimally invasive dentistry approach.

Case presentation

A 52-year-old male patient consulted our practice owing to his desire for functional and aesthetic restora-

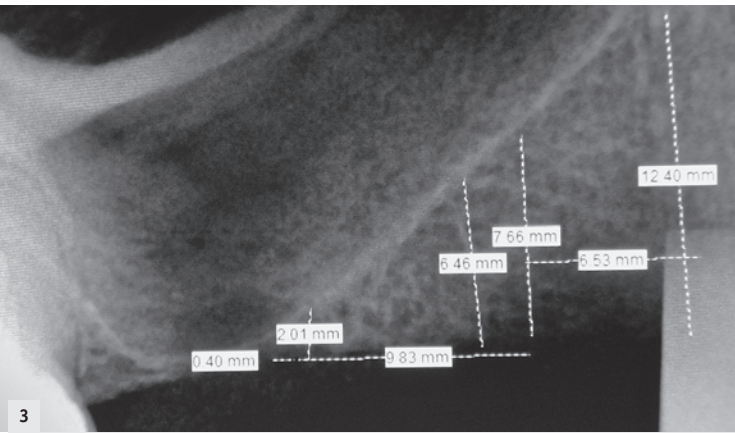


Fig. 3: Residual bone height analysis in the targeted surgical area showed 12.40 mm in the first premolar area, 6.46 mm in the second premolar area and 0.40 mm in the molar area.

tion. The patient did not report any medical background of dental interest. He also signed informed consent prior to the start of treatment and was classified as ASA I physical status. After radiographic (Figs. 1a-e) and clinical (Fig. 2a) examination, it was found that the patient required dental implantation in the right posterior maxilla owing to the missing first and second premolars and first molar.

Amoxicillin (500mg every 8 hours) was prescribed two days before the surgical procedure in order to avoid infections. An experienced clinician then performed the surgical treatment as follows:

1. First premolar: ridge splitting with simultaneous insertion of a narrow implant.
2. Second premolar: ridge splitting, internal sinus lift with simultaneous insertion of a narrow implant.
3. First molar: crestal sinus lift with simultaneous insertion of a short implant.

Surgical technique

Infiltrative anaesthesia was performed during the entire procedure. Initially, a non-adrenaline anaesthetic was used (PRICANEST 4%, Ropsohn Therapeutics) in order to collect blood to mix with a grafting

material (50-500µm SynthoGraft, Bicon Dental Implants). Then, 2% Xylocaine (Dentsply Pharmaceutical) was used to complete the surgical treatment.

Using a #15 blade in a Bard-Parker scalpel, we performed an intrasulcular incision. A full-thickness flap was obtained in the area and then using the blade edges and surgical mallet, cortical perforations were performed covering the premolar area (Figs. 2b & c). Using a carbide round-edge bur (Sinus Lift Bur, Bicon Dental Implants) on a low-speed handpiece, we created a crestal-but not lateral-window until the sinus cortical bone was clearly exposed (Fig. 2d). Then, using a diamond-covered disc (Frios MicroSaw Diamond Discs, Dentsply Sirona) on a low-speed handpiece, we achieved a deeper cortical split in the premolar area (Figs. 2e-g).

A digital radiograph (Dr Suni, Suni Medical Imaging) with a surgical chisel inserted was performed to control RBH (Fig. 3). Surgical chisels were employed to increase length and width in the split area (Fig. 4a). Figures 4b-e show the subsequent use of hand reamers to create the implant space. Besides the ridge split procedure, in the area of the second premolar, a previously published protocol was followed in order to simultaneously perform the sinus lift.²

For the molar area, surgical curettes were used to carefully lift the Schneiderian membrane (Fig. 4f). A synthetic and bacteriostatic grafting material (SynthoGraft; beta-tricalcium phosphate, size 50-500µm) was mixed with the collected blood to a putty consistency—no liquid was evident in the mixture. Then, a 4 mm bone graft syringe was used to place a bone graft material into the apical portion of the osteotomy. Once resistance against the Schneiderian membrane was detected, the syringe was slowly retracted while continuously injecting (Figs. 4g & h). A new digital periapical radiograph was taken to control the grafted space and premolar osteotomies (Fig. 5a). In the first and second premolar areas, one 3.0x8.0mm implant and one 3.5x8.0mm implant (Bicon Dental Implants) were inserted, respectively, with the use of seating tips (Figs. 5b & c).

After bone grafting material had been injected, a 4.5 x 6.0 mm implant (Bicon Dental Implants) was inserted into the lifted sinus using an implant inserter-retriever mounted in a straight handle at first and then gently tapping with a seating tip. Owing to the limited RBH in the area (Fig. 3), a sinus lift abutment (Bicon Dental Implants) was used in conjunction with the implant in order to avoid implant displacement into the lifted grafted space (Figs. 5d & e).

Finally, a continuous suture with polyglycolic acid was used to close the incisions (ACE Surgical Supply, Fig. 5f). After implant insertion, an immediate postoperative radiograph was taken (Fig. 6). The patient received postoperative and home care instructions. An antibiotic (amoxicillin) and analgesic (ibuprofen) were prescribed in order to avoid infection, pain or swelling.

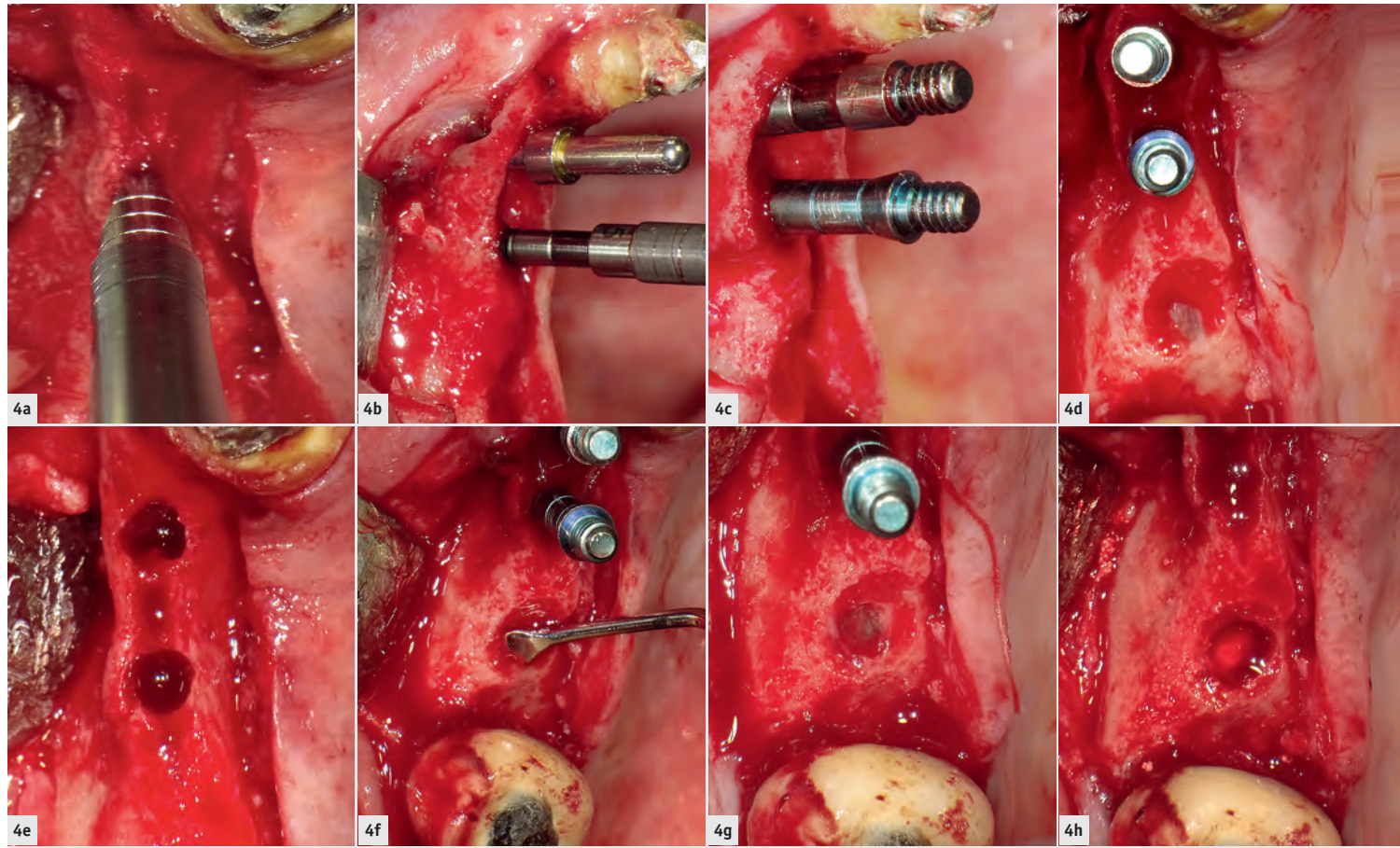


Fig. 4a: Use of surgical chisels to create the artificial space (split) for implant insertion. Fig. 4b: Split area with hand reamers and paralleling pin. Figs. 4c & d: Split area with hand reamers. Fig. 4e: Prepared space to receive implant insertion. Fig. 4f: Schneiderian membrane lift using surgical curettes. Figs. 4g & h: Lifted membrane and grafted space.

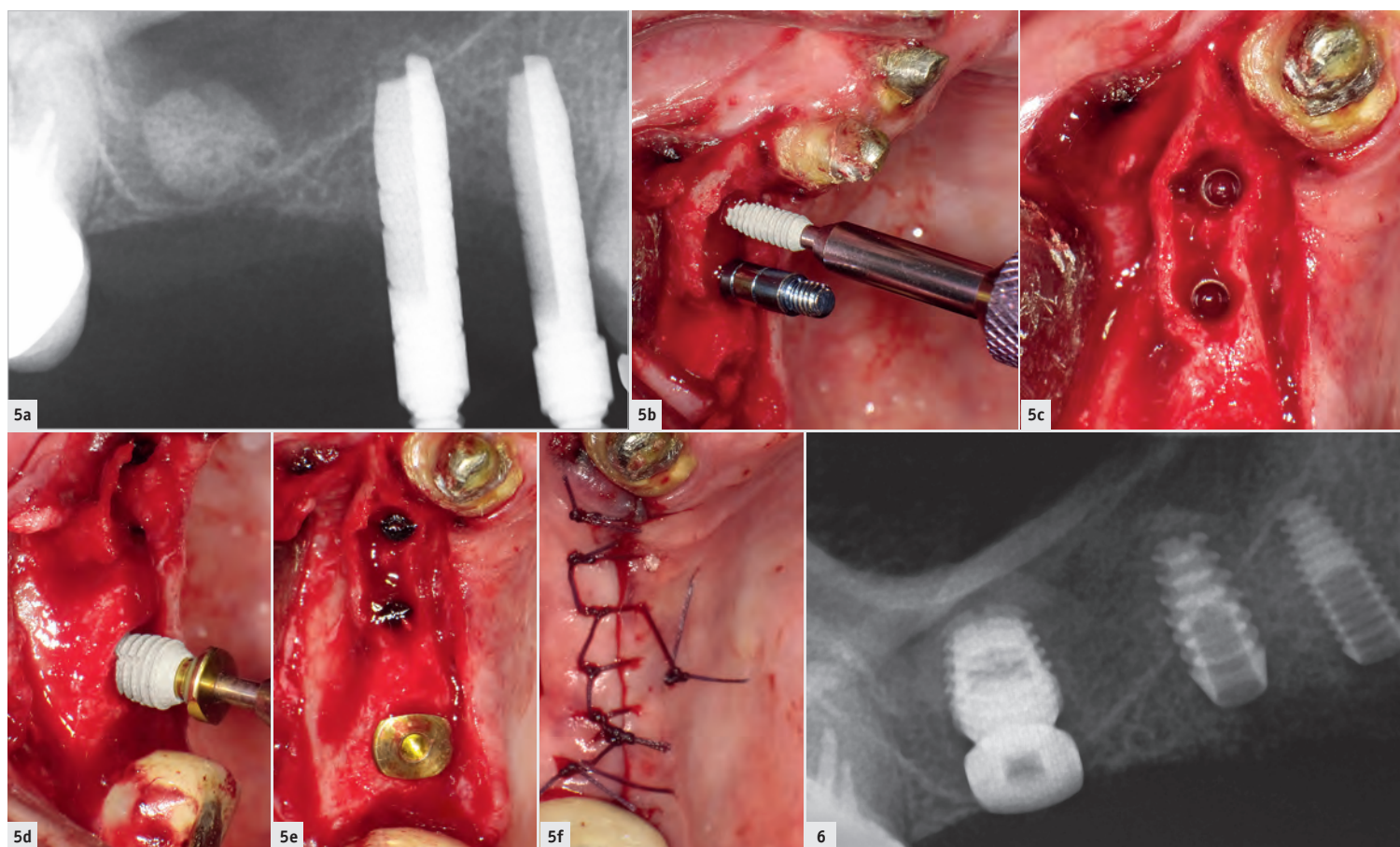



Fig. 5a: Periapical radiograph showing the hand reamers in the premolar area and the grafting material in the molar area. Fig. 5b: Insertion of narrow implant in the first premolar space. Fig. 5c: Inserted narrow implants in the split premolar area. Fig. 5d: Insertion of a short implant with a sinus lift abutment in the molar area. Fig. 5e: Two narrow implants (premolar area) and the short implant (molar area) inserted in the targeted surgical area. Fig. 5f: Sutured wound using the continuous technique. Fig. 6: Immediate post-op radiograph.

Discussion

Several research results have shown the successful outcomes of using surgical procedures such as ridge splitting and sinus lifts in combination with or without dental implants. Brizuela et al. evaluated 36 threaded implants in 36 patients placed using internal sinus lift without grafting material and showed after 24 months that the implant success rate was 91.6 per cent.³ Further, Nedir et al.

showed that atrophic posterior maxillae could be predictably rehabilitated using osteotomes with simultaneous implant placement.⁴ The new bone formed around implants after one year was stable after five years, irrespective of the presence or the absence of a graft.⁴ Grafting was unnecessary to achieve an average bone augmentation of 3.8 mm, but more bone was gained with grafting.⁴ Deliberador et al. successfully demon-



DENTAL TRIBUNE
DT STUDY CLUB
 COURS | DISCUSSIONS | BLOGS | MENTORAT

strated the use of the ridge split technique with simultaneous implant insertion.⁵

Despite all of these results, there is little in the scientific literature on a combination of procedures, for exam-

ple sinus lift and ridge splitting, and implant insertion, as shown in this case report. In this patient, the second premolar area was effectively regained using the ridge split and internal sinus lift techniques in the same surgery.

The literature is conclusive that internal sinus lift should be performed when the available RBH is between 4 mm and 7 mm and lateral sinus lift whenever an RBH of less than 4 mm is present. This case report successfully describes the use of an innovative surgical approach (crestal sinus lift) too via the bone crest lift of the maxillary sinus when the available RBH was less than 1 mm. This approach represents less morbidity and greater time saving and allows implant placement in the same surgery thus decreasing overall treatment time.

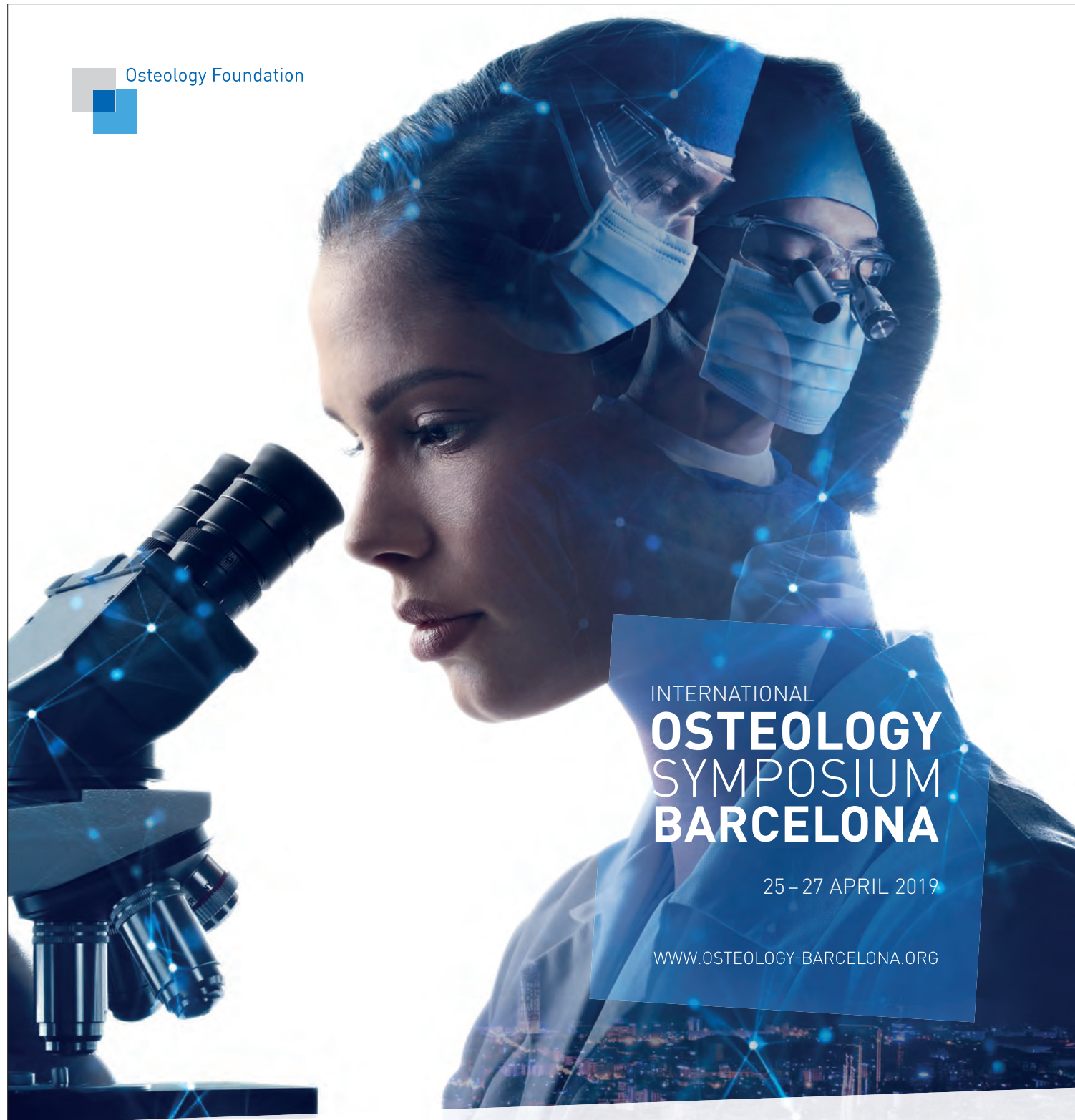Schiegnitz et al. found that evaluation of oral health-related quality of life after sinus augmentation showed significant improvement, indicating a remarkable benefit of this procedure for patients.⁶ Nevertheless, we need additional studies, such as randomised controlled trials, to properly demonstrate effectiveness of these innovative techniques. Tallarico et al. described a crestal approach to sinus lift, showing that sinus floor augmentation can be successfully accomplished with a transcresal approach using a dedicated implant system.⁷ However, in this study, the mean initial RBH was 4.64 ± 0.86 mm, which is more consistent with the internal sinus lift and not the crestal sinus lift surgical indications.

Performing ridge splitting, combined ridge splitting and internal sinus lift, and crestal sinus lift with simultaneous insertion of a short or narrow implant in the same patient constitutes a minimally invasive implant dentistry approach, since they are less time-consuming procedures and produce a minimum rate of complications that represents a less traumatic surgical approach. ◀

Editorial note: The authors disclosed that they have no conflict of interest and that they received no funding for this article.

This article was originally published in implants—international magazine of oral implantology 3/18.

AD



Osteology Foundation

INTERNATIONAL
OSTEOLOGY SYMPOSIUM
BARCELONA

25 – 27 APRIL 2019

WWW.OSTEOLOGY-BARCELONA.ORG

THE NEXT **REGENERATION** MEETS IN BARCELONA. BE PART OF IT!

Programme Highlights

- Latest developments of techniques and technologies in regenerative therapies
- Young experts focusing on oral regeneration in a nutshell
- Hands-on Workshops
- Research Forum
- Case Session for practitioners
- Joint Sessions with DGI and SEPA

Scientific Programme Committee

- Maurício Araújo, Brazil (Chairman)
- Christoph Hämmerle, Switzerland (Chairman)
- Pamela K. McClain, USA
- Mariano Sanz, Spain
- Istvan Urban, Hungary

#NEXTREGENERATION



Dr Miguel Simancas-Pallares

Dental Research Department
 Faculty of Dentistry
 University of Cartagena
 Avenida Del Consulado 48-152
 Cartagena 130014, Bolívar,
 Colombia
 Phone: +57 5 6698172-110
 msimancasp@unicartagena.edu.co

CERAMIC EXCELLENCE

CERALOG[®]
SYSTEM

INNOVATIVE



VISIT US
AT THE EAO
**BOOTH
G12**

CAMLOG Biotechnologies GmbH is a Gold Sponsor.



Sophisticated two-piece construction with innovative abutment solution, ceramic-specific design and high-tech 'Ceramic Injection Molding' manufacturing process – that is CERAMIC EXCELLENCE.

- Dual surface texture: Osseointegration and soft tissue adaption
- Two-piece design, screw-retained reversible prosthetic solutions
- Ceramic-specific design with Hexalobe connection
- Innovative PEKK abutment with stress shield reduction
- Ivory colored for highly esthetic restorations
- 100 % quality control

CERAMIC-SPECIFIC
DESIGN WITH
HEXALOBE
CONNECTION



Become a
CERAMIC EXCELLENCE
partner now
www.camlog.com/en/implant-systems/ceralog

a perfect fit™

camlog