

cosmetic dentistry — beauty & science

1 2014

| **CE article**

Interdisciplinary approach
in aesthetic dentistry

| **case report**

Non-invasive reconstruction
with ceramic veneers—Art or compromise?

| **review**

Ceramics overview:
Classification by microstructure
and processing methods

Dental Tribune International

The World's Largest News and Educational Network in Dentistry

dti] Dental
Tribune
International

www.dental-tribune.com



Dear Reader,

_Welcome to this year's first edition of **cosmetic dentistry**!

In general dental practice, simple to moderate restorative cases dominate the total workload in the practice and the financial gain ratio is comparatively high in simple cases compared with full mouth rehabilitation or other complex treatment. However, it is interesting to note that our young dentists in dental practice are focusing on complex case management and not giving due priority to Class V restorations, inlays, onlays, mild anterior crowding, maintaining optimal oral hygiene, enhancing tooth colour, etc. Globally, the focus is on implant and full mouth restorations, which requires in-depth clinical knowledge and skills in simple case management first. Personally, I always advise my trainees to develop hand skills in direct composite resin restorations, as a good dentist must have artistic hands. Once we understand the minute details (texture, colour, anatomy and effects) of natural teeth using direct restorations, it is easy to obtain quality work from the laboratory and achieve high clinical results. In order to treat complex cases, such as cosmetic full mouth rehabilitation, temporomandibular joint dysfunction (TMD) and sleep medicine, one must complete the required continuing education and learn clinical skills at quality training centres.

During 2013, my team was busy establishing a "regional training centre" for minimally invasive cosmetic dentistry (MiCD) and teeth, muscle, joint and airway (TMJA) harmony dentistry. Cosmetic dentistry, occlusion, TMD and dental sleep medicine are the areas on which the team is focusing. MiCD and TMJA harmony dentistry are becoming quite popular because of their do no harm approach to clinical practice and simplicity in training approach that focuses on skill acquisition.


We have established training centres at Thammasat University in Thailand, the International Center of Dental Excellence in India and the Bangladesh Institute of Advanced Dentistry, and more are coming in Asia.

Our first regional five-day skill training programme is being organised in Thailand on TMJA harmony dentistry and more than 70 senior clinicians from the Philippines, India, Indonesia, Vietnam, Cambodia, Nepal, Thailand, Canada and the US will be participating.

As a practising clinician and presenter of various international training programmes, I feel that every good clinician should participate in a clinical teaching programme, if possible, because this will help clinicians to remain updated and promote personal happiness by sharing their knowledge and skills for better patient care around the world.

We present various clinical articles in this issue and hope you will enjoy reading them.

Yours faithfully,



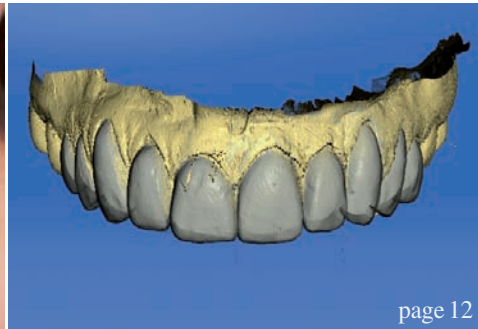
Dr Sushil Koirala
Editor-in-Chief
President of the Vedic Institute of Smile Aesthetics, Kathmandu, Nepal



Dr Sushil Koirala
Editor-in-Chief



page 06



page 12



page 18

| editorial

- 03 **Dear Reader**
| Dr Sushil Koirala, Editor-in-Chief

| CE article

- 06 **Interdisciplinary approach** in aesthetic dentistry
| Dr Sebastian Ercus

| special

- 12 **Projecting a new smile** from a facial photograph:
A new way to plan **multidisciplinary dental treatments**
| Drs Marco Del Corso & Alain Méthot

| case report

- 18 **Non-invasive reconstruction with ceramic veneers—**
Art or compromise?
| Dr Magdalena Jaszczak-Malkowska & Robert Michalik

| review

- 26 **Ceramics overview: Classification by**
microstructure and processing methods
| Profs. Edward A. McLaren & Russell Giordano

| feature

- 36 **“The trend towards the medium-price range**
has accelerated”
| An interview with Straumann executive board member Frank
Hemm about the company's recent investment in MegaGen

| technique

- 38 **Maximal aesthetics in the periodontally**
compromised anterior maxilla
| Drs Nikolaos Papagiannoulis, Eduard Sandberg
& Marius Steigmann

| industry news

- 42 **Planmeca makes CAD/CAM** easier than ever
| Planmeca

| meetings

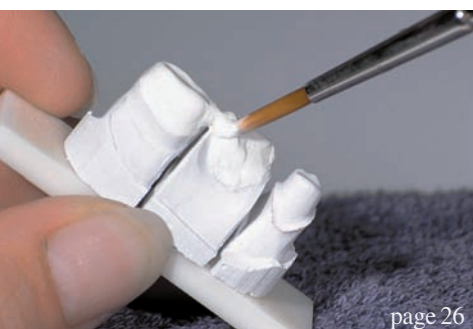- 44 **IMAGINA Dental: Digital dentistry experts**
meet in Monaco
46 **“Clinician education is critical to success”**
| An interview with AO Annual Meeting chairman
Dr Lyndon Cooper
48 **International Events**

| about the publisher

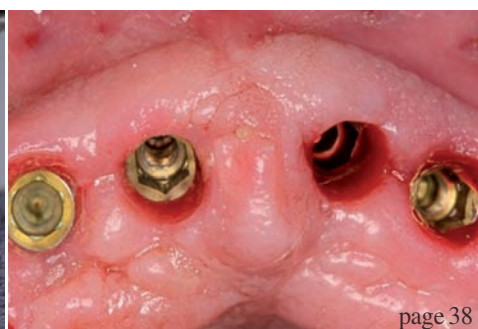- 49 | submission guidelines
50 | imprint



Cover image courtesy of Subbotina Anna



page 26



page 38



page 46



Bio-Emulation™ Colloquium

The Santorini Experience - June 21-22, 2014, Greece

Mentors



Pascal Magne



Michel Magne



Francesco Mangani



Francesca Vallati



Gaetano Calesini

Emulators



Panos Bazos



Gianfranco Politano



Javier Tapia Guadix



Leandro Pereira



Jason Smithson



Claudio Pisacane



Stéphane Browet



Gil Tirlet



David Gerdolle



Sascha Hein



Lucas Zago Naves



Andrea Fabianelli



Giancarlo Pongione

Registration information:

June 21-22, 2014, Greece

The Venue will be held at the Petros M. Nomikos Conference Centre, Fira.

Colloquium fee: € 799

Tel: +1 424 744 0608 / email: c.ferret@tribunecme.com / www.TribuneCME.com

Main Sponsor



Local organizer:



ADA CERP® | Continuing Education Recognition Program

Tribune Group GmbH is the ADA CERP provider. ADA CERP is a service of the American Dental Association to assist dental professionals in identifying quality providers of continuing dental education. ADA CERP does not approve or endorse individual courses or instructors, nor does it imply acceptance of credit hours by boards of dentistry.

Interdisciplinary approach in aesthetic dentistry

Author_ Dr Sebastian Ercus, Belgium

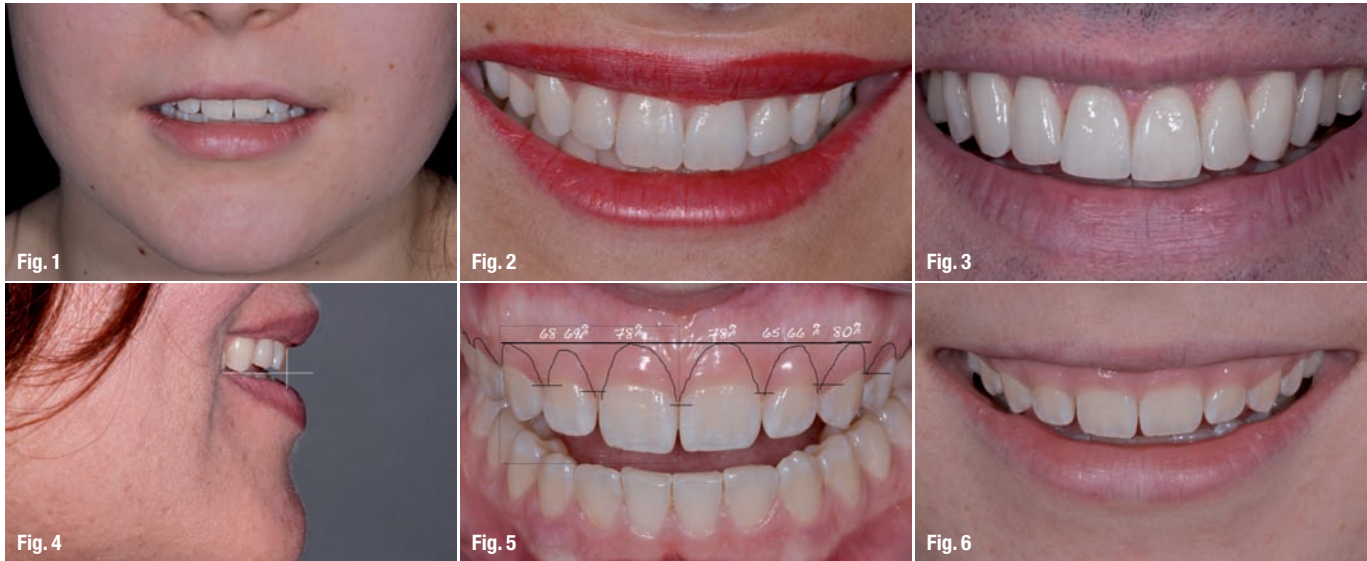

Fig. 1_ The level of the maxillary central incisors in the relaxed position (2–4 mm in women and 1–2 mm in men).

Fig. 2_ A maximum of 2 mm from the incisal edge to the lower lip during smiling, example 1.

Fig. 3_ A maximum of 2 mm from the incisal edge to the lower lip during smiling, example 2.

Fig. 4_ The middle third of the maxillary central incisor should be perpendicular to the occlusal plane.

Fig. 5_ Evaluating width to length ratios.

Introduction

In today's dentistry, for rendering the best comprehensive dental services to our aesthetically driven patients, the paradigm has shifted to an interdisciplinary team of specialists that work together steered by a clinical co-ordinator. This person should be either a multi-competence general dentist or a specialist with additional training outside his or her specialty area. This gives him or her the ability to bring the surgical, orthodontic, restorative and technical teams together as a whole, following treatment sequences customised especially for the patients' best interests and expectations.

The challenge is making the correct diagnosis and selecting the appropriate treatment regimen. In order to achieve that, the clinician has to follow certain guidelines and understand the relations between teeth and the adjacent structures. Establishing the correct position of the incisal edge of a maxillary central incisor in relation to the lower lip, the correct ratios between the tooth's width and length, and the level of gingival margin when smiling are very powerful diagnostic tools.

In order to aid memory, one may remember it as the 42.2 rule:

- a maximum of 4 mm of maxillary central incisor display when the lips are at rest (a minimum of 2 mm; Fig. 1);
- a maximum of 2 mm of gingival display during smiling;
- a maximum of 2 mm from the incisal edge of the maxillary central incisor to the lower lip during smiling (Figs. 2 & 3); and
- the middle third of the maxillary central incisor should be perpendicular to the occlusal plane and the incisal edge should touch the plane (± 0.5 mm; Fig. 4).

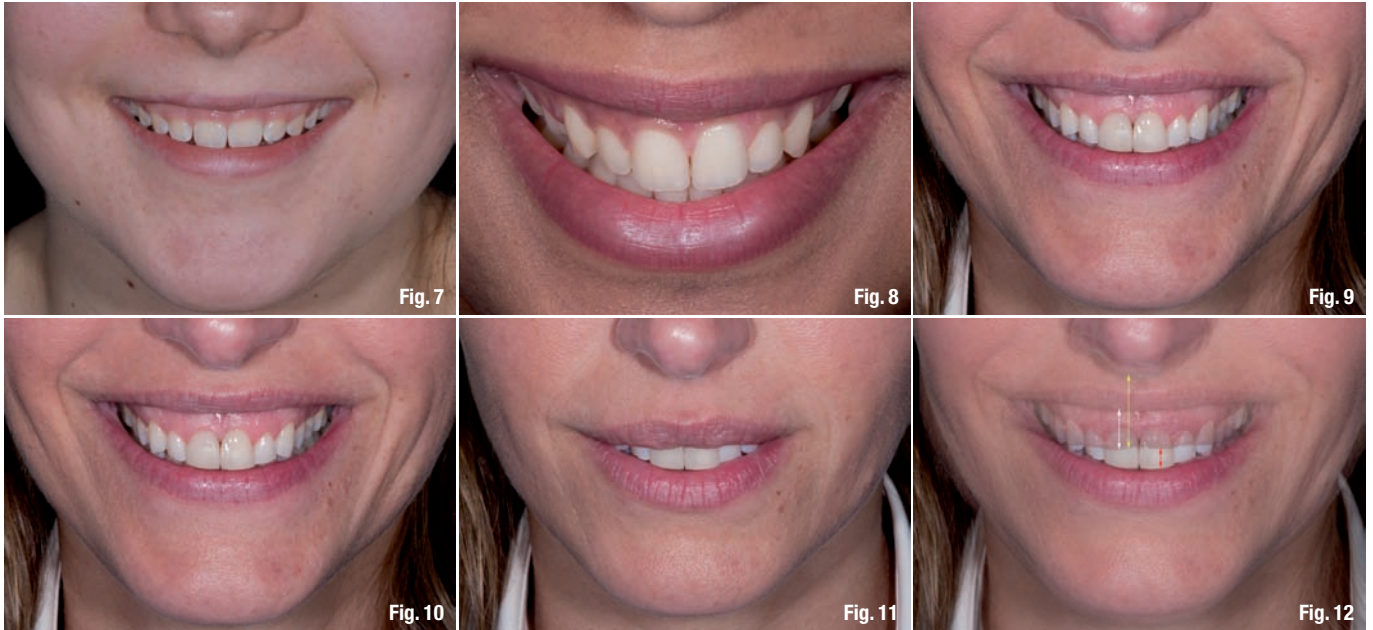The correct ratio between the width and length of a maxillary central incisor is 78 to 80 per cent. With the incisal edge position already determined, we can identify the position of the gingival margin (Figs. 5 & 6).

Gingival margin positioning should be in accordance with the understanding of six conditions present in the oral cavity with different aetiologies and treatment regimens:

1. Altered passive eruption when the gingival margin does not recede to a level near the cemento-enamel junction (CEJ) during tooth eruption. Diagnostically, the gingival margin is located

_ce credit cosmetic dentistry

This article qualifies for continuing education (CE) credit. To take the CE quiz, log on to www.dtstudyclub.com. Click on "C.E. ARTICLES" and search for this article. If you have not registered on the site, you will be asked to do so before taking the quiz.



incisal to the CEJ. Treatment options depend on the amount of attached gingiva and the position of the bone relative to the CEJ (as a general rule, the biologic width should be a minimum of 2 mm):

- (a) gingivectomy;
 - (b) osseous resection (osteotomy) with or without flap surgery (without a flap, it is difficult to control the osseous contour driven by the new gingival margin);
 - (c) apically repositioned flap.
2. Altered active eruption when the osseous crest does not resorb to a level 2 mm apical to the CEJ. The gingival margin is still located incisal to the CEJ. This is treated with periodontal surgery with osseous resection.
 3. Compensatory eruption when the tooth surface is lost, with the reduction in facial height or vertical dimension of occlusion unaffected (short tooth syndrome). Treatment is either restorative or, in the case of hypermobility of the lip, combined with a coronally positioned mucosal flap.
 4. Delayed eruption followed by early loss of primary maxillary incisors, delayed eruption of maxillary permanent incisors or overeruption of mandibular incisors. Diagnostic features are short maxillary incisors, over-erupted mandibular incisors or a Class III maxillomandibular relation. Bearing the 42.2 rule in mind, treatment should follow incisal reduction done selectively with crown lengthening only or crown lengthening combined with orthodontic intrusion of mandibular incisors and possible minimally invasive restoration of maxillary teeth.
 5. Vertical maxillary excess described as a hyperplastic growth of the maxillary skeletal base where teeth are positioned farther from the skeletal base, an increased facial lower third and excessive gingival display, which is classified according to three categories:
 - (a) Category 1: 2–4 mm of gingival display, treated with only orthodontic intrusion, orthodontics and periodontics, or periodontics with restorative therapy;
 - (b) Category 2: 4–8 mm of gingival display, treated with periodontics and restorative or orthognathic surgery (Le Fort type I); and

Fig. 6 Altered passive eruption.

The enamel could be exposed by a gingivectomy in one appointment.

Fig. 7 Lower third smile showing altered passive eruption.

Fig. 8 Delayed eruption.

Fig. 9 A hypermobile lip and a slight vertical maxillary excess.

Fig. 10 Lower third full smile design.

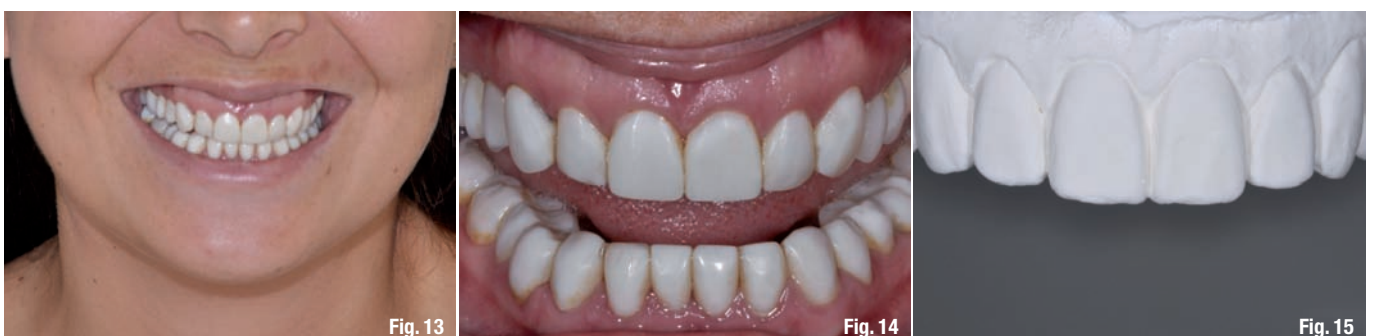Fig. 11 Relaxed position (m/sound—ahhh).

Fig. 12 Superimposed photographs 10 & 11. The red arrow indicates the distance from the incisal edge to the upper lip in the relaxed position. The yellow arrow indicates the height of the upper lip in the relaxed position (~21 mm). The white arrow indicates mobility of the upper lip from the relaxed to smile position.

Fig. 13 Initial lower third when smiling.

Fig. 14 Findings in order of importance after establishing the incisal edge position on the full smile photograph.

Fig. 15 The wax-up duplicated in a stone model.



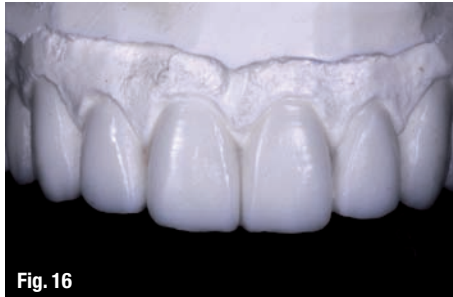

Fig. 16



Fig. 17

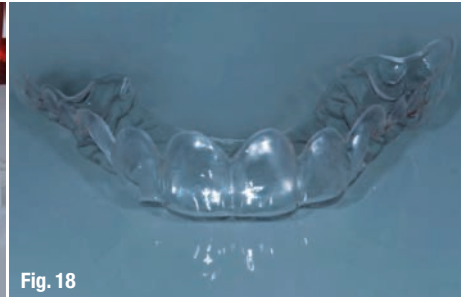

Fig. 18

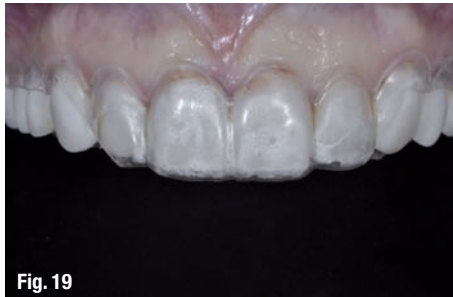

Fig. 19

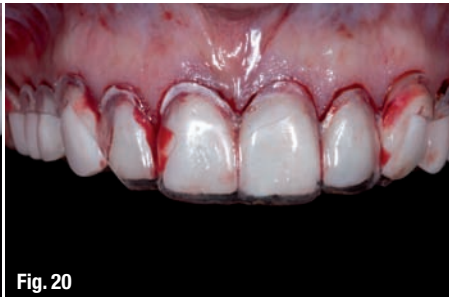

Fig. 20

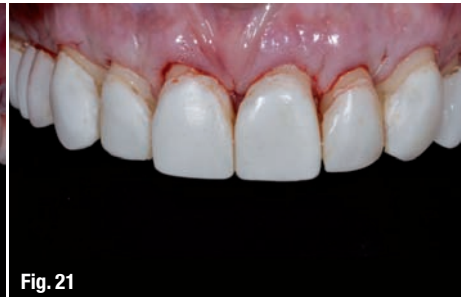

Fig. 21

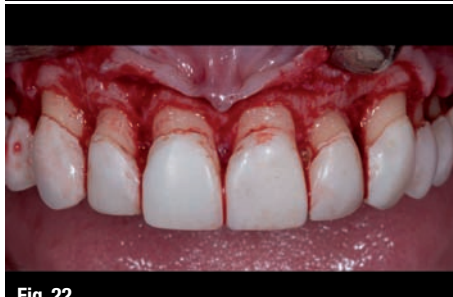

Fig. 22

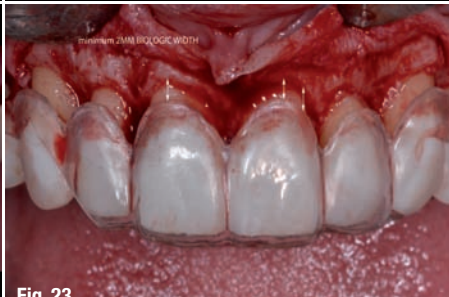

Fig. 23

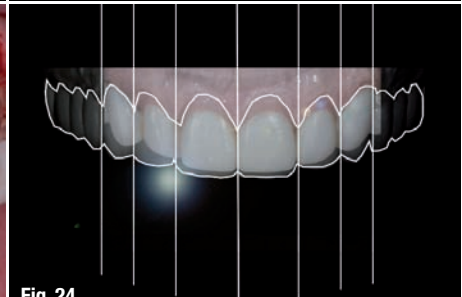


Fig. 24

Fig. 16_ The new design proposal in wax.

Fig. 17_ Very good communication with the dental laboratory.

Fig. 18_ The crown-lengthening surgical guide.

Figs. 19–24_ Crown lengthening with osseous contouring. (Surgery performed by Dr Muriel Krischek, Belgium.)

Figs. 25–27_ The bis-acrylic prototype.

(c) Category 3: more than 8 mm of gingival display, treated with orthognathic surgery with or without periodontal and restorative treatment.

6. Hypermobile upper lip—the average mobility of the upper lip is from 6 to 8 mm from the rest position. More than 8 mm represents hypermobility. Considering that the average distance from the lower margin of the upper lip and the base of the nose (subnasion) is 21 mm, one could take two superimposed photographs with the patient at rest and the patient smiling fully to calculate the lip mobility very easily using the 42.2 rule. Generally normal tooth length is present and dental labial aesthetics is good to ideal. The treatment regimen could entail a coronally positioned mucosal flap, crown lengthening with osseous resection or a combination of both (Figs. 8 & 9)

Example: Photographs captured at the same magnification opened in Adobe Photoshop:

Picture 10: Full smile—length of the central exposed – measure digitally in pixels distance from incisal edge to the lower margin of the upper lip in full smile.

Picture 11: Lips at rest – 2 mm central incisor reveal + 21 mm distance lower lip to base of the nose. Incisal edge to base of the nose 23 mm (incisal edge at the correct position).

x = distance from the incisal edge to the lower margin of the upper lip in full smile

y = the amount of central incisor exposed at rest

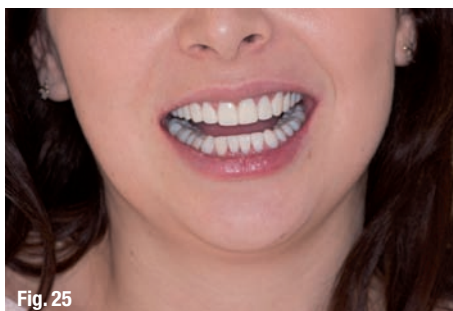


Fig. 25

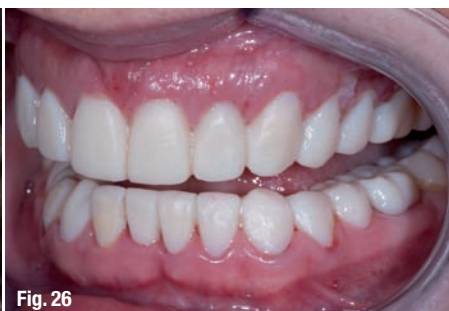

Fig. 26

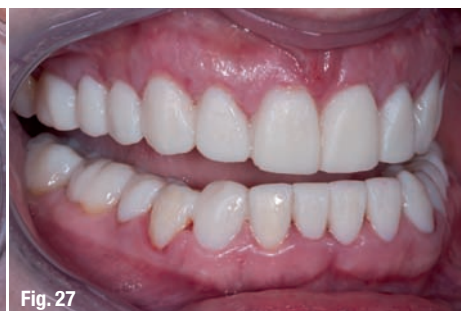
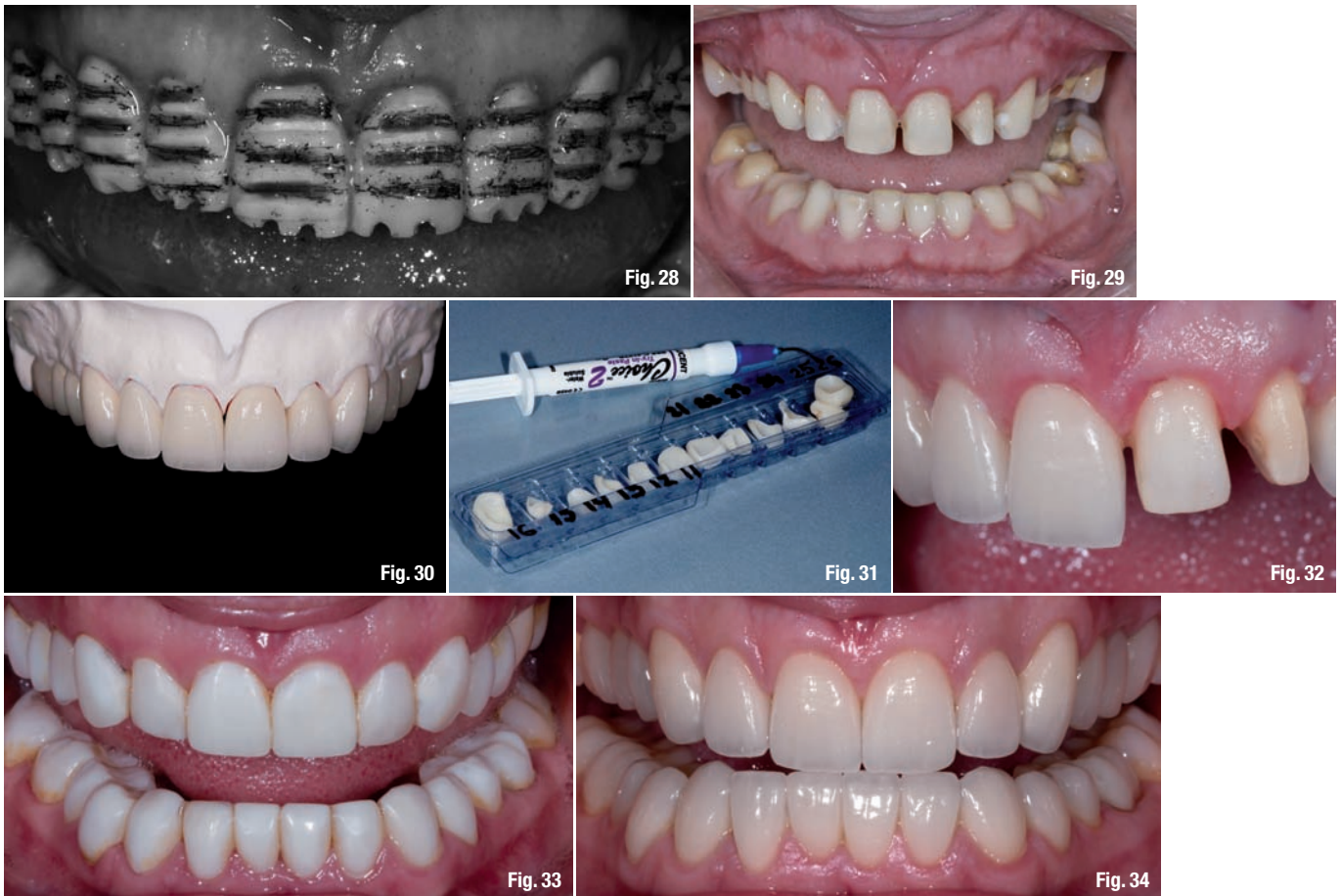
Fig. 27



$23 \text{ mm} = 1,725 \text{ px}$; $x = 900 \text{ px}$; $\text{mobility} = x - y$; $= [(23 \times 900) / 1,725] - 2 \text{ mm}$; $= 12 \text{ mm} - 2 \text{ mm}$; $= 10 \text{ mm}$ (Figs. 10–12)

Since the aetiology is generally multifactorial, by combining all the clinical data gathered during the initial examination, including facial, periodontal, orthodontic, endodontic and restorative data, as well as radiographs and diagnostic photographs, the clinician has the ability to compose a very detailed and comprehensive treatment plan especially for a patient with high aesthetic demands.

Following the digitally designed smile concept, balancing the relations between the teeth and adjacent structures will help the clinical co-ordinator and the specialty team propose treatment planning to the patient. Presenting the plan in Keynote (Apple) or Microsoft PowerPoint is a very powerful communication tool in obtaining treatment acceptance.

Case presentation

A 32-year-old female patient came to the dental office with her chief complaints being short teeth, an uncomfortable bite, too much gingiva showing when smiling, brown-coloured areas of her teeth and insufficient contact points. The patient was in

good general health with a good periodontal status and probing depths of 2 to 3 mm. The aetiology of the excessive gingival display was multifactorial, a combination of delayed eruption, altered passive eruption and hypermobility of the upper lip. From an evaluation of the teeth, both clinically and from the diagnostic photographs, we made the findings given in Table 1 in order of importance (Figs. 13 & 14). We placed incisal edge position first in order of importance because, in the majority of cases, without proper placement whatever follows could result in a tooth that tries to mimic nature but is not properly exposed in a full smile.

Fig. 28 Controlled tooth reduction.

Fig. 29 Tooth preparation.

Fig. 30 Porcelain restorations on alveolar models.

Fig. 31 The try-in paste and organiser.

Fig. 32 Cementation.

Fig. 33 Situation before.

Fig. 34 Situation after.

(Ceramics performed by Edwing Chung, Canada.)

Table 1 Findings.

Incisal edge position	Missing
Form	Missing
Value	Missing
Surface texture	Missing
Translucency	Missing
Chroma	Missing
Hue	Present
Gummy smile evaluation	Missing
Teeth ratios	Missing
Contact points	Missing
Occlusal interferences	Present

Table 1