

# cosmetic dentistry

— beauty & science

1 2010

## | MICD

Midline diastema closure with  
direct-bonding restorations


## | business

Word-of-mouth 2.0

## | feature

An interview with Dr Sim Tang Eng





## BEAUTY – COMPOSE IT!

### Highly aesthetic restorative

- Two simple steps
- Layers like in nature
- Brilliant results



# A M A R I S



NOW AVAILABLE IN  
GINGIVA SHADES

# Dear Reader,


\_Welcome to this year's first edition of **cosmetic dentistry**! With great pride, we are able to look back at a successful year in 2009. **cosmetic dentistry** is now one of the most popular aesthetic dental magazines in the Asia Pacific region. This success was greatly due to the high standard of both printing and article selection. We were able to offer free accessibility to the electronic version of the magazine on [www.dental-tribune.com](http://www.dental-tribune.com) and the official websites of the South Asian Academy of Aesthetic Dentistry (SAAAD) and Asian Academy of Aesthetic Dentistry. Furthermore, various aesthetic continuing education (CE) institutions have approached **cosmetic dentistry** in order to establish a professional relationship for the promotion of the art and science of aesthetic dentistry in the Asia Pacific region.

In my editorial in edition 1/2009, I discussed the scope of the minimally invasive concept in cosmetic dentistry. In edition 4/2009, we published an article proposing the minimally invasive cosmetic dentistry (MICD) concept and its treatment protocol. The concept, which is now widely recognised, was tremendously well received. Various aesthetic and national dental organisations have since invited me to lecture on the concept and its clinical application. It is my pleasure to mention that aesthetic academies now officially endorse the MICD concept and its treatment protocol, introducing it at their scientific meetings and in their CE programmes. For the past six months, I have lectured at the scientific meetings of the Nepalese Academy of Cosmetic and Aesthetic Dentistry, SAAAD, Philippine Dental Association (PDA) and Malaysian Dental Association. Owing to the great response at the PDA conference and at the special request of the Philippine Academy of Esthetic Dentistry, we were encouraged to organise the first exclusive MICD symposium, offering six CE credit points, in Asia on 21 February 2010. With six international speakers and nearly 400 attendees, the symposium was a great success.

Within a short period, the MICD movement has gained popularity and is being accepted by clinicians globally. Keeping this recent trend in mind, we have created a section dedicated to MICD-related clinical cases, with the first in this issue.

I would like to express my gratitude to our valued readers, authors, advertisers and everyone that has directly and indirectly supported **cosmetic dentistry** and thus helped to bring the magazine to its current place. I hope you will enjoy this edition of **cosmetic dentistry** and invite you to send your valuable feedback and ideas.

Sincerely yours,

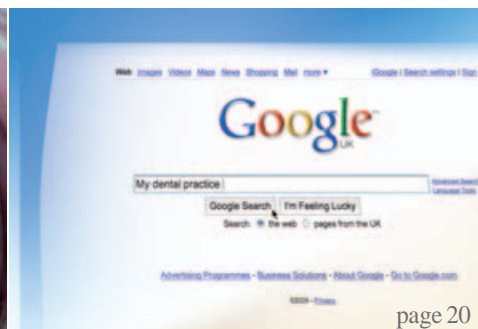
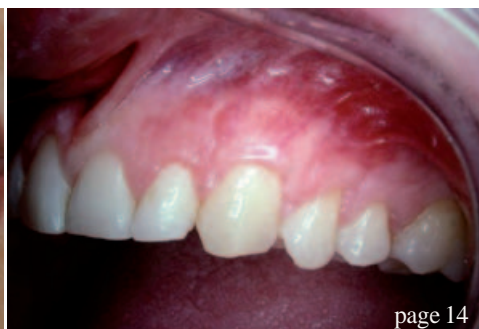
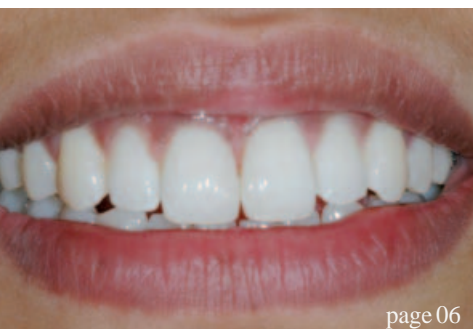
Dr Sushil Koirala  
Editor-in-Chief  
President Vedic Institute of Smile Aesthetics (VISA)  
Kathmandu, Nepal



Dr Sushil Koirala  
Editor-in-Chief





## | editorial

- 03 **Dear Reader**  
| Dr Sushil Koirala, Editor-in-Chief

## | MICD

- 06 **Midline diastema closure with direct-bonding restorations**  
| Dr Sushil Koirala

## | case report

- 12 **Hemisection of a front tooth**  
| Dr Steffen Hohl & Dr Anne Sofie Brandt Petersen

## | special

- 14 **Root recession coverage made predictable using resorbable barriers**  
| Dr David L. Hoexter et al.

## | business

- 18 **The benefits of expanding and refurbishing your practice**  
| Anne Levitch
- 20 **Word-of-mouth 2.0**  
| Dr Lorne Lavine

## | digital dentistry

- 22 **"Once you've tried it, you can't drink anything else"**  
| Dr Jay B. Reznick

## | feature

- 28 An interview with **Dr Sim Tang Eng**, AAAD president

- 30 An interview with **Hans Geiselhöringer**, Head of Global Marketing & Products, Nobel Biocare

## | industry report

- 34 **Opalescent composite resin**  
| Ulf Krueger-Janson
- 37 **'Myth busting' laser dentistry**  
| Fotona

## | industry news

- 38 **Perfect Bleach: Effective and gentle**  
| VOCO
- 39 **VITA Easyshade Compact: The new generation in digital shade-taking**  
| VITA
- 40 **CLEARFIL SA CEMENT: Top Self-adhesive Resin Cement of 2010**  
| Kuraray Europe

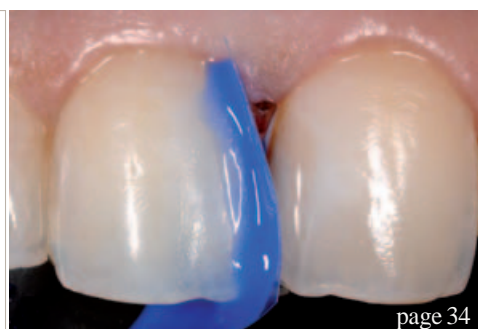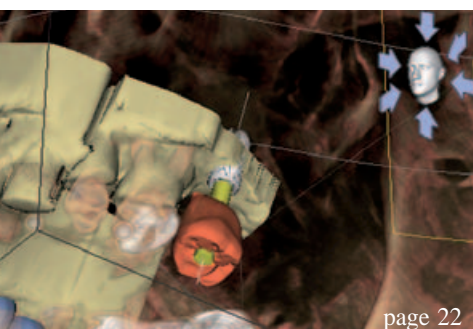
## | meetings

- 42 **The first South Asian cosmetic and aesthetic dental congress**  
| Dr Suhit R. Adhikari
- 44 **All-ceramics works**  
| Manfred Kern
- 48 **International Events**

## | about the publisher

- 49 | submission guidelines  
50 | imprint

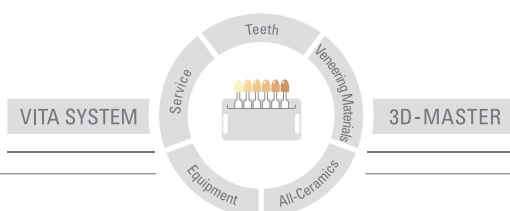
Cover image courtesy of cardiae



# VITA Easyshade® Compact – The exact shade in the blink of an eye.



3384 E



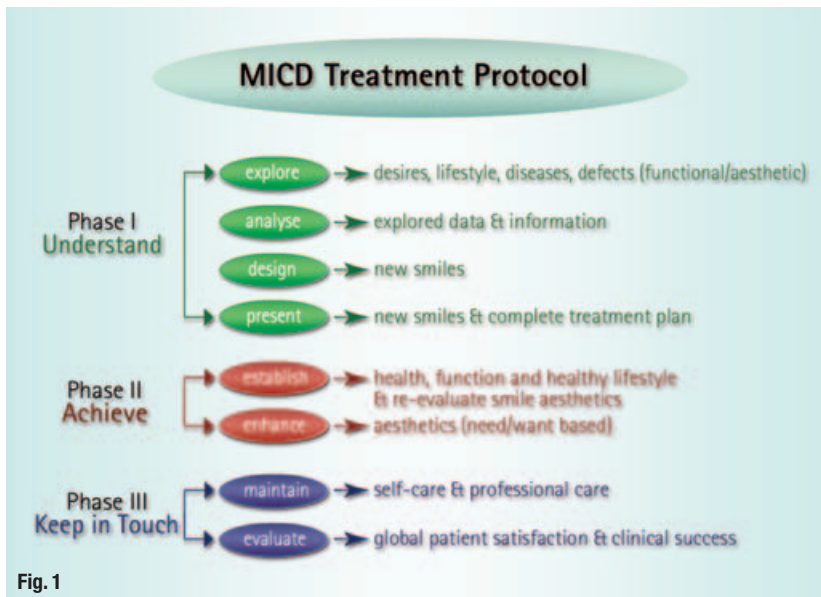
## VITA

It's digital, cable-free, lightweight and mobile – there are a good many reasons for choosing the VITA Easyshade Compact. And every one of these is in itself a winner. With the new generation of digital shade measurement you determine and check the tooth shade in a matter of seconds. The VITA Easyshade Compact is

designed for all shades of the VITA SYSTEM 3D-MASTER and the VITA classical A1-D4 shades. This high-tech instrument impresses with a great accuracy of measurement using state-of-the-art spectrophotometric measurement technology. See for yourself. Find out more at [www.vita-zahnfabrik.com](http://www.vita-zahnfabrik.com).

# Midline diastema closure with direct-bonding restorations

**Author\_** Dr Sushil Koirala, Nepal



**Fig. 1\_** MICD TP.

**\_Midline diastemata (MD)** are spaces of varying magnitude between the crowns of fully erupted maxillary and mandibular central incisors. Keene describes MD as anterior midline spacing greater than 0.5 mm between the proximal surfaces of adjacent teeth. Incidences of maxillary and mandibular MD are 14.8 and 1.6 %, respectively.<sup>1</sup>

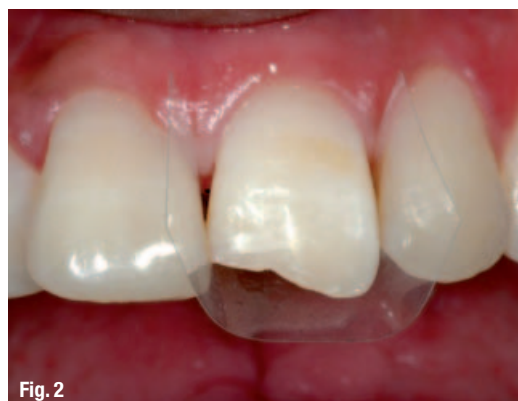MD can occur in temporary, mixed or permanent dentition and may be considered normal for many children during the eruption of the permanent maxillary central incisors. When incisors first erupt, they may be separated by bone and the

crowns incline distally because of the crowding of the roots. With the eruption of the laterals and permanent canines, the MD reduces or even closes completely.

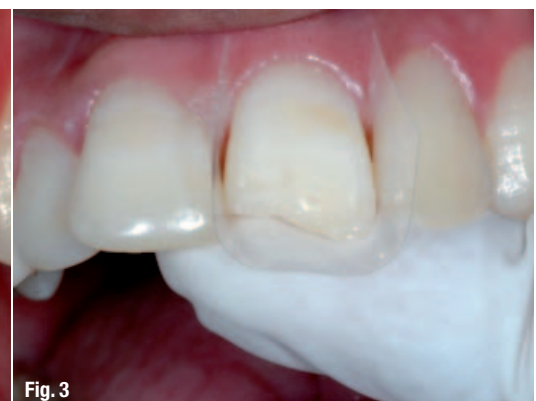## *Etiological factors*

The etiological factors of MD are described by various researchers. Angle concludes the presence of an abnormal frenum to be the cause of MD,<sup>2</sup> a view that has been supported by other researchers.<sup>3-5</sup> According to Tait, the frenum is the effect and not the cause of the incidence of diastemata.<sup>6</sup> He reports causes such as ankylosed central incisors, flared or rotated central incisors, anodontia, macroglossia, dento-alvolar disproportion, localised spacing, closed bite, facial type, ethnic and genetic characteristics, inter-premaxillary suture and midline pathology. Weber lists the causes for spacing between maxillary incisors as the result of high frenum attachment, microdontia, macrognathia, supernumerary teeth, peg laterals, missing lateral incisors, midline cysts, habits such as thumb-sucking, mouth breathing and tongue thrusting.<sup>7</sup> Therefore, the etiological factors can be summarised as follows:

1. developmental: microdontia, missing laterals, mesiodens, macroglossia, macro-hypertrophic fibrous frenum;
2. pathological: midline cysts, tumours and periodontitis;
3. neuromuscular: oral habits, such as tongue thrusting during speech, swallowing or abnormal pressure during rest.



**Fig. 2**



**Fig. 3**

**Fig. 2\_** Placement of plastic strip.

**Fig. 3\_** Plastic strip is supported with index finger.



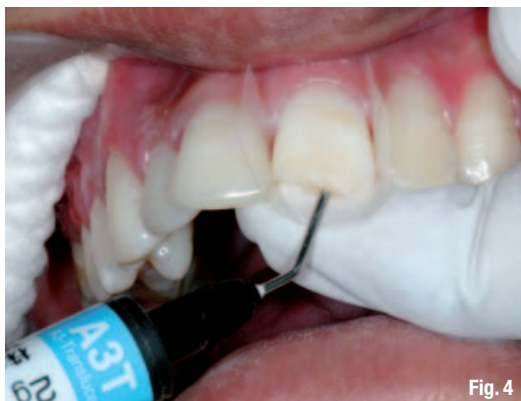

Fig. 4

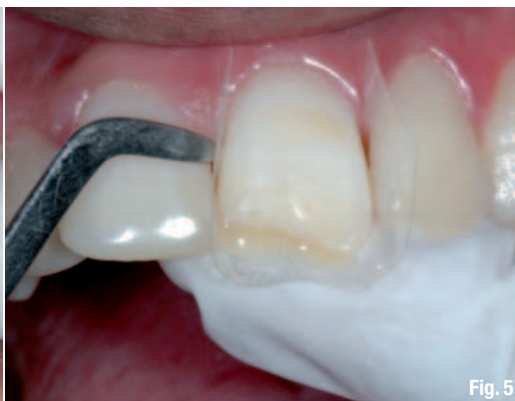

Fig. 5

Fig. 4 \_Injection of flowable resin to create frame.

Fig. 5 \_Flowable resin ready for light curing.

Clinicians must be prepared for patients visiting the dental office with the aim of having their diastema closed in order to fulfil their psychological (aesthetic and beauty enhancement), functional (pronunciation of 'f' and 's' sounds and cutting foods with anterior teeth) and/or health (oral-health maintenance) problems.

### \_Treatment options for diastema closure

Treatment modalities depend on the etiological factors and complexity of the MD. It is suggested that treatment of a MD should be delayed until the eruption of the permanent canines. However, the pathological causes should be ruled out and treated at an early stage, for example extraction of supernumerary teeth (mesiodens) and surgical treatment for the removal of midline cyst, tumour and periodontal pathologies. Surgical, orthodontic (comprehensive/short term), periodontal, direct-bonding and indirect restorations are the treatment modalities that can be used alone or in combination to achieve harmony in terms of a patient's aesthetics, function and health.

MICD by definition is "a holistic approach that explores the smile defects and aesthetic desires of a patient at an early stage and treats them using the least intervention options in diagnosis, treatment and maintenance technology by considering the

psychology, health, function and aesthetics of the patient."<sup>8</sup> The MICD concept as the professional movement that encourages all clinicians to select diagnosis, treatment and maintenance modalities that are the least invasive in order to preserve healthy oral tissues while still achieving the natural aesthetics outcome in the best interests of the patient's health and happiness.

Following, I will demonstrate the clinical use of MICD TP (minimally invasive cosmetic dentistry treatment protocol) to close or reduce the diastema in clinical practice (Fig. 1).<sup>8</sup> The direct-bonding procedure with the application of the Flowable Frame Technique (FFT) is presented here as a special technique.<sup>9</sup>

### \_Case presentation

A 20-year-old female patient presented with the complaint that she did not like her smile because of the large gap between her upper front teeth. The patient was very concerned about her smile aesthetics and also aware of her speech difficulties.

#### *Phase I: Understand*

In the first step of Phase I, the patient's perception, lifestyle, personality, and desires were explored in a personal interview and through completion of the *MICD self smile-evaluation form*. The patient,

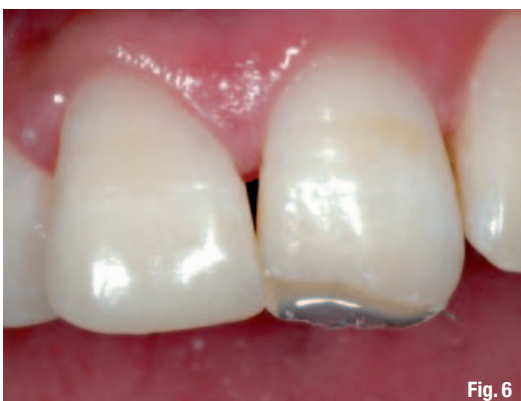

Fig. 6

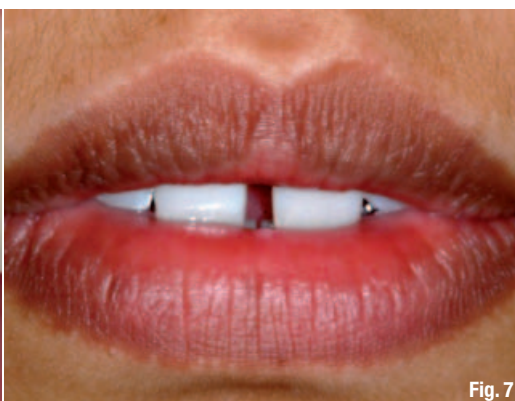

Fig. 7

Fig. 6 \_Plastic strip is removed after light curing; note beautiful lingual frame.

Fig. 7 \_Lips at rest; note MD is clearly visible.

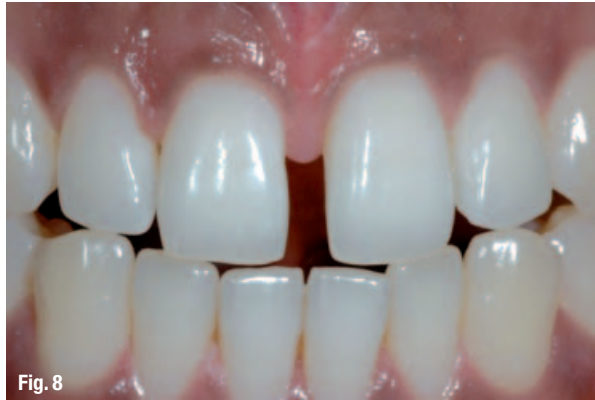

Fig. 8

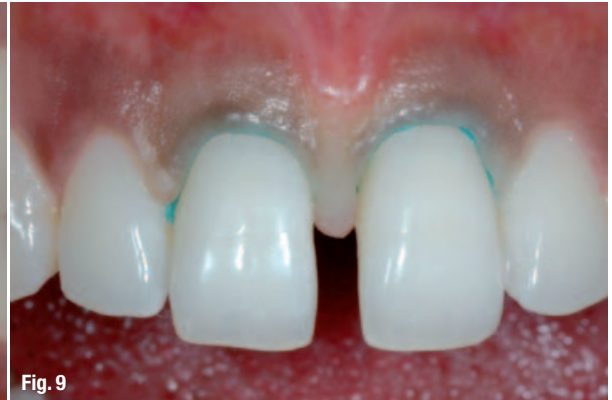

Fig. 9

Fig. 8\_MD in close-up view.

Fig. 9\_Teeth #12 and 21 after isolation with gingival retraction cords.

who exhibited a high dental IQ, evaluated her smile as below satisfactory.

After the interview, the disease, force element and aesthetic defects of her smile were explored clinically. Necessary digital photographs were taken, along with diagnostic study models for further exploration of existing diseases, force elements and aesthetic defects. The patient had good oral health, normal function and no para-functional or other destructive oral habits.

The collected clinical and diagnostic information, such as extra and intra-oral digital photographs, study models and X-rays, was further analysed to determine her smile aesthetic grading in terms of her health, function and aesthetics, as well as to gain an overview of the clinical problems and the macro-, mini- and micro-smile defects. We found a high frenum attachment and the space analysis of the study model revealed a MD of 3.5 mm between teeth #12 and 21. The tooth-size ratio of the centrals was nearly 65 % and lacked central dominance.

Fig. 10\_Light touch upon the enamel surface of tooth #12 with diamond point to enhance bonding process.

Fig. 11\_Enamel etching with phosphoric acid (FL-Bond Etchant) for 20 seconds.

In the design step, a new smile with a closed gap was designed. It is to be noted that the upper central incisors are considered key to a smile<sup>10,11</sup> and must be given sufficient prominence.<sup>12</sup> The aesthetically acceptable width of the centrals is between 75 % and 80 % of their length.<sup>12</sup> In the presented case,

it was logical to close the diastema completely by increasing the width of the centrals. The types of treatment involved, complexity, possible risk factors, complications and treatment limitation were evaluated, and the tentative costs calculated and presented to the patient.

The new smile was proposed through the modified digital photographs and aesthetic mock-up of the study model. In order to correct her MD, a frenectomy with non-invasive indirect partial veneers was proposed as the first option and a direct-bonding restoration without frenectomy as the second option. However, because of financial constraints, the patient preferred the second option.

All patient queries related to the proposed new smile and treatment modalities were addressed in detail. The informed consent form was signed prior to proceeding to Phase II.

#### Phase II: Achieve

In the first step, the patient's health, function and a healthy lifestyle were established. The patient's smile was graded as Grade B.<sup>8</sup> The established parameters of her oral health and function were within normal limits, the aesthetic parameters were below the accepted level and enhancement treatment was to improve her aesthetic parameters further. Hence,

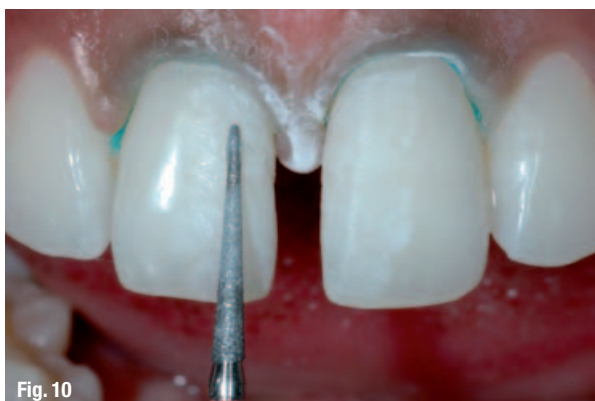

Fig. 10

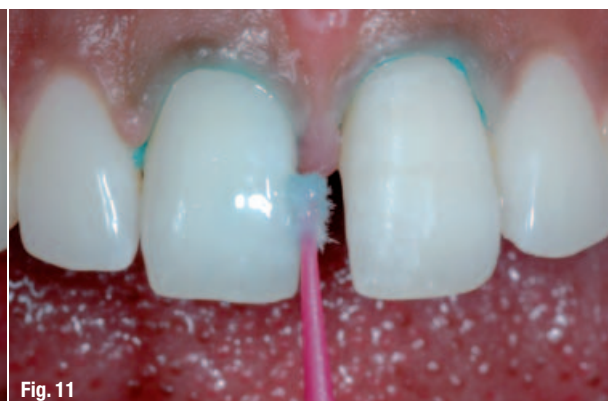

Fig. 11



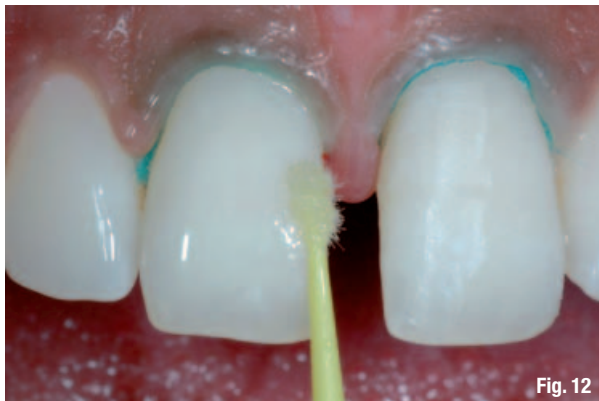

Fig. 12

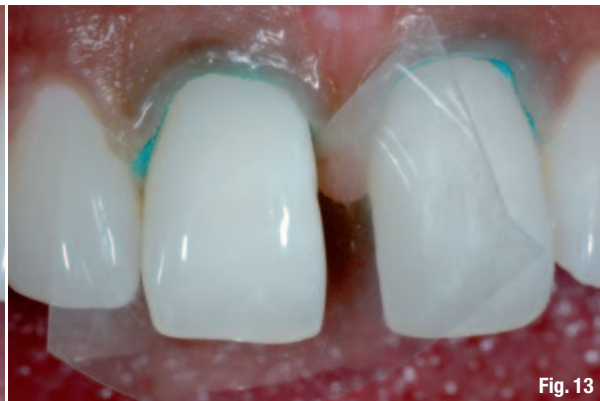

Fig. 13

in this case, it was not necessary to undergo establishment treatment (like orthodontic, periodontal, occlusal adjustment, etc.) before proceeding to the aesthetic enhancement step. According to MICD TP, the desire of the patient in this case was need-based or naturo-mimetic smile enhancement.

### Direct-bonding restoration

The direct-bonding restoration technique represents the preferred therapeutic option in MICD. It preserves maximal tooth structure and helps to restore function and aesthetics in only a few clinical visits. In addition, the technique is economical and the possible need for sophisticated indirect restoration can be postponed. Direct-bonding restorations demand excellent clinical skills. The clinician is required to incorporate various clinical techniques, tips and tricks. Following, I would like to demonstrate a simple technique that I have applied since 2005 in various clinical scenarios and find helpful for the upgrade of clinicians' restorative skills.

#### *The Flowable Frame Technique*

The FFT is a simple restorative technique developed to speed up the placement and simplified confinement of material when restoring challenging anterior aesthetic cases such as large Class IV or Class III defects and diastema closure or reduction. As the name suggests, this technique requires

flowable composite resin as frame material, a plastic strip, composite brush and other usual instruments for direct resin restorations.

#### *Clinical steps in the Flowable Frame Technique*

The following steps are to be taken:

- Step 1—After the completion of etching, priming and bonding of the tooth surfaces, insert a simple plastic strip to the level of gingival sulcus of the tooth to be restored (Fig. 2).
- Step 2—Support the plastic matrix strip lingually with your index finger to create a lingual contour (Fig. 3).
- Step 3—Inject the flowable composite resin of desired shade (either opacious or translucent) and smooth it to a thin layer with a hand instrument or a composite brush if necessary (Fig. 4).
- Step 4—Light cure the flowable composite and remove the plastic strip. A flowable frame is now ready (Figs. 5 & 6). The length, shape and thickness of the flowable frame can be adjusted using the sharp edge of the hand instrument or a diamond point if required.

The advantages of the FFT are:

- time and cost saving (no direct or indirect mock-up required);
- thickness of the layer of restoring materials

**Fig. 12\_**Uniform layer of bonding (FL-Bond) application.

**Fig. 13\_**Placement of plastic strip for FFT.

**Fig. 14\_**Injection of flowable resin (Beautiful Flow shade A3T).

**Fig. 15\_**Adjustment of lingual frame with sharp hand instrument.

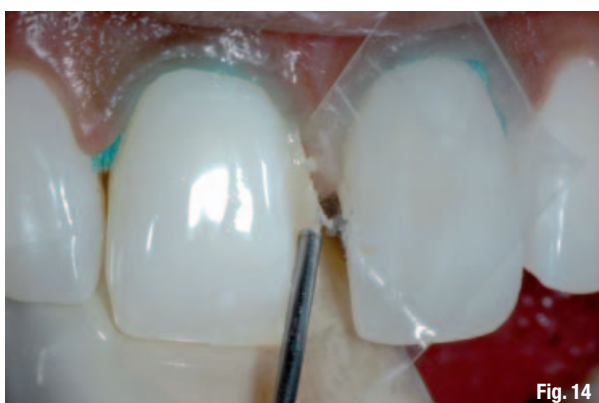


Fig. 14

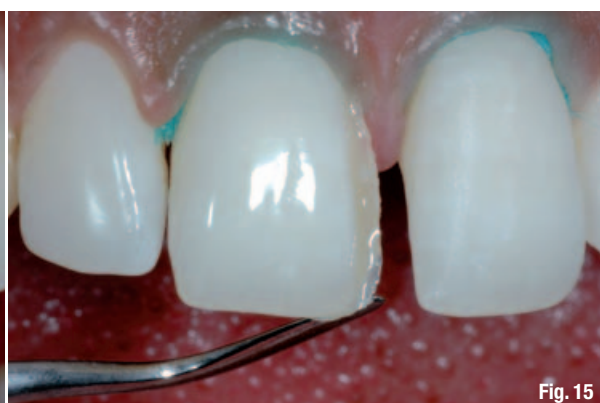

Fig. 15