

# cosmetic dentistry — beauty & science

4<sup>2009</sup>

| **case study**

Cosmetic periodontal surgery

| **digital dentistry**

Safety and reliability with  
CAD/CAM technology

| **special**

MICD—Concept and treatment protocol



**dti** Dental  
Tribune  
International

e.max<sup>®</sup>  
IPS

“e.max LITHIUM  
DISILICATE IS THE  
MOST ROBUST  
CERAMIC SYSTEM  
TESTED TO DATE.”\*

**This changes everything.**

The durability of lithium disilicate glass-ceramic crowns is higher than that of veneered zirconium oxide. Lithium disilicate is therefore the material of choice for single crowns: strong, esthetic, economical. Try it yourself.

**\*Mouth Motion Fatigue and Durability Study**

Petra C Guess, Ricardo Zavanelli, Nelson Silva and Van P Thompson,  
New York University, March 2009

<sup>1</sup> 90% failure by 100,000 cycles

<sup>2</sup> No failures at 1 million cycles

350 N<sup>\*1</sup>

veneered  
zirconium  
oxide

1,000 N<sup>\*2</sup>

IPS e.max  
lithium  
disilicate

all ceramic  
all you need

[www.ivoclarvivadent.com](http://www.ivoclarvivadent.com)

**Ivoclar Vivadent AG**

Bendererstr. 2 | FL-9494 Schaan | Liechtenstein | Tel.: +423 / 235 35 35 | Fax: +423 / 235 33 60

**Ivoclar Vivadent Marketing Ltd. (Liaison Office) India**

503/504 Raheja Plaza | 15 B Shah Industrial Estate | Veera Desai Road, Andheri (West) | Mumbai 400 053 | India  
Tel.: +91 (22) 2673 0302 | Fax: +91 (22) 2673 0301 | E-mail: [info@ivoclarvivadent.firm.in](mailto:info@ivoclarvivadent.firm.in)

**Ivoclar Vivadent Marketing Ltd. Singapore**

171 Chin Swee Road | #02-01 San Centre | Singapore 169877 | Tel.: +65 6535 6775 | Fax: +65 6535 4991

ivoclar  
vivadent<sup>®</sup>  
passion vision innovation

# Dear Reader,

\_The end of 2009 is already drawing near, which is an opportune time to look back and evaluate what we have achieved as dental professionals: What accomplishments and changes have we been able to make thus far? How are we doing overall and what can we improve in the coming year?


A survey conducted by the American Academy of Cosmetic Dentistry (AACD) revealed that cosmetic-related income climbed to an average of US\$495,000 per practice in 2007, representing a 15 per cent increase over the previous year.

In August, the American Academy of Esthetic Dentistry hosted the International Federation of Esthetic Dentistry Las Vegas meeting with the theme *Passion, Esthetics and New Technology: The Future of Dentistry*. Leading lecturers from all over the world contributed to an exchange of invaluable information. The meeting confirmed that the future of dentistry is geared towards aesthetic dentistry with an emphasis on evidence-based dentistry. Cosmetic dentistry is a field of recognisable growth globally and this trend is likely to continue.

I was invited to present at the annual scientific meeting of the AACD in Hawaii and received much positive feedback on **cosmetic dentistry**. It is thus with great excitement and pleasure that I introduce this year's final edition. With the above-mentioned developments in mind, we bring you the latest on the most significant international developments and experiences. I am confident that this edition of **cosmetic dentistry** will satisfy your current needs by providing you with guidelines, instructions and visions for your future cosmetic dentistry procedures.

Please feel free to contact us with your valuable feedback, questions, concerns or suggestions.

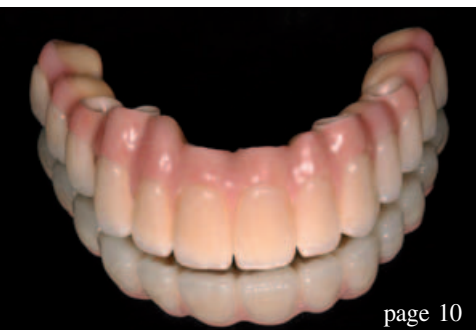Sincerely yours,



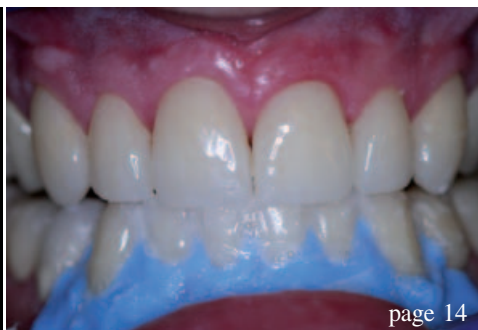Dr So-Ran Kwon  
Co-Editor-in-Chief  
President of the Korean Bleaching Society  
Seoul, Korea



Dr So-Ran Kwon  
Co-Editor-in-Chief



page 10



page 14



page 18

## | editorial

### 03 Dear Reader

| Dr So-Ran Kwon, Co-Editor-in-Chief

## | case study

### 06 Cosmetic periodontal surgery:

**Pre-prosthetic soft-tissue ridge augmentation (Part I)**

| Dr David L. Hoexter

### 10 Complete maxillary implant prosthodontic

**rehabilitation** utilising a CAD/CAM fixed prosthesis

| Dr Neo Tee-Khin et al.

### 14 Aesthetic functional veneers in patients with habitual dysfunctions?

| Prof Martin Jörgens

## | clinical technique

### 18 A new approach for patient acceptance and appreciation

| Dr Lorin Berland & Dr Sarah Kong

### 22 Maintenance of periodontally compromised teeth with **direct splinting**—current materials and options

| Dr Ajay Kakar

## | special

### 28 Minimally invasive cosmetic dentistry—Concept and treatment protocol

| Dr Sushil Koirala

## | digital dentistry

### 34 CAD/CAM expands the scope of restorative dentistry

| Manfred Kern

### 40 Safety and reliability with CAD/CAM technology

| Hans Geiselhöringer & Dr Stefan Holst

## | industry report

### 44 Smile upgrade—Highly aesthetic composite restorations in the anterior region

| Dr Ronald D. Jackson

## | meetings

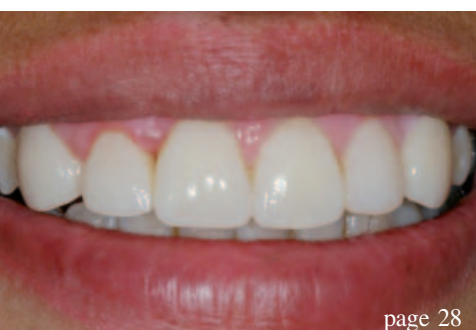### 48 Cosmetic events

## | about the publisher

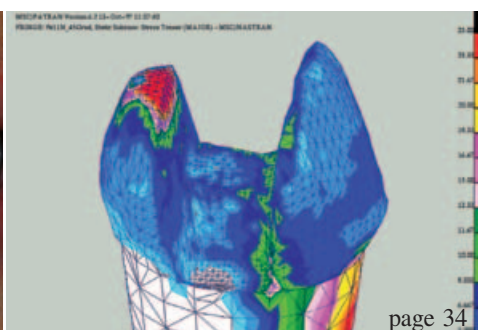
### 49 | submissions

### 50 | imprint

Cover image courtesy of Cardiac and Perov Stanislav.



page 28



page 34



page 40



# *Convenience & Efficiency Now at your Fingertips ...*

## **MonoCem Self-Adhesive Resin Cement**



- Self-Etch
- Unlimited Working Time
- Moisture Tolerant
- Dual Cure, Auto-mix
- No Sensitivity
- Fluoride Release
- 100% Polymerization

***For further information, contact your SHOFU dealer TODAY!***



**SHOFU INC. Singapore Branch**

Tel: 65-6377 2722

Fax: 65-6377 1121

eMail: [mailbx@shofu.com.sg](mailto:mailbx@shofu.com.sg)

[www.shofu.com.sg](http://www.shofu.com.sg)

# Cosmetic periodontal surgery: Pre-prosthetic soft-tissue ridge augmentation (Part I)

Author \_ Dr David L. Hoexter, USA

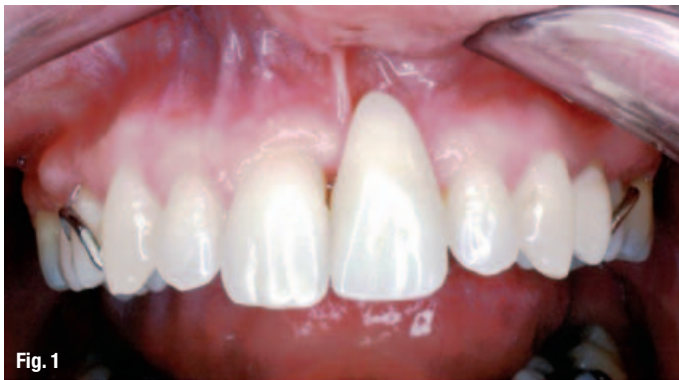

Fig. 1 \_Initial labial view of maxillary #9 edentulous area with a flipper.

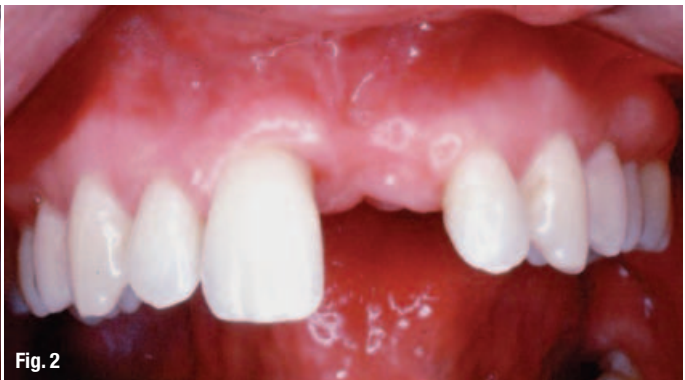

Fig. 2 \_Labial view of maxillary #9 edentulous area.

**\_Dentists understand** that patients demand outstanding aesthetic, as well as physiological, results in all phases of dentistry today. This places an onus on dentists, who must therefore be able to apply the latest technologies and techniques to achieve each patient's unique aesthetic desires successfully. A successful aesthetic outcome requires knowing how to create the right illusion, which is subjective for each individual. Yet, it can be measured in objective and subjective standards. How then can practitioners evaluate and achieve these goals?

To begin, there are certain basic and objective characteristics of a healthy periodontia that must first be observed, respected and maintained. A healthy periodontia is essential for achieving and maintaining restorative aesthetics.

A reddish, inflamed periodontia immediately attracts negative attention to the area. In contrast, a healthy zone of pink attached gingiva acts as a subtle background, providing dentists with significantly more restorative options for teeth.

Similarly, exposed gold crowns, gingival margins, exposed gingival porcelain jackets or laminate margins will draw negative attention. Also, crowns placed sub-gingivally in an inflamed area are likely to lead to recession and an irregular gingival pattern, resulting in dissatisfied patients.

After healthy periodontia has been achieved, colour, hue, shape, form, symmetrical appearance and individual choice must then be discussed. At this point, the challenge of aesthetic dentistry is at its zenith.

Part I of this series discusses the role of pre-prosthetic, cosmetic periodontal surgery to achieve and maintain a healthy periodontia and to aesthetically improve shape, colour, form and appearance.

Clinicians should strive to achieve the appearance of a healthy symmetrical flow. For example, patients will not be satisfied with an oversized pontic placed in a large irregular edentulous area with a fixed bridge for long. It is unaesthetic and retains



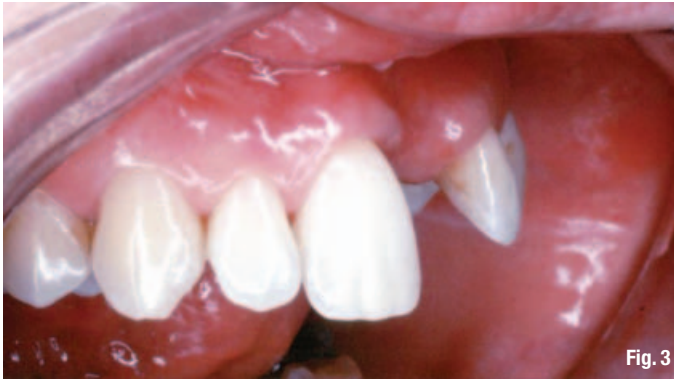

Fig. 3

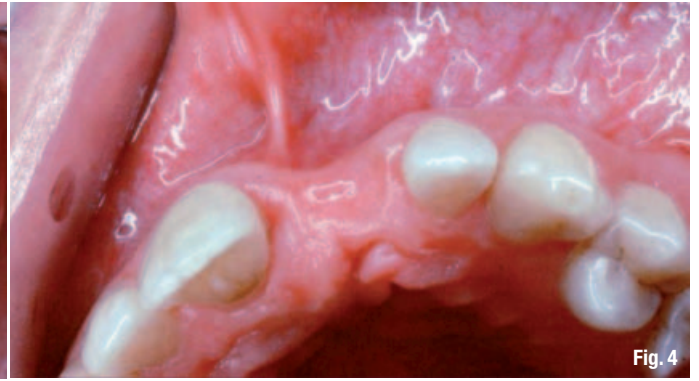

Fig. 4

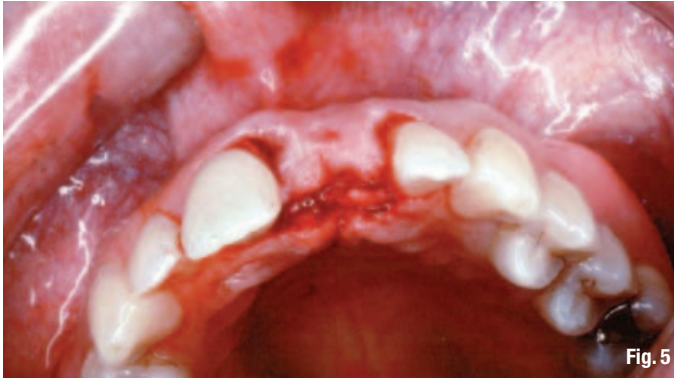

Fig. 5

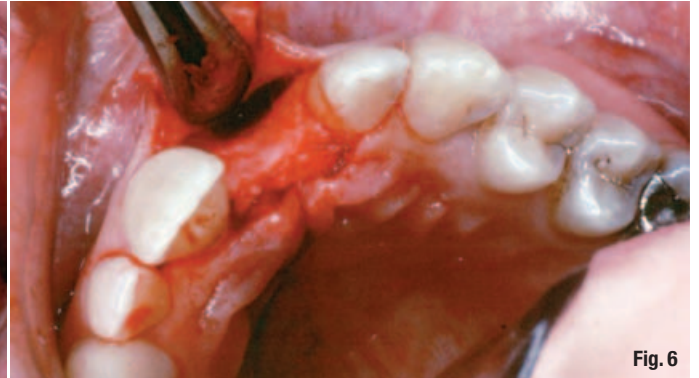

Fig. 6

food and plaque, which will lead to inflammation and periodontal disease. Often, a phonetic problem will also result. These patients will be thwarted in and frustrated by their hygiene efforts, and dissatisfied with the illusion of health and aesthetics that they sought to achieve. Therefore, the relationship of a pontic and the abutment teeth to the gingival must be observed critically before the prostheses are fabricated.

By correcting the edentulous area aesthetically and physiologically with cosmetic periodontal surgery, a restorative dentist is able to fabricate a correctly shaped prosthesis that enhances aesthetics and function.

It is important to make an assessment prior to fabricating the prostheses. In the past, large pontics were made to fill voids created by irregularly shaped,

depressed edentulous ridges between abutments. The opportunity to build out and create a symmetrically harmonious bridge that blends in with the abutment's periodontia is currently available.

The following illustrates an example of treatment of one such case, resulting in a harmonious and aesthetically pleasing appearance.

### \_Case 1

A 25-year-old woman presented to the office very interested in achieving ideal aesthetics with a non-removable appliance. For years, she had been wearing a flipper removable replacement for her maxillary left central incisor (Fig. 1), which was traumatically lost in an accident when she was 15 years old (Fig. 2). Following the accident, it was suggested by her restorative dentist (because of her young age)

**Fig. 3** \_Lateral view showing labial concavity depression.

**Fig. 4** \_Occlusal incisal edge view showing concave labial ridge.

**Fig. 5** \_Occlusal view of flap outline.

**Fig. 6** \_Reflected muco-gingival flap exposing osseous labial defect.

**Fig. 7** \_Gingival connective tissue graft placed in correct position.

**Fig. 8** \_The gingival graft is sutured to the flap, while the flap is repositioned and sutured for stability.

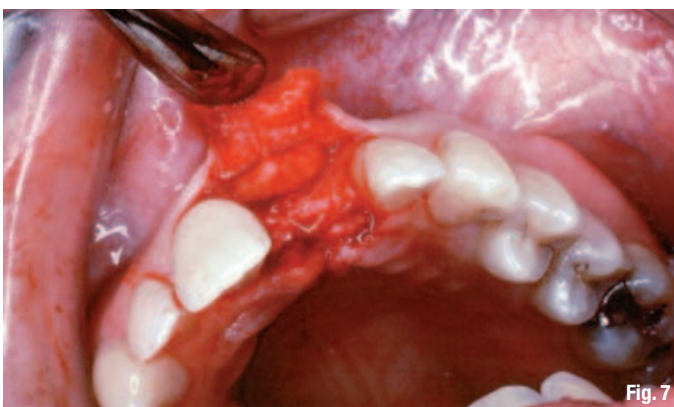

Fig. 7

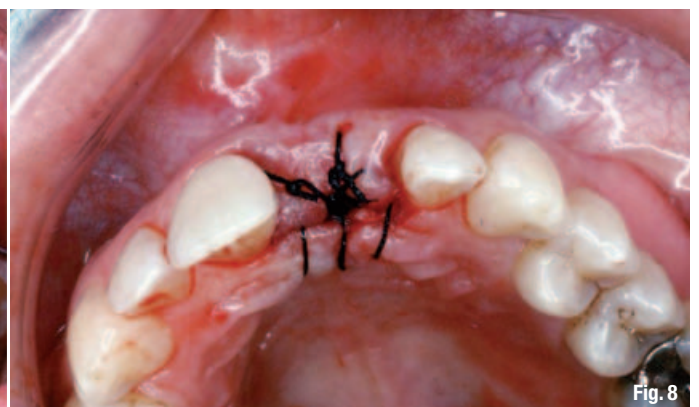
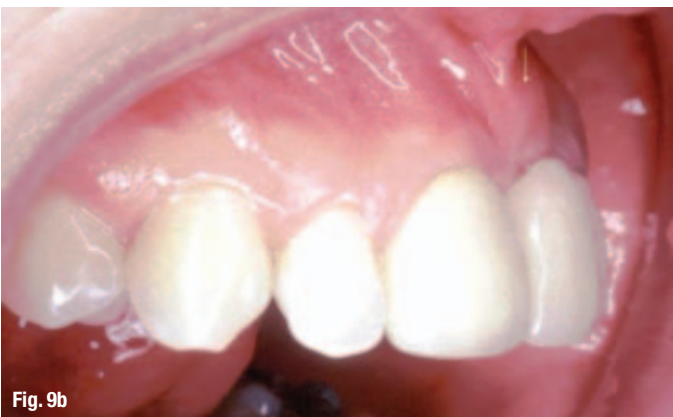
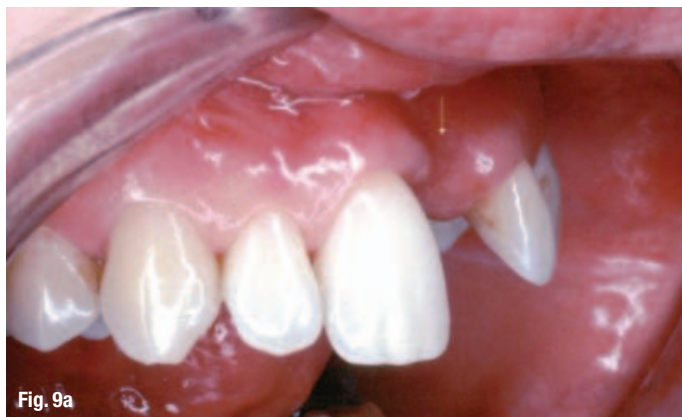Fig. 8



**Fig. 9a**\_Initial lateral view of depressed area.

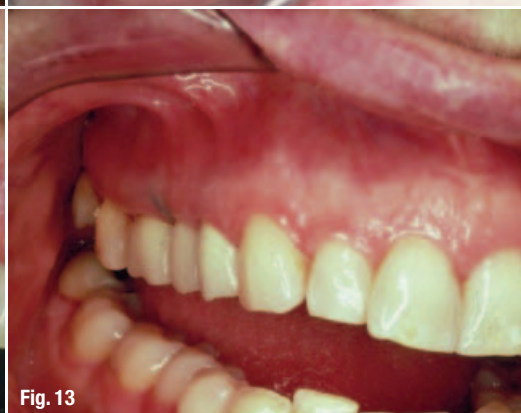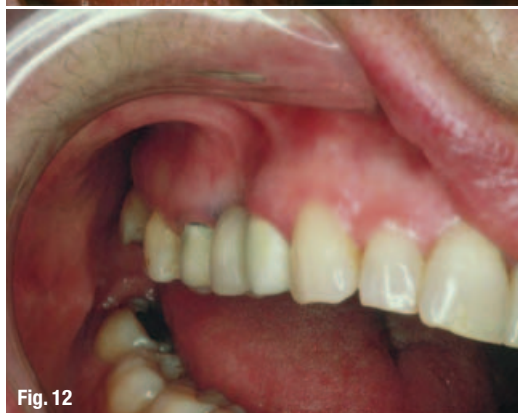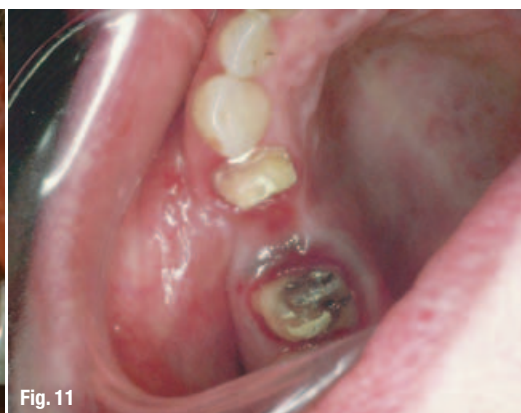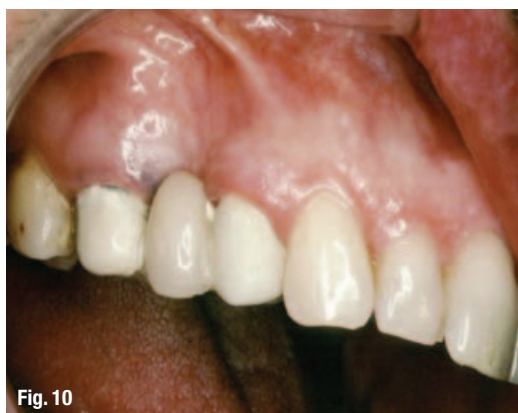**Fig. 9b**\_Healed ridge augmentation, lateral view.

that she avoid a permanent splint and wait for the pulps of the adjacent teeth to mature. Years later, she was referred to me for pre-prosthetic cosmetic surgery that would allow for a non-removable, aesthetically pleasing and physiologically maintainable appliance.

Without the surgery, the permanent replacement would have been a large bulky pontic or physiologically sized pontic, which would have retained food and plaque because of a void between the gingival space of the pontic and the crest of the edentulous ridge. This void would then have created a dark and unaesthetic contrast. If the pontic had been smaller, there would have been a space between the pontic and the edentulous ridge in which food and plaque would also be retained.

If a removable appliance had been fabricated, the practitioner might have achieved an acrylic colour that somewhat resembled the pinkish gingival area, but it would have been discernible. If a clasp partial was used for the removable prostheses, the clasp would have been unsightly. An attachment-type partial would require crowns to be prepared on the remaining abutments, and the contrast of the replacement tooth would have been detected next to the adjacent abutments. Either partial would have been an obvious replacement that contrasted with the adjacent teeth.

After consultation, it was determined that by using a combination of periodontal surgery techniques, the shape, height and form of the ridge could be corrected, enabling the restorative dentist



**Fig. 10**\_Buccal view of a posterior maxillary area with an extreme depression defect.

**Fig. 11**\_Occlusal view of the same posterior defect without provisional prosthesis.

**Fig. 12**\_Anterior-buccal view of same defect.

**Fig. 13**\_Tissue ridge augmentation completed in posterior with new provisional; note the physiological and aesthetic enhancement.



to place a physiological crown. The edentulous ridge had a labial depression and an incisal edge that appeared concave (Figs. 3 & 4). The tissue had to be built up incisally and labially, and a harmonious flow of pink attached gingivally had to be maintained.

Following a thorough evaluation, an autogenous connective tissue graft was placed sub-epithelially in one surgical procedure to achieve a symmetrical look. After anaesthetising the patient, the flap outline and its reflection towards the labial were completed (Figs. 5 & 6). The connective tissue donor site could have been selected from various areas. In this particular case, the tuberosity area was used. The donor tissue was de-epithelialised, and the deformed edentulous area was sculpted to the desired shape. The original flap outline was designed to prevent recession on the adjacent teeth and provide a covering for the graft in order to avoid a keloid on the crest. During healing, a keloid would have been a different colour, which would have detracted from the goal of harmonious colour integration. The flap outline was then extended palatally to include more attached gingival, which avoided a keloid and retained the graft. Once the autogenous free connective tissue graft was in the desired location, the flap was repositioned and sutured for stability (Figs. 7 & 8).

In this case, the patient had worn a flipper for years to replace a missing tooth. Following surgery, I reduced the existing flipper to allow space for the graft to heal.

After an uneventful post-operative period, the patient healed and continued with good oral hygiene. The referring dentist had a choice of several restorative techniques. In this case, a fixed splint was fabricated with an acceptable pontic (Figs. 9a & b).

In a one-stage procedure, we avoided creating a dark area of labial depression and/or an irregular, concave gingival crestal margin. A lengthy, unsightly pontic was replaced by a physiological, cosmetically acceptable, natural-looking pontic, and the patient was delighted.

## \_Case 2

The second case demonstrates the use of the same technique in the posterior segment of a patient's maxilla. An extreme buccal-incisal defect (Figs. 10 & 11) where an extraction was done is shown in a maxillary posterior area (Fig. 12). The soft-tissue ridge augmentation technique was used. A temporary provisional bridge shows the restored ridge enhancing the cleanliness and cosmetic appearance. The final prosthesis displays a prosthetic appliance

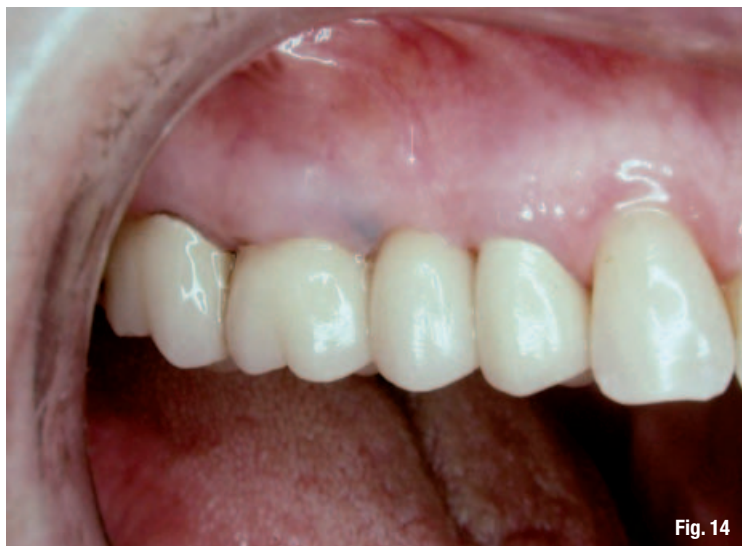

Fig. 14

that had been in the patient's oral cavity for 20 years. This shows the longevity, as well as the aesthetic enhancement of the technique and its ability to enhance the prosthesis. The finished prosthesis, which is easily maintained by the patient, shows that the unaesthetic, unphysiological defects were successfully corrected (Figs. 13 & 14).

Fig. 14\_ With final prosthesis in place.

## \_Summary

In these presentations, depressed concave ridges—one example in the anterior and the other in the posterior—were corrected using soft-tissue grafts. The results eliminated unaesthetic, dark, depressed food-gathering areas. This technique provides a pre-prosthetic treatment, thus avoiding large pontics, which as illustrated make the area difficult to keep plaque free or cosmetically pleasing. The restorative dentist will then have a positive background to create the aesthetic and physiologic prosthesis.

There must be constant communication between the periodontist, restorative dentist and patient. Detailed techniques must be combined with artistic ideas and tempered with patience.

## \_about the author

cosmetic  
dentistry



**Dr David L. Hoexter** is director of the International Academy for Dental Facial Esthetics, an organisation that combines physicians and dentists with other related fields in research and relates its finding to clinical practice. He lectures throughout the world and has published internationally. He has been awarded 11 fellowships including FACD, FICD and Pierre Fauchard. He maintains a practice in New York City, limited to periodontics, implantology and aesthetic surgery. He can be reached at drdavidlh@aol.com.