

cosmetic dentistry

— beauty & science

4²⁰¹²

| **CE article**

The digitized occlusion:
Using something old with something new

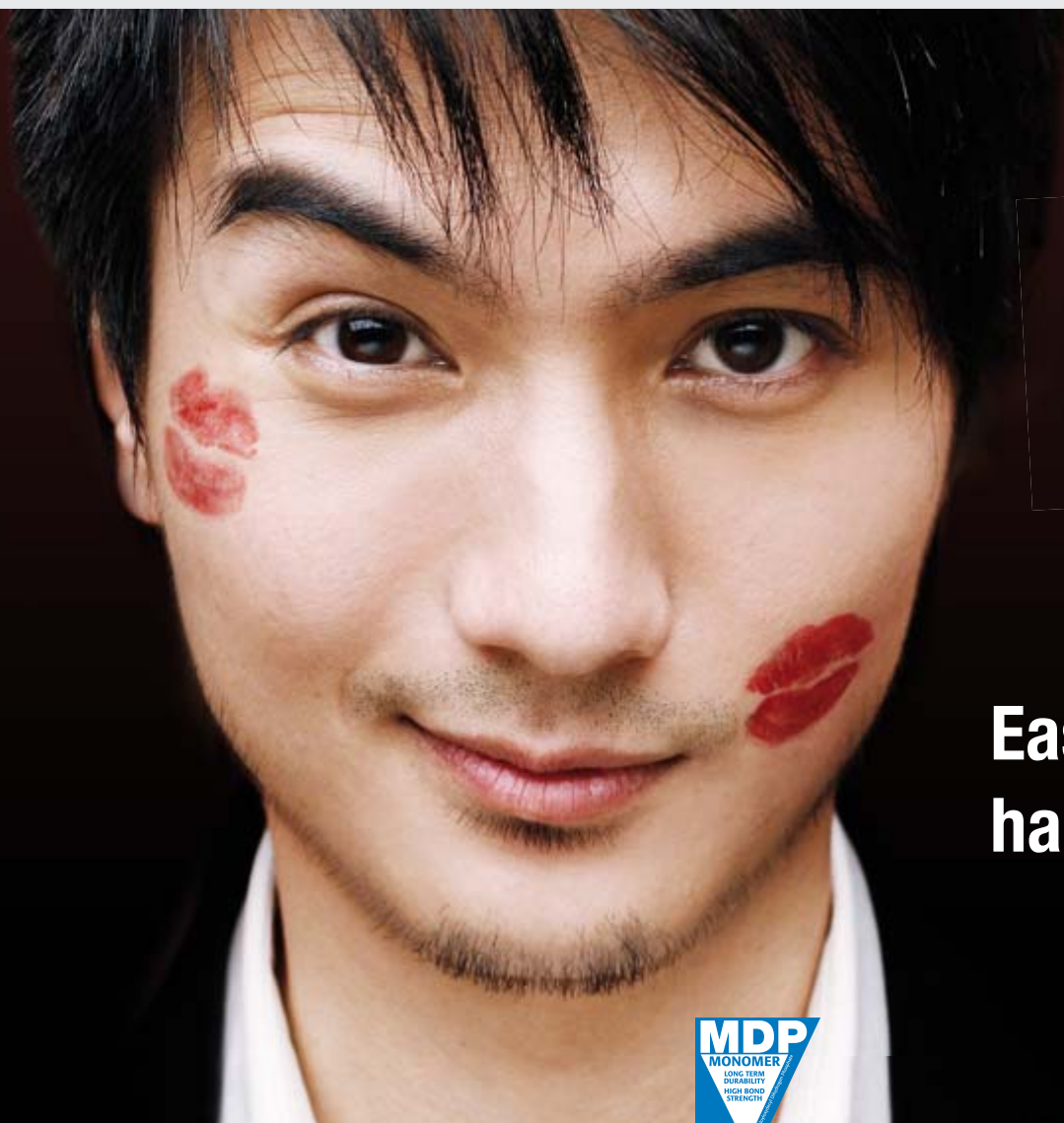| **special**

Cost effectiveness in implant dentistry

| **case report**

The same-day tooth:
From the diagnosis to the final restoration

0377113



Includes indication for
implant restorations!

**Easy to remove –
hard to forget!**



PANAVIA™ SA CEMENT

The self-adhesive resin cement – easy to clean up
excess material whilst creating a strong bond.



SA CEMENT Automix by Kuraray has now been relaunched as part of the PANAVIA™ brand with an expanded range of indications including cementation of restorations on implant abutments.

PANAVIA™ SA CEMENT Automix is a dual-curing, self-adhesive resin cement in an auto-mix syringe for routine restorations - the guarantee for you and your patient's satisfaction. The easy removal of the excess paste reduces the risk of injuring the gingival sulcus and damages of the prosthetic.

This is due to Kuraray's adhesive technology based on a proprietary adhesive phosphate monomer "MDP". This unique adhesive monomer from Kuraray provides high bond strength and secures low technique sensitivity for consistent, reliable results. The high mechanical stability gives excellent marginal seal for long lasting restorations.

The PANAVIA™ brand can look back on a scientific and clinical track record spanning more than 25 years!

Dear Reader,

_As the **Co-Editor-in-Chief** of the official journal of the Asian Academy of Aesthetic Dentistry (AAAD), I am very pleased to announce that the 12th AAAD and 23rd Japan Academy of Esthetic Dentistry (JAED) joint meeting was held in Sapporo, Japan, from 20 to 22 July 2012 under the great leadership of Dr Hisashi Hisamitsu (President of AAAD) and Dr Akira Senda (President of JAED). The scientific programme, including lectures, poster presentations and hands-on workshops, was very well received by the attendees and the social events cultivated a comfortable environment in which to foster friendship among international colleagues.

Many changes, as we well know, are taking place in the dental profession. One of the most significant paradigm shifts in aesthetic dentistry is the emphasis on colour science. Colour measurement of human teeth and restorative materials has become an integral component of both clinical practice and dental research. This change can be traced back to several pioneers who contributed their knowledge and passion to the art and science of colour: Dr Bruce Clark in the 1920s and 1930s, Dr Robert Sproull in the 1960s, Dr Jack Preston and Dr Stephen Bergen in 1970s.

The same passion of these colour pioneers has been kept alive by the Society for Color and Appearance in Dentistry (SCAD), which was founded in 2008 as a consortium of dental professionals and other experts interested in the area of aesthetic dentistry specifically related to scientific investigation and the relationship between colour and appearance. As an active member of SCAD, I personally value the SCAD colour training program (Dental Color Matcher), which is available free online (www.scadent.org). Dental Color Matcher already has thousands of users from over 100 countries. It is a very useful tool for teaching dental students or for continuing education for dental professionals. Therefore I would like to encourage all readers interested in colour related to dentistry to read the 2012 SCAD meeting report which will appear in the next issue.

In this year's last issue of **cosmetic dentistry**, we have virtually kept the best for last. This issue will especially attract our readers interested in implantology. The beautifully illustrated and documented articles cover the whole scope, including diagnosis and treatment planning, surgical procedures and long-term results. Also of interest is the evaluation of cost effectiveness in implant dentistry.

I sincerely hope that you will enjoy this edition and apply your new knowledge to your daily practice successfully. Finally, I would like to thank our valued readers, contributing authors, supporting companies and the **cosmetic dentistry** team for their great support in making our magazine so outstanding!

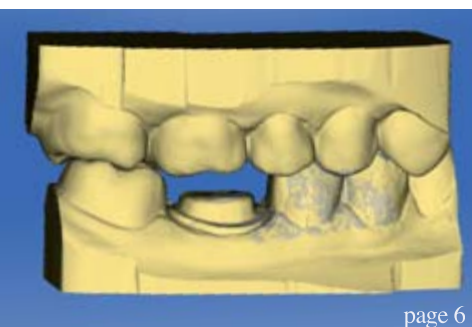
Yours faithfully,

So Ran Kwon

Dr So Ran Kwon
Co-Editor-in-Chief
President, Korean Bleaching Society
Seoul, Korea



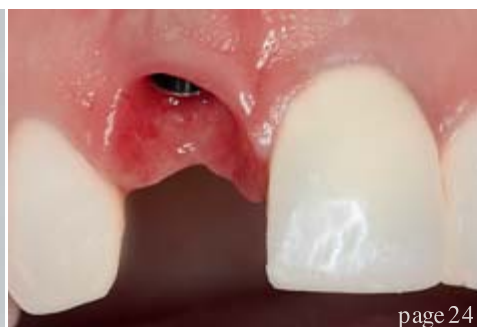Dr So Ran Kwon
Co-Editor-in-Chief



page 6



page 14



page 24

| editorial

03 Dear Reader

| Dr So Ran Kwon, Co-Editor-in-Chief

| CE article

06 The digitized occlusion:

Using something old with something new

| Dr Todd Ehrlich

| special

14 Practical periodontics in daily practice

| Dr Amit Patel

18 Cost effectiveness in implant dentistry

| Prof. Mauro Labanca

| case report

24 The same-day tooth:

From the diagnosis to the final restoration

| Dr Stefanos G. Kourtis

30 Replacement of a single anterior tooth

Surgical procedure and three-year results

| Dr Peter Randelzhofer

34 Modified clinical approach for improved aesthetics in full-arch restoration

| Dr Henriette Lerner, Germany, Prof. Z. Jacobson
& Dr Hugh Flax

| industry news

39 CLEARFIL DC CORE PLUS KIT:

Stressless and reliable

| Kuraray

| meetings

38 ESCD & SSER joint meeting in Bucharest

—Some say “the best!”

| Dr Philip Lewis

40 International Events

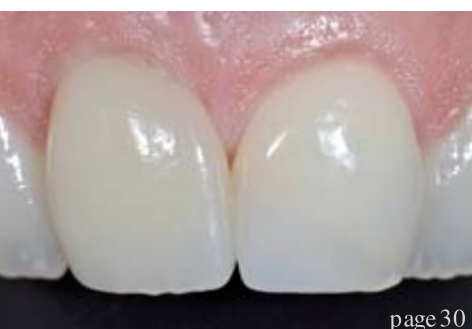| about the publisher

41 | submission guidelines

42 | imprint



Cover image courtesy of Galina Deinega.



page 30



page 39

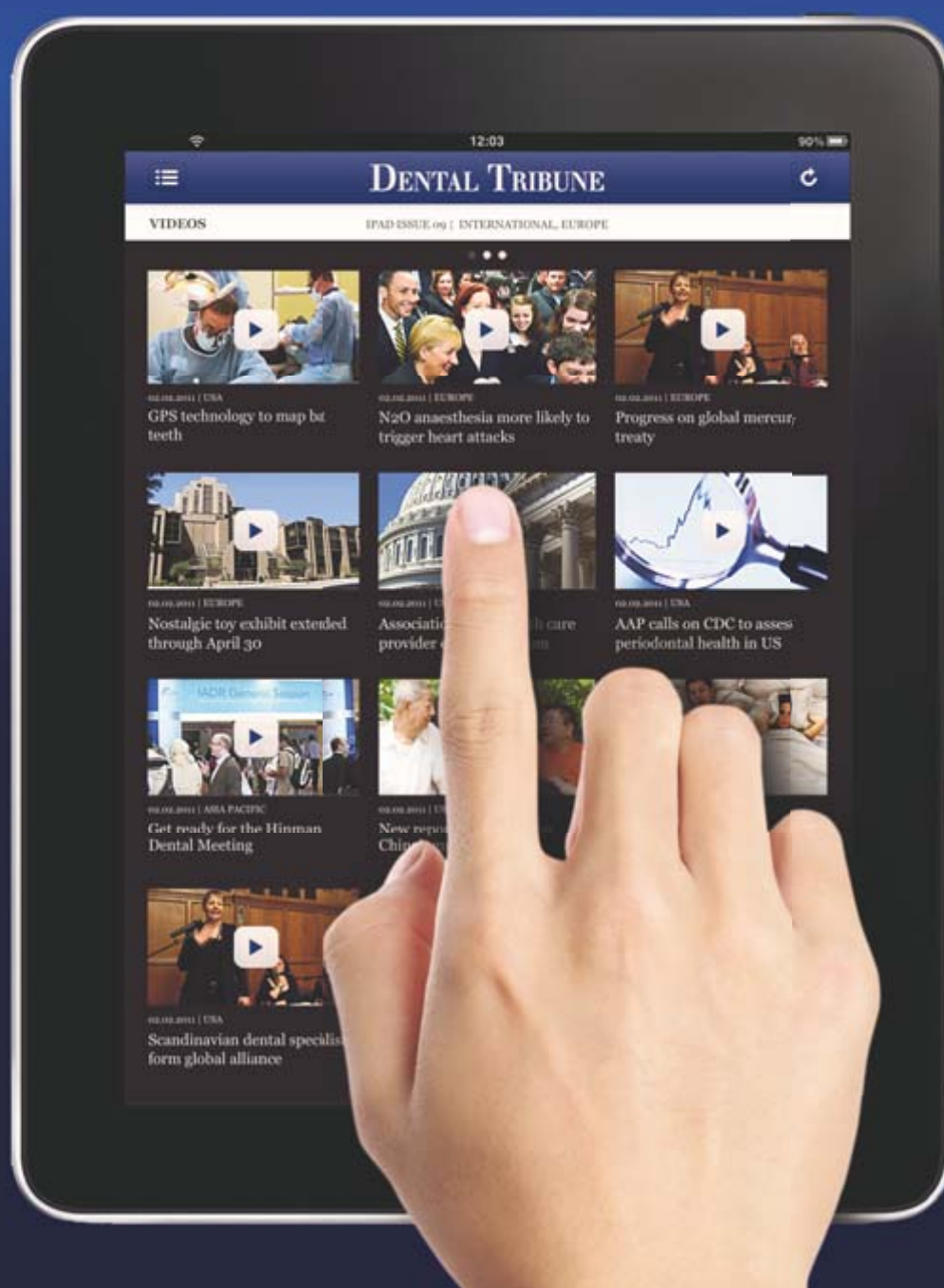

page 40

Dental Tribune for iPad – Your weekly news selection

Our editors select the best articles and videos from around the world for you every week. Create your personal edition in your preferred language.

ipad.dental-tribune.com



DENTAL TRIBUNE

— The World's Dental Newspaper —

The digitized occlusion: Using something old with something new

Author_Dr Todd Ehrlich, USA

Fig. 1 _Tooth #30 being designed in the CEREC Software 4.0.

Fig. 2 _The Biogeneric calculation evaluates adjacent teeth or user-defined teeth.

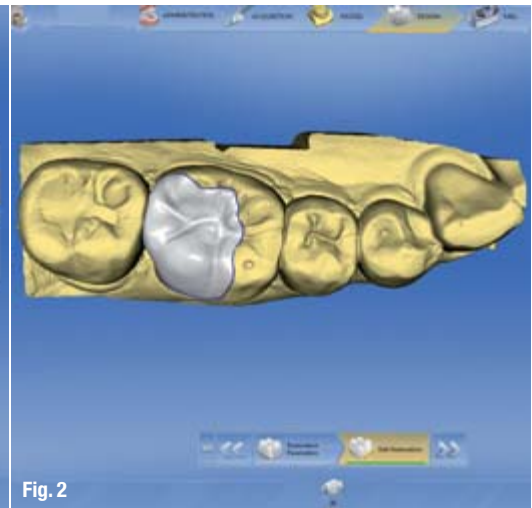
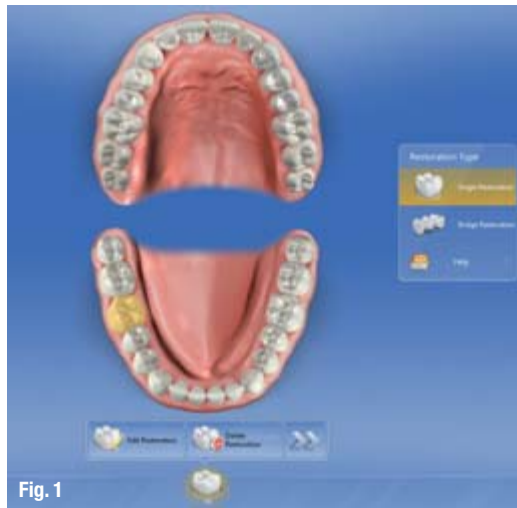


Fig. 3 _Occlusal and interproximal contacts are also taken into consideration.

Fig. 4 _The clinician has control of the "Biogeneric Shape" by scrolling through its database of teeth.

_There is an envelope of occlusal function that we are constantly mastering for our patients. Many times it is exceptionally easy to find a position or shape of a tooth that fits within the patient's comfort and functional zones. However, there are many instances where it can be quite challenging. Using something old with something new can be of great assistance to achieving a

restorative shape that the patient will immediately find comfortable.

_Using something new

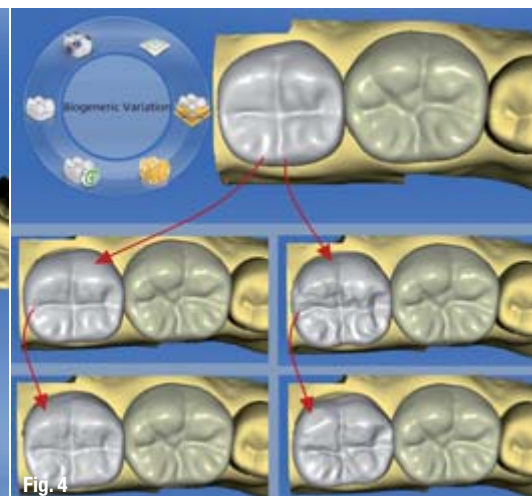

Computerized dental anatomies have greatly evolved over the years. There was a time during CAD/CAM computer design where only limited

_ce credit **cosmetic**
dentistry

By reading this article and then taking a short online quiz, you will gain one ADA CERP CE credit. To take the CE quiz, visit www.dtstudyclub.com. The quiz is free for subscribers, who will be sent an access code. Please write support@dtstudyclub.com if you don't receive it. Non sub-



sscribers may take the quiz for a \$20 fee.



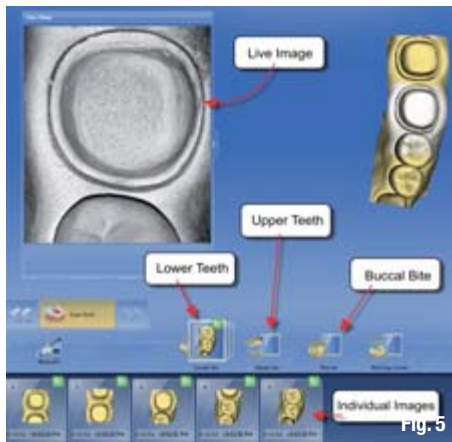


Fig. 5

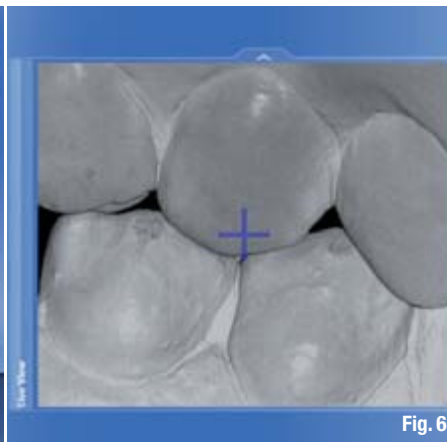


Fig. 6

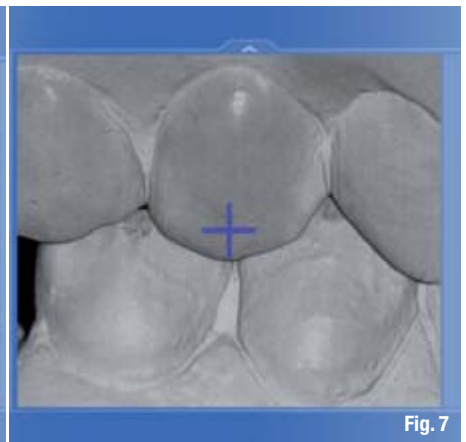


Fig. 7

anatomies were available, and these patterns had to be manipulated greatly by the doctor to fit the clinical situation. This made for a longer design time and, most importantly, made the restoration appear more natural.¹ Today, there are more advanced mathematical calculations for dental anatomy.

Modern tooth-modeling software uses a database detailing the measurements of several thousand naturally occurring tooth samples. Common structures such as cusp tips, cusp slopes, marginal ridges and fissures give the blueprint for computer determination of the "average tooth." The differences between this average tooth and the scanned referenced teeth make up the core for the mathematical calculation, much like with facial recognition software used by government intelligence agencies. Analysis reveals that only 20 data location points are necessary to describe 83 per cent of the variability in naturally occurring tooth surfaces.^{2,3,4,5} This mathematical calculation for tooth morphology therefore predicts the virgin state of the tooth.

It has been shown to have a digitally proposed surface within 156 μ of the original surface.¹ Be-

cause the described process obtains its results through data derived from naturally occurring teeth, the method is referred to as "Biogeneric tooth modeling."^{2,3}

This mathematical calculation of dental anatomy starts with designating the tooth number to be designed. This establishes which database of dental anatomies that it will use to determine the calculations. In other words, the true tooth number needs to be selected for the calculation, or a different tooth number anatomy will be generated (Fig. 1).

The next step for the calculation is to show the computer a tooth that it can use for guidance on the proposed design. This can be done a couple of ways. Primarily, a tooth within the prepared quadrant (not the prepared tooth) will be analyzed automatically by the computer, and is typically the distal neighbor of the prepared tooth (Fig. 2). If the clinician knows of a better tooth to reference, this can easily be selected within the prepared arch, within another area of the dentition, or even off a model. This referenced dataset will trigger the computer to search the entire database, which may contain hundreds of different virgin anatomies for that particular tooth number.^{2,3,4}

Fig. 5 Digitally scanned teeth are organized into specific libraries.

Fig. 6 During imaging, the position of the upper and lower teeth is not correct and space is seen.

Fig. 7 The dentist sees the error and instructs the patient to close properly.

Figs. 8 & 9 The buccal bite images are used to articulate the upper and lower models.

Fig. 10 The digital articulation is completed.

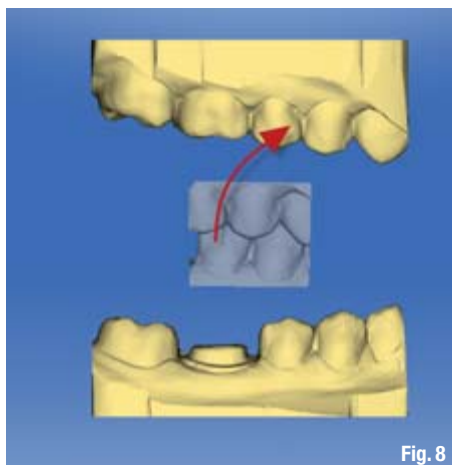


Fig. 8

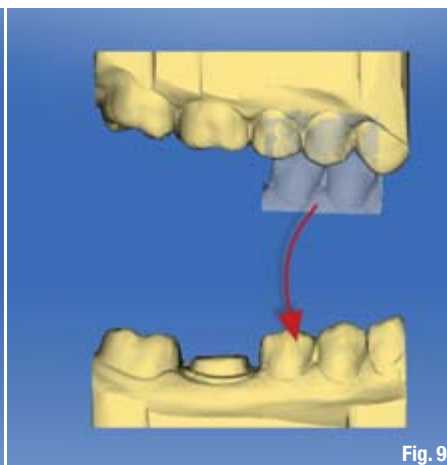


Fig. 9

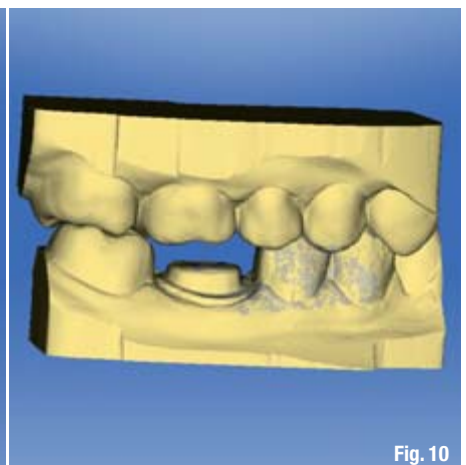


Fig. 10

The computer proposal will morph into various shapes as it is going through the calculation. It also looks for ratios of tooth size and position within the arch. This is a great advantage, because these digital dental anatomies are not limited by size, but can fit within any range of tooth dimensions. The finalized digital anatomy is a reflection of what the computer discovered through its analysis of the reference tooth. It also places the three-dimensional shape in contact with the opposing teeth (Fig. 3). If the clinician would like to see variations of the Biogeneric calculation, a slider allows that to happen. This tool is referred to as "BiogenericVariation." If images have to be re-taken, "BiogenericVariation" is the new name (Fig. 4). The slider travels through

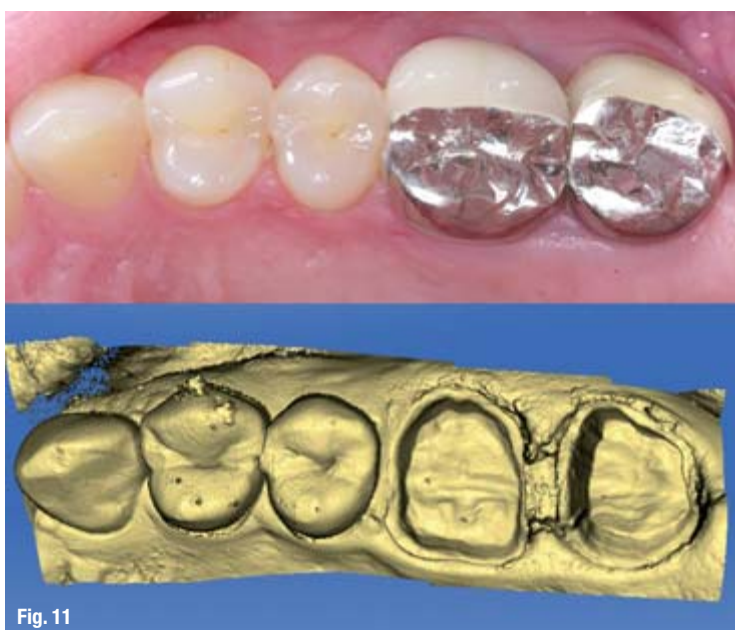


Fig. 11

Fig. 11 _The prior crowns are removed and teeth prepared.

anatomies within the Biogeneric database and reveals them through morphing of the proposal. This allows for a truly customized shape for the clinical situation, and within function.

Digital scanning

During the course of treatment, the upper and lower arches or quadrants are scanned into the computer using the CEREC Bluecam digital scanning camera. The CEREC system can have multiple preparations within the same arch or in opposing arches. Each arch is saved in its corresponding library of images within the software and evaluated for quality of margin integrity, path of draw, preparation geometry, etc. (Fig. 5). The major advantage of digital impressions is that the physical impression is eliminated from the process. This allows for immediate feedback to the clinician if the information is correct, rather than waiting to evaluate the inverse of the physical impression many minutes later.

There are never any tears or bubbles with digital impressions. They also never distort. Therefore, they have tremendous value to the doctor and the patient, especially because the images are taken so easily and within a minute. After the upper and lower arches are captured, they are articulated by images taken from the buccal direction.

The articulation for the upper and lower jaws is done in a static maximum intercuspation position utilizing what is referred to as the "buccal bite." This would be similar to a triple tray type using physical impression material, but by doing it digitally, the position never changes. Articulation of the models is completed within the software, and the maximum intercuspation position is always repeatable. There is never flex or variation with the articulator because of its digital nature. Therefore, if taken correctly, the buccal bite can place the maxillary and mandibular teeth in a very specific position that can be designed to within microns of space.⁵ Another major advantage of an optical buccal jaw registration is that the position can be seen in the computer as the scan is taking place, much like when preparation images are being taken.

How many times does a patient try and help the procedure by biting toward the area of work during an impression? Or, can you even find their centric occlusion through impression material and while anesthetized? The relation is hidden under physical impression material, and may not be realized until physical stone models are mounted on an articulator. However, with digitally scanned articulation, it can easily be seen that it may be incorrect, or the jaws are not stable, during the imaging (Fig. 6). The clinician simply stops the scan, coaches the patient into the proper position, and then scans again (Fig. 7). This greatly enhances the predictability of occlusion of the final restoration.

The operator takes control of the articulation of the three models: upper, lower and buccal bite. The buccal bite is dragged to the corresponding portions of the upper and lower models. The software then recognizes similar surfaces and "shrink wraps" the buccal bite down. The same is done for the opposing arch. This establishes the digital maximum intercuspation position within the software (Figs. 8–10).

The repeatable digital maximum intercuspation position also allows for multiple units to be designed in a highly predictable manner. Whether the restorations are being designed side by side or from one arch to another, the occlusal morphology and pinpoint placement of occlusal stops can be confidently placed knowing the arches are stable within the digital world.

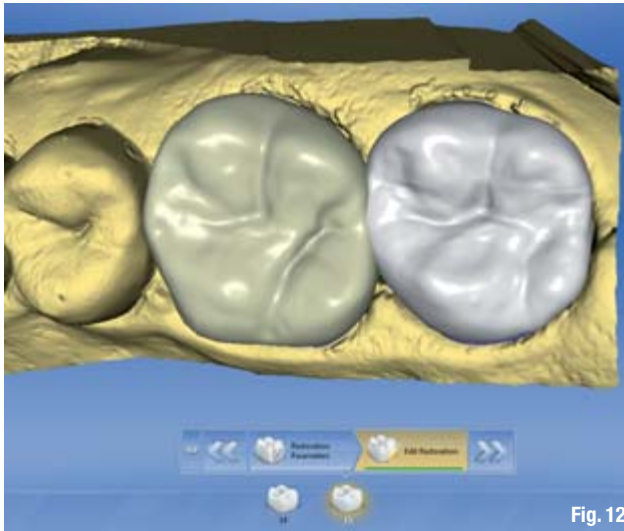


Fig. 12

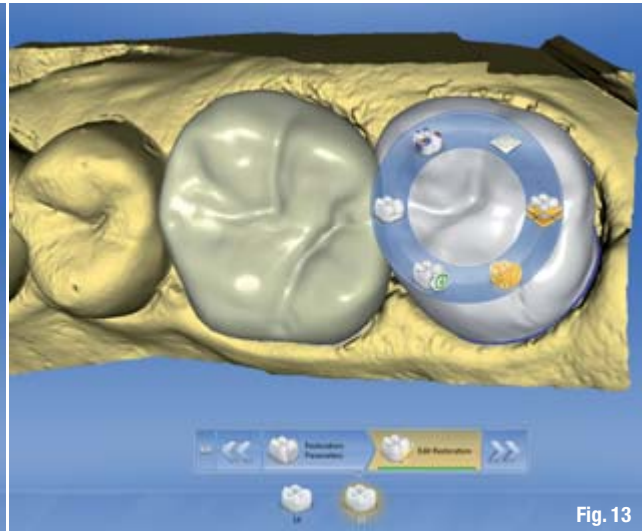


Fig. 13

_Case 1

A 45-year-old female presented with two porcelain-fused-to-metal crowns with recurrent caries on tooth numbers 14 and 15. They were estimated to be about five years old. Her chief complaint was that it was difficult to floss between them. Clinically, the crowns had very tight interproximal contacts and closed embrasures. Dental floss was nearly impossible to penetrate through the contact, and recurrent caries subsequently developed (Fig. 11). The crowns were removed, core build-ups completed, and the intraoral scans taken:

- _Preparation quadrant (upper left);
- _Opposing quadrant (lower left);
- _Buccal bite images.

The models within the CEREC Software 4.0 were articulated, and the Biogeneric calculation was com-

pleted for the two teeth. Because the interproximal contacts were of utmost concern for the patient, both designs were manipulated at the same time to achieve better contact strength and embrasure shape. The interproximal contact between 13 and 14 was designed to mimic the same shape between 12 and 13. The initial Biogeneric proposal for #15 placed the mesial portion into the distal of #14 (Figs. 12, 13). Right-clicking the proposal brought up the myriad of tools to adjust the proposal (Fig. 14). A tool was selected that would reposition just the mesial portion of #15. It could then be repositioned in any direction (Figs. 15, 16). It was simply moved distally. A broader contact was established between the two designs, but with better embrasures than the prior crowns. Minor customization of the occlusal scheme was then done.

The digital crowns were milled with CEREC's MCXL milling chamber out of IPS e.max CAD blocks (Ivoclar Vivadent). Each crown milled in roughly 10 minutes

Fig. 12_ The initial proposals for 14 and 15 were excellent; however, 15 encroached into 14.

Fig. 13_ A design tool wheel emerges when right-clicking on the design.

Fig. 14_ The mesial portion of 15 was selected for movement.

Fig. 15_ The mesial portion was moved into the appropriate position.

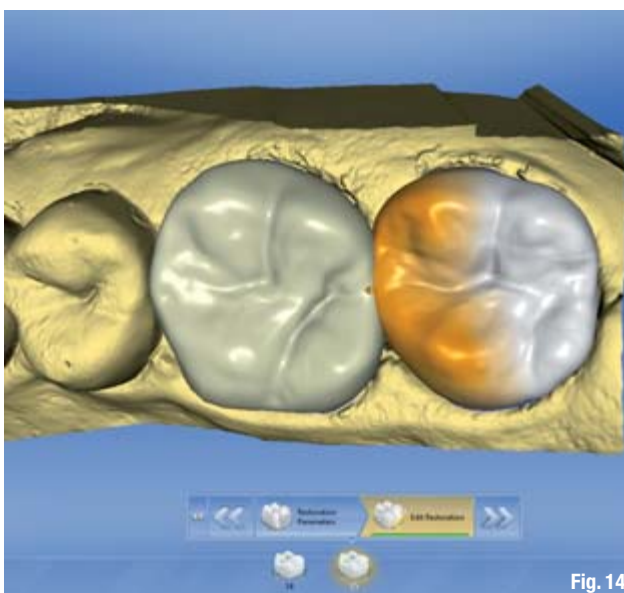


Fig. 14




Fig. 15