

# cosmetic

## dentistry \_ beauty & science

1 2013

**| CE article**

Bioactive materials support proactive dental care

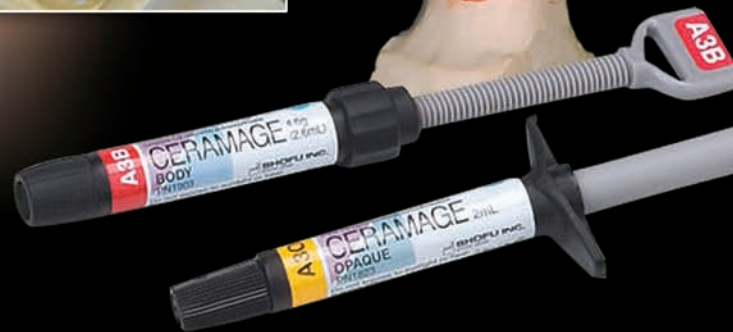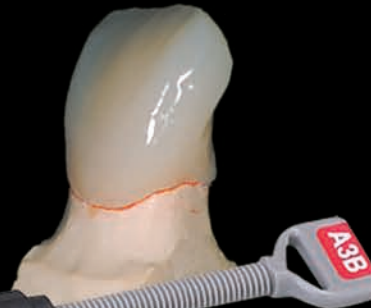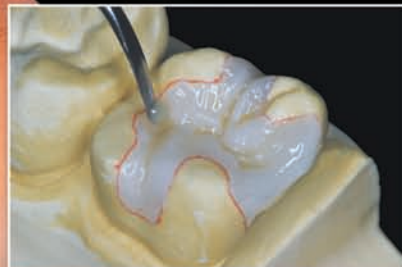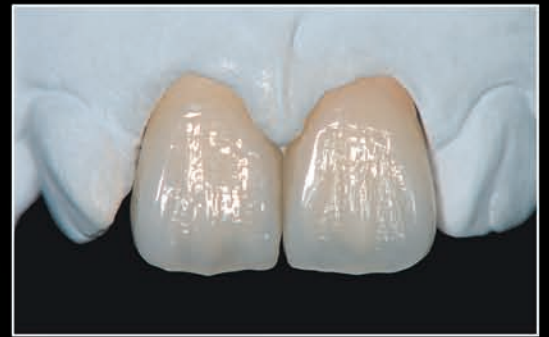**| special topic**

Deep resins, white fillings:  
A new technique for composite restorations

**| industry report**

Lasers in aesthetic dentistry

# Aesthetics of Your Choice



## CERAMAGE ...

*A superior Indirect Composite  
with Ceramic-Like aesthetics for  
Anterior & Posterior Restorations.*

For more information, please contact your  
nearest SHOFU dealer.



Official Partner



Minimally Invasive  
Cosmetic Dentistry

**SHOFU INC. SINGAPORE BRANCH**

Tel (65) 6377 2722 Fax (65) 6377 1121

eMail [mailbx@shofu.com.sg](mailto:mailbx@shofu.com.sg) website [www.shofu.com.sg](http://www.shofu.com.sg)

# Dear Reader,

**Happy New Year for 2013!** May you always have health and happiness in your life.

2012 was very busy for the MICD team. We travelled to various places in Asia to promote the MICD concept and slogan, "Enhancing smiles with minimal biological cost". Our team was invited to many countries to deliver lectures and to conduct hands-on training. It is very gratifying for me to observe that the take-up of the MICD concept around the world has increased rapidly.

I have applied the MICD concept to the majority of worn smile redesign cases that I have treated. Worn smiles may have a negative impact on patients' psychology, health, function and aesthetics. I have noticed in my practice that the demand for treatment of worn smiles has increased dramatically over the past decade, and I think that other dentists have probably observed this too. A combination of factors such as chemical erosion, abrasion, para-functional habits and occlusal prematurities are major causes of worn smiles. Redesign of worn smiles is one of the most complex clinical situations in dentistry and requires detailed examination and evaluation of the patient's diet, history, eating disorders, behavioural factors, para-functional habits, and complete analysis of teeth, muscle, joint and airway (TMJA) harmony, and meticulous treatment planning to achieve the desired function and aesthetics with minimal biological cost.


There are various clinical techniques in oral rehabilitation. Conventional methods use full-coverage crowns that require aggressive tooth preparation and generally have high biological, financial and time costs. However, with the advancement of science and technology in adhesive restorative materials and the availability of digital occlusal analysis technology that can measure precisely different clinical parameters of the underlying force components in a dynamic state, clinicians can treat even complex oral rehabilitation in non or minimally invasive ways so that the biological cost of the treatment can be drastically reduced.

In my practice, I use resin composites in the majority of worn smile redesign cases and I follow the MICD full-mouth rehabilitation protocol, which has four logical clinical steps: 1. develop anterior aesthetics and guidance; 2. establish posterior teeth supports; 3. customise case finishing (aesthetic and force finishing); and 4. recheck para-functional habits.

Once I have restored the smile aesthetics and built up the posterior teeth supports, I customise case finishing. First, I perform the necessary aesthetic finishing, as it is visible to others and can be most appreciated by the patient, then in order to harmonise the occlusal force component I perform digital occlusal analysis and the force finishing of the case. The final step entails rechecking for the absence or presence of para-functional habits (bruxism and clenching) by asking the patient to wear a BruxChecker for three to four nights. After this period, if grinding patterns are visible on the BruxChecker, I always suggest wearing a thin night guard to the patient. I think the reader will find these simple clinical steps for redesigning worn smiles with minimal biological cost useful.

In this new issue of **cosmetic dentistry**, we have gathered a variety of quality clinical articles. I hope you will enjoy reading them.

Yours faithfully,



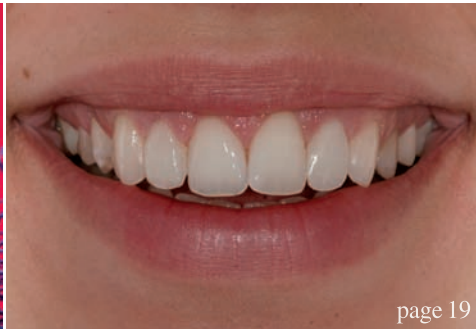Dr Sushil Koirala  
Editor-in-Chief  
President Vedic Institute of Smile Aesthetics (VISA)  
Kathmandu, Nepal



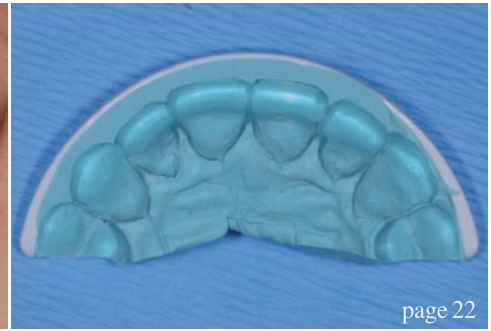
Dr Sushil Koirala  
Editor-in-Chief



page 12



page 19



page 22

**| editorial**

03 **Dear Reader**  
| Dr Sushil Koirala, Editor-in-Chief

**| CE article**

06 **Bioactive materials** support proactive dental care  
| Dr John C. Comisi

**| special topic**

12 **Deep resins, white fillings:**  
A new technique for composite restorations  
| Dr Irfan Ahmad

19 **Conservative smile enhancement:** Direct composite resin restoration of conoid lateral incisors  
| Dr Monika Marciniak

**| industry report**

22 **Improving success with your cosmetic cases** using the TMJ QuickSplint  
| Dr John F. Weston

26 **Restoration of orofacial aesthetics:** A new multidisciplinary concept  
| Drs Hermes Pretel, Jackson Lins & Ismael Drigo Cação

30 **Lasers in aesthetic dentistry**  
| Drs Ilay Maden, Zafer Kazak & Özge Erbil Maden

34 **Stop hurting your patients!**  
| Dr Steven G. Goldberg

36 **What constitutes new technology?**  
**Water flossing revisited**  
| Deborah M. Lyle

**| industry news**

40 **Kuraray Noritake Dental** proudly presents **world-first innovations** in dentistry at IDS 2013  
| Kuraray

**| news**

42 **ESCD tenth anniversary** international meeting  
| Dr Luca Dalloca

**| meetings**

44 **The annual conference of the Society for Color and Appearance in Dentistry**  
| Dr So Ran Kwon

46 **International Osteology Symposium in Monaco**  
| Interview with Prof. Niklaus P. Lang & Prof. Massimo Simion, congress chairmen

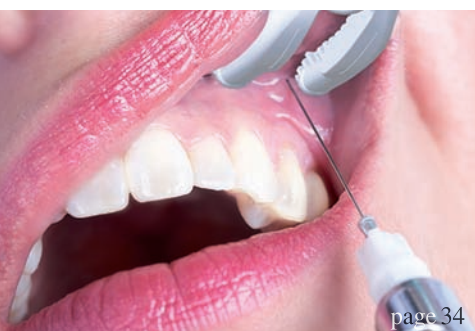
40 **International Events**

**| about the publisher**

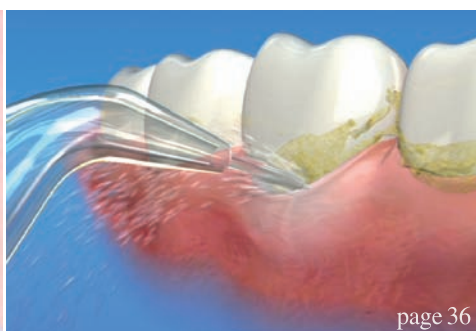41 | submission guidelines  
42 | imprint



Cover image courtesy of Yuri Arcurs



page 34



page 36



page 46

**kuraray**

*Noritake*

**Come and try our  
new product at IDS!**

Hall 11.3 · Booth D 010

**Just  
blend in!**


## **CLEARFIL MAJESTY™ ES-2**

**You'll just be amazed by the blending effects every time you use this intuitive composite concept.**

Start working with the new universal CLEARFIL MAJESTY™ ES-2 and something surprising will happen. We re-engineered the color system to make it simply intuitive. Just pick your VITA™ approved colors and start designing nature. To create the perfect adaption to the tooth, we further optimized the consistency. This will give you great confidence during layering. Especially when using our new Premium Enamel and

Dentin colors to naturally layer your restoration. After finishing you will just be amazed by the blending effect.

To create this unique restorative workflow, we used the latest pioneering technologies to make your restorations better, more predictable and longer lasting.

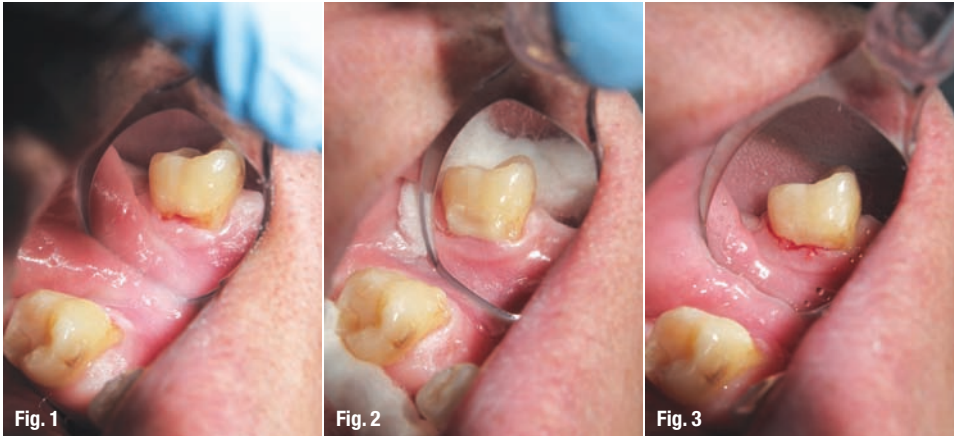


For more information +49 (0) 69-305 35833 or [www.kuraray-dental.eu](http://www.kuraray-dental.eu)

**SCIENCE.KNOWLEDGE.SUPPORT.**

# Bioactive materials support proactive dental care

Author\_Dr John C. Comisi, USA



fied adhesives and dual-/auto-cured composites in direct restorations and the use of resin cements for luting of indirect restorations.

The term "water-tree" formation has been coined to describe this process, which originated from the tree-like deterioration patterns that were found within polyethylene insulation of underground electrical cables. It is now being applied to the water blisters formed by the transfer of dentinal fluid across the dentin-bonding interface. These "water blisters...

act as stress raisers and form initial flaws that cause subsequent catastrophic failure along the adhesive composite interfaces."

The previously mentioned plasma proteins are released by the dentin when subjected to acids and cause hydrolytic and enzymatic breakdown of the dentin and resin bonding agent interface.<sup>5</sup> These enzymes are called matrix metalloproteinases (MMPs).

Currently, there are only three methods of reducing these MMPs: 2 per cent chlorhexidine solutions that are used prior to application of bonding agents; etchants containing benzalkonium chloride, otherwise known as BAC (i.e., Bisco's Uni-etch products); and polyvinylphosphonic-acid-producing products (glass ionomer and resin-modified glass ionomers).

Due to the short efficacy of these chlorhexidine solutions being used before bonding, this methodology has come into question as of late.<sup>6</sup> Etchants with BAC have been shown to be valuable in the reduction of MMPs and should be considered in all bonding processes.<sup>7</sup> However, the most intriguing methodology of reducing MMPs and remineralizing tooth structure is with the use of glass ionomer cements (GIC) and resin-modified glass ionomers (RMGIC).

**\_Resin bonding of the human dentition** has become a "standard" in the United States and Canada. There are more than 80 different bonding systems on the market today. We have seen them evolve through multiple generations in an attempt to "simplify" the bonding process. Yet, as these agents have simplified, many in our profession have seen many challenges arise.

A significant number of reports in the literature have been showing that the "immediate bonding effectiveness of contemporary adhesives are quite favorable, regardless of the approach used (however) in the long term, the bonding effectiveness of some adhesives drops dramatically."<sup>1</sup> The hydrophilicity that both etch-and-rinse and self-etch bonding agents offer initially in the dentin-bonding process becomes a significant disadvantage in terms of longterm durability.<sup>2</sup>

It is this hydrophilicity of simplified adhesive systems combined with other operator-induced challenges that contribute to these failures. Tay, Carvalho, Pashley, et al. have reported repeatedly in the literature of this problem.<sup>3,4</sup> They continue to report that these bonding agents do not coagulate the plasma proteins in the dentinal fluid enough to reduce this permeability. The fluid droplets contribute to the incompatibility of these simpli-

(Photos/Provided by Dr John C. Comisi unless noted otherwise)

\_ce credit **cosmetic** dentistry

By reading this article and then taking a short online quiz, you can gain ADA CERP CE credits. To take the CE quiz, visit [www.dtstudyclub.com](http://www.dtstudyclub.com). The quiz is free for subscribers, who will be sent an access code. Please write [support@dtstudyclub.com](mailto:support@dtstudyclub.com) if you don't receive it. Non-subscribers may take the quiz for a \$20 fee.



## Glass ionomers and resin-modified glass ionomers

Glass ionomer cements have long been used as a direct restorative material. Their early formulations made the material difficult to handle, and the break down of the material made it an undesirable solution in dental restoration. However, these materials, especially in today's formulations and pre-encapsulated presentations, have many properties that make them very important in the restorative process.

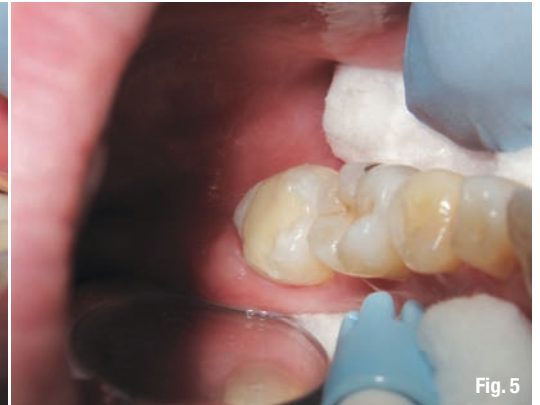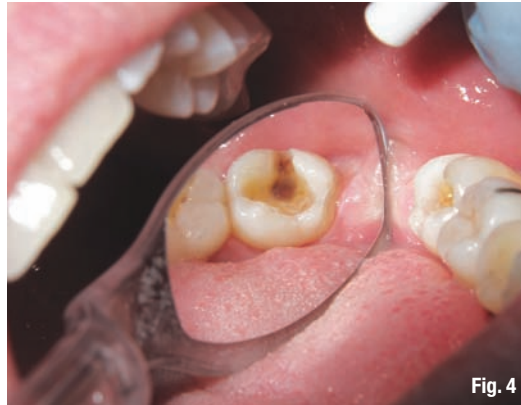The work at companies such as SDI North America (Riva product line), GC America (Fuji product line) and VOCO (Iono product line) have continued to make great strides in improving these products for easier and longer-lasting use of GIC and RMGIC products.

First, these materials are bioactive, and up until recently, they were the only materials with this property; that is they have the capacity to interact with living tissue or systems. Glass ionomers release and recharge with ions from the oral cavity.

This transfer of calcium phosphate, fluoride, strontium and other minerals into the tooth structure helps the dentition deal with the constant assault of the acidic nature of day-to-day ingestion of food and beverages and encourages remineralization; and the incorporation of phosphorous into the acid in today's GICs creates polyvinylphosphonic acid.<sup>8</sup>

This property of GICs makes them a major agent in the reduction of MMP formation, and thereby minimizing if not eliminating the collagen breakdown commonly found in many resin-dentin bonding procedures.<sup>9</sup>

Second, they bond and ultimately form a union with the dentition by chemically fusing to the tooth. The combination of the polyacrylic acid and the calcium fluoroaluminosilicate glass typically found in GICs reacts with the tooth surface, which releases calcium and phosphate ions that then combine into the surface layer of the



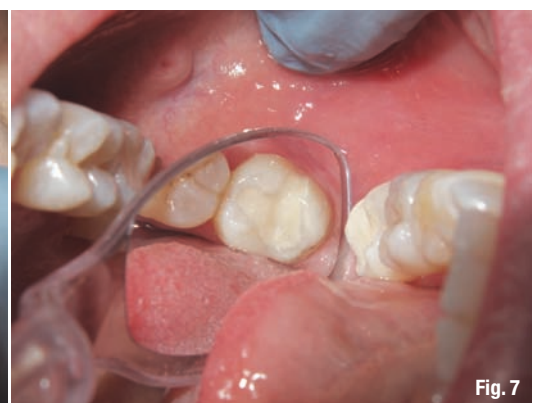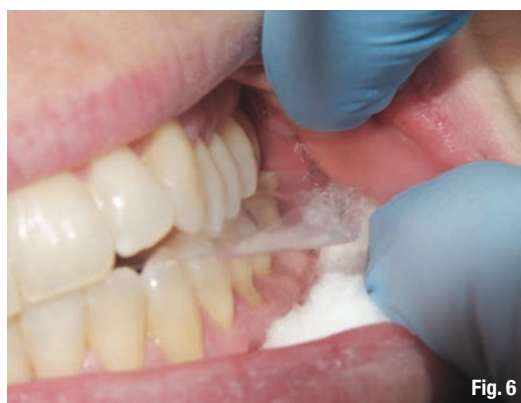GIC and forms an intermediate layer called the "interdiffusion zone."<sup>10</sup>

No resin bonding agents are required due to this chemical fusing to the tooth structure. This ion release helps inhibit plaque formation and provides an acid buffering capability that helps to create a neutralization effect intraorally. In addition, these GICs have very good marginal integrity with better cavity-sealing properties, have better internal adaption and resistance to microleakage over extended periods of time, have no free monomers, can be bulk filled and offer excellent biocompatibility.<sup>11</sup>

Another important consideration is that GICs are moisture-loving materials, which makes them very sensible for use in the intraoral cavity.

The transfer of dentinal fluid from the tooth to the GIC essentially creates a "self-toughening mechanism of glass ionomer based materials... serves to deflect or blunt any cracks that attempt to propagate through the matrix [and]... plays an adjunctive role by obliterating porosities [which] delay the growth of inherent cracks in the GIC under loading."<sup>4</sup>

The intermediate layer of the GIC provides flexibility during functional loading and acts as



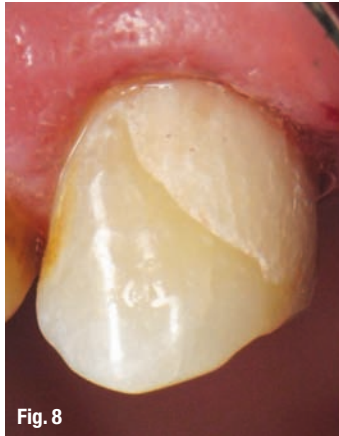

Fig. 8

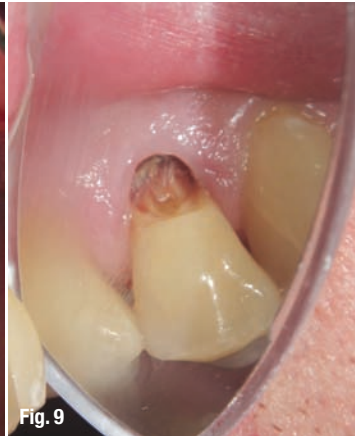

Fig. 9

a stress absorber at the interface of the restoration and the tooth.<sup>12</sup>

Resin-modified glass ionomers (RMGIC), which are a hybrid of traditional glass ionomer cements with a small addition of light-curing resin, exhibit properties intermediate of the two materials.<sup>13</sup> This material has been shown to have properties similar to GIC, but with better esthetics and immediate light cure. RMGICs have been shown to undergo slight internal fracturing from polymerization shrinkage, yet have an inherent ability to renew broken bonds and reshape to enforce new forms.<sup>12</sup>

Application of RMGIC to all cut dentin in Class II composite restorations has been shown to "significantly reduce micro-leakage along (the) axial wall" of the restoration,<sup>14</sup> and helps prevent bacterial invasion of the restored tooth. RMGIC bio-materials are multifunctional molecules that can adhere to both tooth structure and composite resin, thus providing an improved sealing ability by chemical or micromechanical adhesion to enamel, dentin, cementum and composite resin.

They, like GICs, can be bulk filled to reduce the amount of composite necessary to restore the cavity preparation and act as dentin substitutes in the restoration.<sup>15</sup>

The use of GIC and RMGIC in the restoration of posterior Class V restorations and conservative Class I restorations provides many benefits. They are easy to place and reasonably forgiving, even in a slightly moist environment. They should be placed in a moist but not wet environment, so familiarity with technique is imperative as it is with all dental restorations. I will often use Riva SC (SDI) or Fuji 9 GP Extra (GC America) in posterior Class I and V restorations (Figs. 1–7).

Polishing and shaping of the materials must be done with water spray and fine/ultra fine composite finishing burs and polishers so as not to destroy the surface of the material (Fig. 8). The use of RMGIC products, such as Riva LC or Fuji II LC, is great in bicuspid and anterior Class V restorations, especially in high caries prone patients (Figs. 9–12).

Class II restorations, however, have always presented a challenge to the clinician. If the operator wanted to use GIC or RMGIC, there was no easy way to do this that appeared to provide satisfactory results. It is with this in mind that the "sandwich technique" was developed.

It was thought that using the properties of GIC to bond to the tooth and then applying resin-bonding agents and composite to the set GIC could help reduce sensitivity and bond failures typically seen in many resin-bonded composite (RBC) techniques.

Typically, the GIC is placed in the preparation, allowed to set, cut back to ideal form and then bonded to with an RBC technique. However, the inability of RBCs to adhere to the set GIC often creates many failures. The materials by themselves are incompatible over the long term.

The modified sandwich technique evolved as a means to overcome this problem. Placing RMGIC over set GIC—and then adding a RBC to that—provided a better solution, but was as laborious and time consuming to do, as is the sandwich technique.

### The 'Co-Cure Technique'

In 2006, an article was published<sup>16</sup> that, in my opinion, has revolutionized the way I approach direct posterior restorations and direct restorations as a whole. The article presented a radical approach to direct posterior

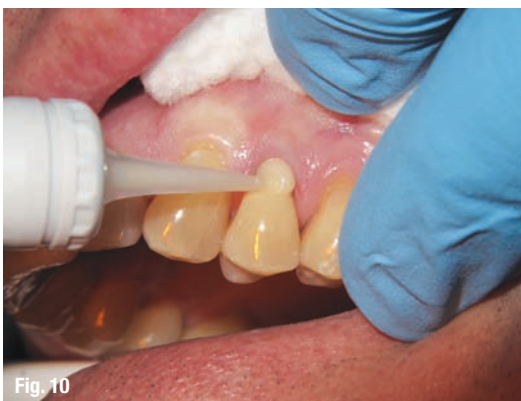

Fig. 10

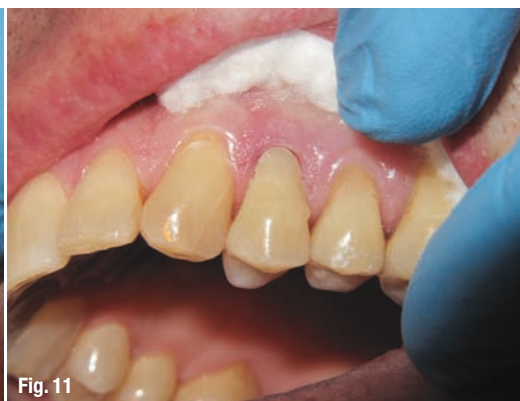

Fig. 11



restorations, called the Co-Cure Technique. This technique is defined as the simultaneous photo-polymerization of two different lightactivated materials that involves "the sequential layering of GIC, RMGIC and composite resin prior to photo-polymerization and before the initial set of the GIC [which] enables an efficient single-visit placement of a [direct] restoration..."<sup>16</sup>

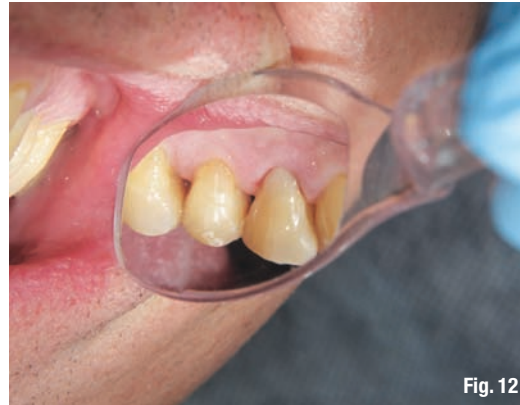

Fig. 12

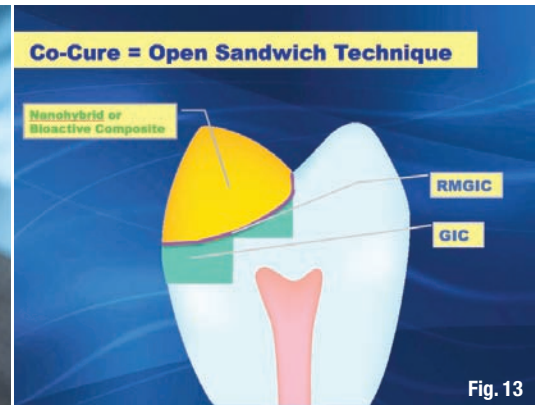


Fig. 13

In the Co-Cure Technique, the composite restoration does not require a bonding agent because the bonding agent is essentially the RMGIC. The RMGIC acts as the interface between the GIC and the composite material. It combines the GIC, RMGIC and composite in a way to form what can best be described as a "monolithic biomimetic restoration."

This restoration is an "open sandwich" type of sandwich technique. That is, the GIC component is exposed to the oral environment (Fig. 13) at the gingival portion of the restoration. It is quickly and efficiently accomplished and has significantly reduced postoperative sensitivity compared with typical direct RBC techniques. I have been placing these types of direct posterior restorations since 2008. They have become the cornerstone of my practice.

#### *Technique procedure (Fig. 14)*

After placement of an appropriate dental matrix, the technique incorporates the use of 37 per cent phosphoric acid to prepare the tooth for restoration. The acid is essentially "flooded" into the preparation in a similar manner to doing a "total-etch" RBC. It is, however, washed off after five seconds of placement. The tooth is then dried but not desiccated. The area remains slightly moist because the GIC that will be placed next is hydrophilic.

Fill the preparation with the triturated GIC material up to the level of the DEJ, then immediately place the triturated RMGIC in a very thin layer to cover the GIC and walls of the preparation. Finally, place the composite over the previous materials to slightly overfill the preparation. With a large round burnisher dipped in an unfilled resin material (i.e., Riva Coat by SDI or G-Coat by GC), wipe away the excess GIC and composite restoration material to create your margins and prevent ditching and white lines.

The occlusal table of the restoration can then be compressed gently with a plastic occlusal matrix by either having the patient bite or by the operator pressing gently with his thumb or forefinger to improve the coalescence of the three materials. This can help reduce the time involved in creating the final occlusion of the restoration by creating a functional occlusal table.

The restoration is then cured for 30 to 40 seconds with an LED curing light that generates at least 1,500 mW/cm<sup>2</sup>. Appropriate light output is critical for all direct cured restorations, and assurance that appropriate output is provided by the curing light is needed for complete cure of any direct restoration.

The restoration is evaluated for complete cure and then a layer of an unfilled resin is placed on the exposed GIC/RMGIC/composite complex and cured for an additional 10 seconds. The matrix band is removed and the restoration is trimmed and polished as any typical RBC restoration would be.

I have found that an entire three-surface posterior restoration can be accomplished in less than three minutes once the matrix has been placed. Typically, finishing the restoration can also be done in less than three minutes. This makes the direct posterior restoration quite efficient and beneficial to the clinician and the patient because we are providing a restoration that will help enhance healing of the dentition and reduce recurrent decay and restorative failure.

#### **\_Nanotechnology in dental materials**

Nanotechnology involves the production of functional materials and structures in the range of 0.1 to 100 nanometers by various physical or chemical methods. Today, the development of nanotechnology has become one of the most highly energized disciplines in science and technology because it can stimulate the creation of many new