

IMPLANT TRIBUNE

— The World's Dental Implant Newspaper • U.S. Edition —

NOVEMBER 2014 — VOL. 9, No. 11

www.dental-tribune.com

AAID wants you to feel the magic



The American Academy of Implant Dentistry will host its 63rd Annual Implant Dentistry Educational Conference beginning Nov. 4 in Orlando, Fla.. Photo/www.freeimages.com

Annual conference to be held in Orlando this year

By AAID Staff

The American Academy of Implant Dentistry's 63rd Annual AAID Implant Dentistry Educational Conference aims to shine a light on the magical artistry and science of dental implant practice in a naturally magical location: Orlando, Fla.

Beginning on Wednesday, Nov. 4, the AAID conference aims to set the curve in implant dentistry. This year's AAID Implant Dentistry Educational Conference Keynote Speaker, Nina Tandon, PhD, will intrigue, motivate and challenge the current thinking of implant dentistry and more.

In her eye-opening keynote address, she will explain the process of growing tissue and transplants, and the future of medical science. With the help of manufacturing and information technology, we are on the verge of being able to grow human tissue. Her presentation, "Body 3.0," is all about growing our own body parts.

The entire day on Wednesday will be devoted to the future of implant den-



Dr. Stephen J. Chu speaks on 'Implant Placement Adjacent to Natural Teeth' at the 2013 AAID Annual Implant Dentistry Educational Conference. Photos/Provided by AAID

tistry with a half-day session consisting of 14 different programs covering "New Trends, Techniques and Technology." Following Tandon's keynote, such luminaries in the field as Peter E. Murray, BSc (Hons), PhD, Tomas Albrektsson, MD, PhD, DDS, and Nelson Pinto, DDS, will provide in-depth and varied views of the future of implant dentistry.

Known as "the organization that pro-

vides practical education for the practicing implant dentist™," the AAID conference delivers on that brand promise with two-and-a-half days of programming, including coverage of digital dentistry, soft-tissue management and treatment planning.

Through main podium programs,

- See MAGIC, page C4



Dr. Clark M. Stanford
Photo/Provided by the Academy of Osseointegration

Interview: Oral implants a 'mainstream' approach

By Sierra Rendon, Managing Editor

In an interview with Implant Tribune, Clark M. Stanford, DDS, PhD, dean of the University of Illinois College of Dentistry and board member of the Academy of Osseointegration (AO), discusses recent advances in dental implants, as well as the AO's efforts to serve as a nexus for those who place or restore implants to learn together.

Current outcomes of oral implants show that between 95 and 98 percent are stable and functioning as intended. What are some recent advances that contribute to this superior clinical outcome?

There are a number of recent advances, such as:

- Computer-guided surgery and dental CAD/CAM technologies that can make surgical and restorative phases of implant therapy more predictable and efficient. These technologies can also enable more accurate placement of implants and create better esthetics for patients, which is highly important.

- New technologies are building on comprehensive diagnostic assessments of patients, such as stereolithographic models created from cone-beam computed tomography data combined with software treatment planning. This process enables planning of surgical templates that accurately guide implants into posi-

- See MAINSTREAM, page C18

NEW!

InterActive™

Simply Smarter Surgery

Neck Matched to Major Diameter

- Seals opening at crest of ridge reducing need for bone grafting

Micro-threads and Grooves

- Micro-grooves to improve tissue attachment and micro-threads to increase stability and reduce stress in crestal bone area

Cutting Edge of Grooves Face Clockwise

- Three long grooves for self-tapping insertion

Apical 1/3rd Tapers 2°

- Slight body taper increases initial stability without over-compression and facilitates self-tapping insertion in dense bone

Rounded Apex

- Reduces risk during insertion of implant diverging from path created by drilling and the risk of sinus perforation



AAID Booth #407

✓ **Reality Check**
Nobel Customers
Save \$553!



All-in-1 Packaging

Includes implant, cover screw, healing collar & new fixture-mount that provides simply accurate impression taking as well as functions as a preparable abutment – \$225 SBM, \$250 SBActive™ surface

InterActive implants compatible with NobelActive™ titanium abutments up to 15° angulations.
Straight titanium, straight temporary, and 15° angled titanium abutments.
Price comparison based upon US list prices as of June 2013. All trademarks are property of their respective companies.
US list price for NobelActive with cover screw, impression coping, healing abutment & abutment.
Measurements based upon 4.5mm diameter, 13mm length implants. Dimensions can vary.

NobelActive® Compatible Conical Connection¹ with Significant Design, Surgical, Packaging and Price Advantages

IQity Impression Technique™

Patent pending fixture-mount design provides:

- The ease of a closed-tray impression
- The accuracy of an open-tray Impression
- The versatility to create impression at either implant-level or abutment-level

Simply Smarter Restorations

Matched Concave Transgingival Profile on Abutments & Components


- Shape soft tissue for improved esthetics


Compatible Abutments with Longer Hex/Shorter Bevel²

- Reduce the need to confirm seating with X-rays

Two Color-coded Implant Platforms for Four Implant Diameters

- Restore more implants with a smaller prosthetic inventory and easily identify the correct size



	Straight Abutment	Laboratory Abutment	Straight Contoured	15° Angled Contoured	Gold/ Plastic	Plastic Temporary Abutment	Ball Abutment	Multiple-Unit w/Cap & Transfer Straight	Multiple-Unit w/Cap & Transfer Angled
Nobel Biocare™ price	\$227	\$194	\$195	\$232	\$223	N/A	N/A	\$235	\$281
Implant Direct price	\$120	\$85	\$100	\$100	\$120	\$40	\$90	\$100	\$120
 Reality Check Savings	\$107	\$109	\$95	\$132	\$103	N/A	N/A	\$135	\$161

-MAGIC, Page C1

workshops, including a dozen hands-on opportunities, 10 concurrent sessions and dental team training, attendees can earn as much as 18 implant-specific hours of C.E.

More than 1,000 implant dentistry professionals will be in attendance at the Hyatt Regency Orlando. In addition to learning from world-class clinicians and presenters, attendees will have the opportunity to interact with more than 125 vendors of products and services they utilize in dental practices across America every day.

Doctors and guests will also enjoy time to network and learn from each other in a variety of social functions including two group lunches, the Welcome Reception, Implant World Expo Reception and the always popular President's Celebration at the conclusion of the conference.

Those interested in attending should plan to register onsite in the Regency Ballroom Foyer of the Hyatt Regency Orlando, located at 9801 International Drive. More information about the programs, speakers and activities at the conference can be found at www.aaid.com.

If you are unable to attend the 63rd annual conference, mark your calendar for AAID's 64th Annual Implant Dentistry Educational Conference to be held Oct. 21-24, 2015, in Las Vegas.

Established in 1951, the AAID is the only dental implant organization that offers credentials recognized by federal and state courts as bona fide. Its membership, which exceeds 4,800, includes general dentists, oral surgeons, periodontists and prosthodontists from the United States and in 40 other countries. Contact AAID at www.aaid.com or at (312) 335-1550 or (877) 335-AAID (2243).



Nina Tandon will be the keynote speaker at this year's 63rd Annual AAID Implant Dentistry Educational Conference.

IMPLANT TRIBUNE

PUBLISHER & CHAIRMAN
Torsten Oemus t.oemus@dental-tribune.com

PRESIDENT/CHIEF EXECUTIVE OFFICER
Eric Seid e.seid@dental-tribune.com

GROUP EDITOR
Kristine Colker k.colker@dental-tribune.com

MANAGING EDITOR IMPLANT TRIBUNE
Sierra Rendon s.rendon@dental-tribune.com

MANAGING EDITOR
Fred Michmershuizen
f.michmershuizen@dental-tribune.com

MANAGING EDITOR
Robert Selleck r.selleck@dental-tribune.com

PRODUCT/ACCOUNT MANAGER
Humberto Estrada
h.estrada@dental-tribune.com

PRODUCT/ACCOUNT MANAGER
Will Kenyon
w.kenyon@dental-tribune.com

MARKETING DIRECTOR
Anna Kataoka
a.kataoka@dental-tribune.com

EDUCATION DIRECTOR
Christiane Ferret c.ferret@dtstudyclub.com

Tribune America, LLC
116 West 23rd Street, Suite 500
New York, NY 10011
Phone (212) 244-7181
Fax (212) 244-7185

Published by Tribune America
© 2014 Tribune America, LLC
All rights reserved.

Tribune America strives to maintain the utmost accuracy in its news and clinical reports. If you find a factual error or content that requires clarification, please contact Managing Editor Sierra Rendon at s.rendon@dental-tribune.com.

Tribune America cannot assume responsibility for the validity of product claims or for typographical errors. The publisher also does not assume responsibility for product names or statements made by advertisers. Opinions expressed by authors are their own and may not reflect those of Tribune America.

EDITORIAL BOARD
Dr. Pankaj Singh
Dr. Bernard Touati
Dr. Jack T. Krauser
Dr. Andre Saadoun
Dr. Gary Henkel
Dr. Doug Deporter
Dr. Michael Norton
Dr. Ken Serota
Dr. Axel Zoellner
Dr. Glen Liddelov
Dr. Marius Steigmann

AD

Best Choice, Buy Direct

PiezoArt 1

\$4500

PiezoArt 2
* W/ LED Handpiece

\$5500

NOVABONE

NA4600 Cartridge Dispenser \$68

NA3600 Syringe Dispenser \$106

NA4640 Mini Cartridge (0.25cc) \$245

NA1610 Dental Putty Syringe \$112

NA3640 Bone Graft Cartridge(0.5cc) \$455

NA3621 Bone Graft Cartridge(1.0cc) \$435

BM Series
\$180 each

BM-NJ15U	BM-NJ15L	BM-PIN15
BM-NJ20U	BM-NJ20L	BM-PIN20
BM-NJ25U	BM-NJ25L	BM-PIN25
BM-NJ30U	BM-NJ30L	BM-PIN30

BM-SL3S \$180

BM-SL5S \$180

BM-UI1 \$120

BM-UI8 \$120

BM-UI9 \$120

Minimal Invasive Antral Membrane Balloon Elevation

MIAMBE

\$2500

Platelet Rich Fibrin

\$1800

www.DoWellDentalProducts.com 1-877-373-8904

Corrections

Implant Tribune strives to maintain the utmost accuracy in its news and clinical reports. If you find a factual error or content that requires clarification, please report the details to Managing Editor Sierra Rendon at s.rendon@dental-tribune.com.

Tell us what you think!

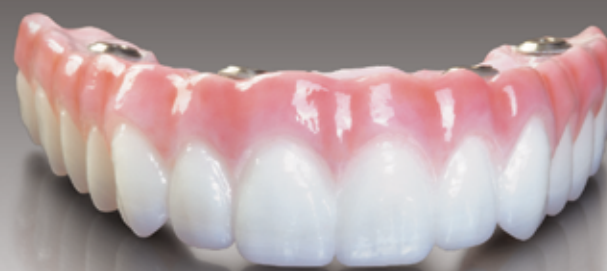Do you have general comments or critique you would like to share? Is there a particular topic you would like to see featured in Implant Tribune? Let us know by e-mailing feedback@dental-tribune.com. We look forward to hearing from you! If you would like to make any change to your subscription (name, address or to opt out), please send an e-mail to c.maragh@dental-tribune.com and be sure to include which publication you are referring to. Also, please note that subscription changes can take up to six weeks to process.

Provide your patients with our toughest implant restoration

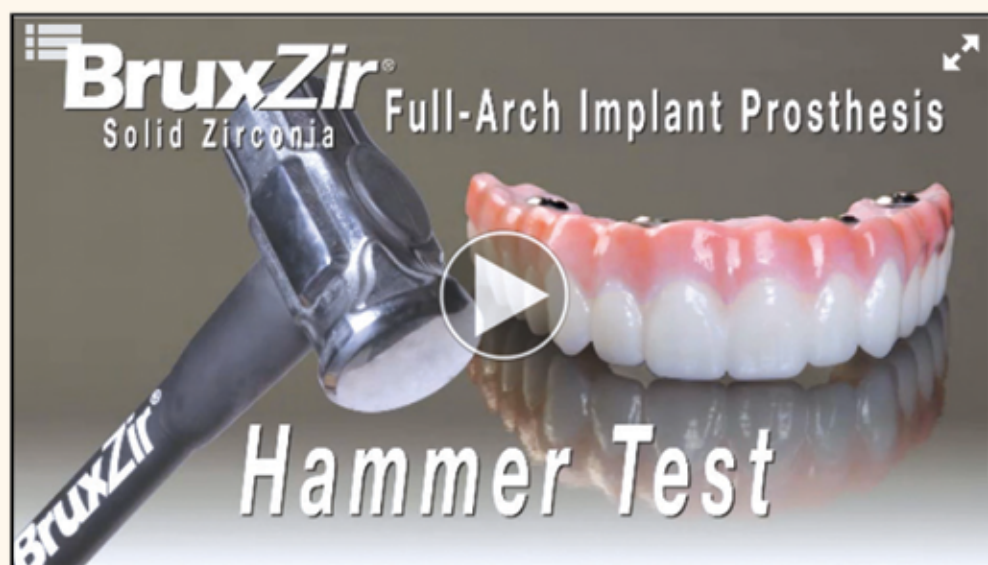

BruxZir® Solid Zirconia

Full-Arch Implant
Prosthesis



\$2,995* per arch
Complete with full-arch
implant provisional



To see the 'Hammer Test' video, or to download step-by-step clinical protocols, go to www.bruxzir.com

- **STRENGTH:** Solid zirconia — no porcelain overlay, denture teeth or acrylics, just 1,465 MPa BruxZir Solid Zirconia
- **DURABILITY:** No color changes, no odor absorption, no metal frame
- **BIOCOMPATIBILITY:** Solid zirconia is hypoallergenic and has been shown in clinical studies to be wear-compatible with enamel¹

7-year warranty provides free replacement from the stored digital data if material damage occurs.

*Warranty is provided to the prescribing dentist and is nontransferrable.
For complete warranty details go to www.glidewell dental.com*

*Price does not include multi-unit abutments, shipping or applicable taxes. 1. Clinicians Report, TRAC Research, July 2014

For more information

888-786-2177

www.glidewell dental.com



**GLIDEWELL
LABORATORIES**

Premium Products - Outstanding Value

Immediate implantation and provisionalization: single-tooth restoration in the esthetic zone

By Susan McMahon, DMD,
and Karrah Petruska

Anterior tooth loss and restoration in the esthetic zone is a common challenge in dentistry today. The prominent visibility of the area can be especially distressing to the patient and requires a timely and esthetically pleasing solution.

Immediate single-tooth implantation followed by immediate provisionalization is becoming an increasingly desirable treatment that offers numerous benefits over conventional delayed loading.

In the past, the non-restorable tooth was extracted and possibly grafted for site preservation. A removable partial denture (or flipper) was fabricated and placed for use during healing. After an adequate healing period, an implant was placed and buried under the gingiva and the patient continued to wear the flipper until the implant had osseointegrated and was ready to be uncovered and restored.

The patient would therefore wear the removable partial denture for upwards of six to eight months. This course of treatment often results in a less than desirable gingival architecture surrounding the final restoration.

There are also clear indications that partial removable dentures are an important causative factor in the alveolar bone resorption process.¹

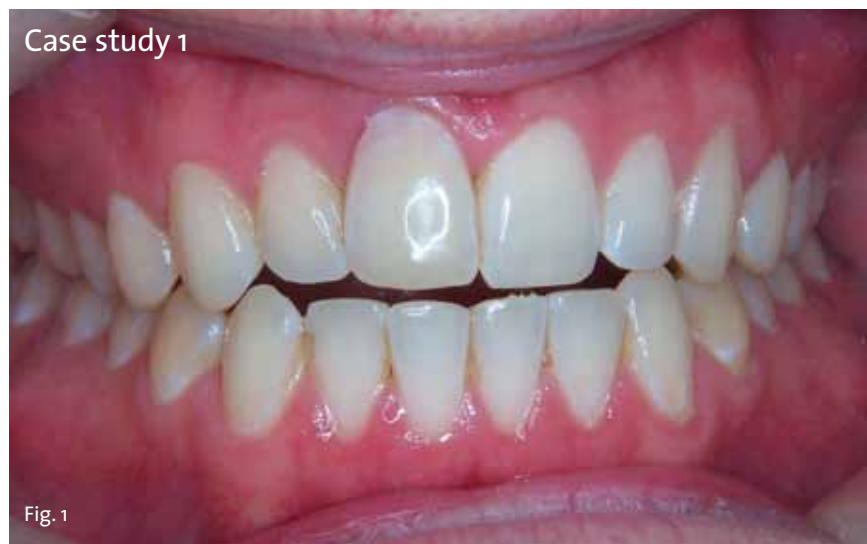Today, immediate treatment offers a better solution. Immediate implantation and same-day provisional replacement of single anterior teeth minimizes treatment time and cost while enhancing esthetic quality.²

In addition to alleviating patient trauma, this technique decreases resorption of hard and soft tissue and results in better function.² Overall, this leads to greater patient satisfaction.

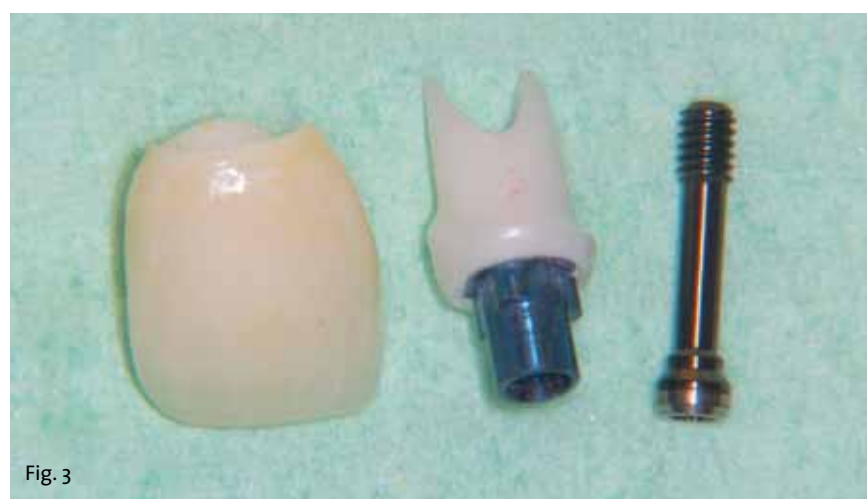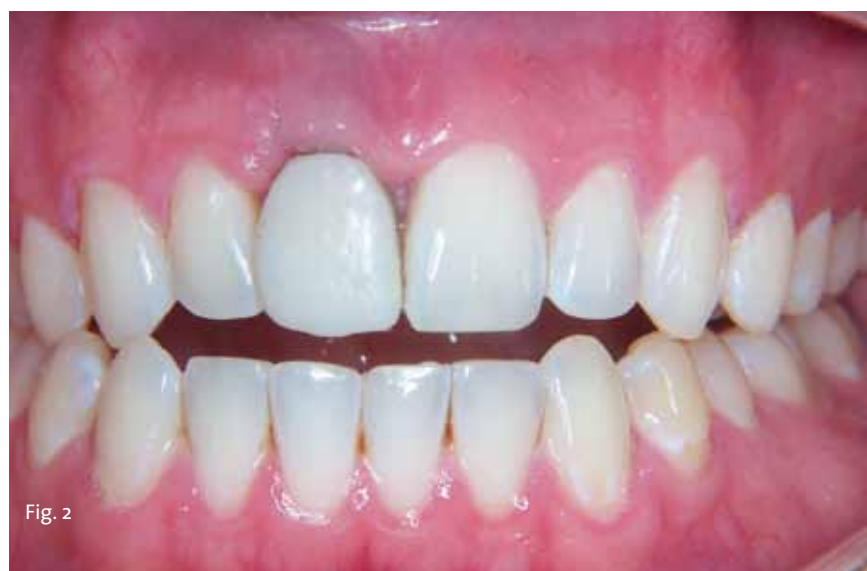In this process, the implant is placed and a provisional is quickly loaded. A nonfunctioning, also known as non-occluding, provisional is used in a protected occlusal scheme. The placement of the non-occluding restoration must occur within 48 hours to be considered immediate loading.³ Both of the following cases received same-day provisionalization.

The clinician faces several challenges when restoring teeth in the esthetic zone. Major cosmetic concerns in the fabrication of the immediately placed provisional are the retention of the interdental papilla and prevention of alveolar bone collapse.⁴

Research has suggested that immediate provisionalization following implan-



Photos/Provided by Dr. Susan McMahon and Karrah Petruska



tation allows for greater clinical control over the regeneration of tissue surrounding the site of extraction.⁵ Unfavorable alterations to the alveolar bone structure must be avoided using ridge preservation techniques and precautions in terms of

osseous exposure.⁵ Immediate placement of the implant into fresh extraction sockets prevents the post-extraction resorption that occurs commonly with alternate forms of treatment, preserving the integrity of the alveolar ridge.⁶

A compromised implantation site is also a concern when dealing with tooth loss. Bone resorption may leave insufficient bone for implantation.

Furthermore, a deteriorated gingival architecture produces an inferior esthetic. Immediate implantation into the fresh extraction socket allows the clinician to maintain the gingival tissue and create a more esthetically pleasing restoration.²

Minimum criteria for implant placement have been established for successful immediate loading. Rough quantitative values for insertion torque and implant stability quotient (ISQ) as well as surgical assessment play a role. Values as low as 15N-cm for insertion torque and 50 ISQ both resulted in successful provisionalization.

Additionally, the surgeon must assess where there is adequate bone support at the apex, at least 3 mm of circumferential bone, and primary stability of the implant. Research has shown that "early loading of dental implants does not appear to interfere with osseous modeling of a developing osseointegration as long as significant micromovement does not occur".⁷

In addition to providing both esthetic and functional benefits, immediate implantation and loading of a nonfunctioning provisional has also been found to result in comparable implant survival outcomes to more traditional techniques.

A recent study measuring clinical success, survival and satisfaction found the technique to be "not less favorable than conventional loading".³ In consideration of this, current literature is now purporting immediate implantation and non-occlusal loading to be the "treatment of choice" in cases of single anterior tooth restoration.⁸

The following are two case studies involving immediate provisionalization. In both cases, the maxillary right central incisors had sustained trauma, were endodontically treated and functioned for a number of years. Approximately 15-20 years later, the teeth in each case failed due to internal resorption. The failing teeth were extracted and implants were inserted immediately and restored the same day with a non-functional provisional.

Dental root resorption involves the loss of hard tissues that compose the teeth (dentin, cementum and enamel).⁹ In most cases, tooth resorption is the result of trauma or irritation to the periodontal ligament and/or tooth pulp.⁹

These conditions may occur as a result of injury, inflammation or chronic infection of the pulp, periodontal conditions, orthodontic tooth motility or tooth



Fig. 4

'Results of a recent study provide evidence that the ceramic oxide abutments can be safely utilized in the incisor region of both the maxilla and mandible as determined by maximal bite forces in the esthetic zone.'

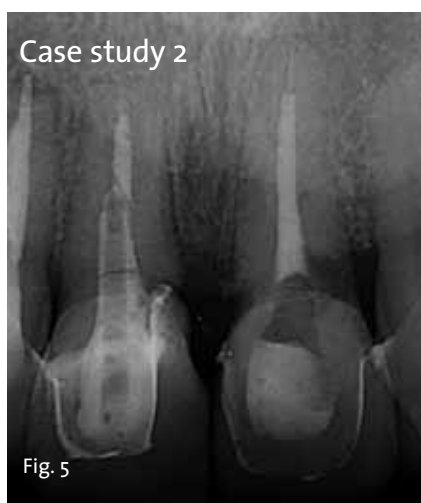

Fig. 5

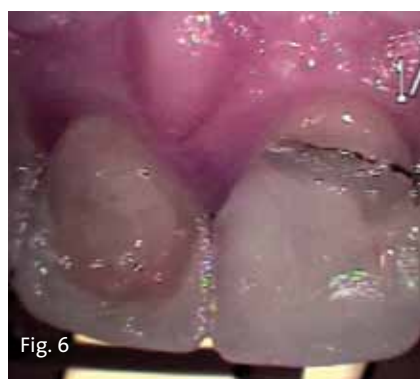

Fig. 6

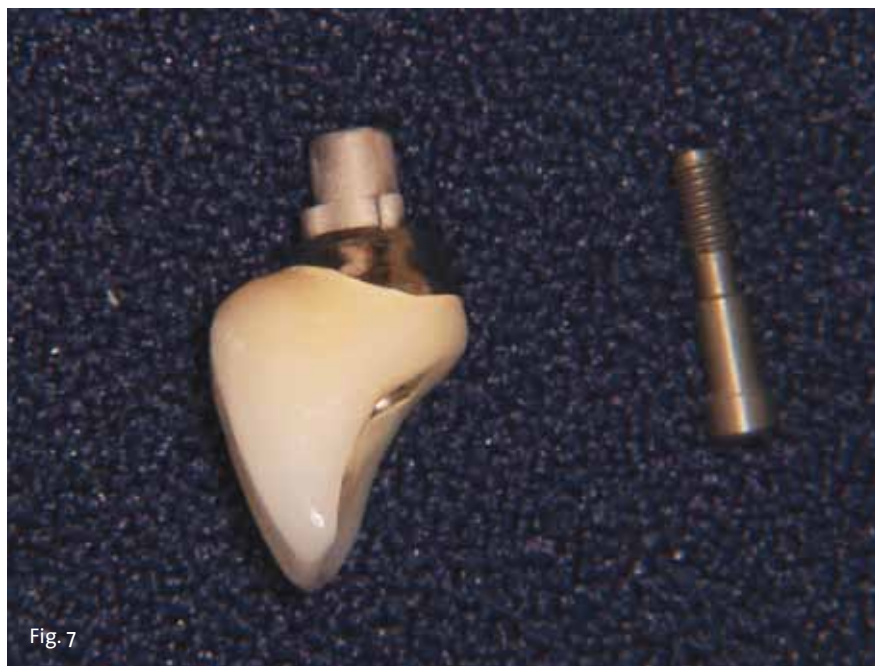

Fig. 7

eruption.^{9,10} Internal resorption is generally asymptomatic and is discovered most frequently through radiographic examination.^{9,10} If internal root resorption is left to progress untreated, it may result in extension to the periodontal ligament through a crown or root perforation.⁹

Case study 1: Failing maxillary right central incisor

The patient is a 30-year-old healthy male who was examined in our office for a failing maxillary right central incisor. His history involves a soccer accident in 1993 that resulted in an elbow to the face with trauma to the right maxillary central incisor.

Approximately one week subsequent to the accident, the patient's tooth was treated endodontically. It eventually became discolored and grew increasingly out of alignment (Fig. 1). Radiographic examination revealed internal resorption.

Clinically, all other maxillary and mandibular teeth were in good condition. Periodontal examination revealed healthy gingival tissue. The patient was concerned that his anterior tooth would fracture unexpectedly and desired an immediate replacement.

Treatment options

Several treatment options were considered. The first was extraction of the maxillary right central incisor and fabrication and placement of a conventional fixed bridge of porcelain fused to metal or an all-ceramic system. The second option was extraction of the tooth followed by placement of a removable partial denture. The next option was extraction, provisionalization with a removable partial denture (flipper) followed by implant placement, healing while wearing the flipper and, finally, restoration of the implant.

The best alternative was extraction and immediate replacement of the extracted tooth with an implant, followed by immediate loading with a nonfunctioning provisional. After adequate osseointegration, a final restoration would be fabricated.

Advantages and disadvantages of all options were explained to the patient. He decided to continue treatment with an immediate implant restoration. The patient was then referred to a periodontist for further evaluation and implant consultation.

Implant evaluation

Implant examination revealed adequate bone height and width for implant placement immediately following extraction of the failing tooth.

A surgical date was scheduled with the periodontist for extraction of the tooth and placement of the implant. An appointment was coordinated with our office for the patient directly following the surgical procedure for provisionalization of the implant.

Surgical protocol

The right central incisor was removed and a NobelReplace Tapered Groovy (internal connection) 5.0 mm x 13 mm implant was placed. An osseous graft of demineralized freeze-dried bone and a collagen membrane were utilized to augment the surgical site. The fixture received an emergence profile, healing abutment.

Provisionalization

The patient presented in our office after the implant placement with a healing abutment in place. The healing abutment was removed. A Nobel Biocare immediate temporary abutment was placed and a provisional was fabricated.

Care was taken to contour the emergence of the provisional as to best support the gingival architecture. The plastic coping for the immediate temporary abutment was roughened with a 56 carbide bur to enhance adherence of the integrity provisional material used.

The provisional was polished and placed on the immediate temporary abutment with a small amount of flowable composite to enhance retention. The provisional crown was fabricated to be completely out of occlusion and non-functional to ensure the implant adequate osseointegration time undisturbed by occlusal forces.

The provisional restoration was observed periodically during the six-month healing process to monitor gingival adaptation (Fig. 2).

Final restoration

Six months post surgery, the patient was scheduled for placement of the final restoration. After removing the provisional crown and the immediate temporary abutment, an implant impression post was placed, radiographic verification was made to assure complete seating and a final impression was taken with a polyether system. Complex shade-mapping was carefully performed to match the existing contralateral natural teeth. The provisional was then reinserted.

A Procera zirconia custom implant abutment was chosen. Zirconium implant abutments have not only been noted for their tooth-like color and esthetic appeal but also for tissue tolerability, high load strength and intrasulcular design enhancement.¹¹

The extraordinary load strength of the oxide ceramics is not compromised by high bending and tensile strength, and fracture and chemical resistance.¹¹

Zirconium abutments are mechanically equivalent to their metal counterparts but boast greater biological compatibility.¹¹

Results of a recent study provide evidence that the ceramic oxide abutments can be safely utilized in the incisor region of both the maxilla and mandible as determined by maximal bite forces in the esthetic zone.¹¹

Due to excellent restorative properties in terms of strength and color conformity, the zirconium implant-abutment is becoming increasingly favored by clinicians for esthetically pleasing anterior implant restorations.¹² A Procera zirconia crown was fabricated for this patient with Noritake CZR porcelain (Fig. 3).

At the time of insert, the provisional crown and immediate temporary abutment were removed. The Procera zirconia custom abutment was seated, the screw was hand tightened and the screw was torqued to 35 Ncm with the manual torque wrench. The access was filled with a small cotton pellet and topped with a thin layer of flowable composite.

The Procera zirconia crown was then seated; margins, contacts and occlusion were confirmed; and the crown was cemented in place with 3M ESPE RelyX luting cement (Fig. 4).

► See IMMEDIATE, page C8

-IMMEDIATE, Page C7

Case study 2: fractured maxillary right central incisor

This patient, a healthy male in his late 30s, was examined in my office for a fractured maxillary right central incisor. The patient had Feldspathic porcelain restorations on his upper central and upper lateral incisors that were placed several years ago. He had a history of trauma to the anterior teeth from a sports injury and subsequent endodontic treatment.

Recent periapical radiographs showed internal resorption in the upper incisors (Fig. 5). The patient sustained additional trauma to the maxillary right central incisor through a fall, which resulted in complete fracture of the crown (Fig. 6). The tooth was nonrestorable.

After reviewing the different treatment options, the patient decided on an immediate implant restoration. Although the maxillary left central incisor also exhibited signs of internal resorption, it was decided that treatment of that tooth would be performed at a later date.

Consideration was given to the poor gingival architecture that results from placing adjacent implants in the esthetic zone. He was then evaluated by the periodontist for the surgical placement of the immediate implant for the maxillary right central incisor.

The patient's treatment was similar to that of the patient in the first case study.

The right central incisor was removed and a NobelReplace Tapered Groovy (internal connection) 5 mm x 13 mm implant was placed. An osseous graft of demineralized freeze-dried bone was utilized to augment the surgical site. The fixture received an emergence profile, healing abutment. The patient then received an immediate non-functioning provisional.

Final restoration

After the six-month healing period, the final restoration was fabricated. In this case, a one-piece screw-through abutment made from a Nobel Biocare Gold-Adapt Engaging NobelReplace (Fig. 7) was fabricated in order to obtain a correct emergence profile of the restoration due to the slightly lingual placement of the implant (Fig. 8).

The restoration was seated, and the screw was hand tightened and then torqued to 35 Ncm with the manual torque wrench. The lingual screw access was filled with a cotton pellet and composite restoration (Fig. 9).

Conclusion

In the cases cited above, both patients had sustained injuries to their anterior teeth as young adults while engaging in sports.

Each of the patients had been treated endodontically and experienced internal resorption of the traumatized teeth approximately 15 years later. Both of their careers and lifestyles demanded immediate replacements that were non-removable and esthetically pleasing.

The failing teeth were extracted and implants were inserted immediately and restored the same day with a non-functional loaded provisional. Immediate placement and restoration of a single implant offers a highly esthetic and timely treatment option in the case of inter-

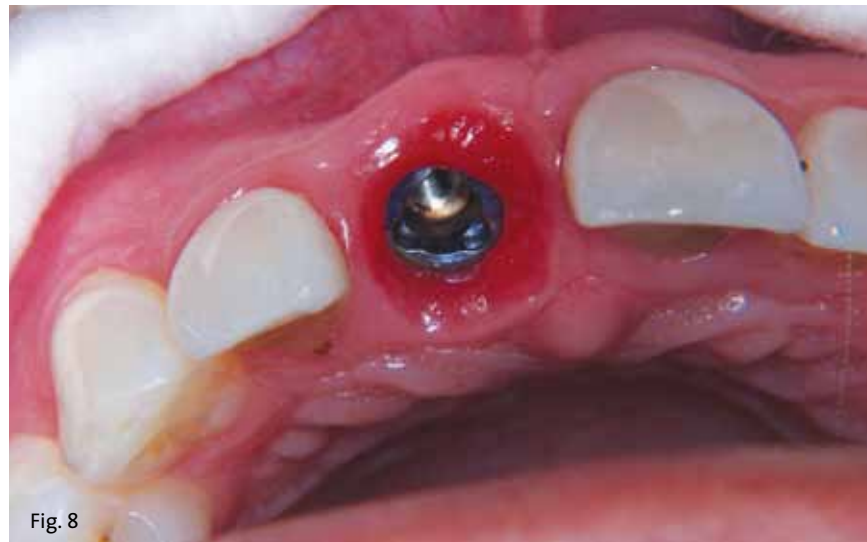

Fig. 8

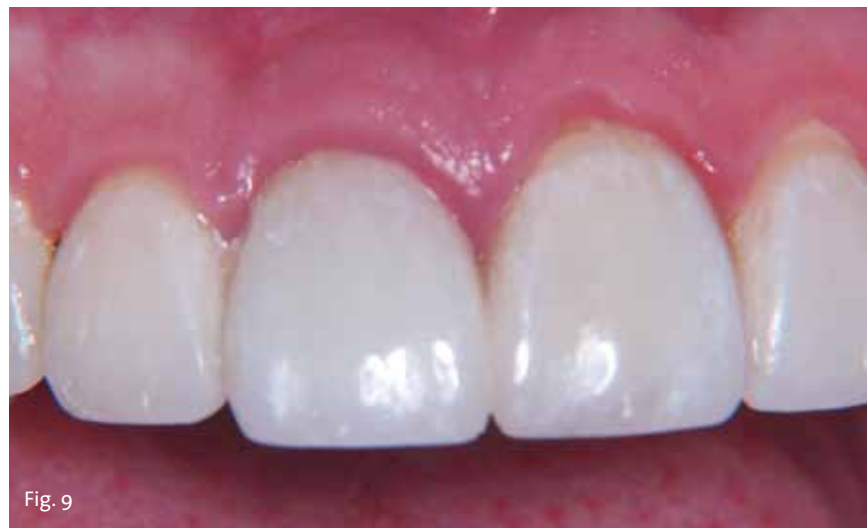

Fig. 9

nal resorption and tooth failure in the maxillary central incisors.

Furthermore, this treatment eliminates the need for a removable partial denture while maintaining the gingival architecture and preventing alveolar bone loss in the extraction site.

As esthetic expectations of patients and the desire for a convenient and timely treatment continue to increase, instantaneous replacement of failing teeth is becoming more routine.¹³

Not only does placing the implant immediately following extraction maintain the alveolar architecture and retain the interdental papillas, placing the provisional immediately thereafter refines the level of treatment the clinician can offer the patient.

Esthetic quality is enhanced without comprising long-term implant stability. Immediately placing and loading implants is both functionally and cosmetically beneficial.

References

- Mijiritsky E. Implants in conjunction with removable partial dentures: A literature review. *Implant Dentistry* 2007; 16(2):146-154.
- Singh A, Gupta A, Yadav A, Chaturvedi TP, Bhatnagar A, Singh BP. Immediate placement of implant in fresh extraction socket with early loading. *Contemporary Clinical Dentistry* 2012; 3(Suppl 2):S219-22.
- den Hartog L, Raghoobar GM, Stellingsma K, Vissink A, Meijer HJ. Immediate non-occlusal loading of single implants in the esthetic zone: a randomized clinical trial. *Journal of Clinical Periodontology* 2011; 38(2):186-194.
- Saghezchi K. Replacing a single anterior tooth immediately after extraction with a single implant to preserve interproximal papilla and alveolar bone. *The Journal of Cosmetic Dentistry* 2004; 19(4):70-76.
- De Kok I, Chang S, Moriarty J, Cooper L. A retrospective analysis of peri-implant tissue responses at immediate load/provisionalized microthreaded implants. *International Journal of Oral and Maxillofacial Implants* 2006; 21(3):405-412.
- Ormianer Z, Schirotti G. Maxillary single-tooth replacement utilizing a novel ceramic restorative system. *Journal of Oral Implantology* 2006; 32(4):190-199.
- Becker CM, Wilson TG Jr, Jensen OT. Minimum criteria for immediate provisionalization of single-tooth dental implants in extraction sites: a 1-year retrospective study of 100 consecutive cases. *Journal of Oral and Maxillofacial Surgery* 2011; 69(2):491-497.
- Malchiodi L, Cucchi A, Ghensi P, Nocini PF. Evaluation of the esthetic results of 64 non-functional immediately loaded postextraction implants in the maxilla: correlation between interproximal alveolar crest and soft tissues at 3 years of follow-up. *Clinical Implant Dentistry and Related Research* 2011 Dec 16; Epub ahead of print.
- Ne R, Witherspoon D, Gutmann J. Tooth Resorption. *Quintessence International Dental Digest* 1999; 30(1):9-25.
- Gunraj MN. Dental root resorption. *Oral Surgery, Oral Medicine, Oral Pathology* 1999; 88(6):647-653.
- Gehrke P, Dhom G, Brunner J, Ing D, Wolf D, Degidi M, Piattelli A. Zirconium implant abutments: Fracture strength and influence of cyclic loading on retaining-screw loosening. *Quintessence International* 2006; 37(1):19-26.
- Biow Tan P, Dunne J. An esthetic comparison of a metal ceramic crown and cast metal abutment with an all-ceramic crown and zirconia abutment: a clinical report. *Journal of Prosthetic Dentistry* 2004; 91(3):215-218.
- Barone A, Rispoli L, Vozza I, Quaranta A, Lovani U. Immediate restoration of single implants placed immediately after tooth extraction. *Journal of Periodontology* 2006; 77(11):1914-1920.

About the authors



SUSAN MCMAHON, DMD, is in private practice in Pittsburgh. She is accredited by the American Academy of Cosmetic Dentistry and is a six-time award winner in the AACD Annual Smile Gallery. She has served as a clinical professor in prosthodontics and operative dentistry at the University of Pittsburgh, School of Dental Medicine. McMahon is a guest lecturer in cosmetic dentistry at West Virginia School of Dentistry and lectures to dentists in the United States and Europe on tooth whitening and cosmetic dentistry. You may contact McMahon at:

Esthetic Dentistry Pittsburgh
2643 E. Carson St.
Pittsburgh, Pa. 15203
(412) 381-3969
www.wowinsmile.com



KARRAH PETRUSKA is a graduate of the University of Wisconsin-Madison. She is in the dual master's program, post-baccalaureate pre-medical program and master's of health management systems at Duquesne University.

Send us your case study

For the implant specialist, periodontist, prosthodontist or general dentist interested in placing implants, the *Implant Tribune* is an excellent monthly resource providing the latest in research, news and products. Here is your opportunity to write an article for the *Implant Tribune*.

Send your prospective articles up to 850 words (longer submissions may be considered) via Word document to s.rendon@dental-tribune.com. Accompanying photos should be high resolution (300 dpi JPGs, preferred) and should include photo captions and credits. Please include with your submission a short (150-word) bio and a high-resolution author image, if available.

NEW

**ASTRA TECH
IMPLANT SYSTEM**



Simplicity

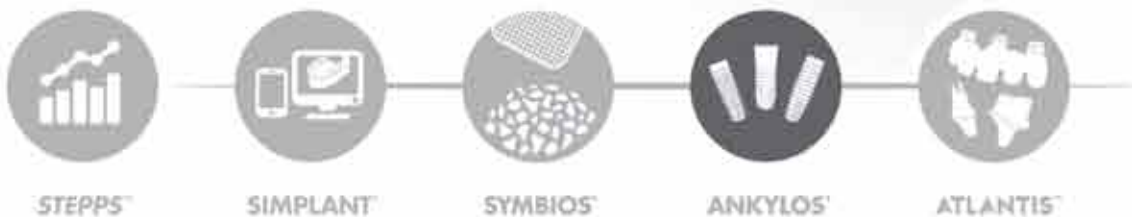
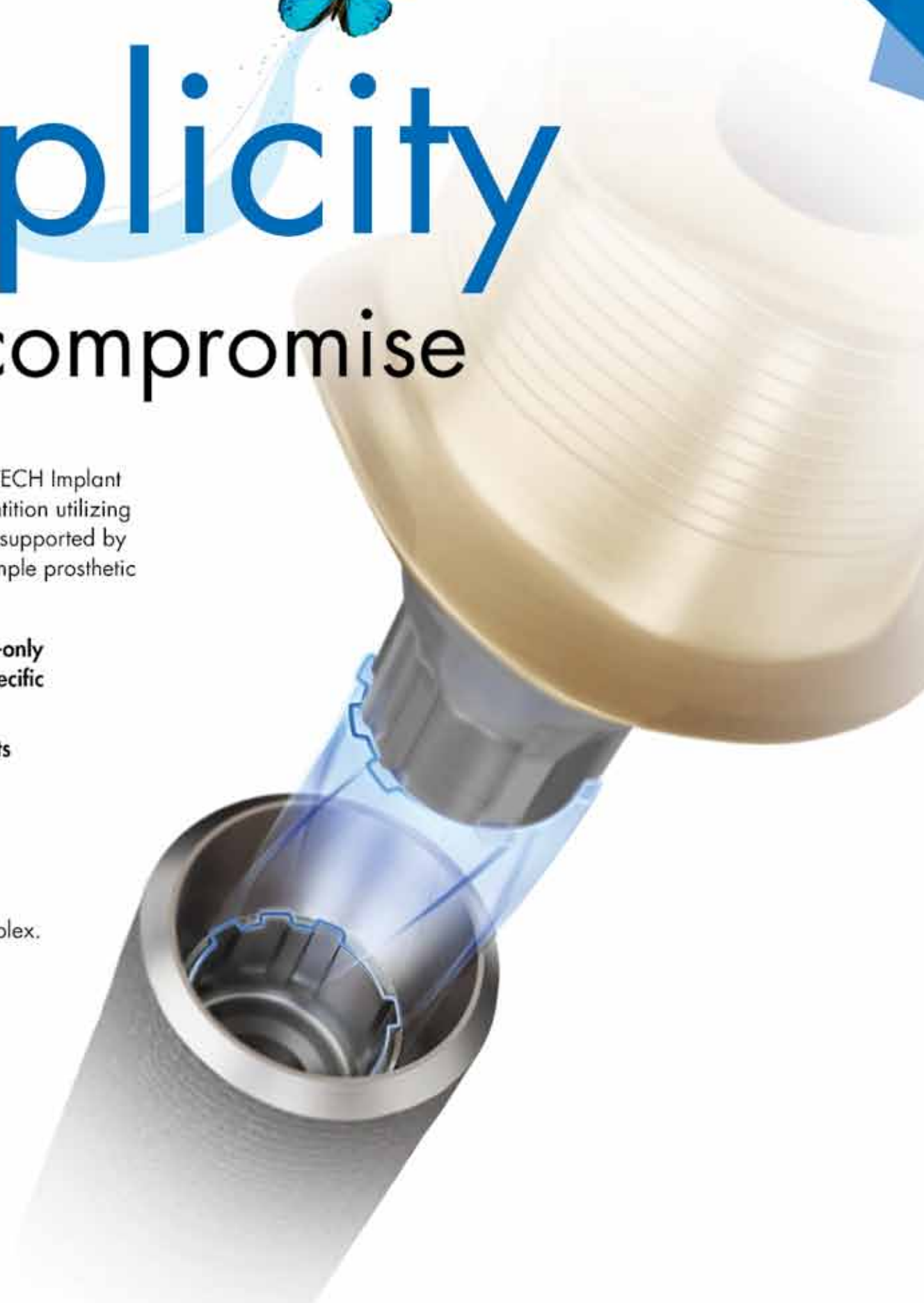without compromise

The design philosophy of the ASTRA TECH Implant System EV is based on the natural dentition utilizing a site-specific, crown-down approach supported by an intuitive surgical protocol and a simple prosthetic workflow.

- Unique interface with one-position-only placement for ATLANTIS patient-specific abutments
- Self-guiding impression components
- Versatile implant designs
- Flexible drilling protocol

The foundation of this evolutionary step remains the unique ASTRA TECH Implant System BioManagement Complex.

For more information visit
www.jointheev.com



STEPPS™

SIMPLANT™

SYMBIOS™

ANKYLOS™

ATLANTIS™

**ASTRA TECH
IMPLANT SYSTEM**

XIVE

www.dentsplyimplants.com



DENTSPLY Implants does not waive any right to its trademarks by not using the symbols ® or ™. 326270635-USX-1407 © 2014 DENTSPLY Implants. All rights reserved.