

ENDO TRIBUNE

Providing ease of use, resistance to cyclic fatigue, swiftness and effectiveness, the new XP-endo®

►A1-4

LAB TRIBUNE

Metal-Ceramic esthetics without boundaries

►B1-4

ORTHO TRIBUNE

Skeletal Class III Malocclusion with Canine Transposition and Facial Asymmetry

►C1-4

HYGIENE TRIBUNE

Dental Hygienist Seminar gathers over 270 dental professionals from MEA region during Dubai Dental Week

►D1-8

Oral health education by itself is ineffective, study finds

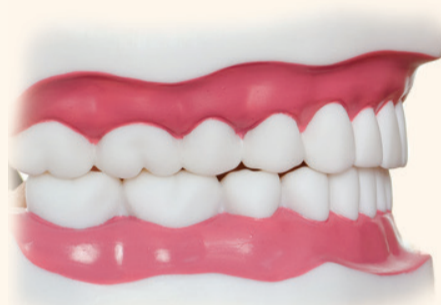By DTI

MELBOURNE, Australia: Evaluating the effectiveness of oral health promotion strategies for preventing dental caries and periodontal disease among children, researchers from the Cochrane Public Health Group have found that oral health education alone, such as classroom lessons, videos, comics and brochures, was ineffective.

From analysis of the results of 38 international studies, the Cochrane researchers found that oral health education as a stand-alone measure, had no significant impact on caries

in permanent or primary teeth and surfaces. Nonetheless, some of the studies reported improvements in gingival health, oral hygiene behaviours and oral cleanliness, the review showed.

"There is a general perception that oral health education will change oral health risk behaviours and promote good oral health practices," commented Dr Shalika Hegde, a research fellow at Dental Health Services Victoria in Melbourne and part of the Cochrane Public Health Group, on the findings in an article on DrBicuspid.com. "However, this thinking is fundamentally flawed, as knowledge



gained alone will not lead to sustained changes in oral health," Hegde emphasised.

When coupled with other measures, such as supervised toothbrushing with fluoridated toothpaste, oral

International researchers from the Cochrane Public Health Group have aimed to determine which promotion strategies are most effective and equitable in preventing poor oral health. (Photograph: Anna Hoychuk/Shutterstock)



►Page 2

AMD LASERS®
EFFECTIVE. PRACTICAL. AFFORDABLE. WORLD CLASS LASERS.

PICASSO LITE+ (NEW!)

PICASSO+ (NEW!)

#1 Lasers in the World

GLOBE
step into the future

TAMER DROGUERIE

DUBAI MEDICAL EQUIPMENT
Dubai Medical Equipment L.L.C.

GLOBE
ADDRESS: 11, EL OBOUR BUILDINGS, OROUBA AV. HOLIOPOLIS, CAIRO, EGYPT
TELEFAX: +2024045621 - +2024010579
MOB: +2 01000 99 6265
WEBSITE: WWW.GLOBEEGYPT.NET
EMAIL: INFO@GLOBEEGYPT.NET

TAMER DROGUERIE
ADDRESS: BEIRUT-LEBANON
WEBSITE: WWW.TAMERHOLDING.COM
E-MAIL: DENTAL@TAMERHOLDING.COM
PHONE: 961.1.694 000
FAX: 961.1.694 777

DUBAI MEDICAL EQUIPMENT
UNITED ARAB EMIRATES
TEL. NO: +971 6 5308055
FAX NO: +971 6 5308077
MOB : +971 50 7370011
MOB : +971 55 4417490
DT_UAE@EMIRATES.NET.AE

866.999.2635 AMDLASERS.COM

◀Page 1

health promotion interventions were generally found to be effective in reducing caries in children's primary teeth. Moreover, oral health education provided in an educational setting, combined with professional preventative oral care in a dental clinic, was effective in reducing caries in children's permanent teeth, the researchers found.

Another most promising intervention approach for reducing caries in children—although additional research is needed—appears to be improving access to fluoride in its various forms and reducing sugar consumption, Hegde told Dental Tribune Online. Generally, the findings of this review will have global implications in the area of models of oral

health care delivery and oral health promotion, research, policy and practice, Hegde concluded.

The review, which was the first of its kind at an international level, included data on 119,789 children in 21 countries from studies conducted between January 1996 and April 2014. All of the studies reviewed focused on community-based oral health promotion in-

terventions for preventing caries and periodontal disease among children from birth to 18 years of age.

The review, titled "Community-based population-level interventions for promoting child oral health", was published online on 15 September in the Cochrane Database of Systematic Reviews. [DTI](#)

Saliva may indicate susceptibility to depression in boys

By DTI

CAMBRIDGE, UK: For the first time, researchers at the University of Cambridge have identified a biomarker for major or clinical depression in human saliva. An examination of saliva samples of hundreds of teenagers revealed that boys especially may be at the greatest risk of depression.

Following a group of boys and girls over 12 to 36 months by measuring levels of cortisol in their saliva, as well as collecting self-reported informa-

tion on symptoms of depression, the researchers found that boys with depressive symptoms and elevated morning cortisol were 14 times more likely to develop clinical depression compared with boys with neither.

However, the connection was not as distinctive in female participants. Girls with high cortisol and depressive symptoms were four times more likely to develop depression, suggesting differences between the sexes in how depression develops.

Clinical depression is a severe and

common illness, affecting one in six people at some point in their lives, according to the researchers. To date, however, scientists have lacked validated biomarkers for the condition in the youth population at large to aid the detection of at-risk groups for depression in general and in boys and young men in particular, partly owing to its various causes and symptoms.

"Through our research, we now have a very real way of identifying those teenage boys most likely to develop clinical depression," said Prof. Ian Goodyer from the university's De-

partment of Psychiatry. "This will help us strategically target preventions and interventions at these individuals and hopefully help reduce their risk of serious episodes of depression and their consequences in adult life."

The study, titled "Elevated morning cortisol is a stratified population-level biomarker for major depression in boys only with high depressive symptoms", was published on 18 February in the Proceedings of the National Academy of Sciences of the United States of America journal. [DTI](#)

IMPRINT

GROUP EDITOR
Daniel ZIMMERMANN
newsroom@dental-tribune.com
Tel.: +44 161 223 1830

CLINICAL EDITOR
Magda WOJTKIEWICZ

ONLINE EDITOR
SOCIAL MEDIA MANAGER
Claudia DUSCHEK

EDITORS
Anne FAULMANN
Kristin HÜBNER
Yvonne BACHMANN

COPY EDITORS
Sabrina RAAFF
Hans MOTSCHMANN

PUBLISHER/PRESIDENT/CEO
Torsten OEMUS

CHIEF FINANCIAL OFFICER
Dan WUNDERLICH

CHIEF TECHNOLOGY OFFICER
Serban VERES

BUSINESS DEVELOPMENT MANAGER
Claudia SALWICZEK-MAJONEK

EVENT SERVICES/PROJECT MANAGER
Sarah SCHUBERT

TRIBUNE CME & CROIXTURE
PROJECT MANAGER ONLINE
Tom CARVALHO

EVENT MANAGER
Lars HOFFMANN

EDUCATION MANAGER
Christiane FERRET

PR & COMMUNICATIONS MANAGER
Marc CHALUPSKY

MARKETING SERVICES
Nadine DEHMEL

SALES SERVICES
Nicole ANDRA

ACCOUNTING SERVICES
Karen HAMATSCHEK
Anja MAYWALD
Manuela HUNGER

MEDIA SALES MANAGERS
Matthias DIESSNER (Key Accounts)
Melissa BROWN (International)
Antje KAHNT (International)
Peter WITTECZEK (Asia Pacific)
Weridiana MAGESWKI (Latin America)
Maria KAISER (North America)
Hélène CARPENTIER (Europe)
Barbora SOLAROVA (Eastern Europe)

EXECUTIVE PRODUCER
Gernot MEYER

ADVERTISING DISPOSITION
Marius MEZGER

DENTAL TRIBUNE INTERNATIONAL
Holbeinstr. 29, 04229 Leipzig, Germany
Tel.: +49 341 48 474 302
Fax: +49 341 48 474 173
www.dental-tribune.com
info@dental-tribune.com

DENTAL TRIBUNE ASIA PACIFIC LTD.
Room A, 20/F
Harvard Commercial Building
105-111 Thomson Road, Wanchai, HK
Tel.: +852 3113 6177
Fax: +852 3113 6199

THE AMERICA, LLC
116 West 23rd Street, Ste. 500, New York
N.Y. 10011, USA
Tel.: +1 212 244 7181
Fax: +1 212 244 7185

DENTAL TRIBUNE MEA EDITION
EDITORIAL BOARD
Dr. Aisha SULTAN ALSUWAI, UAE
Dr. Ninette BANDAY, UAE
Dr. Nabeel HUMOOD ALSABEHA, UAE
Dr. Mohammad AL-OBAIDA, KSA
Dr. Meshari F. ALOTAIBI, KSA
Dr. Jasim M. AL-SAEEDI, Oman
Dr. Mohammed AL-DARWISH, Qatar
Prof. Khaled BALTO, KSA
Prof. Paul TIPTON, UK
Dr. Dobrina MOLLOVA, UAE
Dr. Munir SILWADI, UAE
Dr. Khaled ABOUSEADA, KSA
Dr. Rabihi ABI NADER, UAE
Dr. George SANOOPI, UAE
Dr. Olivier CARCUAC, UAE
Dr. Ehab RASHED, UAE
Dr. Olivier CARCUAC, UAE
Dr. Ehab Heikal, Egypt
Aiham FARRAH, CDT, UAE
Retty M. MATTHEW, UAE

PARTNERS
Emirates Dental Society
Saudi Dental Society
Lebanese Dental Association
Qatar Dental Society
Oman Dental Society

DIRECTOR OF mCME
Dr. Dobrina Mollova
mollova@dental-tribune.me
Tel.: +971 50 42 43072

DIRECTOR
Tzvetan Deyanov
deyanov@dental-tribune.me
Tel.: +971 55 11 28 581

DESIGNER
Kinga Romik
k.romik@dental-tribune.me

PRINTING HOUSE & DISTRIBUTION
Al Nisr Printing
P. O. Box 6519, Dubai, UAE
800 4585/04-4067170

Maxcem Elite™ Chroma dispenses pink and fades to a cement shade, allowing you to recognise the precise moment your excess cement is ready to be removed. Then, with just one peel, success. Your restoration is secure. **Change your cement. Change your outcomes.**



Maxcem Elite™ Chroma
Self-Etch/ Self-Adhesive Resin Cement with Cleanup Indicator

www.KerrDental.eu



Together, we're more.™

SMALL CHANGE. BIG DIFFERENCE.

The new imaging plate scanner XIOS Scan completes the intraoral family from Sirona. Whether you're taking the first steps into the digital world or establishing or updating a fully digital practice, XIOS Scan and XIOS XG Sensors offer perfectly synchronized solutions for every workflow. **Enjoy every day. With Sirona.**



THE NEW
IMAGING PLATE
SCANNER:
XIOS Scan

SIRONA.COM

The Dental Company

sirona.

Solving the problem of postoperative complications of Class I restorations

By Dr. Valentina Kondratieva, Russia

Introduction

In the recent years there has been a rapid improvement in the physical properties of the composite materials and adhesive systems that certainly helped dentists to improve the quality of their work. Shrinkage of composite materials today is lower than before, their strength and wear resistance have increased, and aesthetic rates are comparable to the aesthetics of natural teeth. But, unfortunately, the problem of the polymerization stress has remained to the present time. Shrinkage of the composite material during polymerization causes stress in the composite, the adhesive layer and the tooth tissues. The intensity of the stress depends on such factors as cavity configuration (C-factor), the physical properties and composition of the composite material. The result of the polymerization stress is a number of complications - micro leakage, post-operative sensitivity, cracks in the tooth, subsequent secondary caries and others. To prevent such problems during performing restorations with classic composite materials it's recommended to use flowable composites as an adaptive layer (creating the 'elastic cavity wall'), as well as perform placement of the composite in small portions during filling the

cavity ('incremental' technique). [1] Such approach is familiar to the dentists but require a lot of time for restoration of each tooth as during the work the clinician has to insert into the cavity and adapt multiple number of layers of the composite material. That is why bulk fill materials are increasingly popular. They help solve the problem of polymerization stress and reduce the amount of time spent on the restoration of the tooth. One of such materials, Filtek™ Bulk Fill Posterior Restorative, is used a lot in dental practices world-wide and daily helps us to do a better job.

Clinical case

The patient came to the dental office with complaints about increased sensitivity of the posterior teeth of the lower jaw on the right while eating sweets. During the examination the poor quality restorations of teeth 4.6, 4.7 with micro leakage, numerous cracks and color change along the border between the restoration and the tooth were found (Fig. 1). To minimize polymerization stress, save time during the treatment without compromising the strength and the wear resistance of the restoration it was decided to make a direct restoration of the teeth with Filtek™ Bulk Fill Posterior composite material.

Isolation of the working field

When working with composite materials the use of the isolation will help to make the adhesive procedure more predictable and will provide a dry working field and retraction of the soft tissues surrounding the tooth. But in this case the application of a clamp for fixing the rubber dam material has certain difficulties – a tooth 4.7 has a low clinical crown and there is no possibility to rigidly fix the clamp on it. There is a simple solution to this problem: 36% phosphoric acid is applied on the area near the gingiva on the buccal wall of the tooth in two places and after 5 seconds washed out with the plenty of water, then a piece of the composite material is placed on the surface (composite shoulder), which after the polymerization will perform the function of holding the clamp on the tooth. After the placement of the rubber dam all possible leaks are sealed with gingival protector (Fig. 2).

Preparation step

Old restorations were removed with the diamond burs (diamond particle size is 120-140 microns), the universal carbide bur (SS-White SSW FG-1702SL) was used for preparation of carious dentin, enamel walls of the cavities were treated with fine-grain diamond burs (diamond particle size is 25 microns) and polished with

"Kenda" polishing cup for a better fit of the restoration. [2] The result of the preparation is two Class I cavities, teeth 4.6 and 4.7. (Fig. 3).

Adhesive protocol

To prevent postoperative complications and provide proper adhesion of the composite to enamel and dentin an adhesive protocol using selective enamel etching was performed. Phosphoric acid was applied on the enamel edges of the cavity for 10 seconds (Fig. 4), fully washed out with water. After drying the teeth, a self-etch adhesive was used in the cavity, agitating the dentine for 20 seconds (Fig. 5). The adhesive was dried until formation of a smooth shiny film and then polymerized for 10 seconds (Fig. 6).

Flowable composite use

Many authors describe the use of flowable composite underneath posterior restorations. Improved adaptation and contribution to lower post-operative sensitivity have been given as reasons for this. Although Filtek™ Bulk Fill Posterior is very flowable upon extruding, the author also prefers to apply a layer of flowable composite prior to placing the composite restorative [3M]. [3] In this clinical case, for this purpose Filtek™ Bulk Fill flowable composite was placed on the dentin in an increment of about

0.5-0.7 mm and polymerized afterwards (Fig.7).

Composite restoration

The further restoration was performed with Filtek™ Bulk Fill Posterior Restorative material (Shade A2). The product has high strength and wear resistance, good polishing, self-adaptation, it allows placement in an increment up to 5 mm and has low modulus of elasticity to prevent development of postoperative complications. [4] Filtek™ Bulk Fill Posterior was placed into the cavity directly from the capsule in one large portion (Fig. 8), and then adaptation of the upper layer was performed with the large ball burnisher bur (Fig. 9) to make an occlusal surface.

Anatomy of the occlusal surface was performed with thin LM-Applica and LM-Fissura tools using the technique of direct carving (Fig. 10-13). The excess of the composite material from a tooth-restoration border was removed with a synthetic fiber brush, slightly moistened with the modelling resin (Fig. 14). Polymerization of the composite material was made for 20 seconds (Fig. 15). With the power of curing light of 1000 mW/cm² this time is sufficient for the full polymerization of Filtek™ Bulk Fill Posterior at the entire depth of the cavity.

Finishing of the restoration

On the Fig. 16 and 17 the restorations before finishing and polishing are shown. After the rubber dam removal, the composite shoulder was removed from the buccal wall of the tooth using an ultrasonic tip for removing dental plaque, and the remaining of the composite was polished with the SS-White 12-sided carbide bur during finishing and occlusal adaptation of the restoration. Finishing and polishing of the restoration to a "dry light" were performed with a two-stage polishing system: Sof-Lex™ Spiral Wheels (beige and white).

Final result

The X-Ray showed that the material has an excellent radiopacity and adhesion to the cavity walls (Fig. 18). The amount of time consumed on the restoration of two teeth with Filtek™ Bulk Fill Posterior Restorative was equivalent to the amount of time which is usually taken to treat one posterior tooth, which is an additional advantage for both dentist and the patient. The final result of the restoration after polishing is shown on the Fig. 19. Long-term result in 10 months after the restoration is shown on the Fig. 20.

Conclusions

With this technique using bulk fill nanocomposite materials such as Filtek™ Bulk Fill Posterior the author has less post-operative sensitivity issues than with multi-layer composite placement [3M]. In addition, using the material in one layer up to 5 mm allows dentists to significantly reduce the amount of working time without sacrificing the quality of work. [Dr.](#)

Full list of references is available from the publisher.

Dr. Valentina Kondratieva, leading specialist in esthetic restorations, Hummingbird Dental Practice, the author of EVRICA Project, successful practicing dentist with over 13 years of experience. Owner of the patents in the field of dentistry and developer of "one opacity" technique of aesthetic anterior teeth restoration with Filtek™ Z550 nanocomposite material. Over the past 5 years conducted more than 150 educational events in Russia and abroad. e-mail: wax.vs@yandex.ru

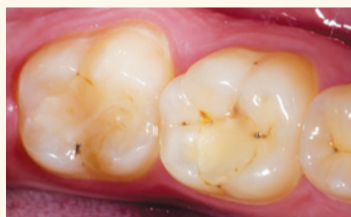

Fig. 1. Initial clinical situation. Teeth 4.6, 4.7 have unsatisfactory restorations with microleakages, color changes along the restoration-tooth border.

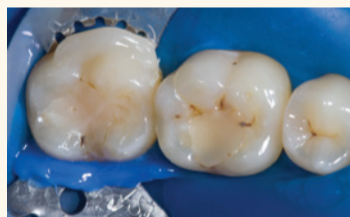

Fig. 2. Isolation of the working field with the latex curtain

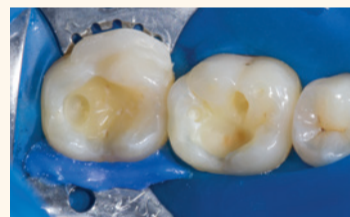

Fig. 3. Old restorations are removed from the teeth, preparation of carious dentin is performed, cavities are prepared for further restorations

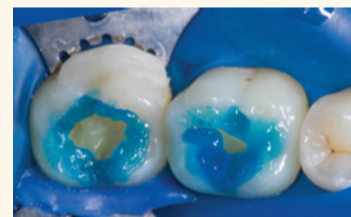


Fig. 4. Selective etching of the enamel with 36% phosphoric acid for 10 seconds

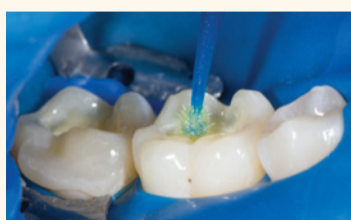

Fig. 5. Application of Single Bond Universal adhesive

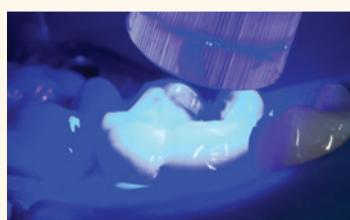


Fig. 6. 10-second polymerization of Single Bond Universal adhesive

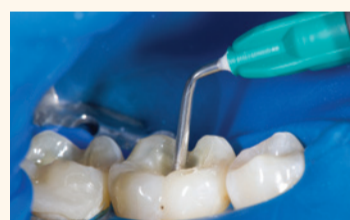

Fig. 7. Application of Filtek™ Bulk Fill Flowable composite as an adaptive layer on the bottom of the cavities

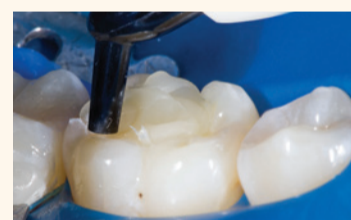

Fig. 8. Application of Filtek™ Bulk Fill Posterior (shade A2) after the polymerization of the adaptive layer

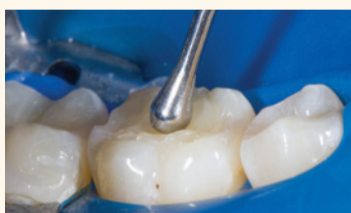

Fig. 9. Adaptation of the top layer of the Filtek™ Bulk Fill Posterior with a ball burnisher bur

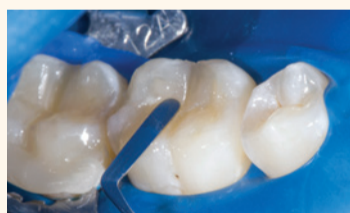

Fig. 10. Shaping the distal buccal cusp of the tooth 4.6 with LM-Applica tool

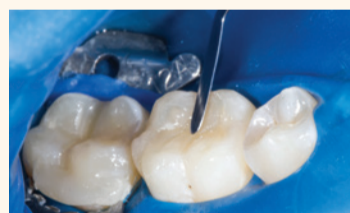

Fig. 11. Shaping the mesial lingual cusp of the tooth 4.6 with LM-Applica tool

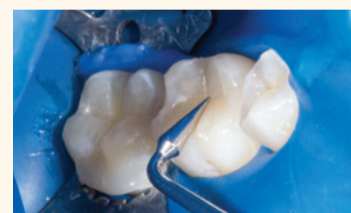

Fig. 12. Shaping the fissures of the tooth 4.6 with LM-Fissura tool

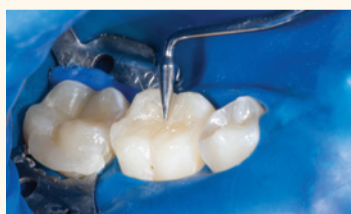

Fig. 13. Position of the LM-Fissura tool during the process of creating the tooth shape

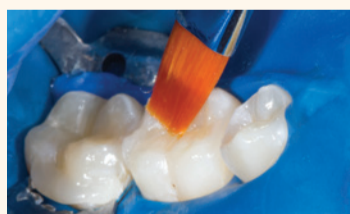

Fig. 14. Removal of the excess of material from the border tooth-restoration with synthetic fiber brush




Fig. 15. Curing of the composite for 20 seconds with Elipar™ S10 Curing Light

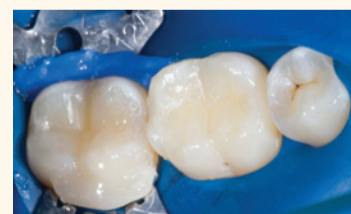

Fig. 16. Restorations of the teeth 4.6, 4.7 before finishing

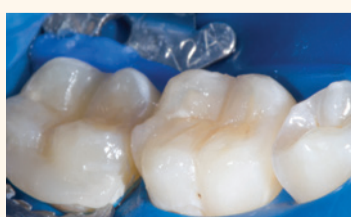

Fig. 17. Restorations of the teeth 4.6, 4.7 before finishing

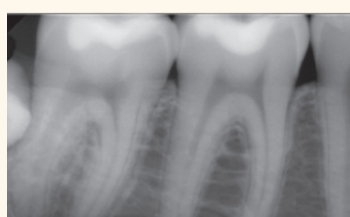


Fig. 18. X-Ray of the final restorations. The material shows an excellent radiopacity and adaptation to the cavity walls

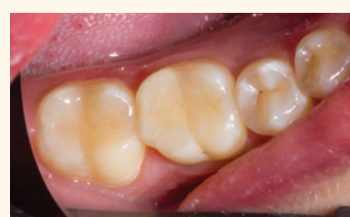

Fig. 19. Final restorations after the occlusal adaptation, finishing and polishing

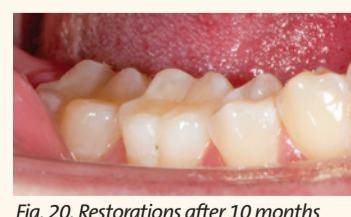
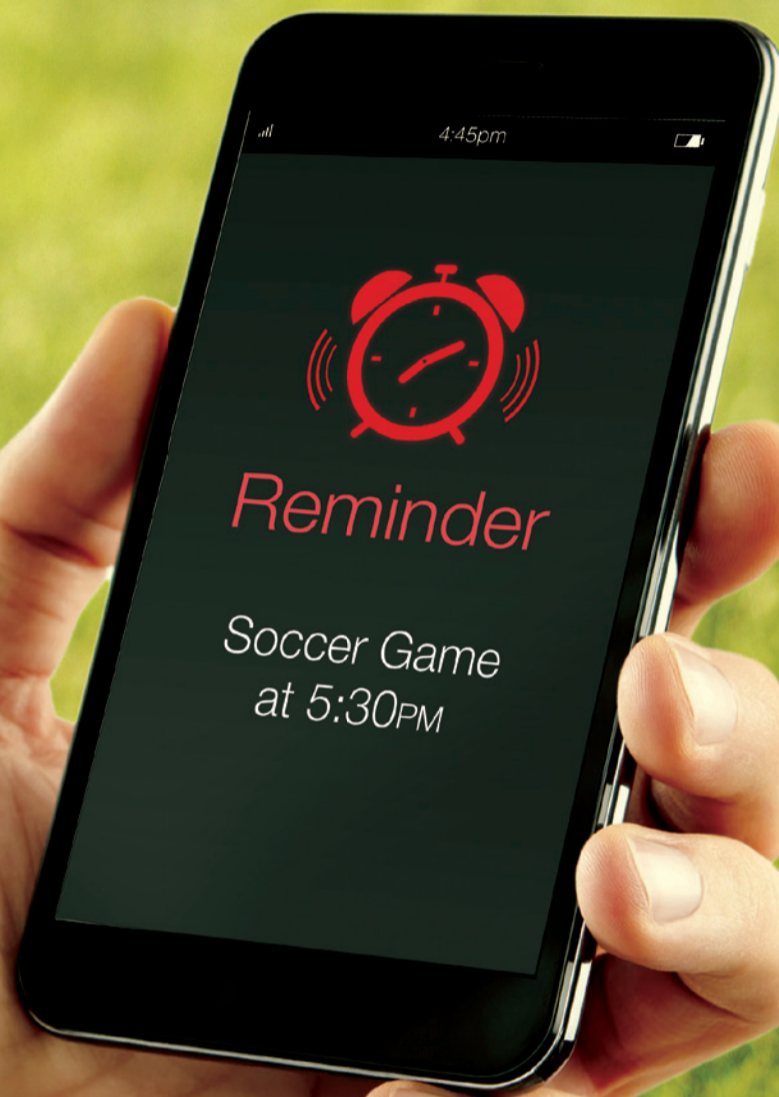
Fig. 20. Restorations after 10 months



3M Oral Care

Takes less time, so you have more time.

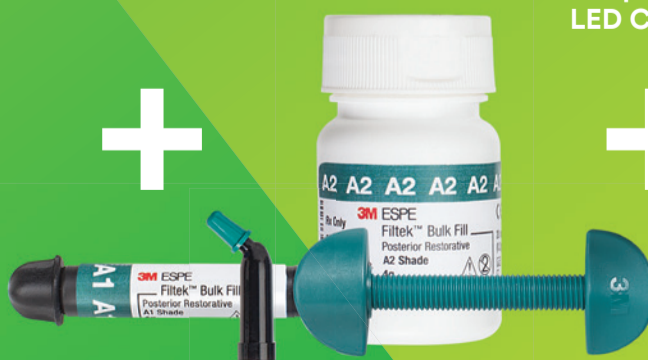There are things in life you don't want to miss. And the more complicated a procedure is, the greater chance there is for something to go wrong and disrupt your day. That's why 3M Oral Care has simplified posterior restorations ... the most frequently performed direct restoration. By using Filtek™ Bulk Fill Posterior Restorative with three other innovative products, you'll move through posterior restorations with speed and simplicity. See how our Posterior Restorative Procedure can help keep you on schedule ... because we know your time outside of work matters.

www.3MGulf.com/espe

Single Bond
Universal Adhesive



Filtek™ Bulk Fill
Posterior Restorative



Elipar™
DeepCure-S
LED Curing Light



Sof-Lex™ Spiral
Finishing and
Polishing Wheels



High-Temperature Furnace for More Speed

By Dentsply Sirona

For high masticatory forces, zirconium oxide is the material of choice. The new CEREC SpeedFire sintering furnace accelerates processing time. In this way Dr. Michael Skramstad from Minnesota, USA, can provide his patients in a single visit. Zirconium oxide is almost as hard as dental alloys. The biocompatible ce-

ramic has been successfully used in dentistry for over 15 years – first only as a veneering framework material and for the last six years also for full anatomical crowns. This gives me the assurance to now use the material chairside when placing a crown that still has to sit perfectly years from now.

Besides its high stability and du-

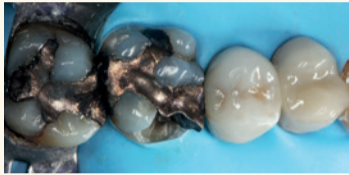rability, zirconium oxide has two more important advantages: The flexural strength of the material allows me to fabricate restorations with very thin wall thicknesses. This enables me to prepare the tooth in a substance friendly way. In addition, restorations can be placed more easily: Traditional cement rather than adhesive bonding is used.

Making Good Use of Waiting Times

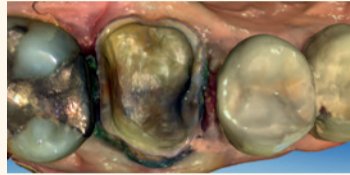
Fabricating and placing full contour zirconia restorations in one appointment is possible due to the fact that I can sinter dry-milled zirconium oxide very quickly with the new CEREC SpeedFire furnace. For one crown, the device usually requires between 12 and 15 minutes. The entire production process therefore takes less

patients. My assistant also operates the CEREC SpeedFire. The user interface is self-explanatory. The restoration just needs to be placed on the occlusion surface and the start button pressed – that is all. Dental assistants can also do repolishing, individualization and glazing. I only come back in the treatment room once the crown has been glazed and is ready for placement.

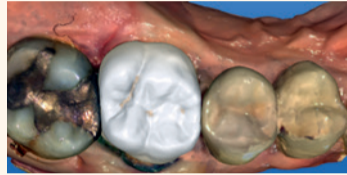
CROWN RESTORATION MADE BY CEREC ZIRCONIA



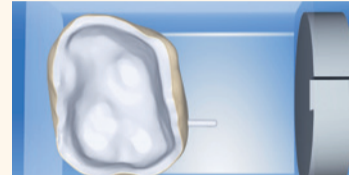1. After a cusp fracture in a tooth restored with amalgam, I proposed a CEREC crown made of full contour zirconia



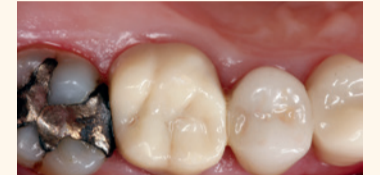2. I drew in the preparation margins on the virtual model with the help of the automatic margin finder



3. The CEREC software reconstructs the crown automatically with the Biojaw algorithm

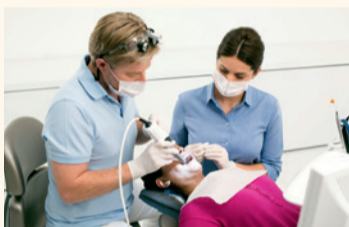

4. In the preview, I checked the position of the crown in the ceramic block. Adjustments could be made at this point if needed



5. Finally, I placed the finished polished crown made from pre-colored zirconium oxide in the patient's mouth

FABRICATION OF ZIRCONIUM OXIDE RESTORATIONS IN JUST UNDER TWO HOURS



Digital impressions: The scan with Omnicam is done in the same way as with conventional CEREC restorations (2 min)



Designing on CEREC AC: Excellent initial proposals are generated with the Biojaw algorithm (8 min)



Milling: Zirconium oxide is milled in enlarged form. This allows for more detailed finishing of the structures (10 min)



Sintering: The assistant places the restoration in the CEREC SpeedFire furnace and starts the sintering process with a touch-pad (16 min)



Polishing and glazing: The restoration can be individualized between both steps (12 min)

TITANIUM RELIABILITY

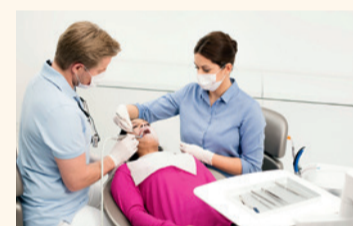



LIGHTWEIGHT
NON-SLIP BODY
22 WATT
POWERFUL TORQUE
QUIET OPERATION
NO MORE BUR FLY OUT
CERAMIC BEARINGS
COMPATIBILITY WITH OTHER COUPLINGS



Your reliable dental handpiece





Low Speed Handpiece set for General Application



Fitting and finishing: The restoration is cemented in the usual way. The remaining cement residue is then removed and the margins smoothed (8 min)

IMAGES AND ADDITIONAL INFORMATION

The CEREC SpeedFire sintering furnace



than 90 minutes. Patients do not mind having to wait such a short time for their crown and use the time to read or watch a film. There is no need for them to make a second appointment and they do not require a temporary. An immediate restoration makes a lot of sense from a clinical perspective because it allows for better preservation of the remaining tooth substance.

I personally devote only around 30 minutes of my work time to this process. In the meantime, I do the preparation, take an impression of it with CEREC Omnicam, design the restoration and then fit it into place. I then delegate the remaining work steps to my assistant. While the crown is milled on the CEREC MC XL Premium Package, I tend to other

As a long-time CEREC user, I know and appreciate the advantages of being able to produce crowns, inlays, onlays and bridges in just one session. The chairside process is a comfort that my patients have known and expected from us for 12 years already. By now, all four dentists in my practice use CEREC. Chairside restorations have become indispensable for our practice and contribute significantly to its economic success. For some time now, I have been hoping to be able to produce full anatomical zirconia restorations in my practice and provide them in one visit. When Dentsply Sirona CAD/CAM made this possible with CEREC, I immediately included the fabrication of full contour zirconia crowns as part of my services.

Producing Zirconium Oxide Easily in The Practice

My experiences with CEREC Zirconia have been very positive. Fabricating dental prostheses from full contour zirconia using CAD/CAM technology is easy; we familiarized ourselves with the process very quickly. This is not surprising since the process is hardly any different from producing other milled restorations. By means of full anatomical zirconium oxide chairside fabrication with CEREC becomes even more versatile and economical. A great benefit for my practice! ^[1]

First publication: VISION, Customer magazine of Dentsply Sirona; Issue 1/2016, p. 32-34



Dr. Michael Skramstad is a dentist in Orono, Minnesota, USA. He specializes in restorative and cosmetic dentistry as well as implantology.

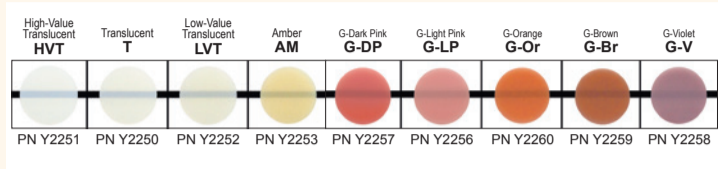
He is a certified trainer for Patterson Dental and lectures internationally on digital dentistry.

Pink & White Aesthetics with BEAUTIFIL II

By SHOFU

BEAUTIFIL II ENAMEL and GINGIVA from Shofu are developed as a complementary line extension of BEAUTIFIL II to easily create life-like direct aesthetic restorations. A special one-push syringe ensures controlled dispensing of the smooth and creamy material that is easy to sculpt into fine details and recreate the surface textures seen in natural teeth & gum.

Integration of nanofillers and newly developed organic-inorganic filler complex into a unique silanol modi-



fied resin network imparts BEAUTIFIL II Enamel and Gingiva with exceptional handling characteristics, longer working time, high abrasion/wear resistance, stable shades, effortless and superior polish with sustained polish retention for lasting aesthetics. Shofu's proprietary S-PRG fillers offer additional fluoride benefits and anti-plaque effect on the restoration surface.

BEAUTIFIL II ENAMEL is available in 4 naturally translucent and opalescent, Value based shades that facilitate life-like shade reproduction and value adjustment in the final restoration to meet individual clinical needs.

Beautifil II GINGIVA is available in 5 natural shade variations of pink to match all ethnicities and easily mim-



ic patient's individual gum while restoring areas with receded or missing gums/papilla, cervical defects,

root caries/erosion, exposed PFM margins and abutments to achieve red and white aesthetic harmony. [D1](#)

Dentsply Sirona appoints new group Vice President of CAD/CAM Systems

By DTI

BENSHEIM, Germany/SALZBURG, Austria: Dentsply Sirona has announced that Dr Frank Thiel will be succeeding Dr Joachim Pfeiffer as head of the company's strategic CAD/CAM business unit. Owing to the Dentsply-Sirona merger at the

beginning of 2016, Pfeiffer's tasks as chief technology officer will keep expanding and Thiel, who was previously involved in the development of the CEREC Omnicam 3-D intra-oral scanner, will take over his responsibilities in the development, production and acquisition sections of the CAD/CAM division.

Thiel will be sharing the management position of the division with Roddy MacLeod, who will be in charge of product management, marketing and control.

Thiel has been working in the company's CAD/CAM division for more than 12 years. From 2009 to 2016, he

held the position of head of development for optical 3-D measurement technologies, and he oversaw basic development from 2006 to 2009. Thiel began as a development engineer at the then Sirona Dental Systems and took over management of the development projects soon afterwards. Prior to his career at the

company, Thiel was involved in basic research in the fields of atomic, molecular and electronic physics, as well as photonics. [D1](#)

A-SILICONE IMPRESSION MATERIAL

PRESIDENT The Original

New Putty super soft consistency - very smooth and easy to mix -
PRESIDENT wash materials show perfect flow behavior under pressure -
to capture all marginal details precisely
New, fresh colors provide better contrast and more accurate detail readability -

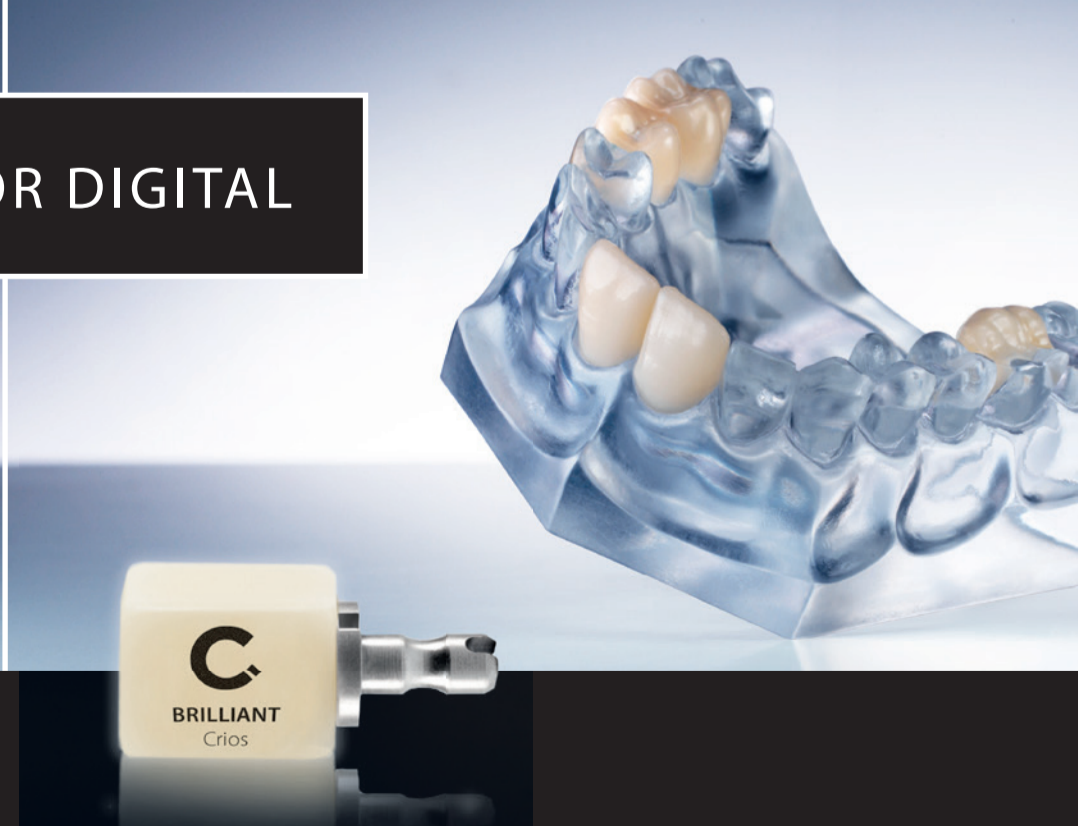

ANALOG OR DIGITAL

REINFORCED COMPOSITE BLOC FOR PERMANENT RESTORATION

BRILLIANT CRIOS High performance – made brilliant

High flexural strength – resistant restorations -
Tooth-like modulus of elasticity – shock absorbing -
Wear resistant and gentle to the antagonist -



Congress on Guided Biofilm Therapy (GBT)

By E.M.S.

DIVONNE LES-BAINS, France: More than 30 years ago, EMS developed AIR-FLOW® and PIEZON® NO PAIN and since then continuously improved these technologies. In July 2016, it is time to launch the next game changer: EMS presented the Guided Biofilm Therapy (GBT). The GBT revolutionizes what Axelsson and Lindhe started more than 40 years ago and will set a new standard in dental maintenance and oral hygiene. International guest speakers from Universities, Dental Offices and the Swiss Dental Academy were

invited to a two-day conference in Divonne Les-Bains. The summit provided a stage where dental professionals could discuss biofilm management, the main causes of biofilm and the clinically effective ways to remove it.

The Game Changer

"I believe that education and awareness is key to making game changers out of our colleagues." (Jolene Pinder, Dental Hygienist)

EMS organised the GBT conference under the heading "How to manage biofilm and its effective removal?"

The presented 'Game Changer' was developed in close cooperation with universities, dentists, dental hygienists and EMS specialists. Therefore, it is no surprise that Nina Von De Fenn, prophylaxis professional and trainer at the Swiss Dental Academy, is "proud to be a game changer". Indeed, dental maintenance and oral hygiene has never been as important as it is today: The participants feel like pioneers who experience a high standard homogenous solution for every patient. And it seems that a new gold standard has been created in the field of prophylaxis, coming straight out of Switzerland.

"I believe that education and awareness is key to making game changers out of our colleagues"

The GBT is safer, more comfortable and more efficient than conventional methods. Thus, it is definitely time to change the game!

Try it and you like it

"GBT meeting made me realize that AIR-FLOW® can be used not only in periodontal maintenance but also for active treatment – periodontitis, peri-implantitis and peri-implant mucositis." (Dr. Dong Xiao Xiao, Periodontist)

The GBT, which is a detailed clinical protocol, ensures a high standard in dental maintenance and facilitates complete removal of biofilm sub- and supra-gingivally. The GBT aims to bring a fast and comfortable treatment to any patient profile with the use of the high technology powder PLUS based on Erythritol, the AIR-FLOW® and the PIEZON® NO PAIN technologies. Be it children, sensitive patients, recall or pre-surgery prophylaxis, the GBT offers a complete solution. The GBT, this new, simple and predictable approach to professional dental maintenance, begins with the use of a disclosing agent. It guides the dental professional to see the biofilm normally not visible to the naked eye and to demonstrate biofilm presence to the patient. This procedure is followed by removal of biofilm and stains from the hard and soft tissues sub- and supra-gingivally by using AIR FLOW® with the very fine Erythritol powder PLUS. After this procedure, calculus and concretions are easy to detect and can be removed using PIEZON® NO PAIN and the PS instrument. Scaling is only needed if there are hard deposits. Therefore, GBT provides a minimal invasive therapy. Afterwards, the GBT is completed with a quality control and the recall management.

Nevertheless, the presentation of the detailed GBT protocol was only one of the highlights of the conference. The guest speakers like Prof. Magda Mensi, Dr. Klaus-Dieter Bastendorf, Eva Müller, Karen Davis and Brigitte Schöneich, board member of the European Dental Hygienist Federation, offered a course on pathogenic biofilm, the history of biofilm removal and the challenges of clinical cases. With a total of 18 speakers a variety of topics was treated, including hand piece technique and literature analysis. The attendants were professors, dentists, dental hygienists and dental assistants, actively involved in dental prophylaxis either at the clinics or in dental universities. The aim of the congress on Guided Biofilm Therapy was essentially to build a common understanding of the need to introduce the approach towards prophylaxis – based on knowledge, experience and supported by clinical evidence. Every presenter shared his personal opinion on best practices including challenges which were differentiated and country specific.

GBT – no conflict of ethics and profitability

"I prefer to earn money with the health of my patients (GBT), than the diseases of my patients!" (Dr.



**THE LEADING DENTAL LAB IN GCC
SINCE 1995**

White Crown Building, Apt. 1901, P.O. Box 12135, Dubai, U.A.E.
Tel.: +971 4 3329201, Fax: +971 4 332 9210, Email: info@mdentlab.com, www.mdentlab.com



Middle East Dental Laboratory



Middle_East_Dental_Laboratory

◀Page 8

Klaus Dieter Bastendorf, Dental Specialist in Prevention)

It has long time proven that oral biofilm causes caries, gingivitis, periodontitis, peri-implantitis and peri-odontitis – the main causes of tooth and implant-loss. Helping patients to keep their natural teeth is one of the highest ethical values for a dentist and the GBT makes this possible. As the dentist is not only a medical scientist, but also an entrepreneur, the profitability of a treatment is an important aspect. With the GBT the dentist can delegate this service to a dental hygienist and therefore generate further revenue and profit. Additionally, the GBT opens the opportunity to run a successful recall operation in a dental cabinet. Emphasizing on patient motivation and individual oral hygiene education, the GBT strengthens the relation between the dental professional and his patient by increasing patient satisfaction and personal well-being. Following the GBT protocol, patients are not only enthusiastic for a dental prophylaxis but it also serves them as an incentive to keep their oral hygiene at the optimal level even at home. Thus, the GBT provides a sustainable and long-lasting improvement of health and attractiveness. As the GBT offers a maximal patient comfort, it subsequently increases the patient recall.

Oral health: Why annoy when you can enjoy

“With Guided Biofilm Therapy, no more patients complain, only smiles” (Prof. Magda Mensi, University of Brescia)

The GBT congress emphasized the importance of high-quality dental maintenance. The effective removal of biofilm is paramount to long-term oral health. Thus, it's definitely time to provide the neglected fields of dentistry – dental maintenance and prevention – the reputation they deserve. Indeed, the awareness of dental care and oral hygiene has never been as high as it is today. And that is why the GBT protocol is so vital. Conventional dental prophylaxis with hand instruments, rubber cups and abrasive pastes – the so-called gold standard – is not up to date anymore but is still used by over 80% of dental professionals. These methods induce recession when used in a sulcus, create scratches on exposed dentine or cementum, remove natural enamel structure and obviously, this treatment is not comfortable for the patient at all. Jasmina Karisik, dentist, has only one answer to this: “Guided Biofilm Therapy – finally to replace the traditional way of thinking that endodontics is the savior.”

Perio for a better life

“GBT and its focus on general health aspects reducing massively the overall oral bacterial load – thus reducing health risks” (Kleathis Manolakis, Prosthodontist)

Compared to conventional methods, the GBT is more comfortable, safer and makes professional dental maintenance feel more like a wellness treatment instead of an unloved medical examination: The AIR-FLOW® Powder PLUS has a grain size of only 14µm, therefore it feels very soft, even if applied sub-gingivally! The presentations convinced the attending dental professionals: “GBT meeting encouraged me to use PLUS powder for all my periodontal and implant maintenance patients”, states Jolene Pinder, Dental Hygienist. And with PIEZON® NO PAIN – composed of PIEZON® NO PAIN Module, Original PIEZON® handpiece and Original SWISS INSTRUMENTPM PS – the removal of


calculus and concretions is comfortable and safe. And the long-term benefits are remarkable as well: By avoiding over-instrumentation you preserve the natural tooth structure, the implant surface and prevent root sensitivity. For the clinician, the approach of GBT reduces treatment time and hand fatigue with minimal use of ultrasonic. The safe and comfortable treatment is easy to adapt and decreases recolonization by biofilm due to antibacterial properties of Erythritol. Given the resulting advantages, it is not surprising that the prevailing mood at this congress

was dominated by an atmosphere of striving, positive spirit and overall optimism, confidence and trust in the future. It's time to shape the future of dental prophylaxis – it's time to change the game adopting the GBT protocol in dental maintenance.

SDA – Swiss Dental Academy

“SDA in China encourages the trainers to share the “real” knowledge to help the clinicians and patients through evidence based dentistry.” (Dr. Dong Xiao Xiao, Periodontist)

The GBT is based on the state of the art technologies AIR-FLOW® and PIEZON®. They are easy to handle and guarantee a high level of safety. Therefore, the GBT is easy to adapt for dental professionals. To learn more about the GBT and all the benefits it provides, we highly recommend the Swiss Dental Academy:

Experienced dental hygienists present clinical evidence for the GBT, offer pragmatic tips for the daily business and in the hands-on part of the course, the participants have the opportunity to experience the superiority of AIR-FLOW® and PIEZON® one-by-one. One thing we can certainly take from SDA and the congress on Guided Biofilm Therapy is the GBT, or in other words: ‘Get a much Better and more sustainable Treatment’. 

For further information visit us on www.byebyebiofilm.com and <https://int.sda-swissdentalacademy.com/>

Olga Honegger
T: +49 89 42 71 61 46
E: ohonegger@ems-ch.de



“With Guided Biofilm Therapy, no more patients complain, only smiles”

 CROIXTURE

PROFESSIONAL MEDICAL COUTURE



NEW COLLECTION

EXPERIENCE OUR ENTIRE COLLECTION AT WWW.CROIXTURE.COM