

implants

international magazine of oral implantology

2²⁰¹⁵

| **case report**

The challenge of aesthetic
implant restoration

| **research**

Mixed picture:
The state of periodontology in the UK

| **industry**

“It is our mission to simplify dental implantology”



More than
primary stability.
The new tapered standard.



The perfect symbiosis of design, material and surface –
the Straumann® Bone Level Tapered Implant:

- Roxolid® material – Reducing invasiveness with smaller implants
- SLActive® surface – Designed to maximize your treatment success and predictability
- Apically tapered – Excellent primary stability even in compromised bone situations
- CrossFit® connection – Simplified handling, legacy of Bone Level System

In combination with:





Dr Georg Bach

Wind of change

Dear reader,

Times are changing—with their song "Wind of Change", the Scorpions recognised the changing political situation in Europe already in 1990 and captured the spirit of the time. Our profession as implantologists is evolving currently in nearly as vehement a manner as these changes in the past. This assessment is not related to the political situation that affects our profession and work; it is due to the shift from analogue to digital dentistry.

A walk through the most recent International Dental Show in Cologne in Germany confirmed this impression. It is fascinating and surprising how rapidly and radically the new digital options are displacing traditional methods and ultimately replacing them entirely. In dental technology, this development is considerably more advanced.

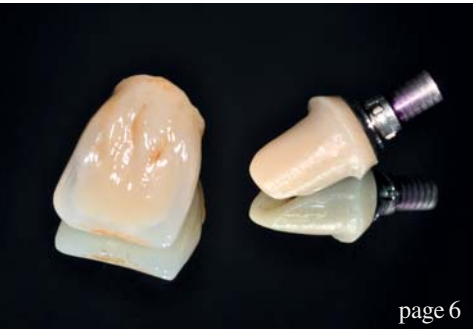These developments have already changed our profession and work and will continue to do so even more in the near future. As implantologists, we each have to face this transition in our own practice. As the German Association of Dental Implantology (DGZI), we are seeking to respond to these changes as well.

This objective will form a clear thread running through all the activities of the DGZI this year, beginning with the further expansion of our collaboration with dental technicians through our educational activities in the curriculum and study groups to our annual congress in Wiesbaden in October. There, you can experience the wind of change yourself, obtain information and engage in discussions.

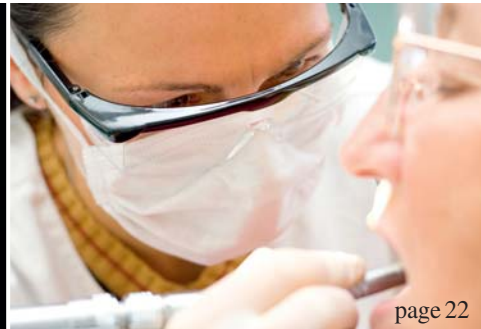Times are changing and we are well prepared.

Yours sincerely,

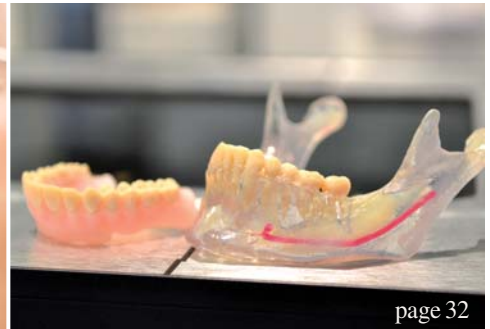Dr Georg Bach



page 6



page 22



page 32

| editorial

03 **Wind of change**
| Dr Georg Bach

| case report

06 **The challenge of aesthetic implant restoration**
| Dr Jan Spieckermann *et al.*

14 **Quality of implant surfaces and deficient osseointegration — Part I**
| Dr Nikolaos Papagiannoulis

18 **Treatment of an unusual presentation of radicular cysts**
| Dr Manthan Desai

| research

22 **Mixed picture: The state of periodontology in the UK**
| Prof. Francis Hughes

| industry

- 28 **“It is our mission to simplify dental implantology”**
- 30 **ClaroNav introduces new device for navigated surgery**
| Timo Krause
- 32 **3-D printing: Next generation of dental modelling**
| Georg Isbaner

| events

- 38 **Biggest IDS of all time in Cologne**
- 42 **6th International CAMLOG Congress**
- 44 **“We are planning to be the best and biggest EuroPerio to date”**

| laudatio

46 **Pioneer of implantology celebrates 90th birthday**
| Jürgen Isbaner

| news

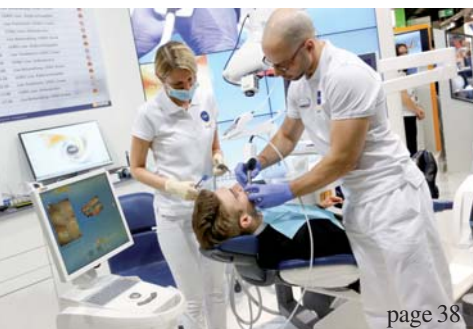- 26 **Manufacturer News**
- 48 **News**

| about the publisher

50 | imprint



Cover image courtesy of MIS Implants Technologies Ltd., www.mis-implants.com



page 38



page 44



page 46

Restoring happiness

Patients rely on you in order to eat, speak, and smile with confidence. It can be said, you are actually restoring quality of life and happiness.

To succeed, you need technology that is well founded and documented in science. That is why we only deliver premium solutions for all phases of implant therapy, which have been extensively tested and clinically proven to provide lifelong function and esthetics.

Moreover, with an open-minded approach, we partner with our customers and offer services that go beyond products, such as educational opportunities and practice development programs so you can rest assured that you have the support you need.

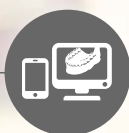
Reliable solutions and partnership for restoring happiness—because it matters.

Comprehensive solutions for all phases of implant dentistry




Professional and practice development

STEPPS™



Digital planning

SIMPLANT™



Regenerative solutions

SYMBIOS™



Implants

ANKYLOS™

**ASTRA TECH
IMPLANT SYSTEM**

XiVE™



Restorations

ATLANTIS™

The challenge of aesthetic implant restoration

Authors_Dr Jan Spieckermann & Jörg Wildenhain, Germany

The demands of treatment with implants are high, particularly in the aesthetically relevant areas. In the case of difficult morphological conditions, the individual wishes of patients regarding their natural appearance represent a major challenge for the treatment team. A host of materials and techniques for crowns and abutments allow for perfect imitation of the tooth structure. However, aesthetic restoration is only successful if a natural periimplant hard and soft tissue profile can be preserved or reconstructed. The following case study illustrates the complexity of implant treatment for combined horizontal and vertical bone resorption after the traumatic loss of the left central incisor.

Dental history and treatment plan

The most predictable, stable long-term aesthetic results are achieved through a synergistic process for di-

agnosis and therapy involving the various dental specialties. Science-based therapies need to be implemented with surgical and prosthetic precision and require the active participation of the patient both during and after treatment. A 29-year-old patient was referred to our oral surgery practice with the request for implant therapy in the anterior maxilla. He had lost the upper left incisor in an accident some months before. The gap had been treated with a flipper by the referring dentist. The removable restoration strongly affected the social well-being of the young man.

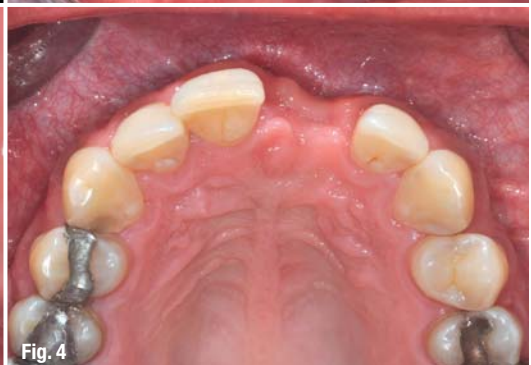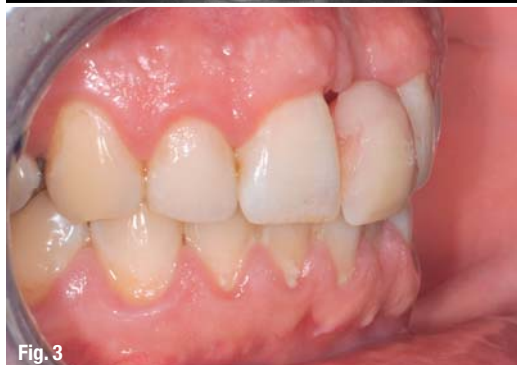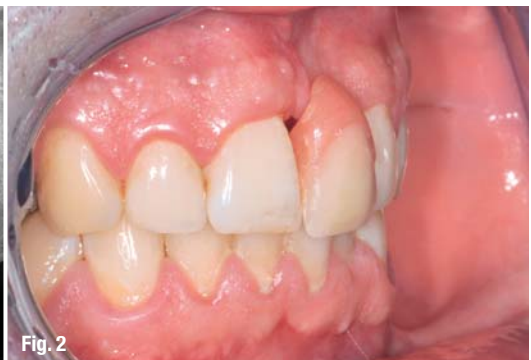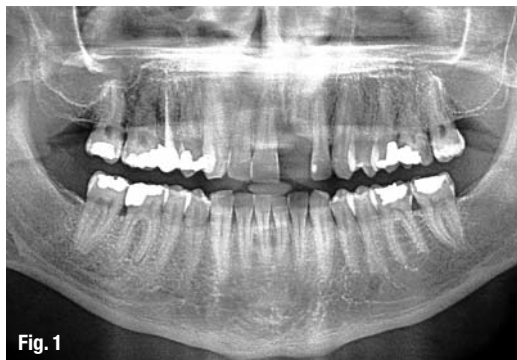Examination showed advanced horizontal and vertical bone resorption (Fig. 1). An extended plastic shield on the flipper was to visually compensate for bone loss (Fig. 2). This untoward design of the flipper exerted continuous pressure on the alveolar ridge owing to the rotary freedom around the clamping axis, particularly during removal but also during chewing motions. The

Fig. 1_The X-ray shows progressive horizontal and vertical bone resorption.

Fig. 2_The too long gingiva shield contributes to resorption due to the rotational freedom of the flipper.

Fig. 3_To avoid further traumatisation of the soft tissue, the flipper shield was shortened.

Fig. 4_The occlusal top view shows the horizontal hard and soft tissue deficit in the implant region.



Implant planning made easy

Planmeca PlanScan®

Planmeca ProMax® 3D

3^x
3D

Planmeca Romexis® software offers a completely integrated and digital workflow for modern implantology. From intraoral scanning to easy prosthetic design and realistic implant libraries, the most sophisticated implant planning tools are just a few clicks away.

- All the scanned and design data for prosthetic works is immediately available and can be mapped with the patient's CBCT data
- Use crown library or patient-specific crown from CAD system
- Verify the implant plan with verification tool
- Order surgical guide directly from the software
- Share data easily with partners through **Planmeca Romexis® Cloud** image transfer service



Find more info and your local dealer

www.planmeca.com



Planmeca Oy Asentajankatu 6, 00880 Helsinki, Finland
Tel. +358 20 7795 500, fax +358 20 7795 555, sales@planmeca.com

PLANMECA

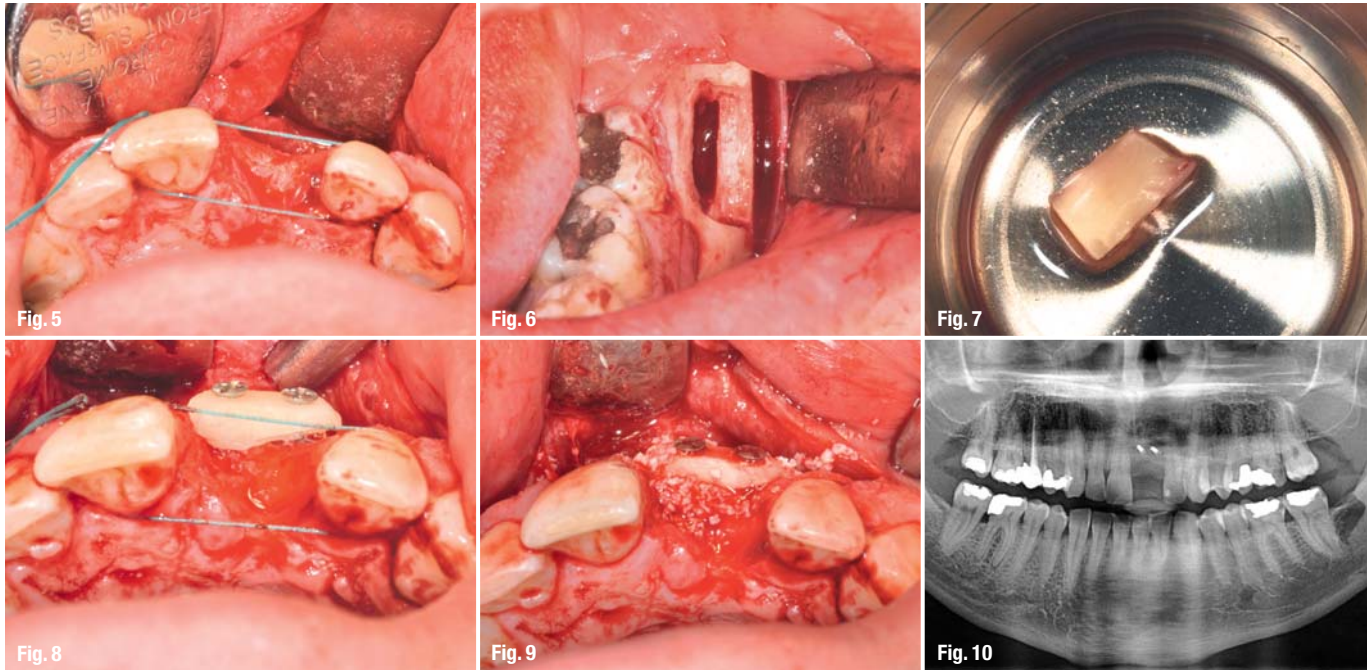


Fig. 5 A loop thread around the adjacent teeth illustrates the bone deficit.

Fig. 6 The bone block was harvested in sufficient size from the Corpus/Ramus mandibulae.

Fig. 7 The bone graft was stored in physiological solution until further processing.

Fig. 8 The autologous bone block was adapted to the shape of the host site. The focus was on the forming of the juga alveolaris.

Fig. 9 The cavities were filled with ground autologous bone chips and Bio Oss® was applied to the bone edges to protect against resorption.

Fig. 10 The X-ray control image shows the fixated bone block in the upper jaw and the donor site in the lower jaw.

unphysiological force induction influences the progression of bone resorption. To avoid further traumatization of the hard and soft tissue, we removed the gingival plate of the flipper and created a pontic-like design for region #21 (Fig. 3). With the exception of the pronounced bone deficit in region 21, there were no negative findings during examination of the anterior tooth region (Fig. 4).

We took impressions of the situation, prepared models and performed articulations. Then all therapeutic options were weighed against each other. We prepared a biological and financial cost-benefit analysis for each solution.^{1,2} We discussed all options in-depth with the patient. The justification for implantation was that both adjacent teeth were free of caries and should not be ground. Knowing that a correctly placed implant would prevent further resorption of the jaw bone, we prepared the most suitable treatment plan for the patient in our view.

The challenge of every treatment is the natural appearance of the restoration. The aesthetic characteristics proposed by Magne and Belser³ are part of our pre-prosthetic planning and are discussed by the team. The focus is on the condition and colour of the gingiva, achieving closed interdental spaces, a balanced profile of the gingiva, interdental contact points, the shape of the teeth, characterisation of the teeth and their texture, the alignment and position of the teeth, as well as the symmetry of the smile. The design of the convex structure of the alveolar bone ridge and the reshaping of the jugae alveolaris in the "red" area are just as important for a natural appearance as the perfect "white" crown reconstruction. Reconstruction of the bone deficit, both vertically and horizontally, requires a bone

block graft. In order to ensure the success of the surgical intervention for the 3-D placement of the implant, we opted for a two-stage procedure. In other words, the planned implant is inserted after regeneration of the bone.

Reconstruction of the bone defect

After administering local anaesthetic in both the donor and the host regions, a mediocrestal incision with vertical relieving incisions was performed in the anterior maxilla, distal to the adjacent teeth. In order to allow sufficient mobilisation of the mucoperiosteal flap and tension-free adaptation of the margins, the relieving incisions were extended over the mucogingival margin. Care was also taken to ensure that the flap edges were positioned on the local bone as this is where the growth factors for marginal regeneration originate. The mucoperiosteum/mucosal flap was prepared. To ensure blood supply to the flap, this was opened 5 mm apical to the mucogingival margin. The degree of bone deficit was demonstrated visually using a thread loop (Fig. 5).

A sufficiently large bone graft was harvested from the Corpus/Ramus mandibulae. This was preserved in physiological solution until the soft tissue at the donor site had been sutured (Figs. 6 & 7). We then adapted the cortical bone block as precisely as possible to the host site. In order to achieve an aesthetic overall outcome, attention was paid to the shaping of the juga alveolaris in the later implant region. The bone block was fixated with two osteosynthesis screws (Fig. 8). The remaining autologous bone material was ground and then used to fill the spaces between the block graft and the local bone (Fig. 9). Bio Oss® was added around the graft to



To experience something truly evolutionarily, you are cordially invited to attend our sponsor session lecture on June 4 & 5, at 10:30-12:00. Capital Suite 14-16. See our mini-site: v-implant.com

MIS Implants at the EUROPERIO8 in London: Capital Hall, Booth No 7 - so much to see!

... By *mis*[®]