

An evidence-based endodontic implant algorithm; untying the Gordian Knot

By Kenneth S. Serota, DDS, MMSc

Study the past, if you would divine the future.

— Confucius

The Endodontic Implant Algorithm provides highlights in the assessment and identification of determinant factors leading to endodontic failures, in order to help in the decision-making process whether or not it is adequate to implement a new endodontic approach vs. extraction and replacement with dental implants.

— Confusion

Over the years, endodontics has diminished itself by enabling the presumption that it is comprised of a narrowly defined service mix; root canal therapy purportedly begins at the apex and ends at the orifice.

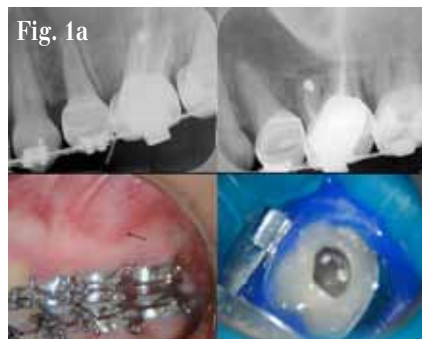Nothing could be further from the truth. It is the catalyst and precursor of a multivariate continuum, potentially the foundational pillar of all phases of any rehabilitation (Figs. 1a–1c).

Early diagnosis of teeth requiring endodontic treatment, prior to the development of periradicular disease, is critical for a successful treatment outcome.¹ Esthetics, function, structure, biologics and morphology are the variables in the equation of optimal oral health. Interventional or interceptive endodontics, restorative endodontics, the re-engineering of failing therapy, transitional endodontics and surgical endodontics encompass a vast scope of therapeutic considerations prior to any decision/tipping point to replace a natural tooth.

Everything we do as dentists is “transitional,” with the exception of extractions. No result is everlasting, none are permanent; thus our treatment plans must reflect this reality. Artifice versus a natural state is not a panacea for successful treatment outcomes (Fig. 2a–2d).

In 1992, funding from the Cochrane Collaboration was obtained for a UK Cochrane Center based in Oxford to facilitate the preparation of systematic reviews of randomized trials of health care.² The Cochrane Systematic Review is a process that involves locating, appraising, and synthesizing evidence from scientific studies in order to provide informative empirical answers to scientific research questions.

In 1952, the enterprising son of an inventor named Ron Popeil created infomercials using 30- to 120-second television spots to sell his inexpensive array of useful products, including the Pocket Fisherman and the Veg-O-Matic



Figs. 1a, 1b: Previous endodontic therapy on tooth #2.6 (14) had failed; the clinician chose to correct the problem with a microsururgical procedure on the MB root. This procedure failed over time as well (sinus tract). Radiographic and clinical evidence demonstrate the developing apical lesion. The root canal system was re-accessed, the untreated canal identified, the entire system debrided, disinfected and after interim calcium hydroxide therapy, obturated. One year later, the lesion has healed. While the retrograde amalgam remained in the root end, its presumed ability to effectively seal a complex apical terminal configuration was ill-considered. Everything leaks in time; retreatment is always the first choice for resolution of an unsuccessful endodontic procedure, where possible.

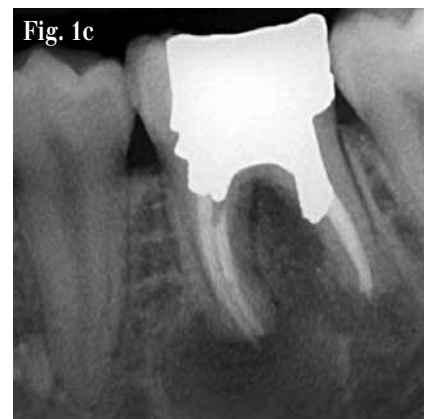
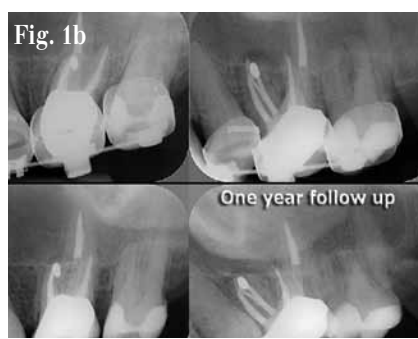
Fig. 1c: ‘Listening to both sides of a story will convince you that there is more to a story than both sides (Frank Tyger).’ The endodontic implant algorithm ensures that philosophy does not obscure pragmatism and expediency does not denigrate adaptive capacity.

food slicer. The singular goal of an infomercial was to get the viewer to a phone immediately and have them place their order. No waiting weeks, months or even years for the lofty marketing goals of branding to pay off. Somewhere along the way, dentistry morphed the two concepts. Nowhere is this becoming more apparent than in the debate on the endodontic implant algorithm. “We have met the enemy ... and he is us” (The Pogo Papers).

Scientific doctrine is the cornerstone of endodontic therapeutics. However, of late, anecdotal testimony has become the default setting for new paradigms to justify endodontic treatment modalities and an encomium to technologic advances. The strength of the arch of this or any specialty’s integrity and relevance must rely on a keystone of randomized clinical trials and evidence-based treatment outcomes. Expert opinions reflected through the looking glass of business models or global tours cannot replace stringently controlled clinical assessments distilled from exacting independent investigations. Science cannot be applied through a McLuhanistic rearview mirror of technology. The two must symbiotically occupy the same space regardless of whether that is antithetical to the Pauli Exclusion Principle, one of the most accepted laws of physics; no two objects can simultaneously occupy the same space.

In December 2004, Salehrabi and Rotstein³ published an epidemiological study on endodontic treatment outcomes in a large patient population. The outcomes of initial endodontic

treatment by general practitioners and endodontists participating in the Delta Dental Insurance plan on 1,462,936 teeth of 1,126,288 patients from 50 states across the United States were assessed in an eight-year timeline. Ninety-seven percent of teeth were retained in the oral cavity subsequent to nonsurgical endodontic treatment over this period. The combined incidence of untoward events such as retreatments, apical surgeries, and extractions was 3 percent and occurred primarily within three years from the completion of treatment. Analysis of the extracted teeth revealed 85 percent had no full coronal coverage. A statistically significant difference

was found between covered and uncovered teeth for all tooth groups tested, which is consistent with the findings from numerous investigations.^{4–6}

The purpose of this publication is to evaluate current trends and perceptions pertaining to the standard of care in endodontics and provide an evidence-based consensus on their relevance and application. Part II will address the algorithm by which sacrifice of natural structures for orthobiologic replacements can be validated and the engineering principles and designs that best mimic clinical dictates.

→ **EI** page 2C

AD

NEW EZ-Fill XPRESS

New EZ auto mix syringe:

- No Mixing
- Faster, more consistent, delivery
- Increased radiopacity

The EZ-Fill bi-directional spiral creates a lateral flow of cement sealing accessory canals.

EDS

89 Leuning Street • S. Hackensack, NJ 07606 • 800-22-FLEXI • 201-487-9090 • Fax: 201-487-5120 • www.edsdental.com

← **ET** page 1C

Evolutionary paradigm shifts

Three surveys have been conducted with the membership of the American Association of Endodontists since the late 1970s. The first reflected what is now an anachronistic view of emergency procedures and the standard of care defining non-surgical therapy during that period⁷; the second, done prior to the technologic advances of the last decade of the twentieth century, was hallmarked by a dramatic decrease in leaving pulpless teeth open in emergency situations and a significant decline in the use of culturing prior to obturation⁸.

The report indicated that the concept of "debridement and disinfection" versus "cleaning and shaping" was now the focus of the biologic therapeutic imperative and the need for expansive microbial strategies was recognized as being of paramount importance (Fig. 3). The primary patho-physiologic vectors of pulpal disease and the myriad complexity of the root canal system had always been understood; as the century closed, clinicians were provided with new tools and technology to expand the boundaries and limitations of endodontic treatment procedures (Figs. 4a, 4b).

Root canal infections are polymicrobial, characterized predominantly by both facultative and obligate anaerobic bacteria.⁹ The necrotic pulp becomes a reservoir of pathogens, toxic consequences and their resultant infection is isolated from the patient's immune response. Eventually, the microflora and their by-products will produce a periradicular inflammatory response. With microbial invasion of the periradicular tissues, an abscess and cellulitis may develop. The resultant inflammatory response will initiate either a protective and/or immunopathogenic effect; additionally, it may destroy surrounding tissue resulting in the five classic signs and symptoms of inflammation: calor, dolor, rubor, tumor and penuria. Patient evaluation and the appropriate diagnosis/treatment of the source of an infection are of utmost importance.

Patients demonstrating signs and symptoms associated with severe endodontic infection (Table I) should have the root-canal system filled with calcium hydroxide and the access sealed. In the event of copious drainage, the access can be left open for no longer than 24 hours, the tooth then isolated with rubber dam, the canals irrigated and dried and calcium hydroxide inserted into the root canal space and the access sealed.¹⁰

The antibiotic of choice for periradicular abscess remains Penicillin VK; however, recent studies have reported that amoxicillin in combination with clavulanate (1 gm loading dose with 500 mg q8h for seven days) was a more effective therapeutic regimen.¹¹

Systemic antibiotic administration should be considered if there is a spreading infection that signals failure of local host responses in abating the dispersion of bacterial irritants, or if the patient's medical history indicates conditions or diseases known to reduce the host defense mechanisms or expose the patient to higher systemic risks.

→ **ET** page 3C

Fig. 2a

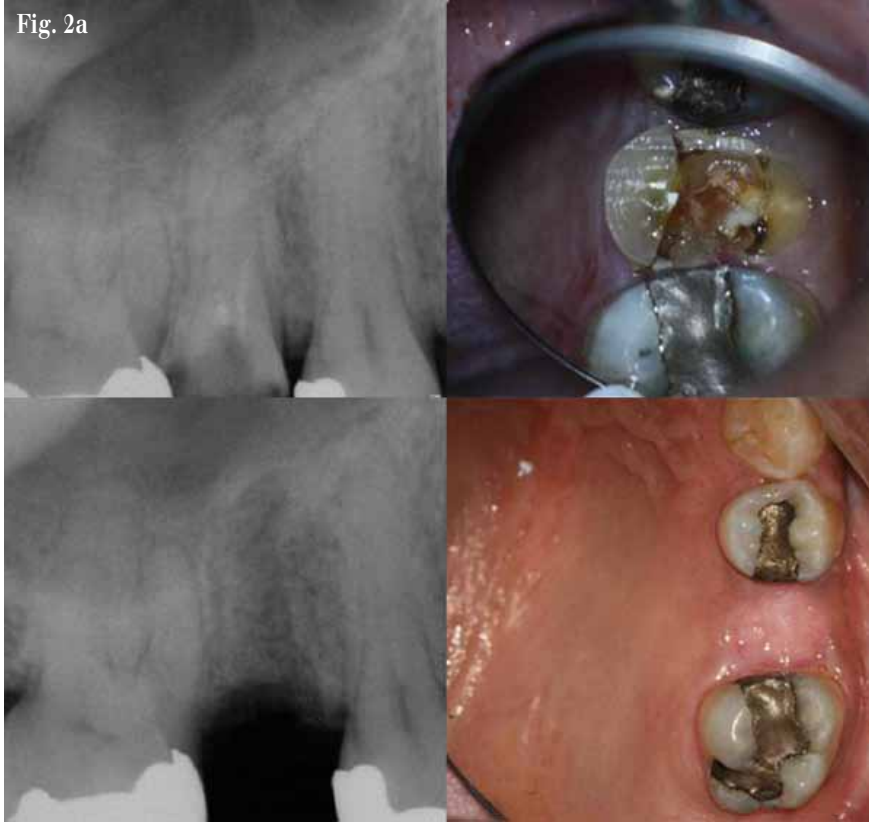
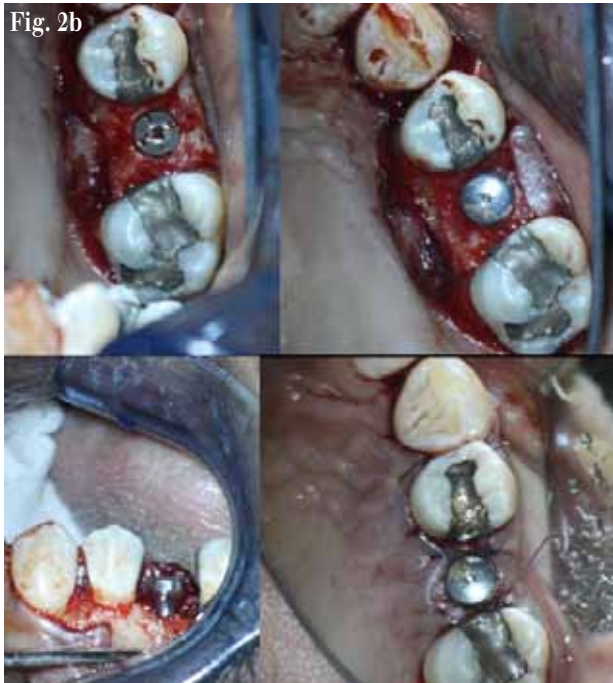
Fig. 2b



Figs. 2a, 2b: Tooth #1.5 (4) was determined to be non-salvageable. It was removed, the socket stimulated to regenerate and in four month's time an ANKYLOS® implant inserted, a sulcus former placed and the tissue closed over the site to allow for osseointegration to occur.

Dental Collab BETA
FINALLY A SOLUTION FOR GETTING
THAT SECOND OPINION.
WWW.DENTALCOLLAB.COM
FIRST MONTH FREE
CODE: ITDC09
IT'S NEW

**Tell us
what
you
think!**

Do you have general comments or criticism you would like to share? Is there a particular topic you would like to see more articles about? Let us know by e-mailing us at feedback@dental-tribune.com. If you would like to make any change to your subscription (name, address or to opt out) please send us an e-mail at database@dental-tribune.com and be sure to include which publication you are referring to. Also, please note that subscription changes can take up to 6 weeks to process.

ENDO TRIBUNE

The World's Endodontic Newspaper • U.S. Edition

Publisher & Chairman

Torsten R. Oemus
t.oemus@dental-tribune.com

Vice President Global Sales

Peter Witteczek
p.witteczek@dental-tribune.com

Chief Operations Officer

Eric Seid
e.seid@dental-tribune.com

Group Editor & Designer

Robin Goodman
r.goodman@dental-tribune.com

Editor in Chief Endo Tribune

Frederic Barnett, DMD
BarnettF@einstein.edu

International Editor Endo Tribune

Prof. Dr. Arnaldo Castellucci

Managing Editor/Designer

Implant & Endo Tribunes
Sierra Rendon
s.rendon@dental-tribune.com

Managing Editor/Designer

Ortho Tribune & Show Dailies
Kristine Colker
k.colker@dental-tribune.com

Online Editor

Fred Michmershuizen
f.michmershuizen@dental-tribune.com

Product & Account Manager

Humberto Estrada
h.estrada@dental-tribune.com

Marketing Manager

Anna Włodarczyk-Kataoka
a.wlodarczyk@dental-tribune.com

Marketing & Sales Assistant

Lorrie Young
l.young@dental-tribune.com

C.E. Manager

Julia Wehkamp
j.wehkamp@dental-tribune.com

Dental Tribune America, LLC
215 West 55th Street, Suite #801
New York, NY 10001
Tel.: (212) 244-7181
Fax: (212) 244-7185

Published by Dental Tribune America
© 2010 Dental Tribune America, LLC
All rights reserved.

Dental Tribune America makes every effort to report clinical information and manufacturer's product news accurately, but cannot assume responsibility for the validity of product claims, or for typographical errors. The publishers also do not assume responsibility for product names or claims, or statements made by advertisers. Opinions expressed by authors are their own and may not reflect those of Dental Tribune America.

Editorial Advisory Board

Frederic Barnett, DMD (Editor in Chief)

Roman Borczyk, DDS
L. Stephen Buchanan, DDS, FICD, FACD
Gary B. Carr, DDS
Prof. Dr. Arnaldo Castellucci
Joseph S. Dovgan, DDS, MS, PC
Unni Endal, DDS
Fernando Goldberg, DDS, PhD
Vladimir Gorokhovskiy, PhD
Fabio G.M. Gorni, DDS
James L. Gutmann, DDS, PhD (honoris causa), Cert Endo, FACD, FICD, FADI
William "Ben" Johnson, DDS
Kenneth Koch, DMD
Sergio Kuttler, DDS
John T. McSpadden, DDS
Richard E. Mounce, DDS, PC
John Nusstein, DDS, MS
Ove A. Peters, PD Dr. med dent., MS, FICD
David B. Rosenberg, DDS
Dr. Clifford J. Ruddle, DDS, FACD, FICD
William P. Saunders, PhD, BDS, FDS, RCS Edin
Kenneth S. Serota, DDS, MMSc
Asgeir Sigurdsson, DDS
Yoshitsugu Terauchi, DDS
John D. West, DDS, MSD

← **ET** page 2C

Antibiotic treatment is generally not recommended for healthy patients with irreversible pulpitis or localized endodontic infections (Table II). Numerous studies with well-defined diagnosis and inclusion criteria failed to demonstrate enhanced pain resolution beyond the placebo effect.^{12, 15}

The sophistication of endodontic equipment, materials and techniques has been steadily iterated and innovated since the second survey. The microscope first introduced to otolaryngology around 1950, then to neurosurgery in the 1960s, is now standard of care for the voyage into the microcosmic world of the root canal system. Recursions in the micro-processing technologies of electronic foramenal locators begat unprecedented accuracy levels, improved digital radiographic sensors and software-enhanced diagnostic acumen, and ultrasonic units with a variety of tips designed specifically for use when performing both nonsurgical and surgical endodontic procedures minimized damage to coronal and radicular tooth structure in the effort to locate the pathways of the pulp. The treatment outcome of non-surgical root canal therapy at this point in time is far more predictable than at any other period in our history.

Diagnosis

Of all the technologic innovations embraced by endodontics, digital radiography should have generated the greatest impact; however, its value remains limited in diagnosis, treatment planning, intra-operative control and outcome assessment. Flat-field sensors still require three to four parallax images of the area of interest to establish better perception of depth and spatial orientation of osseous or dental pathology. These three-dimensional information deficits, geometric distortion and the masking of areas of interest by overlying anatomy or anatomic noise are of strategic relevance to treatment planning in general and in endodontics specifically¹⁴ (Figs. 5a, 5b).

Cone-beam computed tomography (CBCT) produces up to 580 individual projection images with isotropic submillimeter spatial resolution enhanced by advanced image receptor sensors; it is ideally suited for dedicated dento-maxillofacial CT scanning. When combined with application-specific software tools, CBCT can provide a complete solution for performing specific diagnostic and surgical tasks. The images can be resliced at any angle, producing a new set of reconstructed orthogonal images, and studies have shown the scans accurately reflect the volume of anatomic defects. The limited volume CBCT scanners best suited for endodontics require an effective radiation dose comparable to two or three conventional periapical radiographs and as such are set to revolutionize endodontics^{15, 16} (Fig. 6).

Three-dimensional pre-surgical assessment of the approximation of root apices to the inferior dental canal, mental foramen and maxillary sinus are essential to treatment planning. The ability of CBCT to diagnose and manage dento-alveolar trauma using multiplanar views, the determination of the

root canal anatomy and the number of canals, the detection of the true nature and exact location of resorptive lesions and the discovery of the existence of vertical and horizontal fractures outweigh concerns about the degree of ionizing radiation and the risks posed.¹⁷ Provided CBCT is used in situations where the information from conventional imaging systems is inadequate, the benefits are essential for optimization of the standard of care.

Patel reported that periapical disease can be detected sooner and more accurately using CBCT compared with traditional periapical views and that the true size, extent, nature and position of periapical and resorptive lesions can be accurately assessed.¹⁸ Using a new periapical index based on CBCT for identification of apical periodontitis, periapical lesions were identified in 39.5 percent by radiography and 60.9 percent of

cases by CBCT respectively ($P < .01$).

Simon et al compared the differential diagnosis of large periapical lesions with traditional biopsy. The results suggested CBCT might provide a faster method to differentially diagnose a solid from a

fluid-filled lesion or cavity, without invasive surgery.^{19, 20} In spite of the presence of artifacts, the learning curve related to image manipulation and the cost,

→ **ET** page 4C

AD



Dental Collab BETA
FINALLY A SOLUTION FOR MENTORING
WITH EXPERTS & PEERS.
WWW.DENTALCOLLAB.COM
FIRST MONTH FREE
CODE: ITDC09



NEW EZ-Fill XPRESS

The patented EZ-Fill bi-directional spiral whips EZ-Fill non-eugenol epoxy cement laterally preventing cement being driven past the apex providing a complete seal when used in conjunction with gutta percha.

Thoroughly fill canals quickly & economically.¹

Avoids shrinkage associated with lateral condensation & thermoplastic gutta percha.²⁻⁴

Eliminates the need for expensive thermoplastic equipment.

Coronal path of exit for excess cement eliminates stress.

New EZ auto mix syringe:

- No Mixing
- Faster, more consistent, delivery
- Increased radiopacity

The EZ-Fill bi-directional spiral creates a lateral flow of cement sealing accessory canals.

89 Leuning Street • S. Hackensack, NJ 07606 • 800-22-FLEXI • 201-487-9090 • Fax: 201-487-5120 • www.edsdental.com

EDS ESSENTIAL DENTAL SYSTEMS

1 Wu MK, Van der Sluis LWM, Ardila CN, Wessink PR. International Endodontic J 2003;36:533-540. 2 Cohen BL, Pagnillo MK, Musikant BL, Deutsch AS. The Evaluation of Apical Leakage for Three Endodontic Fill Systems. AGD (General Dentistry) 1998;46(6):618-623. 3 Musikant BL, Cohen BL, Deutsch AS. Simplified Obturation of Tapered Canal Preparations. Compendium 1998;19(11):1152-1155. 4 Lee CQ, Chang Y, Cobb CM, Robinson S, Hefluth EM. Dimensional Stability of Thermosensitive Gutta-Percha. J Endodon 1997;23(9):579-582. All Essential Dental Systems Products Are Backed By A 60-Day Satisfaction Guarantee. CE Approved Products. Essential Dental Systems and EZ-Fill are registered trademarks of Essential Dental Systems, Inc.

← **ET** page 3C

cone-beam tomography will invariably be the accepted standard of diagnostic care and treatment planning in endodontics in the very near future.

Access

An improperly designed access cavity will hamper facilitation of optimal root canal therapy. If the orientation, extension, angulations and depth are inaccurate, retention of the native anatomy of the root canal space becomes precarious. The requirements of access cavity design can be achieved by conceptual and technical regression of the existing configuration to that which one would logically expect to have seen prior to the insults of restoration, function and aging. If tertiary dentin were perceived of as "irritational dentin" or dystrophic calcification considered "decay," the chamber outline could be used to blueprint an inlay configuration for the access design that literally replicates the "virgin" tooth (Fig. 7).

Removal of the existing restoration in its entirety and/or preliminary preparation of the coronal tooth structure for the subsequent full coverage restoration will identify decay, fractures, unsupported tooth structure and expose the anatomy of the underlying root trunk periphery, which assists in discovery of the spatial orientation and morphology of the roots. The pulp chamber ceiling and pulp stones can be peeled away with a football diamond bur to grossly identify the primary orifices.

Micro-etching (Danville Materials; San Ramon, Calif.) the floor of the chamber, perhaps the most underused of all access tools, is invaluable in the exposure of fusion lines and grooves in order to identify accessory orifices. Troughing with ultrasonic tips of any design is used solely to trace fusion lines, not affect gross removal. The use of ultrasonics to "jackhammer" pulp stones is simply too risky as one approaches the floor of the chamber, particularly if there are no water ports on the tips. Orifice lengthening and widening enables straight line glide path to the apical third. The strategic objective is not to impede the file, stainless steel or nickel-titanium rotary along the axial walls with minimal dentin removal (Figs. 8a, 8b).

It is equally important to produce a high-quality coronal restoration at the time of sealing the root canal system.^{21, 22} Despite research supporting the effectiveness of coronal barriers and the need for immediate placement as a component of the completion phase of root canal treatment, a universally

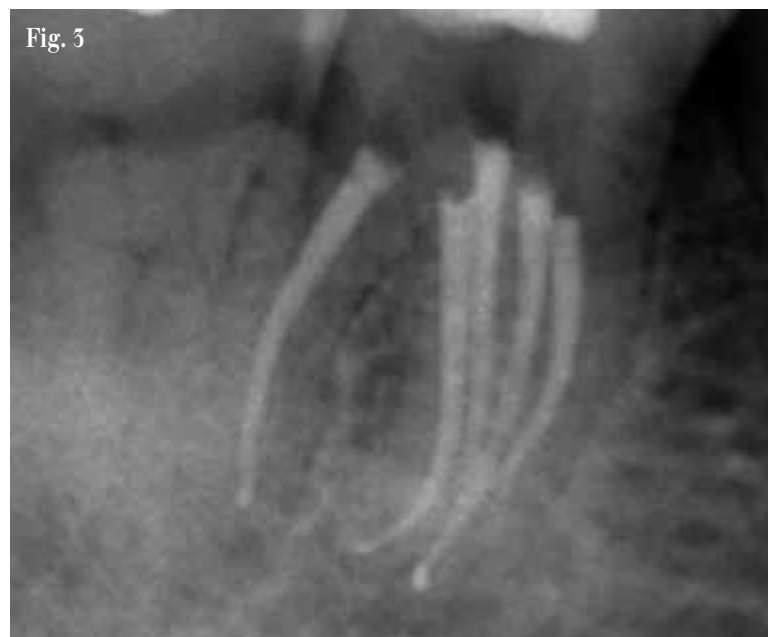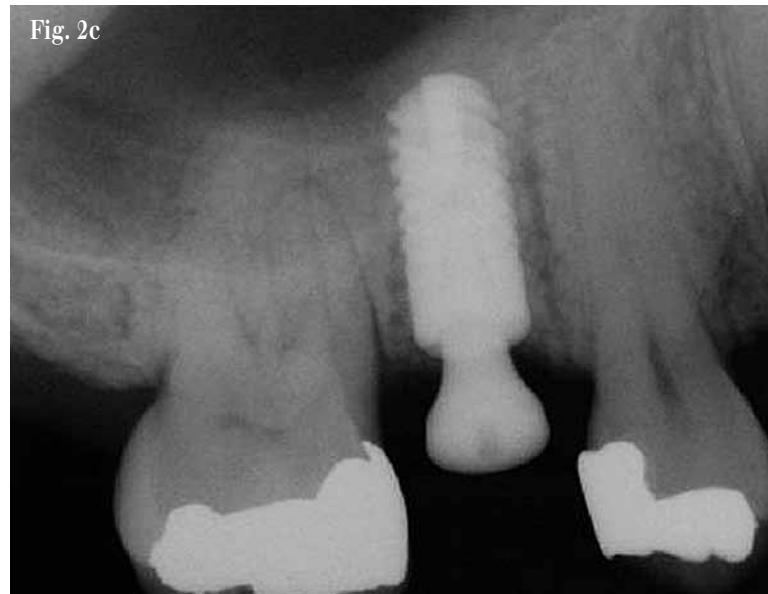

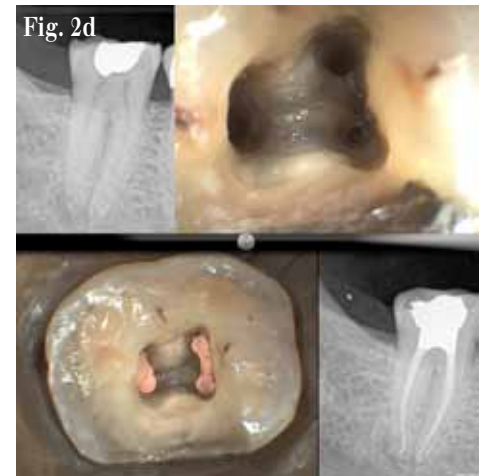
Fig. 3: The degree of complexity of the root canal system has been understood for most of the past century. The failure to negotiate the labyrinthine ramifications of the root canal system has purportedly been a function of technical limitation rather than comprehension and yet, it took until the mid-'70s to appreciate that thermolabile condensation of an obturating material could demonstrate a greater occlusive degree of the system than any other modality.

accepted protocol does not exist.

Schwartz and Fransman described a clinical strategy for coronal sealing of the endodontic access preparation that lists the following considerations in the protocol, use bonded materials [4th generation (three-step) resin adhesive systems are preferred because they provide a better bond than the adhesives that require fewer steps]; the "etch and rinse" adhesives are preferred to "self-etching" adhesive systems if a eugenol containing sealer or temporary material is used; "self-etching" adhesives should not be used with self-cure or dual-cure restorative composites. When restoring access cavities, the best esthetics and



Figs. 2c, 2d: The choice of a natural tooth versus an orthobiologic replacement will increasingly be a powerful force in dental treatment plans. The temptation to choose one or the other based on expediency vs. complexity, on marketing vs. science, is going to be the sine qua non of the standard of comprehensive care.

Fig. 4a

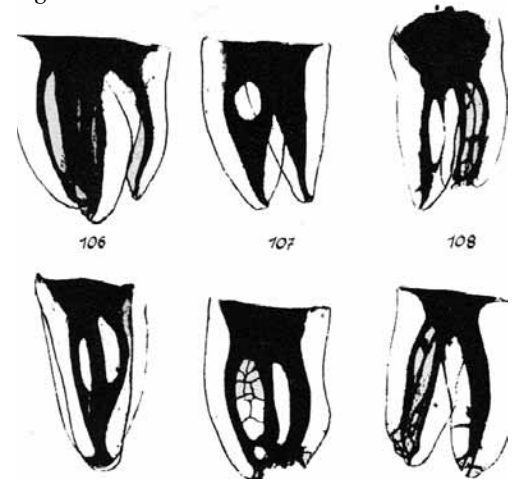


Fig. 4a: Panel of anatomic preparations from the classic work by Professor Walter Hess of Zurich, 'The Anatomy of the root canals of teeth of the permanent dentition,' London, 1925, John Bale, Sons & Danielsson.

highest initial strength are obtained with an incremental fill technique with composite resin. A more efficient technique that provides acceptable esthetics is to bulk fill with a glass ionomer material to within 2 to 3 mm of the cavo-surface margin, followed by two increments of light-cure composite and, if retention of a crown or bridge abutment is a concern after root canal treatment, post placement increases retention to greater than the original state²⁵ (Fig. 9).

Irrigation

The complex anatomy of the root canal space presents a daunting challenge to the clinician who must debride and disinfect the corridors of sepsis with absoluteness to achieve a successful treatment outcome (Fig. 10).

In addition, the absence of a cell-mediated defense (phagocytosis, a functional host response) in necrotic teeth means the microorganisms residual in tubuli, cul de sacs and arborizations are mainly affected by the redox potential (reduction potential reflects the oxidation-reduction state of the environment — aerobic microflora can only be active at a positive E_h , whereas strict anaerobes can only be active at negative E_h values) and availability of nutrients in the various parts of the root canal.²⁴

While our knowledge of persistent bacteria, disinfecting agents and the chemical milieu of the necrotic root canal has greatly increased, there is no doubt more innovative basic and clinical research is needed to optimize the use of existing methods and materials and develop new ones to prevent and treat apical periodontitis.

Varying degrees of sterility of the root canal space are achieved by mechanistic removal, the chemical reactivity and fluid dynamics of irrigants and their introduction to the canal space; however, the protocols used today cannot predictably provide sterile canals. As none of the elements of endodontic therapy (host defense system, systemic antibiotic therapy, instrumentation and irrigation, inter-appointment medicaments, permanent root filling, and coronal restoration) can alone guarantee complete disinfection, it is of utmost importance to aim at the highest possible quality at every phase of the treatment.

In the classic study by Sjogren et al, 55 single-rooted teeth with apical periodontitis were instrumented and irrigated with sodium hypochlorite and root filled. Periapical healing was followed-up for five years. Complete periapical

AD

Dental Collab BETA
FINALLY A SOLUTION FOR CONSULTING
ON-LINE WITH PATIENTS.
WWW.DENTALCOLLAB.COM

FIRST MONTH
FREE
CODE: ITDC09



→ **ET** page 5C

← **ET** page 4C

healing occurred in 94 percent of cases that yielded a negative culture.

Where the samples were positive prior to root filling, the success rate of treatment was just 68 percent — a statistically significant difference. These findings emphasize the importance of completely eliminating bacteria from the root canal system prior to obturation. This objective cannot be reliably achieved in a one-visit treatment of necrotic pulps because it is not possible to eradicate all infection from the root canal without the support of an inter-appointment antimicrobial dressing²⁵.

NaOCl is the most widely used irrigating solution. It is a potent antimicrobial agent and lubricant that effectively dissolves pulpal remnants and organic components of dentin, thus preventing packing infected hard- and soft-tissue into the apical confines. Hypochlorous acid (HClO) is the active moiety responsible for bacterial inactivation.

NaOCl is used in concentrations varying from 0.5 percent to 5.25 percent; the *in vitro* and *in vivo* studies differ significantly in terms of the effectiveness of the range of concentrations as the *in vitro* experiments provide direct access to microbes, higher volumes are used and the chemical milieu complexity of the natural canal space are absent as compared to the *in vivo*

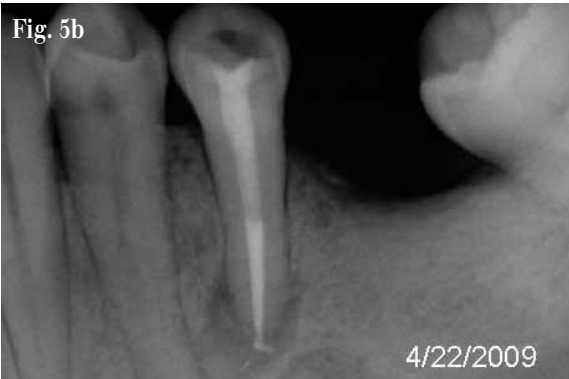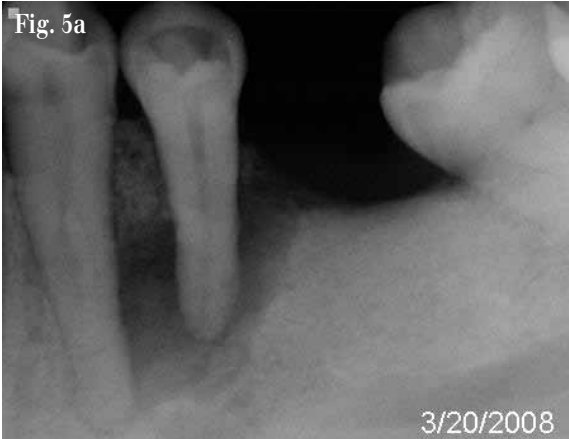→ **ET** page 6C



Fig. 4b: Vertucci FJ, 1984. Two thousand four hundred human permanent teeth were decalcified, injected with dye, and cleared in order to determine the number of root canals and their different morphology, the ramifications of the main root canals, the location of apical foramina and transverse anastomoses, and the frequency of apical deltas.

Table I and II: Derived from Antibiotics and the Treatment of Endodontic Infections, Summer 2006, American Association of Endodontics, Colleagues for Excellence.

Table I	Table II
Indications for adjunctive antibiotics	Conditions not requiring adjunctive antibiotics
Fever > 100°F	Pain w/o signs and symptoms of infection
Malaise	Symptomatic irreversible pulpitis
Lymphadenopathy	Acute periradicular periodontitis
Truisms	Teeth with necrotic pulps and radiolucency
Increase swelling	Teeth with a sinus tract (chronic periradicular abscess)
Cellulitis	Localized fluctuant swellings
Osteomyelitis	



Figs. 5a, 5b: Flat field sensors provide a sense of the extent of osseous pathology; however, the periapical radiographic image corresponds to a two-dimensional aspect of a three-dimensional structure. Periapical lesions confined within the cancellous bone are usually not detected. Thus a lesion of a certain size can be detected in a region covered by a thin cortex, whereas the same size lesion cannot be detected in a region covered by thicker cortex.

AD



Magnification

Magnification in dentistry is not a new concept to dental professionals.

However, *Seeing is believing*

Contact your local dealer to schedule a demonstration and change the way you "see" dentistry!



SEILER iQ AND EVOLUITON XR6

- Brightest standard light source
- Highest quality optics
- Best Warranty: Limited Lifetime



SEILER

(800) 489-2282 • www.seilerinst.com

← ET page 5C

experimentation. A study by Siqueira et al²⁶ showed no difference (*in vitro*) between 1 percent, 2.5 percent and 5 percent NaOCl solutions in reducing the number of bacteria during instrumentation. What has been shown is that the tissue dissolving effects are directly related to the concentration used.²⁷

Perhaps the most misunderstood aspect of NaOCl irrigation is the need for the quantities of irrigation required due to the morphologic and anatomic variations in the volumetric size of the root canal anatomy. Siqueira showed that regular exchange and the use of large amounts of irrigant should maintain the antibacterial effectiveness of the NaOCl solution, compensating for the effects of concentration.²⁸

Numerous devices have appeared in the endodontic armamentarium to address this situation:

- EndoVac (Discus Dental) — a negative pressure differential device designed to deliver high volumes of irrigation solution while using apical negative pressure through the office high-volume evacuation system,
- Negative Pressure Safety Irrigator (Vista Dental, Racine WI) — device is similar to EndoVac,
- Rinsendo (Air Techniques; Corona, Calif.) uses pressure suction technology; 65 ml of irrigant are automatically drawn from the attached syringe and aspirated into the canal [pressure created is lower than manual irrigation],
- VIBringe (Bisco Canada, Richmond, BC) in which sonic flow technology facilitates enhanced irrigation through the myriad complexities of the root canal system (Fig. 11).

NaOCl cannot dissolve inorganic dentin particles and thus prevent smear layer formation during instrumentation.²⁹ Chelators such as EDTA and citric acid are recommended as adjuvants in root canal therapy. It is probable that biofilms are detached with the use of chelators; however, they have little if any antibacterial activity.

Several studies have shown citric acid in concentrations ranging as high as 50 percent were more effective at solubilization of inorganic smear layer components and powdered dentin than EDTA. In addition, citric acid has demonstrated antibacterial effectiveness.

Technology and innovation will not negate the need for optimal preparation (debridement and disinfection) to eliminate microbial content and its impact on a necrotic root-canal system. We as a discipline need to be better; however, by the same token, endodontics has shown its commitment to endless reinvention. In time, that will restructure the role of natural teeth in foundational dentistry, currently diminished by the market forces of implant-driven dentistry.

Orthobiologic replacement is not a panacea as random clinical trials increasingly show; the severity of peri-implantitis lesions demonstrates significant variability and as such no treatment modality has shown superiority. The pendulum will continue to swing as the endodontic implant algorithm becomes increasingly multivariate.

→ ET page 7C

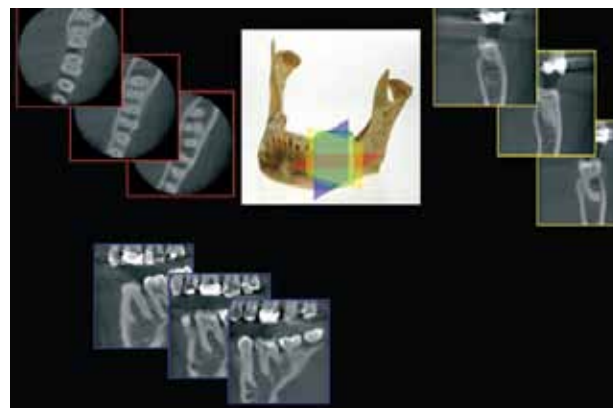


Fig. 6: All cone-beam tomography units provide correlated axial, coronal and sagittal multiplanar volume reformations. Basic enhancements include zoom or magnification and visual adjustments to narrow the range of gray-scale, in addition to the capability to add annotation and cursor-driven measurement.

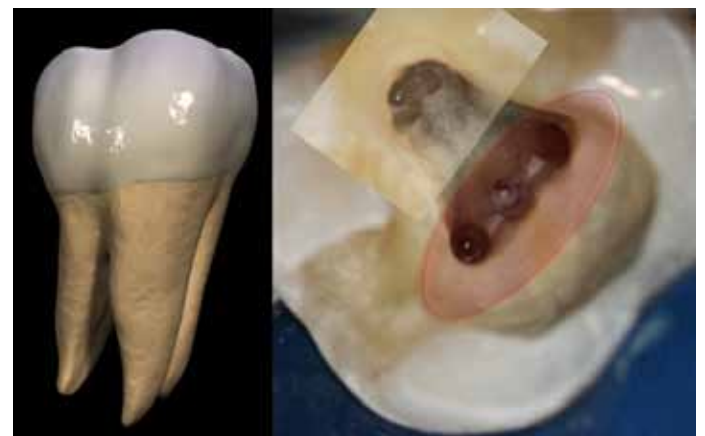

Fig. 7: Strategic extension of the access perimeter is too often undervalued in terms of successful endodontic treatment outcomes. The shape of the chamber must be regressed to its native state to ensure that axial interference is negated as an instrument traverses the length of the root canal space.

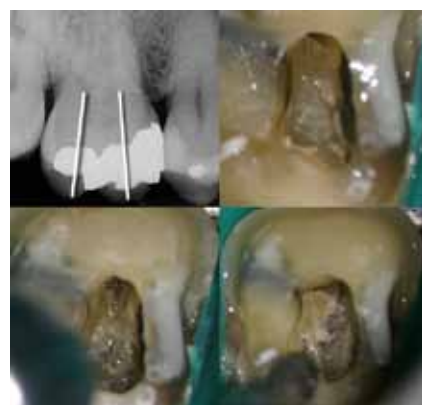

Fig. 8a: Dystrophic calcification confounds even the most experienced clinician. The key to identification of the orifices is to regress the inner space using the continuum, cusp tip, pulp horn and canal orifice. In lieu of an ultrasonic tip, which tends to chop the stone and scatter debris, gross removal is best done with a diamond bur in a high-speed handpiece. The fine removal of residue can be done with a multi-fluted carbide bur to trace the fusion lines.

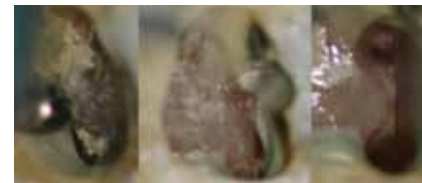

Fig. 8b: Keeping the chamber wet with alcohol improves optics and highlights color differential. The most important tool for orifice identification in addition to dyes is a micro-etcher. The satin finish produced highlights the disparity between the natural tooth structure of the floor and the secondary and tertiary dentin of the calcified orifice.

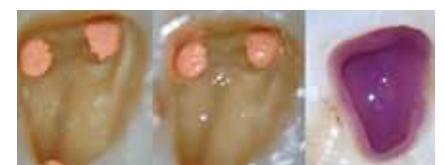

Fig. 9: Micro-etching ensures the removal of oils and debris as well as eliminating the residue in fusion lines and fissures. Routine dentin bonding is then performed. The composite chosen in this instance is Permaflo® Purple (UPI, South Jordan, Utah), which enables differentiation of restoration and tooth structure should re-entry be necessary.

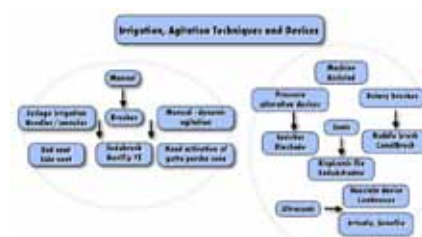

Fig. 10: A vast array of equipment exists in the marketplace to optimize irrigation protocols. Radical change may well be in the offing; however, research and development on bio-active obturating materials may prove to be the defining variable in total asepsis.




Fig. 11: Numerous investigators have shown the concept of keeping the apical foramen as small as practical does not mean a size 20 or 25 file. This Schilderian concept should read as small as the apical morphology permits in order to ensure the free flow of irrigant to the apical terminus enables more definitive cleaning of the apical segment of the root-canal space.

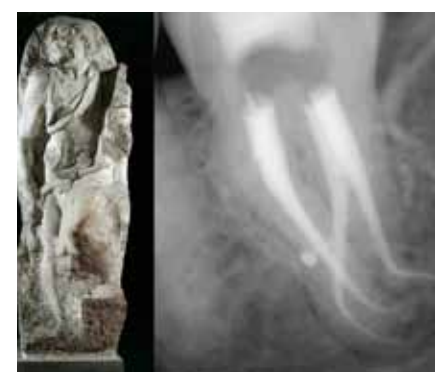

Fig. 12: The artist/clinician recognizes that negative space surrounding an object is equally important as the object itself. In the case of root canal therapy, the positive space is alterable, but must be created in balance with the encompassing negative space to ensure morphologic integrity.



Fig. 13: While there is no meta-analysis to elucidate this concern, the incidence of fracture of the mesial root of mandibular molars has been shown to have a significant correlation to cuspal fracturing.



Fig. 14a: At left, the working length has two reference points, coronal and apical. Failure to maintain patency at the minor apical diameter will cause loss of the apical reference point as a result of blockage, or ellipticization of the foramen.

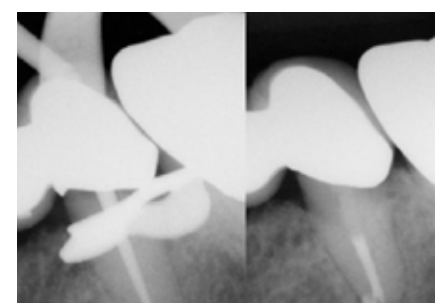


Fig. 14b: The volume of irrigant necessary to prevent apical blockage is indeterminant. While NiTi rotary instrumentation has minimized this to a significant degree, a slurry of dentin mud is always a risk factor to be monitored.

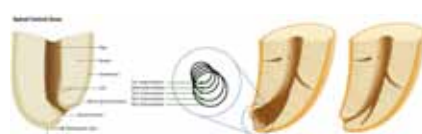

Fig. 15: Rheology is a science that addresses the deformation and flow of matter. The biochemistry of filling material, its viscosity gradient, the lubricating effect of sealer and optimal thermal application are only as effective as the flow characteristics of the shape created and its degree of cleanliness.

← ET page 6C

Microstructural replication — obturation

Steven Covey is known for his book “The Seven Habits of Highly Effective People.” The habit most applicable to endodontics is the second one: “Begin with the End in Mind.” The implication of this vision in regard to idealizing the final shape of the root-canal system to ensure that the obturation represents a totality is profound. The root canal is negative space and as such recovery of its original unaffected form is the sine qua non of obturation or more descriptively — microstructural replication.

Perhaps the most significant example of negative space recovery is Michelangelo’s statuary for the funerary of Pope Julius II. Four unfinished sculptures speak eloquently to this process: the figure was outlined on the front of the marble block and then Michelangelo worked steadily inward from this side, in his own words “liberating the figure imprisoned in the marble.” This is an exacting description of debridement and instrumentation of the root canal space prior to root filling after a myriad of pathologic vectors have destroyed the dental pulp, and altered the morphology/topography of the system (Fig. 12).

Incomplete filling of the debrided and sculpted root canal space is one of the major causes of endodontic failure⁵⁰. Until recently, *in vitro* testing (dye leakage, fluid transport, bacterial penetration, glucose leakage) was used to evaluate the sealing efficacy of endodontic filling materials and techniques by assessing the degree of penetration/absorbance of these tracers.⁵¹⁻⁵⁵

Unfortunately, leakage studies are limited static models that do not simulate the conditions found in the oral cavity (temperature changes, dietary influences, salivary flow). Given the historic dominance of *in vitro* testing, the clinician must be cautious when extrapolating study findings to the clinical situation, regardless of manufacturer’s claims.⁵⁴ This reliance on invalid testing protocols diminishes the “mono-block” assertions applied to the new generation of adhesive obturating materials proposed as the “replacement material” for gutta-percha.⁵⁵

Gutta-percha was introduced to dentistry by Edwin Truman in 1847.⁵⁶ The concept of thermo-labile vertical condensation of gutta-percha was originally described by Dr. J. R. Blaney in 1927.⁵⁷ The defining article on obturation remains Dr. Schilder’s classic on filling the root canal space in three dimensions published 40 years later.⁵⁸

Logically, one cannot physically fill the root canal in two dimensions; however, one can fill the root canal space badly, in three dimensions. This does not critique Dr. Schilder’s exposition, but it does demonstrate that words can easily be misconstrued and alter perspective once they become, as Kipling said, “the most powerful drug of mankind.” Ironically, Schilder’s article came seven years prior to his treatise on cleaning and shaping the root-canal system, which even to this day remains the iconic standard.

The Washington Study by Ingle indicated that 58 percent of treatment fail-

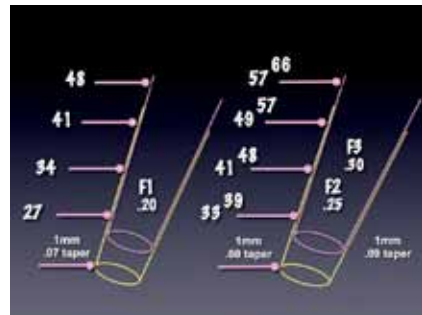


Fig. 16a: The ProTaper Universal System comprises two shaping files that address the planes of geometry of the coronal and middle thirds of the root canal space. There are five finishing files that include tips sizes, 20, 25, 30, 40 and 50. Tapers range from .06 to .09 through the series. A thorough understanding of the metrics is essential for the preparation of the myriad variations in internal micro-morphology of the root canal space and the assurance of minimal iatrogenic impact.

ures were due to incomplete obturation⁵⁹. The corollary is obvious; teeth that are poorly obturated are invariably poorly debrided and disinfected. Procedural errors such as loss of working length, canal/apical transportation, perforations, loss of coronal seal and vertical root fractures have been shown to adversely affect the integrity of the apical seal.^{40, 41}

The Toronto study evaluating success and failure of endodontic treatment at four to six years after completion of treatment showed that teeth treated with a flared canal preparation and vertical condensation of thermolabile gutta-percha had a higher success rate when compared with step-back canal preparation and lateral compaction. Highlighting the vertical condensation of warm gutta-percha obturation technique as a factor influencing success and failure simply confirmed a perspective evident to most endodontists from years of clinical empiricism.

There is a never-ending array of obturation materials, delivery systems and sealers appearing in the marketplace. Each is hallmarked by proprietary modifications and each is heralded as the most significant iteration in obturation since the previous one; today, we practice with a sad truism — marketing is inexorably directing science. However, gutta-percha in combination with a myriad of sealers and solvents remains the primary endodontic obturating material.

The dominant systems remain carrier-based obturation (Thermafil — Tulsa Dental Specialties; Tulsa, Okla.); Continuous Wave Compaction Technique (Elements Obturation — Sybron Endo; Orange, Calif.); and Thermoplastic Injection (Obtura III Max — Obtura Spartan; Earth City, Mo.).

Resilon (RealSeal — SybronEndo Corp., Orange, Calif.), a high-performance industrial polyurethane, was developed as an alternative to gutta-percha. There are scattered studies that show Resilon exhibits less microbial leakage⁴² and higher bond strength to root-canal dentin⁴⁵, reduced periapical inflammation⁴⁴ and enhanced fracture resistance of endodontically treated teeth when compared with gutta-percha⁴⁵ (Fig. 13). Other studies have reported undesirable properties

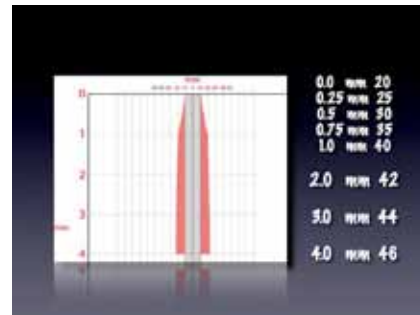


Fig. 16b: Modification of taper in last mm of the apical terminus, exaggerates the ‘constriction’ or minor apical diameter. Thermo-labile vertical condensation has been shown to enhance successful endodontic outcomes. The matrix effect of the apical control zone enhances the gravimetric density of the required hermetic apical seal as well as enabling more material to flow into the region to occlude fins, cul-de-sacs, deltas and lateral arborizations.

associated with Resilon, including low push-out bond strength⁴⁶ and low cohesive strength plus stiffness.⁴⁷ In addition, Resilon could not achieve a complete hermetic apical seal.⁴⁸ These results indicate that a more appropriate material for root canal obturation still needs to be developed. There is still no obturation method or material that produces a leakproof seal. A material that is bio-inductive and promotes regeneration, a “smart” nano-material that can adapt to the ever-changing microenvironment of the canal system is essential, but to date, remains elusive.

All polymers demonstrate melt temperature and flow rate. Both gutta-percha and Resilon demonstrate a viscoelastic gradient that manifests as a dynamic rheological birefringence in the molded state. Dependent upon the molecular weight of the source material (without the opacifiers, waxes and modifiers), gravimetric measurements of the time-temperature-transformation diagram of any molding compound can be constructed. In the thermoplastic world of today, this has engendered an increase in the weight of the mass of obturating material and an improvement in the bacterial seal. This applies to carrier-based obturation techniques, Continuous Wave Compaction Technique and Obtura III obturation without cone placement.

Instrumentation

The steps required for debridement and disinfection of the root canal space are sequential and interdependent. Aberration of any node in the process impacts upon the others leading to iatrogenic damage and potentially, treatment out-

come failure. The most common distortion of native anatomy is ledging; canal curvature exceeding 20 degrees was shown to produce ledging of mandibular molars in a cohort of undergraduate students 56 percent of the time.⁴⁹ Dentin chips pushed apically by instrumentation incorporated with fragments of pulp tissue will compact into the apical third and the foramenal area causing blockage, altering the working length due to the loss of patency (Figs. 14a, 14b).

Apical patency is a technique in which the minor apical diameter of the canal is maintained free of debris by recapitulation with a small file through the apical foramen.⁵⁰ The most predictable method is to regularly use a designated patency file throughout the cleaning and shaping procedure in conjunction with copious irrigation. A #.08 K-file passively moved through the apical terminus without widening it is most effective; it will refresh the NaOCl at the terminus as the action of the file going to the point of patency produces a fluid dynamic. Regrettably, loss of working length remains a common adverse event during endodontic therapy, especially among less experienced clinicians. Its major cause is the formation of an apical dentin plug. Therefore, establishing apical patency is recommended even during treatment of canals with vital pulps.⁵¹

Historically, numerous techniques have been advocated for canal preparation (balanced force, anti-curvature, double-flare, modified double-flare); however, step-back⁵² and crown-down⁵⁵ are the most universally accepted. Experience has shown a crown-down preparation will cause fewer procedural errors (apical transportation, elbow formation, ledging, strip perforation, instrument fracture). The preliminary removal of coronal dentin (pre-enlargement — treating the apex last) minimizes blockage and enables an increasing volume of irrigant penetration thereby sustaining working length throughout the procedure.⁵⁴

The balanced force shaping philosophy is integral to the crown-down approach. Its premise is that instruments are guided by the canal structure when rotational/anti-rotational motion (watch-winding) is used. Changing the direction of rotation controls the probability that instruments will become overstressed and thus ensures that the cutting of structure occurs most efficiently.⁵⁵ Endodontists have long appreciated what the science reported, that the balanced-force hand instrumenta-

→ ET page 8C

AD

Dental Collab BETA

FINALLY A SOLUTION FOR SHARING CASES WITH LABS & SUPPLIERS.

WWW.DENTALCOLLAB.COM

FIRST MONTH FREE
CODE: ITDC09

← **ET** page 7C

tion technique produced a cleaner apical portion of the canal than other techniques^{56,57} (Fig.15). As will be discussed shortly, this author remains committed to hand filing in order to refine apical third shaping and creating an enhanced apical control zone taper.

Two distinct phases are required for the preparation of canals with nickel titanium (NiTi) rotary files. It is essential, that no matter the protocol used, a reservoir of NaOCl must be maintained and replenished repeatedly in the strategically extended access preparation. The coronal portion of the canal space is explored with small-sized K-files to establish a glide path for the rotaries to follow. The taper of NiTi files, regardless of manufacturer, induces a crown-down effect in the straight portion of the canal. After the coronal and middle third segments are opened and repeatedly irrigated with NaOCl, a sequence of small K-files can progress apically, ultimately defining patency, confirming the topography of the accessible canal space and its degree of curvature.

A second “wave” with the NiTi rotaries is then used to effect deep shape approximating the working length and depending upon the configuration of the apical third, to enlarge the terminus to the gauged apical size and initiate the taper of the apical control zone⁵⁸. This is a basic concept. It is inherent in all templated protocols that each tooth is different, and modifications to the process are always necessary as a function of the tooth morphology.

The apical control zone is defined as a matrix-like region created at the terminus of the apical third of the root canal space. The zone demonstrates an exaggerated taper from the spatial position determined by an electronic foramenal locator to be the minor apical diameter.

Whether this is linear or a point determination is a function of histopathology. The enhanced taper at the terminus creates a resistance form against the condensation pressures of obturation and acts to prevent excessive extrusion of filling material during thermo-labile vertical compaction.

All NiTi systems are modeled upon a single or multiple taper ratio per millimeter of file length. Fig. 16a demonstrates the metrics of the F1, F2, F3 finishing files of the ProTaper Universal system (author's preference). These files demonstrate a common taper in the last 4 mm of the file, which in the vast majority of situations corresponds to the length of the apical third of the root-canal space. As shown, the .07

taper of the F1 (.20 tip), the .08 taper of the F2 (.25 tip) and the .09 taper of the F3 (.30 tip) produce the corresponding diametral dimension indicated each millimeter back from the apical terminus if the crown down protocol built into this multiple taper file system is adhered to. If the shape of the internal micro-morphology of the root complex were epidemiologically similar, then “imprinting” of the canal preparation would be logical. Unfortunately, such is not the case.⁵⁹

Fig. 16b shows how the use of hand files in the apical third can alter the preliminary shape created by the NiTi files. Hand files have a .02 taper (along the shaft of the file, the diameter increases by .02 mm per mm of length — .20 file with 16 mm of flutes would be measure .52 mm at the coronal end of the flutes). In the example shown, a #20 file is positioned at the minor apical diameter. Careful positioning of a series of file within the last mm can produce a .2 mm or 20 percent taper with no undue disruption of the native anatomy. Schilder's precept for shaping was to keep the apical foramen as small as practically possible. Whatever file approximates the minor apical diameter, in conjunction with hand filing, the apical control zone created will enhance the apical seal as the rheologic vectors of compaction and condensation have a greater lateral volume of displacement at the terminus.

A risk-assessment algorithm

If the biologic parameters that mandate endodontic success are adhered to, in almost all cases, treatment outcomes will be successful. The endodontic implant algorithm processes the array of contributing factors leading to endodontic failure, in order to determine whether to implement a re-engineered endodontic approach or to extract and replace the natural tooth with an osseointegrated implant. It finds the greatest common divisor among the degree of coronal breakdown of the involved or adjacent teeth, the quality and quantity of the bone support and tissue condition, the engineering demands to be born by the tooth or teeth in question and assesses the occlusal scheme and the patient's esthetic and functional expectations of treatment.

The reasons for tooth extraction may include, but are not limited to, crown to root ratio, remaining root length, periodontal attachment levels, furcation status, periodontal health of teeth adjacent to the proposed fixture site and non-restorable carious destruction. In addition, the clinician must consider questionable teeth in need

Upcoming online C.E. program: ‘An Endodontic Implant Algorithm’

An assessment of whether to rehabilitate a tooth requiring endodontic treatment or to replace it with a dental implant can often involve a challenging and complex decision-making process.

In 2010, DTSC will introduce a focused curriculum, pertaining to both treatment modalities, which will identify key issues that need careful consideration in planning the most appropriate course of care in a given clinical situation. A need to appreciate advances across both disciplines is emphasized, allowing the development of effective interdisciplinary evidence-based treatment strategies to maximize treatment outcome.

This curriculum offers dental professionals a carefully planned sequence of learning experiences, including, first and foremost, online attendance of lectures, along with hands-on and group learning opportunities. By hosting the main body online — the theory content — we are ensuring that the curriculum is as accessible as possible to those willing to learn, independent of their geographical location, with an equal chance of success.

This curriculum is designed to help those practitioners who are interested in better preparing themselves to determine which treatment option is most appropriate for each individual patient. Through this program, we offer participants the opportunity to learn from a world-class, experienced faculty, enhancing their strengths and addressing areas for improvement. The curriculum has been developed under the guidance of Dr. Kenneth Serota, Dr. Fred Barnett and Dr. Jose Hoyo, and will consist of a 100-hour blended learning program (ADA CERP accredited) over a period of two years.

Please contact Julia Wehkamp at j.wehkamp@dtstudyclub.com for further information.


of endodontic treatment, teeth requiring root amputations, hemi-sections or advanced periodontal procedures with a questionable prognosis and pulpless teeth fractured at the gingival margin with roots shorter than 13 mm. These teeth will require endodontic treatment, crown lengthening, post/cores and crowns; however, their longevity is very much in doubt with these parameters.⁶⁰

Practitioners are ethically obligated to inform patients of all reasonable treatment options. It is the patient's attitude, values and expectations that are integral to the risk assessment algorithm. Poor motivation to retain a tooth mandates extraction, not clinical intervention whereas high motivation advocates non-surgical intervention or surgery. The process of planning, presentation and acceptance of dental treatment plans is always dominated by the duality of emotion and pragmatism associated with cost. Where it becomes specious is the side-by-side dollar comparison of restoring a natural tooth or placement of a fixed bridge et al in contrast to orthobiologic replacement of a debilitated tooth.

Far too often the comparison of purported treatment outcome percentages are based upon corporate affiliation and/or fiduciary bias, or are simply too narrow a parameter to suggest comparable alternatives. With the treatment options available to an experienced endodontist, only a very few structurally sound teeth need be removed.

Benjamin Disraeli said: “Expediency is a law of nature. The camel is a wonderful animal, but the desert made the camel.” The endodontic implant algorithm begs the question, “Does science drive the market, or does the market drive science?” “All truths are easy to understand once they are discovered; the point is to discover them,” Galileo said. Time and forbearance will bear witness to the discovery of the salient and relevant truths that guide the endodontic implant algorithm. **ET**

ET About the author



Kenneth S. Serota, DDS, MMSc, graduated from the University of Toronto, Faculty of Dentistry in 1973 and was awarded the George W. Switzer Memorial Key for excellence in prosthodontics. He received his certificate in endodontics and master of medical sciences degree from the Harvard-Forsyth Dental Center in Boston.

A recipient of the American Association of Endodontics Memorial Research Award for his work in nuclear medicine screening procedures related to dental pathology, his passion is education and most recently e-learning and rich media. Serota provided an interactive endodontic program for the Ontario Dental Association from 1985 to 1997 and was awarded the ODA Award of Merit for his efforts in the provision of continuing education.

The author of more than 60 publications, Serota is on the editorial board of Endodontic Practice, Endo Tribune and Implant Tribune. The founder of ROOTS, an online educational forum for dentists from around the world who wish to learn cutting-edge endodontic therapy, he recently launched IMPLANTS (www.rzimplants.com) and www.tdsonline.org in order to provide a more clear understanding of the endodontic/implant algorithm in foundational dentistry.

AD



The perceptions of a David in a land of Goliaths

By Barry Lee Musikant, DMD

When you are competing against giants in a field that has become tremendously lucrative for these giants, one could easily be convinced we are out of our depth and should beat a hasty retreat lest we encounter their true wrath. It is undeniable that we are exposed to the all-encompassing marketing power of these giants.

We recognize their ability to dominate the endodontic education in the schools (both undergraduate and graduate), the commercial exhibits and lectures at all the major meetings, the majority of the articles published in the trade journals all nicely capped off with an army of salesmen who make sophisticated pitches to the dentists to buy one or another of the expensive rotary NiTi systems.

We, on the other hand, have one over-riding advantage: We work with the simple but powerful idea that we have a safer, far more cost-effective and efficient way to perform endodontics that is so strongly based in common-sense logic that for those who expose themselves to these alternative concepts, the acceptance rate will be extremely high. We don't have to see a lot of people to convince a small portion they should adopt our approach because the logic and application of our approach is readily accepted by a large percentage of the far fewer dentists we do come in contact with.

We have no other choice than to think this way, and it has done very well for us these past several years. We created an endodontic system that meets *our* needs because the products that have been heavily promoted in the marketplace did not. It is an absolute essential that the instruments not break. For us, there is no compromise on this point. I don't want to know they won't break if I only use them once, use them lightly with several iterations of recapitulation, not use them in highly curved, dilacerated, bifurcating or merging canals.

I want to know these instruments used in the recommended fashion will not break, period. This was not a requirement before the use of rotary NiTi because while breakage occasionally occurred, it was a rarity. Once I used rotary NiTi, I appreciated the greater tapered shaping, but this advantage did not outweigh the trepidation I had when using them. Moving forward in time as only a narrative allows, we came up with a system that incorporated the shaping associated with NiTi, but without breakage as a worrying side effect. I clearly remember giving a lecture at a fairly large dental meeting introducing our concepts. After the lecture, one of the dentists I was friendly with asked a younger dentist if he was interested in the system. The dentist

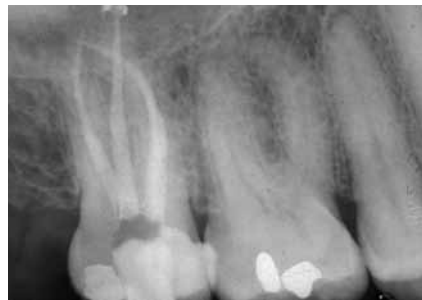

Fig. 1

responded he wasn't interested in what I was talking about because it could not possibly be true. If it was, everyone would be using it.

The dentist's response was an insight into human nature. What I gathered from this remark is:

1. If it sounds like it is too good to be true, then it is most likely not true. Having come to this conclusion, there is little follow-up to see if by chance it actually is true. It is more comforting to simply dismiss it. This reaction is even more true when a dentist's focus for new endodontic systems is already filled by one of the expensive systems offered by the major manufacturers.

Against the exposure of my single endodontic lecture, the dentists attending the lecture have seen and heard about rotary NiTi systems at other lectures, articles, testimonials all from well-known opinion leaders as well as the ever-present salesmen who are convincing the clinicians to go with their latest system. It is hard not to pay credence to a flow of information that appears to be coming from diverse sources, but in reality is being centrally choreographed.

2. Once an expensive system is paid for, it is only natural the dentists would want to defend their decisions, that they made the right choices to make their efforts better and more productive. For many dentists, increased usage makes the dentists more familiar with the rotary systems' limitations and they begin to take the precautions that are necessary for safe usage. It is an unusual phenomenon of rotary NiTi that the more one learns how to use these instruments, the more selectively they are employed. Case selection becomes an important part of treatment.

One should be very clear, however, that case selection has become increasingly necessary simply because there are many situations that can lead to instrument separation. I cannot think of another innovation in dentistry where the more one learns how to use the instruments, the less they are used. Now depending upon your point of view, one could look at the selective use of these instruments as a study in sophistication, that only the best and most trained dentists will use them safely and this is somehow a plus. Learning how to use a system that is

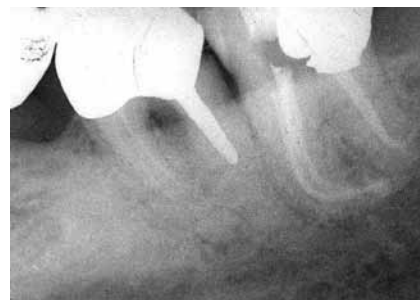

Fig. 2

defined by a narrow window of success, may appear to be a study in professional growth. I look at it as just the opposite: the need to expend a great deal of energy in mastering a system that will produce results that are (at best) no better than those attained by simpler, far less expensive and far safer approaches.

I teach many dentists and when a dentist comes to me to learn, I always ask them what they are presently using. The other night I was teaching a dentist from Virginia who came to our NYC endodontic office. She has been using the GT rotary NiTi system. I asked her if she fears separation and she said she'd only broke one instrument in the past few years.

Despite that single incidence of breakage, she now takes extreme precautions not to separate an instrument. I then asked her how she handles curved canals and she said if they are mildly curved, she will use the GTs in a double sequence (otherwise known as recapitulation) after shaping the canals up to a 15 or 20 via K-files. If the canals are more than mildly curved, she sends these patients to the specialist.

As an endodontist, I have no problem in having patients sent to me, but from an academic point of view, I don't like systems whose vulnerabilities are so obvious they force a dentist to refer. It should not be the vulnerability of the system that determines whether a referral is made or not. Not being able to negotiate calcified canals, or failing at finding them, is a good reason to refer. Fear of instrument breakage should not be a reason.

Ironically, these referrals are made because of the fear of breakage of rotary NiTi. However, the endodontist has the same concerns, and he will use alternative means to shape the curved part of the canal at least up to the point where the concern for instrument breakage has passed. Certainly, if the specialist attains safer results using a more cautious approach, the dentist can also adopt this approach. We teach a far safer approach and those using it find the shaping of canals not only to be safer, but so highly efficient the need to ever transition to rotary NiTi is not necessary.


I have read a number of articles about the less distorted shaping rota-

ry NiTi produces, but these results are always in comparison to the use of K-files used with a twist-and-pull stroke. When K-files are used with a balanced force technique, the results of non-distorted shaping favor the K-files.

The results will favor stainless-steel instruments even more when the instrument is a relieved reamer rather than the traditional K-file and it is negotiated to the apex using a tight watch-winding stroke or used in the 30-degree reciprocating handpiece. With the understanding that both the tight manual watch-winding stroke and the 30-degree reciprocating handpiece virtually eliminate all the torsional stress and cyclic fatigue that causes rotary NiTi (and for that matter, stainless steel) to break, we are addressing the basic concerns of dentists.

Solving these basic problems gives the dentist the ability to become more productive by turning out superior work on a greater variety of cases than he would have attempted in the past. Extending the dentists' skills by the invention of systems that produce compatibility between the metal and what is asked of it, is what progress is all about, and despite being Davids, it is worth battling the Goliaths. I suppose you have to be a dentist to appreciate that last remark.

For those who are interested in learning about the relieved reamers used in the reciprocating handpiece and learning how to three-dimensionally fill canals without the need for expensive thermoplastic approaches, call me at (212) 582-8161 for a free two- to three-hour one-on-one workshop in our office. This hands-on experience will definitely open your eyes to a far safer, far less expensive and more efficient way to perform excellent endodontics. Additional courses can be found at www.essentialseminars.org.

Your wallet and your stomach lining will appreciate the change. 

ET About the author

Barry Lee Musikant, DMD, is co-director of dental research and co-founder of Essential Dental Systems (EDS). The company's roots stem from the desire for product improvements to the items of focus in lectures and daily practice. His research and business partner is Allan S. Deutsch, DMD. Musikant and Deutsch have a combined 60-plus years of practice experience. Contact them at info@edsdental.com.

