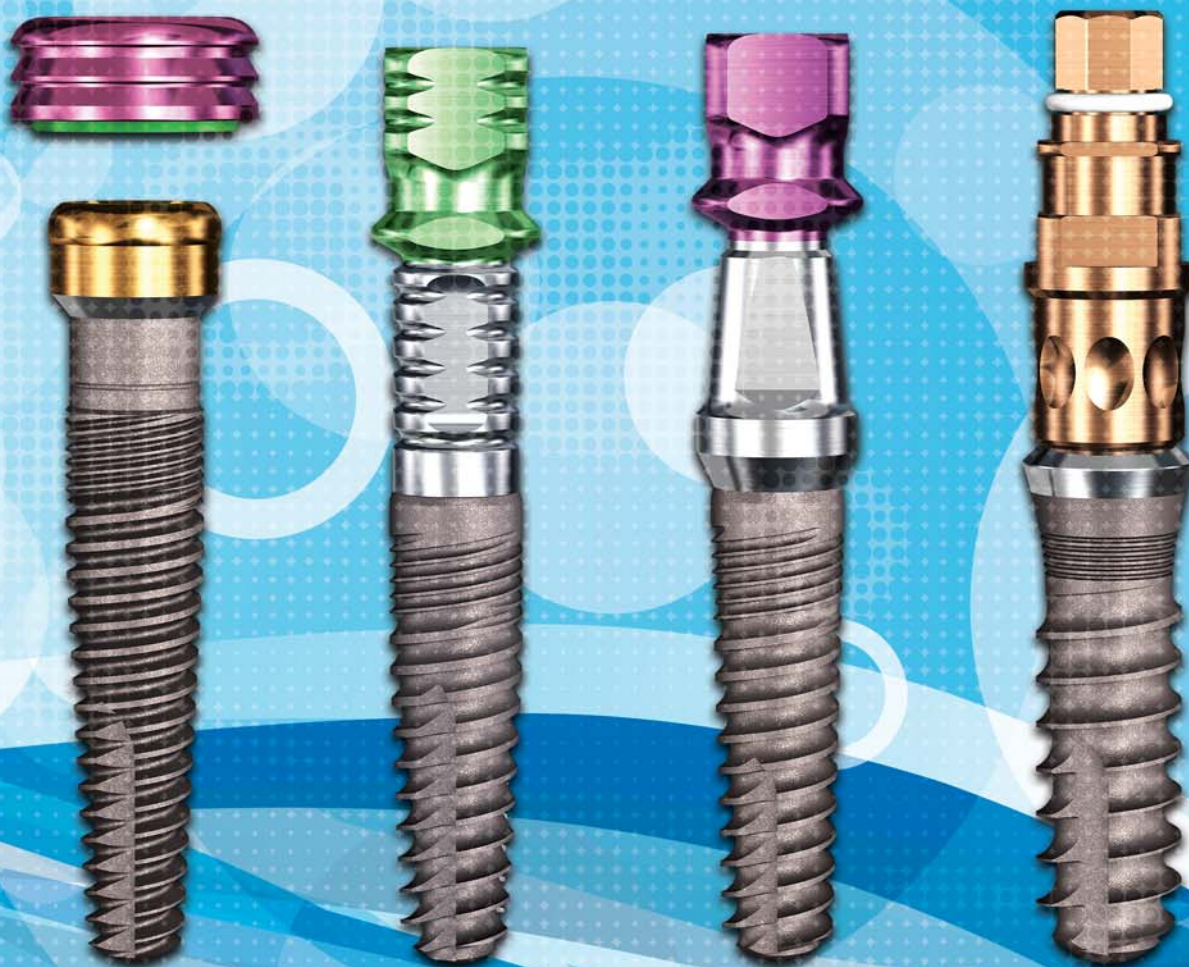

implants

international magazine of oral implantology

3²⁰¹²



| **research**

Rehabilitation of a complex case with zirconium dental implants

| **case report**

Immediate implantation in the anterior maxilla

| **industry report**

CAD/CAM-based restoration of an edentulous maxilla

0277113

IDENTICAL
IMPLANT SHAPE



TUBE-IN-TUBE™
CONNECTION



CONICAL
CONNECTION

CAMLOG IS
TWICE AS GOOD

Conical – and of CAMLOG quality: The CONELOG® Implant System. First-class Tube-in-Tube™ or conical implant-abutment connection – all from one source.

For more information: www.camlog.com

a perfect fit™

camlog

To know **when** to do! To know **when** not to do!

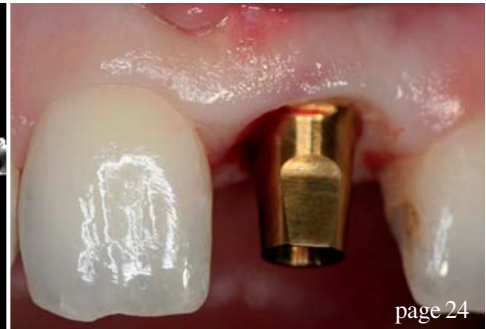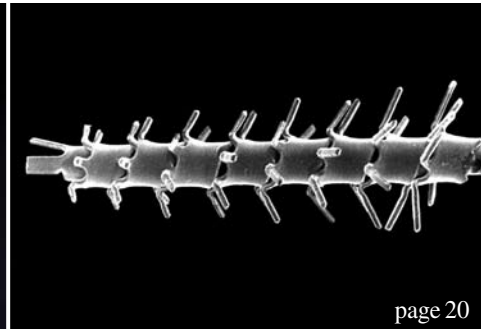
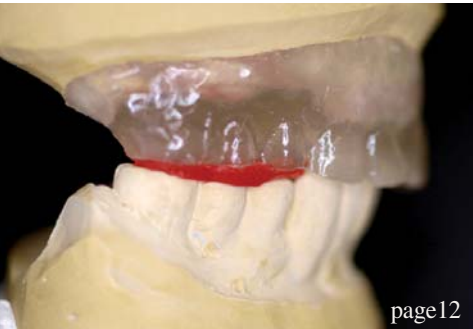


Dr Rolf Vollmer

Dental implantology has experienced a substantial change in the last 25 years. The treatment spectrum has been significantly expanded; simultaneously, our patients' expectations and demands in implant treatment have developed disproportionately. In addition, implant dentistry now is also an integral part of everyday dental practice. In spite of the growing importance of oral implantology, most dentists receive their education in implant dentistry after graduation with only little emphasis on the complexity and risks of implant treatment. Providing our patients with quality implant treatment motivates us to give the best our profession has to offer. This does however not imply that our treatments must be perfect to 100 per cent, since perfection such as this does not exist in the practice of implant dentistry. Instead, we must strive to achieve the best we can do for our patients. We need to work either as individuals or as members of a team to assure that implant treatment is safe, effective, and aesthetically acceptable. We can all play a part in providing quality dental implant treatment by being there for the patient with skills that are attained by proper education, experience, and counsel from those who have gained the necessary skills, knowledge, and judgment.

For 42 years, DGZI has organized its annual conferences in order to inform about scientific insights and "truths" established by research and evidence-based clinical observations. Not only for novice clinicians is attaining the proper education a continuing process, but it is also an ongoing enterprise for the highly experienced clinician. New developments occur with each passing day. Therefore, providing the best we can do for our patients and profession becomes an impossible task if we keep our blinders on and persist in our practice as we did yesterday. As early as the beginning of the 1990s did DGZI begin to administer an examination for particularly qualified colleagues, allowing them to both revise and prove their knowledge and skills to the advantage and the safety of their patients. The Curriculum Implantology was established as a systematic education for the newcomers as well as for the experienced implantologist. Some thousand colleagues have since passed the education successfully. A subsequent master studies postgraduate program can be attended additionally for more theoretical skills. In addition, a specialist and German board (GBOI) international examination was established by DGZI for clinicians who want to have their theoretical and practical experience tested by an international examination board. One of this year's DGZI highlights will be our International Annual Meeting in Hamburg from 5 to 6 October titled "Quality Oriented Implantology—Ways to Long-Term Success". Complex situations in dental implantology and the digitalization of surgery and prosthetics are discussed, along with a periimplantitis special session and discussion. Take your chance and register for the meeting as well as the German board and specialist examination. You can request more information from our central office in Düsseldorf (Tel. +49 211 1697077). I invite you all to join us and enjoy Hamburg where it is most beautiful, directly located on the Elbe River—at the heart of the harbour! Indulge in new culinary creations and an unforgettable atmosphere, combining state-of-the-art scientific meeting with maximum relaxation. Sincerely Yours,

1st Vice president of DGZI



| editorial

03 To know **when** to do! To know **when** not to do!
| Dr Rolf Vollmer

| research

06 **Rehabilitation of** a complex case with **zirconium dental implants**
| Dr Andrea Enrico Borgonovo *et al.*

12 **Impression and registration** for full-arch **implant dentures**
| Dr Gregory-George Zafiropoulos

20 **Time-saving** debridement of implants with **rotating titanium brushes**
| Dr Dirk U. Duddeck *et al.*

| case report

24 **Immediate implantation** in the **anterior maxilla**
| Dr Nikolaos Papagiannoulis *et al.*

| industry report

28 **Fixed full arch metal-free prosthesis on four SHORT® implants**
| Dr Mauro Marincola *et al.*

32 **CAD/CAM-based restoration** of an **edentulous maxilla**
| Arnd Lohmann

| business news

36 **Conical internal connections** will fuel **growth** in dental **implant market**
| Dr Kamran Zamanian *et al.*

| news

38 **Manufacturer News**

48 **News**

| education

40 **Master of Oral Medicine in Implantology**
| DGZ

41 **Celebrating the Triumph of Osseointegration**
| Frederic Love

| meetings

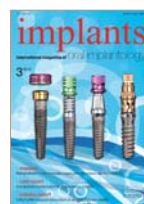35 **International events 2012**

42 **National Osteology Symposium** in Bonn
| Verena Vermeulen

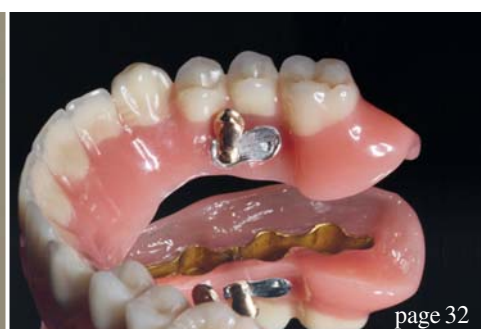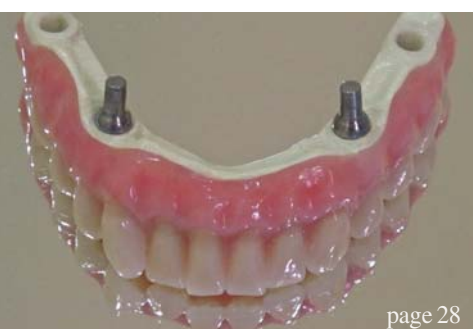44 **“Quality-oriented implantology”**
| DGZ

| about the publisher

50 | imprint

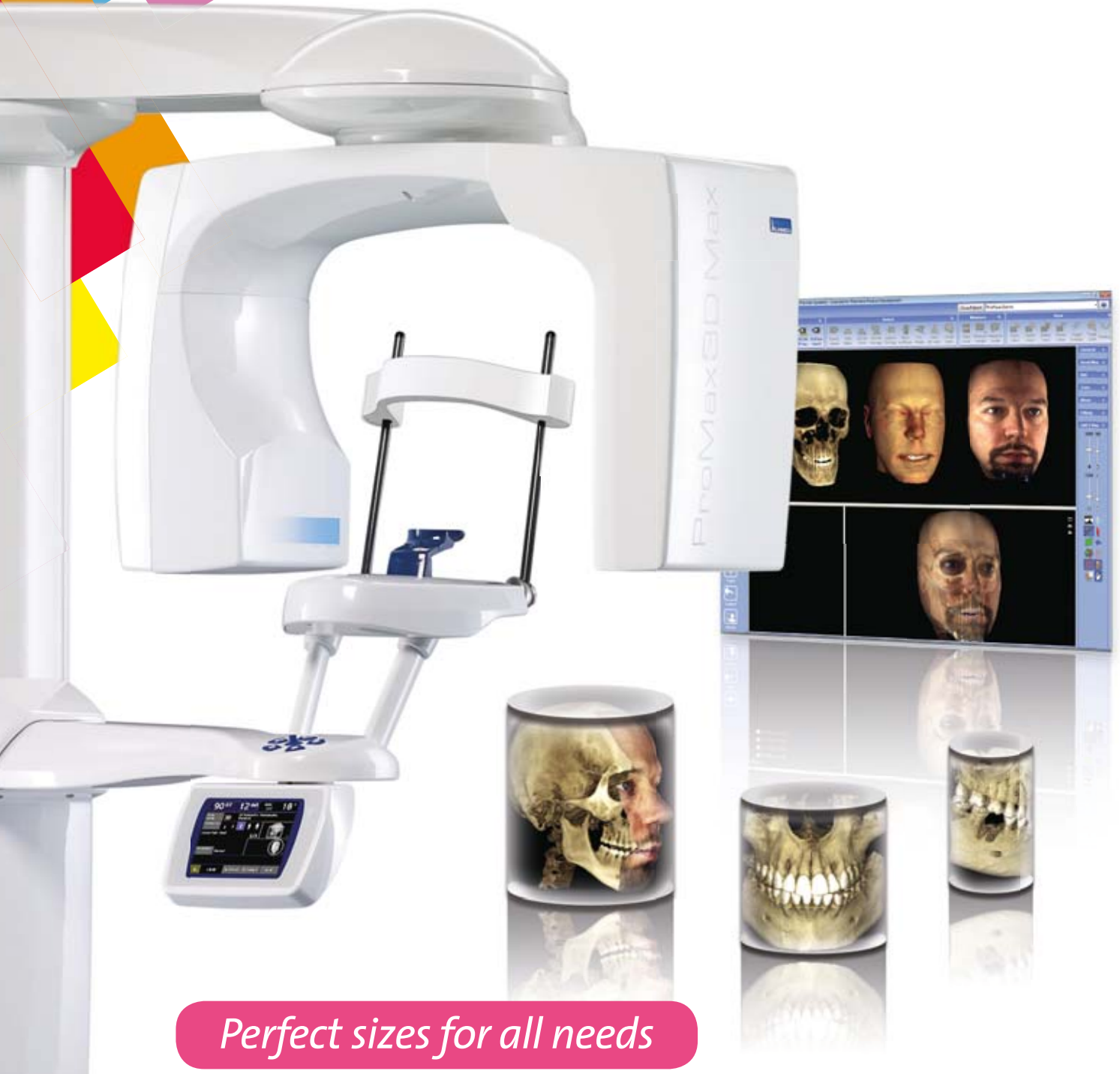

Cover image* courtesy of Implant Direct, www.implantdirect.com
Original Background: ©antishock
Artwork by Sarah Fuhrmann, OEMUS MEDIA AG.



Planmeca ProMax[®] 3D

Unique product family



Perfect sizes for all needs

3D X-ray • 3D photo • panoramic • cephalometric

Romexis[®] software completes 3D perfection



Digital perfection™

More information

www.planmeca.com

Planmeca Oy
Asentajankatu 6, 00880 Helsinki, Finland
tel. +358 20 7795 500, fax +358 20 7795 555
sales@planmeca.com

PLANMECA

Rehabilitation of a complex case with zirconium dental implants

Authors Dr Andrea Enrico Borgonovo, Dr Marcello Dolci, Dr Rachele Censi, Dr Oscar Arnaboldi, Dr Virna Vavassori & Prof Carlo Maiorana, Italy

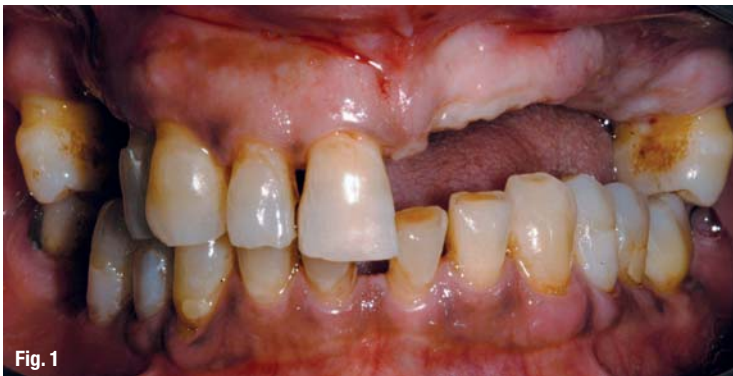

Fig. 1

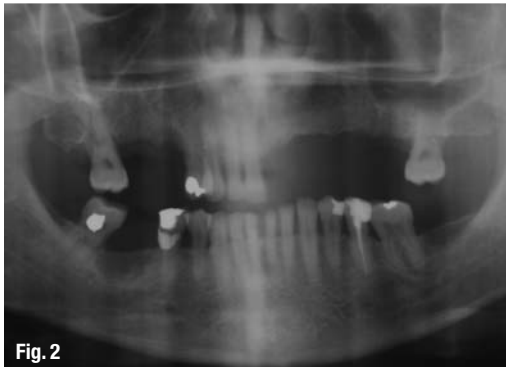


Fig. 2

Fig. 1 Pre-op clinical view.
Fig. 2 Pre-op radiograph.
Fig. 3 Preparation of implant site.

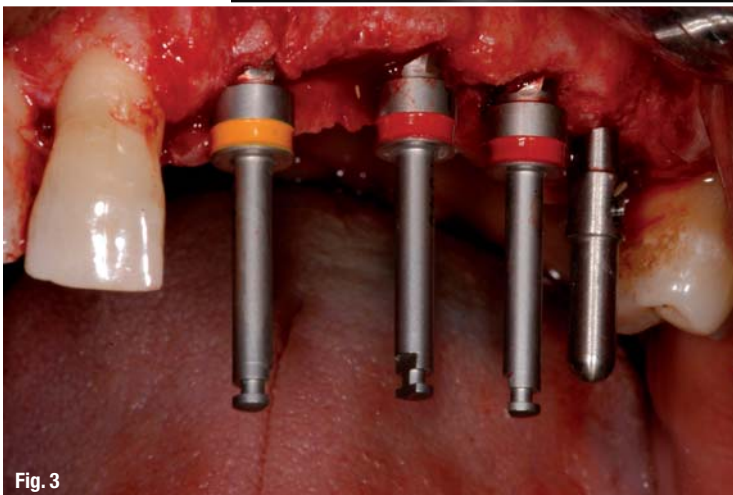


Fig. 3

Introduction

For several decades, dental implants have largely been used for the rehabilitation of completely and partially edentulous ridges with success. For this reason, implant dentistry has been the object of numerous investigations to further improve the effectiveness of this kind of device.^{1,2} Titanium is the material most often utilised for dental implants because of its favourable properties, such as its biocompatibility.^{3,4} However, aesthetic concerns may arise when restoring anterior teeth owing to the grey colour of this metal.

For this reason, new techniques and materials were developed to achieve better aesthetics, such as ceramic (zirconium) abutments^{5, 6} and metal-free restoration.^{7, 8} These prosthetic devices have already achieved assessable results. There are, however, some situations, resulting from a thin gingival biotype or incorrect tri-dimensional implant positioning, in which zirconium abutments and crowns are not able to obtain optimal aesthetics.^{9, 10}

Many authors¹¹ have attempted to solve these problems by coating titanium dental implants with white material such as ZrO_2 and Al_2O_3 . While the popularity of coating has increased, its use has remained controversial. Concerns have been raised owing to problems such as the dissolution and cracking of coatings, as well as the separation of coatings from metallic substrates, a phenomenon referred to as "delamination".

For the same purpose, Al_2O_3 implants have been tested in various clinical studies since the 1970s. They were commercialised in France, Germany, Japan and the USA. Among them, Tübingen implants are probably the most well known ceramic implants.¹² These im-

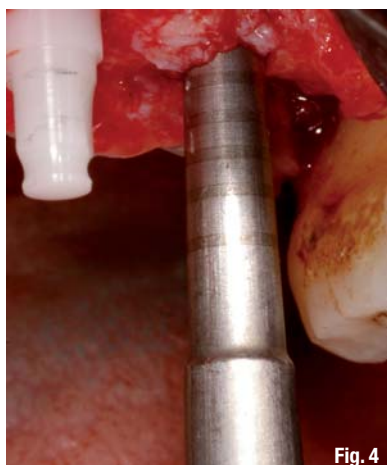

Fig. 4

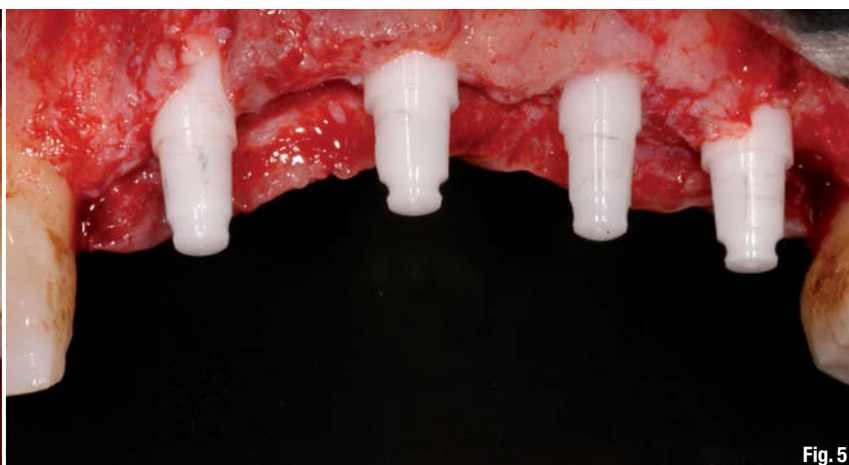


Fig. 5

plants were soon abandoned because of frequent implant fractures, mobilisation, loss of osseointegration and peri-implant bone loss. Most of these problems probably occurred owing to the inadequate mechanical characteristics of Al_2O_3 .^{13,14}

More recently, ZrO_2 has been introduced to dentistry for its good mechanical properties and high biocompatibility, combined with excellent aesthetics. While ZrO_2 has been largely used and documented in prosthetic dentistry, only few studies have reported clinical experiences with zirconium implants.^{15,16}

The aim of this article is to present a five-year follow-up study of a complex implant-prosthetic rehabilitation with ZrO_2 dental implants.

Case report

A 55-year-old male patient presented with partial edentulism in the left maxilla in regions 21 to 26 at the Department of Oral Surgery at the Dental Clinic at the University of Milan. The patient was in general good health and a non-smoker. However, lately he had had financial difficulties that had led to him taking inadequate care of his oral health and consequently losing teeth. After professional hygiene and oral hygiene instructions, the patient was re-evaluated for an implant-prosthetic rehabilitation. His edentulism was complex owing to the lack of numerous teeth and because the alveolar process had undergone moderate resorption. Yet, it was sufficient to insert four dental implants. There was no need for an augmentation procedure and the predictable level within the gingival marginal profile was not considered a problem because of the patient's low smile line (Figs. 1 & 2).

After a diagnostic wax-up, the surgical guide was created. A mucoperiosteal flap was raised with a vertical releasing incision distal to tooth 1.2. Four one-piece yttria-stabilised ZrO_2 (YSZ) implants (whiteSKY, bredent) were inserted. Two 4 x 12 mm implants were

positioned in regions 2.1 and 2.3, and two 4.5 x 12 mm implants in regions 2.5 and 2.6 (Fig. 3). After the implant sites had been prepared, implant insertion was performed using a surgical contra-angle handpiece and then a dynamometric key, at a maximum torque of 40 N. The fixtures were screwed in until the sanded surface reached the bone crest level, leaving the polished part untreated at transgingival level. A heterologous bone graft (Bio-Oss, Geistlich Pharma), together with a double layer resorbable membrane (Bio-Gide, Geistlich Pharma), was positioned on the implant placed in region 2.1 because of the thin cortical wall and to reduce bone resorption. A sinus lift was performed using Summers' osteotome technique to insert the implant with an adequate length (12 mm) in region 2.6 (Figs. 4–7). The flaps were sutured with non-absorbable 4.0 monofilament (Premilene, B. Braun). The removable partial denture was adapted in order to avoid any contacts with the implants.

The patient was prescribed a soft diet, antibiotic therapy with 1 g amoxicillin and clavulanic acid (Laboratori Eurogenerici) every eight hours for seven days and a 0.2% chlorhexidine mouth rinse (Corsodyl, GlaxoSmithKline) twice a day for 15 days. The patient attended a follow-up visit ten days later. The sutures were then removed and the implant stability was checked. The supra-gingival portion of the one-piece zirconium implant was minimally prepared with ETERNA burs (bredent) to achieve parallelism of the implant axes. Then the partial denture was replaced with a temporary acrylic resin bridge to enhance soft-tissue healing and guide the gingival profile (Fig. 8). In the temporary phase, particular attention was given to occlusion to ensure centric contact that was as slight as possible and to avoid contacts in eccentric movements.

After four months, the temporary bridge was removed. Implant stability, probing depth and gingival health were examined. Furthermore, the occlusal surface of the temporary restoration was modified and

Fig. 4 Sinus lift using Summers' osteotome technique in region 2.6.

Fig. 5 The four implants are positioned.

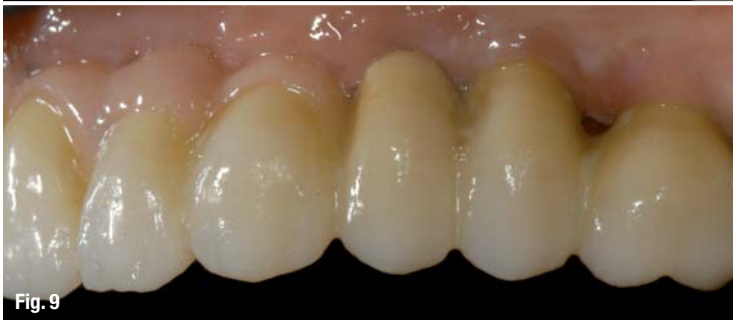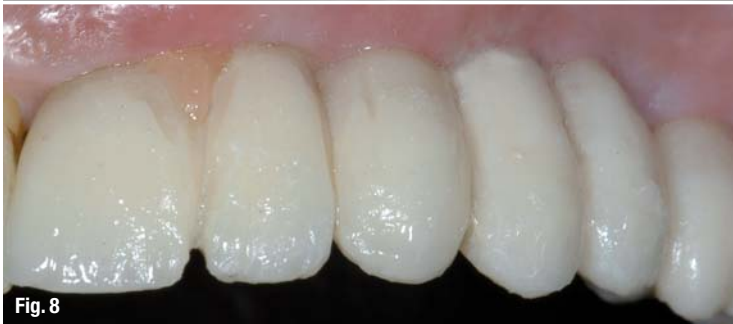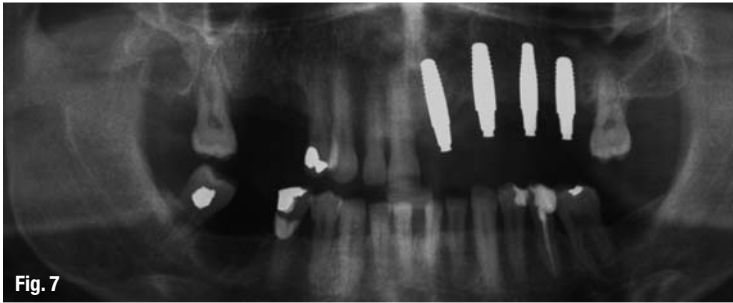
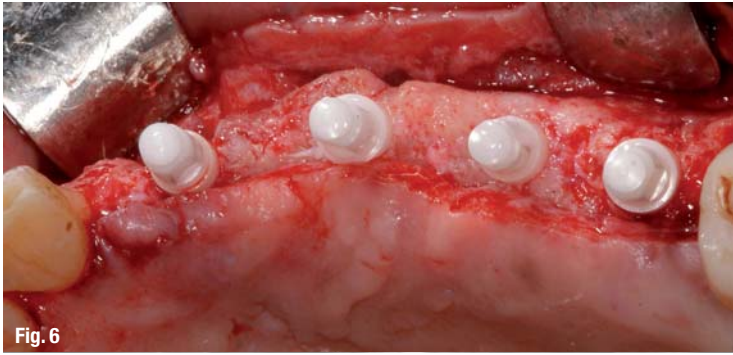


Fig. 6_ Occlusal view of the implants.
Fig. 7_ Post-op radiograph.
Fig. 8_ The acrylic resin temporary bridge is placed.
Fig. 9_ Clinical view of the all-ceramic ZrO₂ bridge five years after surgery.

the implants were loaded. Six months after surgery, the YSZ implants were definitively restored with a ZrO₂ bridge. A light-pink ceramic layer was applied to the marginal areas of regions 2.1 to 2.3 to better support the upper lip and limit the width of the interdental space (Fig. 9).

Follow-up appointments were scheduled for six months after prosthesis delivery and thereafter once a year. Periodontal indices were measured and standardised periapical radiographs were obtained. The plaque index and bleeding on probing scores were 1, except at the last follow-up. No implants had probing depth values of less than 5 mm. Mobility was not present at any site. No pain (spontaneous or on percussion) or paraesthesia was reported. From baseline to

five years after surgery, radiographical evaluation observed the absence of peri-implant radiolucency and no implant exhibited marginal bone resorption at any follow-up (Figs. 10 & 11).

Discussion

Titanium dental implants have proved to be highly successful in replacing missing teeth. Several studies have demonstrated the successful osseointegration of this material and its use for restoration in patients with partial or total edentulism.¹⁷ In recent years, numerous studies have focused on the development of implant surfaces to ensure better and faster osseointegration and to re-establish masticatory function in a shorter period.^{18,19} Although excellent results have been obtained in the maxillary anterior region by several clinicians, aesthetics remains a challenge for implant dentistry.

Titanium implants are of a grey colour, which can shine through gingival tissue, particularly in thin biotypes or in patients with a high smile line. Moreover, it must be considered that soft tissue around dental implants may shrink or develop gingival recession, or that peri-implantitis may occur, thus compromising the overall treatment outcome, particularly if treatment entails an aesthetic region.

In recent years, several solutions to this problem have been proposed. Various authors have suggested placing implants 3 to 4 mm apical to the cemento-enamel junction or free gingival margin of adjacent teeth, considering that soft-tissue margins around implants tend to re-establish a biological width.²⁰ Implants positioned too far apically in an attempt to establish appropriate biological width can cause gingival recession.²¹ Gingival recession may also develop in thin gingival biotypes because these tissues are more sensitive to trauma and inflammation. For these reasons, surgical approaches such as connective tissue grafts have been suggested to augment tissue thickness and improve peri-implant aesthetics.^{22,23} However, these techniques are not always completely predictable from an aesthetic point of view. Moreover, morbidity of the donor site and patient discomfort must also be taken into account. Other authors²⁴ have recommended colouring the implant neck, thus changing the optical appearance of peri-implant mucosa. For the same reason, a great number of investigations have been conducted on tooth-coloured implants. Various ceramics have been tested as coating material, such as ZrO₂ and Al₂O₃.^{13,26} However, even if the studies conducted in the 1990s showed better results than earlier investigations, these implants did not have adequate mechanical properties for long-term loading²⁷ or required large diameters that were incompatible with use in the anterior region with lim-



PERFECT FIT BY DESIGN

In combining Soft Tissue and Bone Level implants with a comprehensive prosthetic portfolio, Straumann has devised one system for all indications. The **Straumann® Dental Implant System** – excellent product quality designed for convincing, naturally esthetic outcomes.



Featuring the
SLActive® surface!

More information on www.straumann.com

COMMITTED TO
SIMPLY DOING MORE
FOR DENTAL PROFESSIONALS