

implants

international magazine of oral implantology

1 2014



| **research**

Maximal aesthetics in the periodontally compromised anterior maxilla

| **case report**

Comprehensive prosthetic restoration

| **industry report**

Influence of implant design on osseointegration





More than an implant. A sense of trust.

The Straumann® Dental Implant System is a worldwide leading solution for general practitioners and specialists. Our commitment to research ensures high quality backed by independent science. Producing innovations that improve patient care has made us a trusted business partner in over 70 countries.

www.straumann.com

60 YEARS

 **straumann**
simply doing more

How many **scientists fabricate and falsify research?**



Dr Rolf Vollmer

— "The frequency with which scientists fabricate and falsify data, or commit other forms of scientific misconduct is a matter of controversy. Many surveys have asked scientists directly whether they have committed or know of a colleague who [has] committed research misconduct, but their results appeared difficult to compare and synthesize."

"To standardize outcomes, the number of respondents who recalled at least one incident of misconduct was calculated for each question, and the analysis was limited to behaviours that distort scientific knowledge: fabrication, falsification, 'cooking' of data, etc. Survey questions on plagiarism and other forms of professional misconduct were excluded." Twenty-one surveys were included in the systematic review and 18 in the meta-analysis.

While I am familiar with reports of scientific misconduct, I was shocked about the high occurrence in medicine and pharmacy reported in Fanelli's meta-analysis of these surveys—the first of its kind: "A pooled weighted average of 1.97 % (N = 7, 95 % CI: 0.86–4.45) of scientists admitted to have [having] fabricated, falsified or modified data or results at least once—a serious form of misconduct by any standard—and up to 33.7 % admitted [to] other questionable research practices. In surveys asking about the behaviour of colleagues, admission rates were 14.12 % (N = 12, 95 % CI: 9.91–19.72) for falsification, and up to 72 % for other questionable research practices. Meta-regression showed that self reports surveys, surveys using the words 'falsification' or 'fabrication', and mailed surveys yielded lower percentages of misconduct. When these factors were controlled for, misconduct was reported more frequently by medical/pharmacological researchers than others."

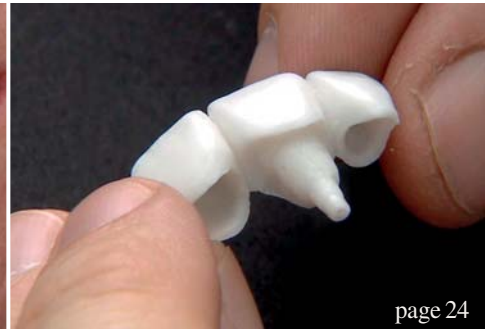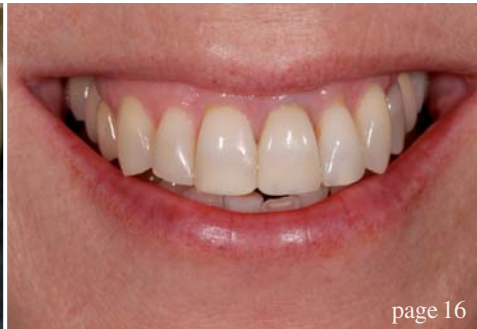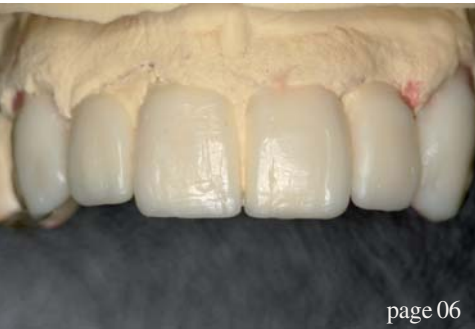The study cited above should make us consider all we read carefully. Especially with the development of new materials (for bone replacement, for example), we should always critically examine the current research and determine whether one can actually trust the evidence. For each of us, we need to ensure that our decisions are for the benefit of our patients and that they do not make them test subjects.

In this regard, the DGZI (German Association of Dental Implantology) offers you up-to-date training opportunities, such as the recently completely redesigned implantology curriculum and the presentations at our annual meetings (our next annual meeting is on 26 and 27 September in Düsseldorf), as well as critical, unbiased, objective information on companies and products.

We hope you will enjoy reading our current **implants** international magazine of oral implantology.

Yours faithfully,

Dr Rolf Vollmer



| editorial

- 03 **How many scientists fabricate and falsify research?**
| Dr Rolf Vollmer

| research

- 06 **Maximal aesthetics in the periodontally compromised anterior maxilla**
| Dr Nikolaos Papagiannoulis *et al.*
- 10 **Ridge augmentation for an atrophied posterior mandible using NanoBone block**
| Dr Omar Soliman *et al.*

| case report

- 16 **Comprehensive prosthetic restoration**
| Michael Peetz *et al.*

| industry report

- 20 **Jawbone cavitation and its implication in implant dentistry**
| Prof. Dr Mauro Marincola
- 24 **Immediate implantation and full-ceramic restoration in the maxillary anterior region**
| Dr Arndt Happe *et al.*
- 32 **Influence of implant design on osseointegration**
| Dr R. Fromental *et al.*

| interview

- 40 **The time has come**
| Interview by Jürgen Isbaner
- 42 **Short implants**
| An interview with Prof. Dr Christoph Hammerle, Switzerland

| meetings

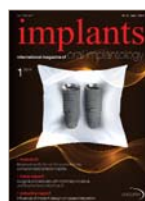- 44 **International implantology in Berlin**
- 46 **More than 500 attend ISOI annual meeting in Tokyo**
| Dr Rolf Vollmer

| news

- 36 **Manufacturer News**
- 49 **News**

| about the publisher

- 50 | imprint



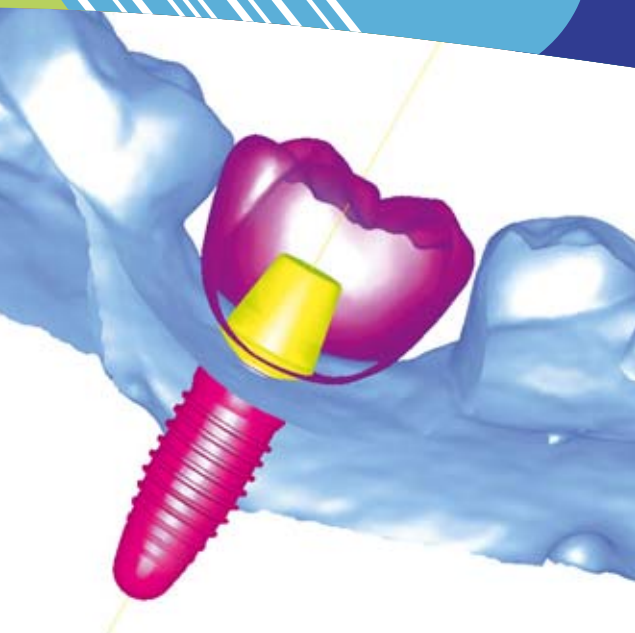
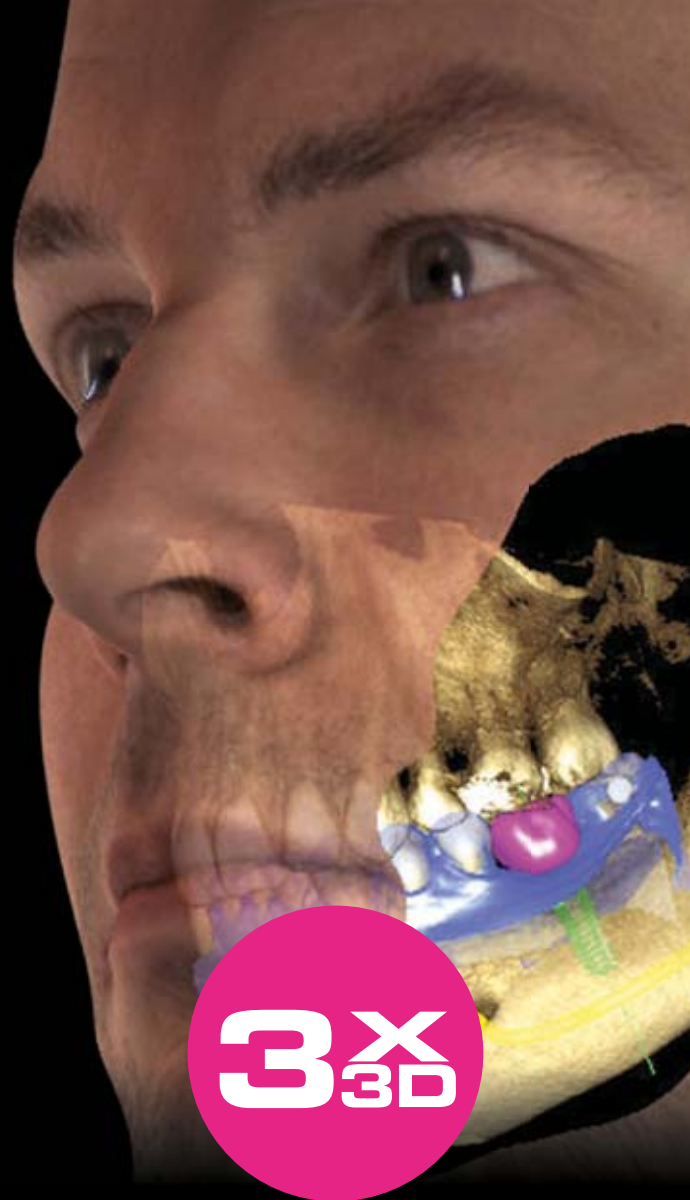
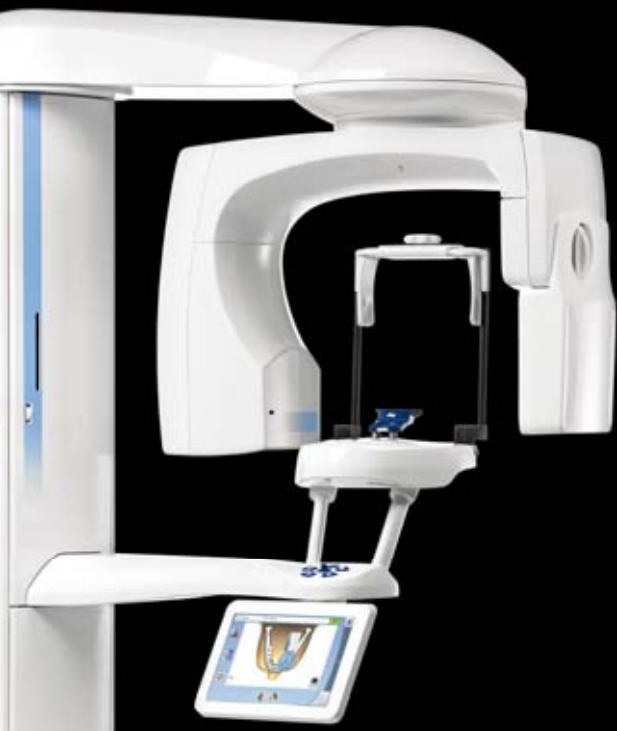Cover image courtesy of
BEGO Implant Systems GmbH & Co. KG
www.bego-implantology.com
Original Background: ©Click Bestsellers
Artwork by Sarah Fuhrmann, OEMUS MEDIA AG.



Planmeca ProMax® 3D

Planmeca Romexis®

Implant planning made easy



Planmeca Romexis® 3D Implant Planning software offers the most sophisticated tools for the needs of modern implantology.

- Superimpose surface scan on to CBCT data
- Use crown library or import patient-specific crown from CAD system
- Position the implant using realistic implant and abutment libraries
- Verify the implant plan with verification tool
- Order surgical guide directly from the software

Find more info and your local dealer
www.planmeca.com

PLANMECA



Planmeca Oy Asentajankatu 6, 00880 Helsinki, Finland. Tel. +358 20 7795 500, fax +358 20 7795 555, sales@planmeca.com

Maximal **aesthetics** in the **periodontally** compromised anterior maxilla

Immediate **implantation**

Authors_Dr Nikolaos Papagiannoulis, Dr Eduard Sandberg & Dr Marius Steigmann, Germany

_Introduction

In addition to habits, systemic diseases and bruxism, periodontal diseases are challenging problems in oral implantology. Here, surgeons have to deal with tooth loss, prolonged epithelia, bone resorption and loss of periodontal ligament. In the following case, we could clearly see at the preclinical analysis that major bone resorption had occurred horizontally as well as vertically. The bony defects referred to more than one wall, the bone resorption around the root was like a crater, infiltrated with soft tissue. Primary stability was difficult to achieve for the implant.

The periodontal treatment was the primary focus, accompanied by fillings and extraction therapy to cure acute inflammations and achieve oral health. Nevertheless, periodontal treatments result in regular to functionally and aesthetically compromised situations and unsatisfied patients. Further, periodontal treatment does not secure the adequate prosthetic treatment of the patient. Depend-

ing on the art of the restoration, teeth often have to be extracted, in spite of successful periodontal treatment. So the question to be asked is whether and when a periodontal treatment makes sense as a definite treatment or if it should be a tool that enhances later surgical and restorative procedures.

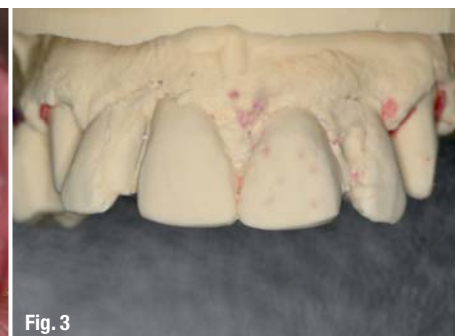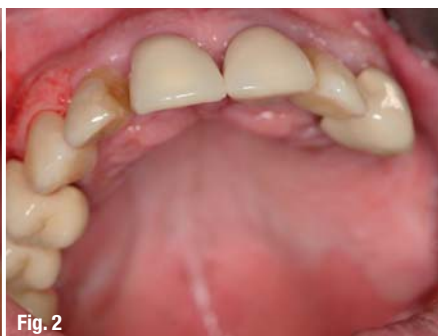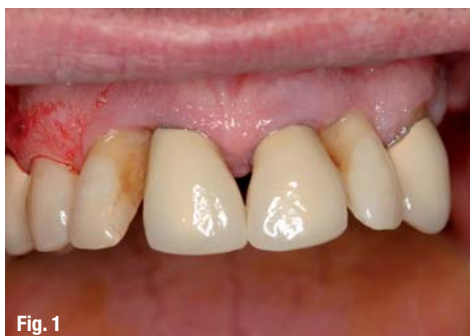_Clinical and radiological findings

The clinical examination showed a severe periodontal defect, screening index of Grade IV, pockets of up to 6 mm, tooth mobility grade II–III and a bleeding index of 3–4. The functionality was very limited and the aesthetic situation unsatisfactory. The existing prosthetics on the central incisors were too long to cover the recessions, resulting in further attachment loss. The aesthetics also were compromised, following periodontal fibre loss and bone support. Especially the lateral incisors suffered severely from loss of interproximal bone, followed by mesiorotations and ante-inclination (Figs. 1 and 2). Radiological findings confirmed that all four upper incisors needed to be extracted.

Fig. 1 _Initial clinical situation.

Fig. 2 _Initial clinical situation, coronally.

Fig. 3 _Situation models for provisional planning.



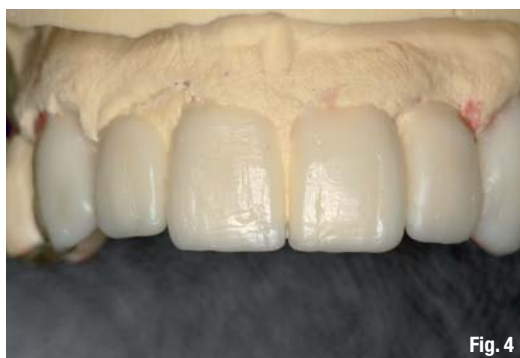

Fig. 4

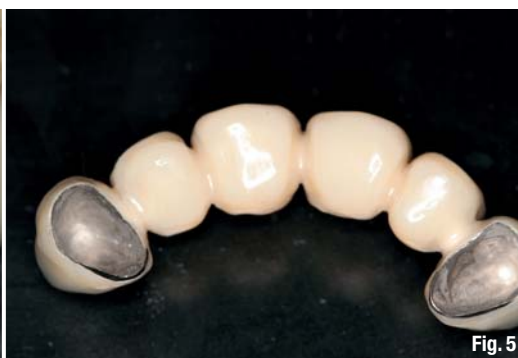

Fig. 5

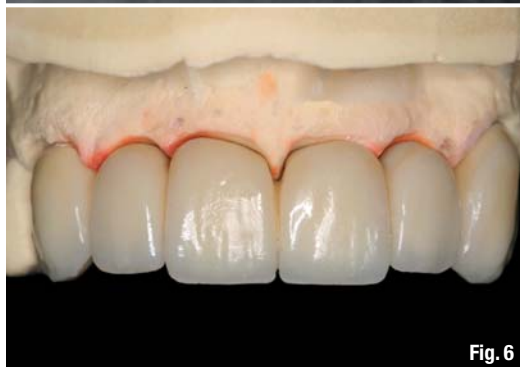

Fig. 6

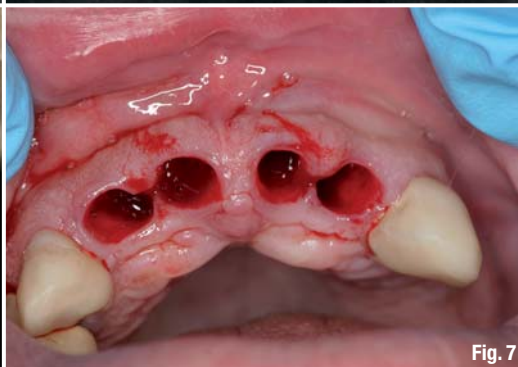


Fig. 7

Fig. 4_Wax-up of the provisional bridge.

Fig. 5_Provisional bridgework with pontics.

Fig. 6_Provisional bridgework frontally.

Fig. 7_Extraction sockets.

Treatment plan

Taking into consideration that the goal of surgical periodontal treatments is a screening index of 2–3 mm and that they almost always result in recessions, the outcome of these procedures is aesthetically poor. Especially in highly scalloped biotypes, patients are rarely satisfied. Longer prosthetics to cover the free root surface do not improve this outcome. On the other hand, these procedures are not always successful, resulting additionally in thermal sensitivities and persisting tooth mobility. Because of the high costs of surgical periodontology and the previous arguments, patients increasingly ask for alternative procedures. In the case discussed in this article, periodontal treatment would further neither aesthetic nor functional improvement, but only maintain the teeth for some months or years. The risk would be additional loss of bone and soft tissue, compromising future plans and prosthetic possibilities. The treatment plan for this case included conservative periodontal treatment and recall to treat inflammations, tooth extraction and immediate implantation with guided bone and tissue regeneration.

Surgery

Before extracting the incisors, the crowns 13 and 23 were removed and the teeth were prepared to receive temporary bridgework. With a wax-up on the situation model and pontics, an optimal form was created to support and manipulate soft tissue during the healing phase. At the same time the tempo-

rary bridge functions as wound coverage if primary closure is not possible (Figs. 3–6).^{1–4}

In the next step, the teeth 12 to 22 were extracted. The flap outline spared the middle papilla and mesial ones on 12 and 22. Due to interproximal bone defects, raising of the papilla in this region would have led to severe recessions. The vertical bone defects, especially between 11 and 12, were obvious after raising a full-thickness flap. Releasing incisions were placed distally at the canines and only in the attached gingiva to prohibit scar formation through vertical cuts in the mucosa. The low vestibule made a split thickness or periosteal pocket flap less logical. Mobilizing soft tissue from the lips by other flap designs would provoke functional limitations, suture tension and a secondary gum plastic to reposition the coronal transpositioned soft tissue. The wound margins were freshened to remove prolonged epithelia and the bone defects freed from soft tissue ingrowth (Figs. 7–10). The horizontal bone loss was moderate. Implants were placed slightly subcrestally. Although the gap between implants and the buccal plate was approximately 1–1.5 mm and the buccal plate thickness 1–1.5 mm due to the resorption, we decided for 3.8 mm implants, leaving a 1.5 mm gap to the buccal plate.^{5–10}

The interimplant space and the buccal plate were augmented with a combination of allograft and xenograft. Xenograft was also placed on the buccal plate so as to manipulate buccal plate resorption. A pericardium membrane was used as barrier (Fig. 11).

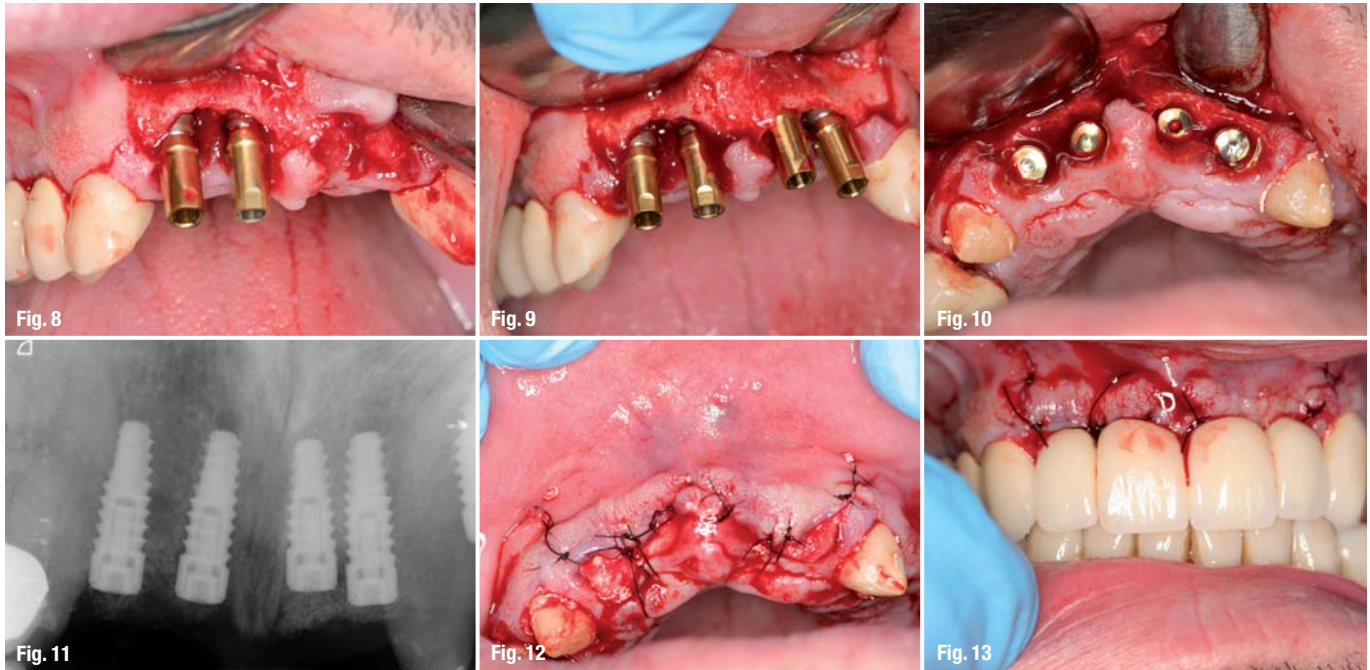


Fig. 8_Flap raising and implantation.

Fig. 9_Implantation of four implants.

Fig. 10_Inserted implants, coronally.

Fig. 11_Radiological control after surgery.

Fig. 12_Flap closure.

Fig. 13_Provisional bridge in situ.

The anatomy of the upper jaw and the low vestibule did not allow primary closure. To protect the membrane from proteolytic resorption and the augment, we placed two layers of tissue fleece above the membrane. Through the collagen fleece and the protection of the provisional bridge, free granulation of the extraction socket cover was expected after two weeks (Fig. 12).^{11,12}

The patient received a weekly recall with prophylaxis and hygiene instructions. Three weeks postoperatively, sutures were removed. The clinical situation showed no irritation and the wound healing and closure ideal (Fig. 13).

Re-entry and prosthetics

The re-entry was performed after three months with minimally invasive crestal cuts. A papilloplastic adjusted the wound margins between 11-12 and 21-22 (Fig. 14). After three additional weeks, impression was performed. The healed situation showed optimal soft tissue quality and adequate attached gingiva quantity. We measured 2-2.5 mm soft tissue height above the implant necks, enough for the necessary emergence profile. With the help of convex or concave formed prosthetics, soft tissue can be manipulated to the direction needed for esthetics (Figs. 15 & 16).¹³⁻¹⁶

The final crowns show great results. The papillas and pseudopapillas fill up the approximal space. The approximal contact had to be longer and wider than normally in order to compensate the former vertical bone loss, especially in the region 11-12. Nevertheless, there were no black triangles, the patient was satisfied

and with the proper hygiene, the aesthetic outcome will be optimized in the next months. Therefore, there was no need to work with rose ceramics (Figs. 17-19).

Discussion

In the periodontally compromised situation, it is important to decide on whether a curative periodontal treatment offers satisfactory long term results. As in this occasion, the extraction in a crucial moment helps us preserve what we have, use it to the maximum for the implant surgery and risk no further bone loss or recessions. Any other procedure would have led to a two-stages surgical approach and probably to removable prosthetics. Very favourable was the thick biotype of the patient, such as the low lip line. The soft tissue quantity was evident. Tension on the flap closure was prohibited by the surgical protocol and the free granulation of the wound. The bone quantity insured a primary stable implant insertion. Immediate implantation provided stability for the augmentation and less material. The positioning of the implant allowed us to create an optimal emergence profile, making complicated soft tissue procedures unnecessary.¹⁷⁻¹⁹

The clinical situation and the bony defects made clear during surgery that we would have to make an aesthetic compromise in region 11-12. The bony support of the interproximal soft tissue is difficult to regenerate and the pseudopapilla formation not predictable. Immediate implantation in these regions preserve hard and soft tissue. Through the positioning of the implants and the free granulation of the extraction wound, we enhance the soft tissue, a major advantage for the re-entry and prosthetics.²⁰⁻²²

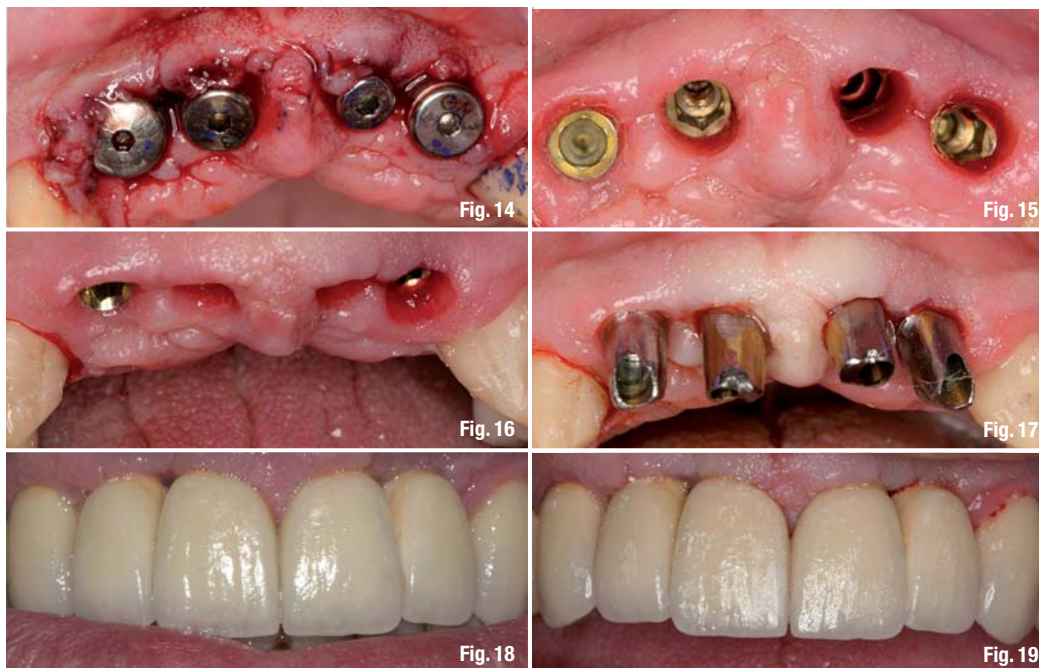

Fig. 14_Re-entry with healing abutments.

Fig. 15_Three weeks after re-entry.

Fig. 16_Papilla morphology after healing abutments.

Fig. 17_Definite abutments try-in.

Fig. 18_Final prosthetics.

Fig. 19_Pseudopapilla formation after three months of loading.

The implants placed feature micro grooves at the implant neck in a height of 1 mm. This laser manufactured design imitates biology and promises an improved cell adhesion on this surface. These modern designs, combined with the advantages of platform switching, result in high tech products. Modern crestal bone maintenance functions because of the protection of the crestal bone. When implants are placed subcrestally or crestally, a soft tissue ring builds on the platform and protects the bone beneath. When implants are placed supracrestally, implant neck options secure the crestal bone beneath, through soft tissue fibre attachment of their necks.^{23,24}

In cases in which primary closure is not possible or mobilization of neighbouring soft tissue through other flap designs is not wanted, temporary prosthetics are essential. The soft tissue manipulation begins from the very first moment and decides about the aesthetic outcome.²⁵⁻²⁷

The clinical situation after three weeks with healing abutments needed to be altered buccally at 11 and 21 and manipulated 0.5 mm apically. This was achieved via individualized abutments with convex base and breadth of 1 mm. In contrast, the gingiva margins at the lateral incisors needed to be corrected coronally. Therefore, we used narrow abutments to give soft tissue more space to head coronally.¹³⁻¹⁵

The combination of the biomaterials belongs to our standard augmentation protocol and is well documented. The results of guided bone regeneration are predictable and can be planned, even in major defects. In addition to the combined biomaterials, their structure is very important. Rocky and edgy particles help

internal stabilisation at the augmentation area. Often is an external stabilization with pins or screws unnecessary. The porosity of the particles is defined through their biology. This is the reason why we prefer no alloplastic biomaterials and take advantage of the pros of combined allografts and xenografts. At the same time, these are the requirements of modern biomaterials, accompanied of course by inductivity and conductivity.²⁸⁻³⁰ Periodontal diseases are a regular limitation factor in oral implantology. Thus, there are situations in which periodontal disease pose no contraindication to implantology. Preconditions for similar procedures are understanding and knowledge of biology, surgery and prosthetics. These procedures underlie no algorithms but proper diagnosis, analysis and planning of every individual patient and the choice of the appropriate implant system and biomaterials. Modern implantology provides all tools for successful implant treatment. Complications are, however, severe and can hardly be solved without compromises.

Editorial note: A list of references is available from the publisher.

_contact

implants

Dr. Nikolaos Papagiannoulis

Steigmann Institute
Bahnhofstraße 64
69151 Neckargemünd
Germany

m.steigmann@t-online.de
www.implantologie-heidelberg.de