

implants

international magazine of oral implantology

2²⁰¹⁶



research

Morbidity after harvesting of autologous pelvic bone

case report

Bimaxillary implant restoration by all-ceramic bridges

interview

A nuanced perspective on periimplantitis



It is not a trick. It is
legendary science.
Discover the magic of
the tapered standard.

Designed for excellent primary stability thanks to an apically tapered implant with groundbreaking material and surface technology for maximizing predictability.

The Bone Level Tapered Implant – the new tapered standard. Engineered in Switzerland, home of Straumann.

<http://blt.straumann.com>



Material

Roxolid®



Surface

SLActive®



Education at its best



Dr Rolf Vollmer

Responding flexibly to individual and contemporary demands on further education has always been a strength of the DGZI e.V. Thus, we have established various further-education opportunities with the DGZI curriculum, our study groups and the DGZI International Annual Congress, which this year takes place from 30 September to 1 October in Munich—the last Oktoberfest weekend. All of those events can be adapted to individual learning demands.

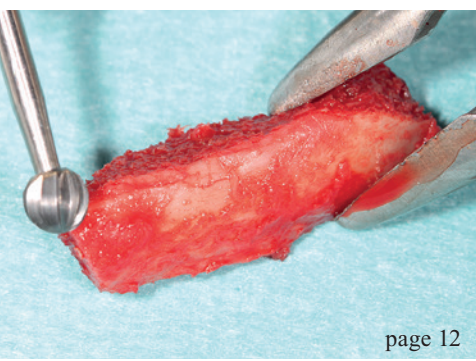
At the same time, Europe's oldest specialist association of dental implantology aims at discovering and training new opinion leaders, who can prove themselves in our DGZI Young Generation study groups for the first time. Only in this way can our society achieve to maintain implantology as a pioneering discipline for modern therapy approaches and technical innovation in dentistry.

In this regard, I should also mention the DGZI Implant Dentistry Award, which is granted annual at the DGZI International Annual Congress. This international award, which is endowed with 10,000 Euros, is granted by the DGZI scientific board in order to acknowledge ground-breaking scientific achievements in implantology. Therefore, it is the DGZI's most important form of honouring which is aimed at all implantologists in training who engage themselves in academics and science. The final date for this year's applications is 30 June 2016. Please contact our headquarters for further information.

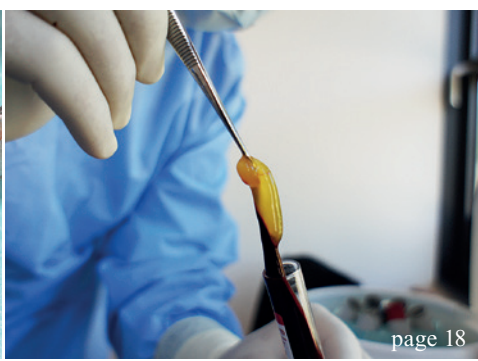
I would like to end with encouraging you to enjoy reading this latest edition of **implants international magazine of oral implantology**.

Warm regards,

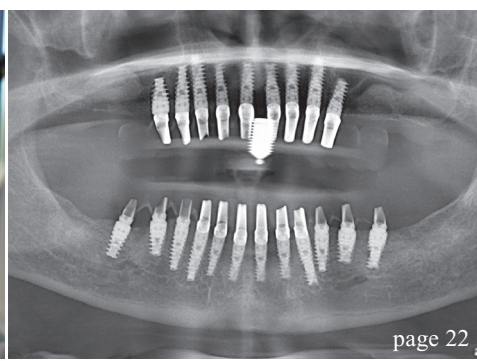
Dr Rolf Vollmer
First Vice President and Treasurer of the German Association of Dental Implantology



page 12



page 18



page 22

| editorial

- 03 Education at its best
Dr Rolf Vollmer

| research

- 06 CBCT zones of the jaw
Souheil Hussaini
- 12 Morbidity after harvesting of autologous pelvic bone
Prof. Dr Dr Peter Stoll, Dr Verena Gaydoul,
Dr Verena Stoll, Dr Kai Höckl & Dr Georg Bach

| case report

- 18 A-PRF as sole grafting material in sinus lifts
Dadi Hrafnkelsson
- 22 Bimaxillary Rehabilitation
OA Dr Björn Dziedo, CA Prof. Dr Dr Stefan Schermer &
Dr Elena Mihalcioiu

| industry

- 30 Fixed implant-supported prostheses
Zhe qu, Xiang zhang & Lan ma
- 36 A nuanced perspective on periimplantitis
Dr Stefan Holst

| events

- 42 6th International CAMLOG Congress
in Krakow

| news

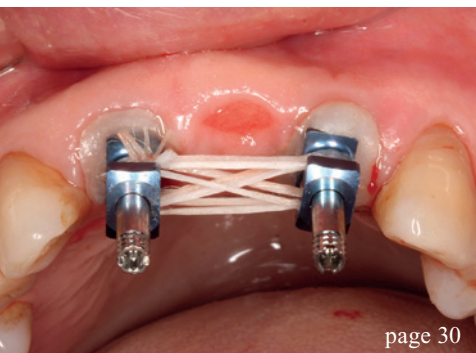
- 38 manufacturer news
- 46 news

| about the publisher

- 50 imprint



Cover image courtesy of Nobel Biocare Deutschland GmbH
www.nobelbiocare.com



page 30



page 36



page 42

Implant planning made easy

Planmeca PlanScan®

Planmeca ProMax® 3D

3_{3D}X

Planmeca Romexis® software offers a completely integrated and digital workflow for modern implantology. From intraoral scanning to easy prosthetic design and realistic implant libraries, the most sophisticated implant planning tools are just a few clicks away.

- All the scanned and design data for prosthetic works is immediately available and can be mapped with the patient's CBCT data
- Use crown library or patient-specific crown from CAD system
- Verify the implant plan with verification tool
- Order surgical guide directly from the software
- Share data easily with partners through **Planmeca Romexis® Cloud** image transfer service



Find more info and your local dealer
www.planmeca.com



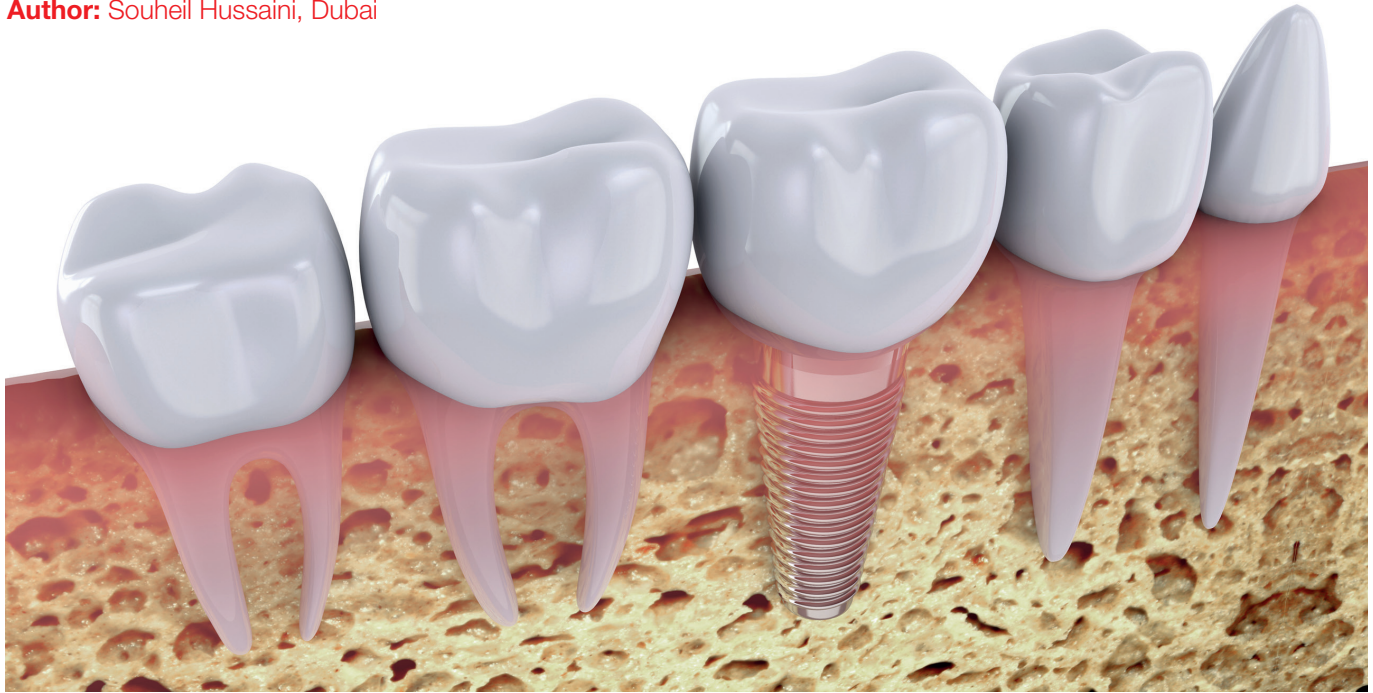PLANMECA



CBCT zones of the jaw

Bone quality related to implant location

Author: Souheil Hussaini, Dubai



© romma/Shutterstock.com

Introduction

The causes of early implant failures during the osseointegration process include poor quality and quantity of bone and soft tissue,¹⁻⁸ the patient's medical condition,^{2,6,8-10} unfavorable patient habits (bruxism, heavy long-term smoking, poor oral hygiene, others),^{3,4,6,8,11} inadequate surgical analysis and technique,^{3,7-9,11} inadequate prosthetic analysis and technique,^{3,7,8,11-13} suboptimal implant design and surface characteristics^{6,9,13} implant position or location¹⁴ and unknown factors.

This article attempts to further investigate implant location as one of many factors in early stages of diagnosis that improves success rate in implant dentistry treatment. Predisposing factors to implant complications in different jaw regions are discussed.

CBCT Zones D1 to D5 is formulated to better analyse implant dentistry procedure preparation during the diagnostic phase based on the location that has a logical sequence during examination of the alveolar ridge of both maxilla and mandible to have pre-existing information regarding the demands and the clin-

ical requirements in different zones of the jaws. This article identifies the Hounsfield units (HFU) of different alveolar jaw regions, according to which dental implants can be inserted with better understanding of what to expect.

Five CBCT zones are identified in this article in a logical sequence: the discreet zone D1 being the anterior mandible, the danger zone D2 being the posterior mandible, the death zone D3 being the anterior maxilla, the demand zone D4 being the posterior maxilla and the delicate zone D5 being the posterior maxilla that requires sinus lift procedure.

Zones D1–D5 are related to the bone quality classification of Lekholm & Zarb.¹⁵ D1 known as an interforamina area in which a careful diagnosis should be made due to the following procedure, bone density is very high and the osteotomy drills could heat the bone, irrigation temperature could facilitate healing response, dullness of the drills during osteotomy should be counted for, tap drills are required, arterial supply in the symphysis area should be considered and this area is utilised as a donor site for the chin (symphyseal) block bone graft. D1 includes six

Nobel Biocare Global Symposium

June 23–26, 2016 – New York

Where innovation comes to life



Register
now

nobelbiocare.com/global-symposium-2016

An experience beyond the ordinary

The Nobel Biocare Global Symposium 2016 program will offer unparalleled clinical and scientific education, as well as in-depth hands-on training. Held at the Waldorf Astoria in New York, it's a unique opportunity to experience how innovation can come to life in your daily work.

Design your own learning experience

Choose from numerous lectures, forums, master classes and hands-on sessions – from over 150 of the best speakers and presenters in the world. This must-attend event will cover a vast variety of techniques and treatment solutions, from diagnosis to treatment completion. Don't miss this opportunity. Sign up now and we'll see you in New York!



[Read more about the Symposium](#)



anterior teeth: four incisors and two canines. A thin alveolar process in this area necessitates implant diameter selection of a narrow-to-standard diameter (3–4 mm). Based on many case reports, a penetration of the thin lingual mandibular cortex during an implant insertion in this area on occasion can lead to serious bleeding with formation of expanding sublingual haematomas.^{16–24} Haemorrhage from a branch of the sublingual artery (a branch of the lingual artery), the submental artery (from the facial artery), or the mylohyoid artery (from the inferior alveolar artery, a branch of the maxillary artery) or their anastomoses can in some cases cause a life-threatening airway compromise.^{19–22} Tepper et al. demonstrated the presence of at least one (sometimes multiple) lingual perforating vascular bone canal(s) and suggested a routine CT examination prior to an implant procedure in this area.²¹ A similar report of serious haemorrhage from an implant insertion in the first mandibular premolar position also suggests a common arterial supply of all eight mandibular front teeth and one more reason for including first premolars in this zone.¹⁶ A successful placement of two to six implants in this zone in many edentulous arch cases offer a stable foundation for a variety of implant-retained and implant-supported removable and fixed mandibular prostheses. A symphyseal (chin) monocortical block bone graft harvested in this area is often used for the horizontal augmentation of bone in other regions, especially for the anterior maxilla.

D2 is a bilateral area of the alveolar ridge of the posterior mandible from the first premolar to the retro-molar pad. The mental foramen in the front and the inferior alveolar canal below limits this functional implant zone. An implant's success in this area relates to the quality (density) of bone and quantity of preserved alveolar ridge, among other factors. The ramus block bone graft is often harvested in the proximity of this zone. Embryologically, this bilateral mandibular alveolar zone develops above the inferior alveolar canal. The alveolar height between the inferior alveolar canal and the alveolar crest is routinely analysed in oral implantology when posterior mandibular implants are considered. A heavy masticatory demand during function, especially for people with parafunctional habits, necessitates an insertion of two to three implants into this region for replacement of missing first, second premolar, first molar, and occasionally the second molar.

D3 is a zone of the alveolar ridge of the anterior maxilla (aesthetic area), including six front teeth: four incisors and two canines. Part of the anterior maxilla is a protruding alveolar process with thin labial and thick palatal cortical plates covering and protecting the upper front teeth. A prominent position

of the anterior maxilla and upper front teeth in the face is responsible for bone and soft-tissue injuries.²⁵ Fracture of crowns and roots, subluxation, displacement and avulsion of teeth are frequent in this zone.²⁵ The main blood supply to the anterior maxilla is derived from the branches of the maxillary artery: the anterior superior alveolar artery (from the infra-orbital artery), the greater palatine artery, and the nasopalatine artery. A middle superior alveolar artery is occasionally described as a branch of the infra-orbital artery that supplies the region of the canine tooth. The anterior and middle superior alveolar arteries anastomose with the posterior superior alveolar artery to form an arterial network feeding both endosteal and periodontal plexuses.

Another traumatic event in the life of the alveolar ridge is a tooth loss. A tooth extraction, or periodontal disease also leads to bone resorption. The progression of healing after a tooth extraction goes through certain resorptive stages of fibrin clot organisation (first four weeks), immature (woven) bone formation (four to eight weeks), mature (lamellar) bone development (eight to twelve weeks), and bone stabilisation stage (twelve to 16 weeks or about four months).^{26–28} Post extraction bone resorption is always three-dimensional, with the greatest loss of bone in the bucco-palatal or horizontal direction (the width) and occurring mainly on the buccal side of the alveolar ridge.²⁸ Schropp et al. reported that two thirds of the horizontal bone loss occurs within three months and one-third takes place within the remaining nine months of the first year post extraction.²⁹ A mean reduction of the width of the ridge has been reported to be 5 to 7 mm within a six-month period or 50 per cent during the twelve months following tooth extraction.²⁹ The loss of bone height is smaller, reported to be about 1 mm within the first six months post extraction.^{20,29} If a bone grafting and implant treatment approach is not considered soon after trauma, the atrophy of the alveolar process of the anterior maxilla continues with time. Resorption of the buccal plate compromises the anatomy of the edentulous alveolar ridge and makes it difficult to place an implant in the prosthetically favourable position.³¹ Even when a dental implant is placed, its strength is diminished without the presence of a buccal cortical plate. Using a two-dimensional finite-element model for stress analysis, Clelland and associates demonstrated low stresses and high strains surrounded the implant for the all-cancellous (lack of cortical plate) bone model.³² When a layer of thick cortical bone was added to the model, it had a significant impact and improved stresses and strains on the implant.

D4 is related to first and second premolars in the maxillary region and rarely first and second molars.

Although this area is not considered the maxillary anterior teeth, it is still a prime concern for the patients during conversation and smiling. In addition to two anterior premolar teeth, two posterior molars are not considered as a separate class in this group if sinus lift is not required due to their common bone quality. These implants once restored are the longest support in front of maxillary sinuses. Park, Hyo-Sang et al. reported that the cortical bone density of the maxilla ranged approximately between 810 and 940 HFU at the alveolar bone except for the maxillary tuberosity (443 HFU at the buccal and 615 HFU at the palatal alveolar bone), and between 835 and 1,113 HFU at the basal cortical bone except for tuberosity (542 HFU).³³ The cortical bone density of the mandible ranged between 800 and 1,580 HFU at the alveolar bone and 1,320 and 1,560 HFU at the basal bone. The highest bone density in the maxilla was observed in the canine and premolar areas, and maxillary tuberosity showed the lowest bone density. Density of the cortical bone was greater in the mandible than in the maxilla and showed a progressive increase from the incisor to the retromolar area.

D5, known as the sinus zone, is a bilateral zone of the alveolar ridge of posterior maxilla located at the base of the maxillary sinus from the second premolar to pterygoid plates. There are certain common features of replacement of missing tooth or teeth (rarely two premolars and commonly one or two molars) with dental implants in this zone. It often relates to the degree of sinus pneumatisation and vertical bone deficiency that may require supplemental surgical procedures in the subantral area in order to place endosseous implants.

This bilateral maxillary posterior zone that extends from the second premolar to the pterygoid plates is located at the base of maxillary sinuses (antra of Highmore). Embryologically, the hard palate and the

alveolar process of the maxilla form the barrier between the maxillary sinus and the oral cavity. The bone height between the floor of the maxillary sinus and the alveolar crest is routinely analysed in oral implantology when posterior maxillary implants are contemplated. An increase of sinus volume or sinus pneumatisation after a loss of posterior tooth/teeth often necessitates vertical bone augmentation with a sinus lift procedure. The bone of this region is also known to have compromised bone quality (types 3 and 4) that can increase an implant failure rate. The main blood supply to the posterior maxilla derives from the posterior superior alveolar artery, the greater and lesser palatine arteries (all from the maxillary artery), the ascending pharyngeal branch of the external carotid artery, and the ascending palatine branch of the facial artery. An injury to the posterior superior alveolar artery during the lateral approach for subantral augmentation can cause haemorrhage that may require coagulation.

Materials and method

From a database of 1,134 patients who had received 4,800 dental implants from 2001 till August 17th 2015, randomly a prosthodontist with no knowledge of these criteria was requested to select 100 files from the data base and present them for this study. The 100 files had received panoramic and cone beam computed tomography (CBCT, Table 1) during their diagnostic visit. The average HFU of the randomly selected 100 cases was calculated.

Results

Hounsfield unit: The data in table #1, out of 100 samples, demonstrated that the average HFU was the minimum in D5 (213 HFU), and followed by D4 (528 HFU), D3 (561 HFU), D2 (599 HFU) and D1 (654 HFU) in ascending order respectively (Fig. 1 and Table 2).

Discussion

There are few literature reports that attempt to study implant location, among a multitude of other factors, to determine its influence on the success or failure of dental implant treatment. Becker et al. evaluated 282 implants placed in the maxillary and mandibular molar positions in a prospective study.³⁴ The six-year cumulative success rate (CSR) for maxillary posterior implants was 82.9 per cent, for mandibular posterior, 91.5 per cent. He concluded that CSR in the posterior regions is lower than usually reported for anterior regions of the maxilla and mandible due to differences in bone quality and quantity. Eckert et al. assessed 1,170 endosseous implants placed in partially edentulous jaws in a

Technical data	
Anode voltage	60–90 kV
Anode current	1–14 mA
Focal spot	0.5 mm, fixed anode
Image detector	Flat panel
Image acquisition	Single 200 degree rotation
Scan time	7.5–27 s
Reconstruction time	2–25 s

Table 1