

# implants

international magazine of oral implantology

3<sup>2015</sup>



| **research**

A time shift link:  
Implant planning affects  
periimplant diseases

| **case report**

Quality of implant surfaces and  
poor osseointegration

| **events**

“Dental technology and implantology —  
Interface to success”



# Implant planning made easy

Planmeca PlanScan®

Planmeca ProMax® 3D

3<sub>3D</sub>X

**Planmeca Romexis® software** offers a completely integrated and digital workflow for modern implantology. From intraoral scanning to easy prosthetic design and realistic implant libraries, the most sophisticated implant planning tools are just a few clicks away.

- All the scanned and design data for prosthetic works is immediately available and can be mapped with the patient's CBCT data
- Use the crown library or a patient-specific crown from a CAD system
- Verify the implant plan with a verification tool
- Order a surgical guide directly from the software
- Share data easily with partners through the **Planmeca Romexis® Cloud** image transfer service



Find more info and your local dealer  
[www.planmeca.com](http://www.planmeca.com)



Planmeca Oy Asentajankatu 6, 00880 Helsinki, Finland. Tel. +358 20 7795 500, fax +358 20 7795 555, sales@planmeca.com

# PLANMECA



Dr Rolf Vollmer

# Dear readers,

In this edition of implants we would like to welcome you back after the summer break and to take a look at our activities of the past weeks while also bringing to your attention this year's annual international DGZI congress.

As the oldest professional association in Europe, the DGZI's key concern has always been to communicate as well as further develop the scientific and user-orientated standards of modern implantology.

In addition to our partners in the US, Japan and the Middle East, our board members have established new contacts with Mexico as a gateway to the South American region. This region shows a great interest in the training opportunities provided by the DGZI.

However, our biggest event remains the annual international DGZI congress. For the 45<sup>th</sup> time running, the congress will take place on 2–3 October at the Dorint Hotel in Wiesbaden and is dedicated to the main topic of "Dental technology and implantology—Interface to success".

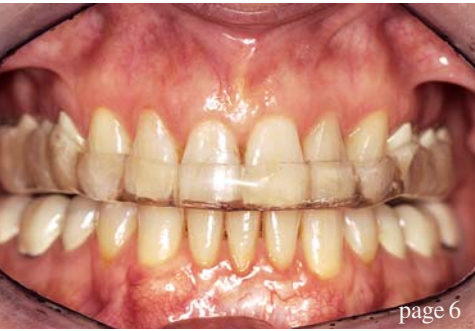For years, the DGZI has been promoting the teamwork of dentists and dental technicians. This year's congress theme highlights once again the DGZI's emphasis on this particular team spirit. In numerous shared presentations, dentists and dental technicians have the opportunity to express their role in making the implantological teamwork a success. Furthermore, we hope not only to see consensus among the speakers but fruitful and stimulating discussions that will ultimately benefit the patients.

Hoping to have caught your professional interest in our association, I wish you an enjoyable read of the new edition.           


Dr Rolf Vollmer

First Vice-President and Treasurer of the German Association of Dental Implantology

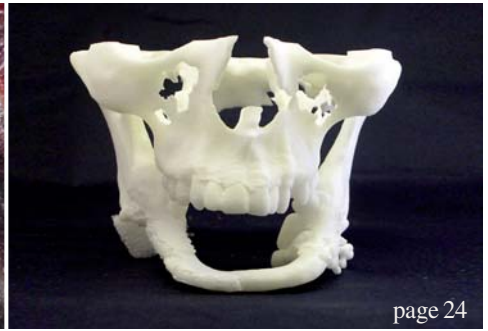



page 6



page 16



page 24

| editorial

03 **Dear readers**

| Dr Rolf Vollmer

| research

06 **Implant planning** affects periimplant diseases

| Rainer Buchmann *et al.*

| case report

16 **Quality of implant surfaces** and poor osseointegration—Part II

| Dr Nikolaos Papagiannoulis *et al.*

24 **Mandibular body reconstruction** with a 3-D printed implant

| Dr Saeid Kazemi *et al.*

28 **Simplifying implantation** in socket and ridge preservation

| Martin Keweloh *et al.*

34 **Immediate loading** with dynamic navigation implant surgery

| Dr Jan D'haese *et al.*

| industry

42 **Implant design** of the future

| Georg Isbaner

| events

44 **UNAM Congress opens in Mexico City**

46 **EuroPerio in London**

| Georg Isbaner

48 **“Dental technology and implantology—Interface to success”**

| DGZ

| news

38 **Manufacturer News**

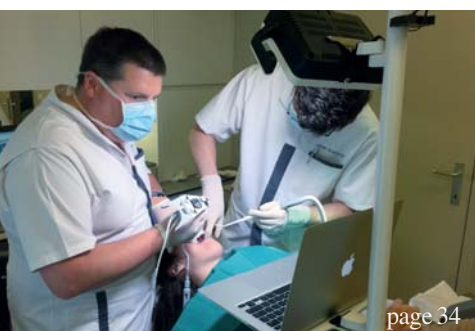49 **News**

| about the publisher

50 | imprint



Cover image courtesy of Straumann GmbH  
[www.straumann.de](http://www.straumann.de)



page 34



page 42



page 46



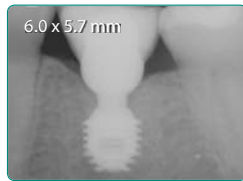
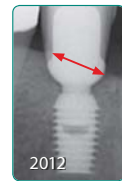
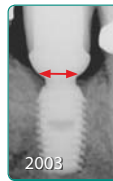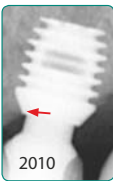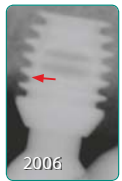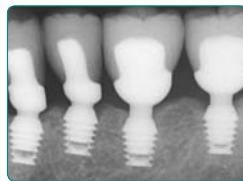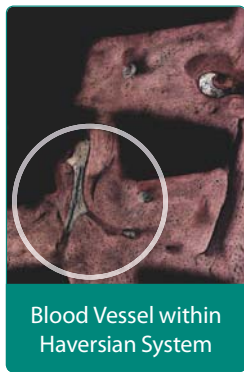
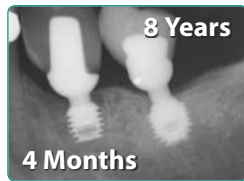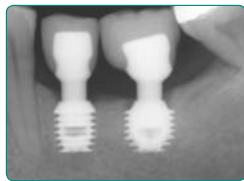

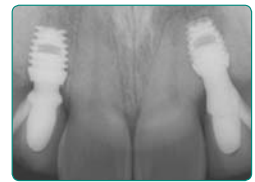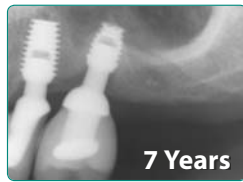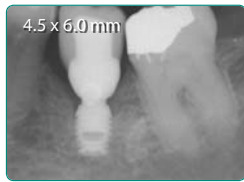
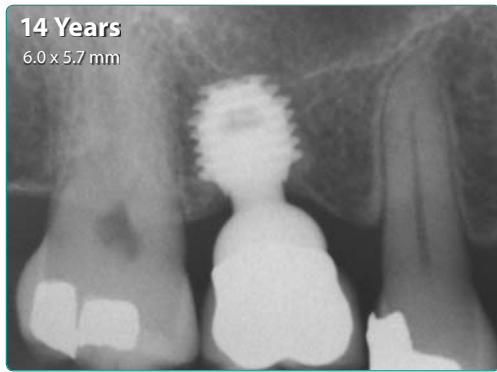
# bicon®

DENTAL IMPLANTS

Since 1985 » Simple. Predictable. Profitable.



## SHORT™ IMPLANTS



# Implant planning affects periimplant diseases

## A time shift link

**Author** Rainer Buchmann, Daniel Torres-Lagares & Guillermo Machuca-Portillo, Germany & Spain

Implants are becoming increasingly popular with low-cost offers promoting this development. The number of customers preferring implants to customary restorations is expanding. The variety of client demands, individual settings, treatment options and risks related to inflammation and bone damage following implant treatment advocate evident, comprehensible and durable solutions.

Safeguarding implant treatment commences with careful tooth removal, pre-implant treatment and implant planning respecting four key issues:

1. Early decision making to ensure implant bone support with limited number of implant placements.
2. Sound tooth removal to protect bone loss by intraalveolar root dissection.
3. Accuracy of implant diagnosis and implant placement by 3-D visualization (DVT) of implant surgical access.
4. Minimal surgical involvement with short and low diameter implants while restricting augmentation to prosthetic relevant settings.

### Planning

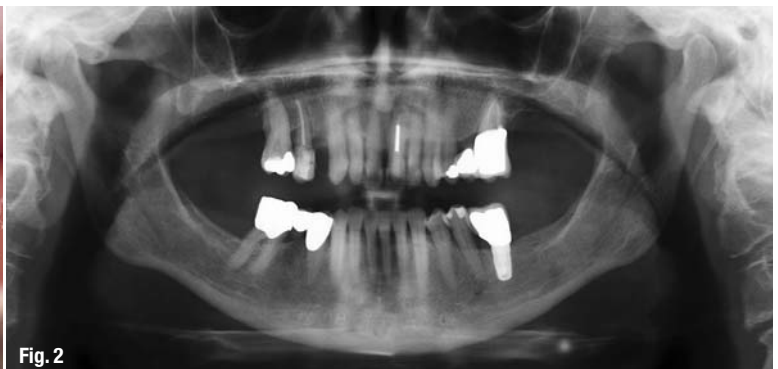
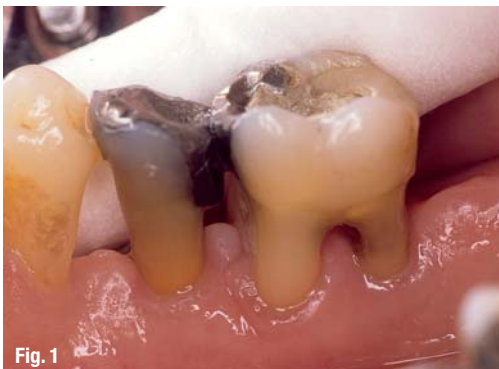#### Early Decision Making

Early implant decision making comprises anatomical, functional and economic issues:

- a) Anatomy: Treated severe periodontitis usually displays clinical stability with further drawbacks around implant supported bone at buccal plates or interapproximal sites by inflammation (Figs. 1 & 2).<sup>1</sup>
- b) Function: Following untreated periodontal diseases or tooth removal, shifting of single tooth initiates due to myofunctional imbalance. By loss of front-canine equilibration, a group side shift emerges with further bite reduction as result of age and misuse.<sup>2</sup>
- c) Dues: Periodontal therapy of severely compromised teeth with bone loss > 50% often results in a later date implant treatment that doubles dental efforts and bills. Economic issues should downregulate this strategy.
- d) Oral comfort: Stability, oral hygiene and esthetics become fostered by timely implant placement and optimized implant prosthetics.

**Fig. 1** Severe periodontitis, residual inflammation and bacteremia. Poor hygienic capability, comfort and esthetics with furcation caries.

**Fig. 2** Drawn-out expectation period in advanced periodontal disease at # 15, 16 with horizontal alveolar bone resorption at assigned implant site (see Fig. 14).





More than  
primary stability.  
The new tapered standard.

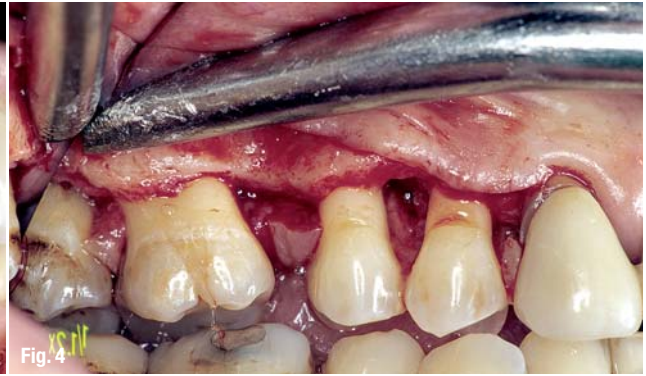
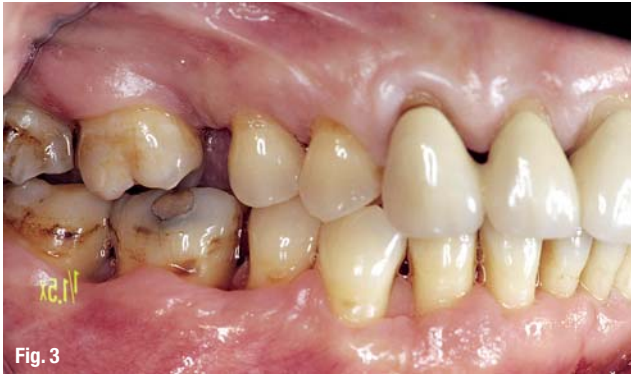
The perfect symbiosis of design, material and surface –  
the Straumann® Bone Level Tapered Implant:

- Roxolid® material – Reducing invasiveness with smaller implants
- SLActive® surface – Designed to maximize your treatment success and predictability
- Apically tapered – Excellent primary stability even in compromised bone situations
- CrossFit® connection – Simplified handling, legacy of Bone Level System

In combination with:





**Fig. 3** Surgical access to deep intrabony periodontal pockets securing the residual dentition and safeguarding inflammation prior to implant placement following completion of non-surgical periodontal therapy.

**Fig. 4** Microsurgical revision using a vascular pedicle flap to maintain interdental papillae and augment resting periodontal pockets with autogenous bone. Usage of Osteora (antiinflammatory) or Emdogain, if applicable.

**Fig. 5** Relaxation appliance in the maxilla with a frontal plateau to decompensate age and use related bite reduction prior to final implant planning.

**Fig. 6** Temporary relief from damage resulting from use (wear) and habits by restoring a front-canine equilibration.

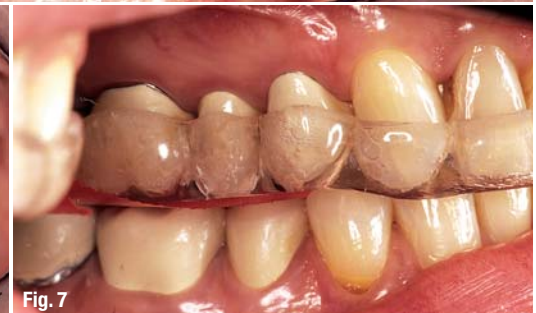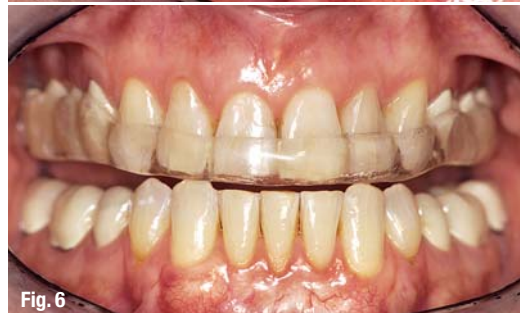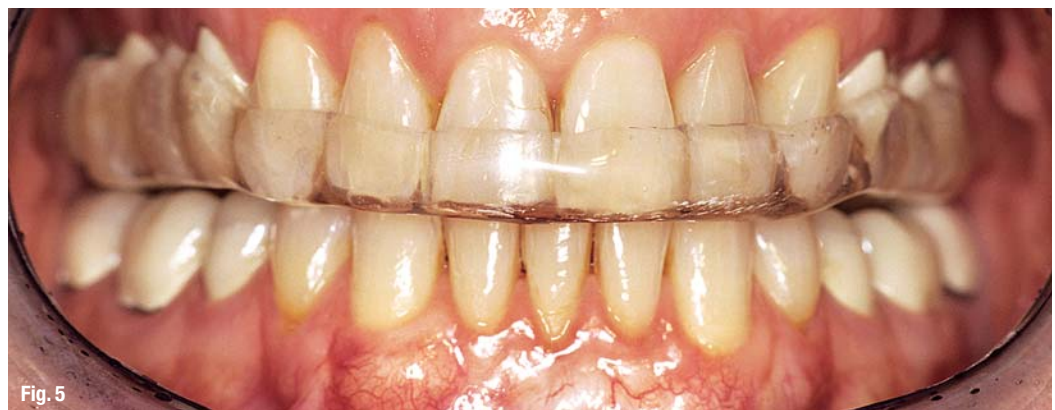**Fig. 7** Vertical release of 1 mm achieving premolar and molar relief to promote bone healing following treatment of periodontal compromised sites prior to implant surgery.

Clinical practice emphasizes a time-tested planning with (i) removal of severely compromised teeth, (ii) periodontal therapy securing the residual dentition, supplemented by (iii) microsurgical revision of deep intrabony pockets prior to implant placement to safeguard inflammation (Figs. 3 & 4). Implant planning resides tentatively. A final quotation will be drawn after completion of functional relief and 3-D digital evaluation of the implant bone anatomy.

*Functional decompensation*

Fully and partially edentulous patients frequently reveal a bite reduction by usage (wear) with loss of front-canine equilibration and a resulting left and right grouped premolar and molar sideshift.<sup>3</sup> Dysfunction and habits (pressing, grinding etc.) promote further damage. In severe periodontitis, group sideshift accelerates disease progression, impedes post therapy healing and weakens alveolar bone assigned for later implant placement. Early implant planning includes following key issues:

1. Inspection of the oral cavity comprises evaluation of the mastication muscles (M. temporalis, M. masseter) and the temporomandibular joints (M. pterygoideus medialis und lateralis) with focus of tension, induration and pain pressure.
2. Osteopathic examination of craniocaudal dysfunctions: initiated by body statics (inclined position), (mis-)posture, walk (activity) etc. should exclude somatic sources. If applicable supportive therapy. If applicable, manual osteopathic treatment to improve physiologic function, i.e. body alignment, symmetry and support homeostasis that has been altered by somatic dysfunctions.<sup>4</sup>
3. Carefull reduction of prominent protrusive contacts (front) and sliding bars during laterotrusion on the operating side.
4. Placement of a relaxation appliance in the maxilla (overbite and deep bite in the mandible) for functional decompensation with a frontal plateau allowing a front-canine equilibration and temporary relief in molars by vertical release of 1 mm (Figs. 5–7).





**MORE BONE** Where it Matters Most...



Find out more about the new V3 Implant at: [www.V3-implant.com](http://www.V3-implant.com)

**V3** By *MIS*