

ceramic implants

international magazine of ceramic implant technology



research

Dental implants and
bone marrow defects

case report

Ceramic implant placement
in a medically compromised patient

industry

Patent™ —the proven master of zirconia implants



SICwhite
the individual approach



Metal free. Cement free. Two parts.

www.sic-invent.com



Janine Conzato

Managing editor



A new year, new faces and new long-term data

Today, patients have significant access to information and may come into the dental office with in-depth questions or recommendations regarding their treatment. Responding to these may require dentists to learn more about new procedures or technologies, looking at the scientific evidence with a critical eye. Regarding dental implantology, for example, there is market demand for a broader range of indications and greater prosthetic flexibility. Now new reliable long-term data on the clinical success of two-piece ceramic implants has made a fundamental contribution to evidence-based implantology, heralding a paradigm shift in the scientific discussion about ceramic implant systems. Many readers will be learning about this evidence for the first time in this issue of **ceramic implants**.

Among the new generation of ceramics in dentistry, zirconia presents outstanding aesthetic characteristics, a low propensity for plaque adhesion around the implant surface, excellent biocompatibility, and good osseointegration, muco-integration and biomechanics. In addition, zirconia implants have characteristics similar to those of titanium implants, and zirconia is frequently used in implant prostheses with pleasing results.

This issue of **ceramic implants** provides reports on the advantages of ceramic implants and a scientific update on the topic, including a worldwide survey by the European Society for Ceramic Implantology, conducted to gain a deeper insight into the daily use of ceramic implants. The survey findings provide valuable information for the further development of ceramic implants and make an important contribution to their reliable use—ultimately for the safety of patients. It is clear that

the work being done in dental clinics and continuing education regarding the use of ceramic implants are contributing greatly to this development. This issue of **ceramic implants** is good testimony to that: numerous research articles, case reports, reviews and upcoming events testify to an extraordinarily active community.

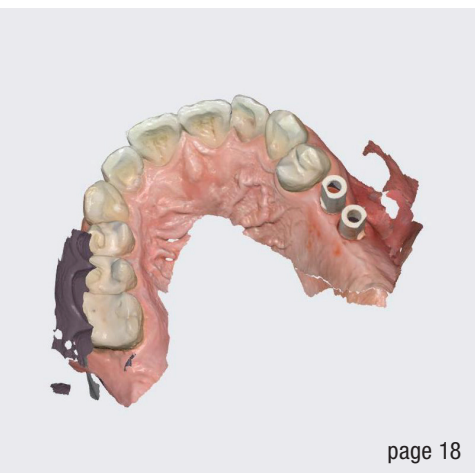
Over the past two years, continuing dental education in the form of in-person events has practically come to a standstill—not only in Europe but also beyond. Many of the great events in the dental world, like the International Society of Metal Free Implantology's annual conference, EuroPerio and the European Association for Osseointegration's annual scientific meeting, had to be called off. In-person events are slowly resuming, and the opportunity these offer for exchange among peers and socialising is more appreciated than ever.

Like the title of this editorial implies, we have something new to announce. There is a new dynamic duo in implant dentistry publishing: Timo Krause, OEMUS MEDIA AG product manager, and I are excited to have teamed up to write articles for our magazine. These are aimed at providing our readers with a comprehensive overview which reflects the diversity of ceramic implant initiatives, and we hope to live up to this objective in this new issue of **ceramic implants**.

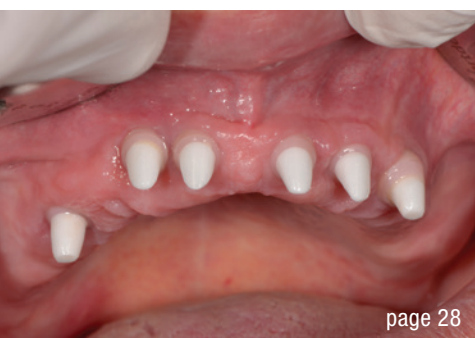Stay up to date with us by following us on LinkedIn.

Sincerely wishing you an enjoyable read,


Janine Conzato
Managing editor



page 18

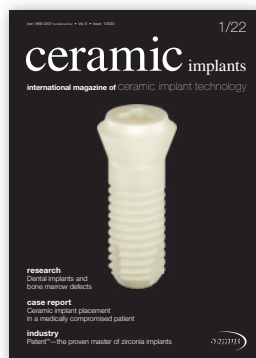

page 28



page 34

Cover image courtesy of
Zircon Medical Management AG
www.zircon-medical.com



editorial

A new year, new faces and new long-term data 03
Janine Conzato

research

Dental implants and bone marrow defects 06
Dr Johann Lechner

Ceramic dental implants in clinical use 12
Dr Jens Tartsch

case report

Ceramic implant placement in a medically compromised patient 14
Dr Alexandr Bortsov

Single-tooth replacement with ceramic implants 18
Professors Curd Bollen & Paul Tipton

Biological and osseointegration capabilities of a zirconia implant 24
Dr Saurabh Gupta

Rehabilitation of the maxilla with implant-supported zirconia bars 28
Dr Witalij Kolbe

interview

Ceramic implants account for 50% of implants we use 30
Prof. Michael Gahlert & Dr Stefan Röhling

industry

Patent™—the proven master of zirconia implants 34
Zircon Medical Management

Second-generation ceramic implant 36
bredent medical

events

46

news

manufacturer news 42

news 48

about the publisher

imprint 50

NovoMatrix™ Reconstructive Tissue Matrix – the next generation material

NovoMatrix™ Reconstructive Tissue Matrix is an acellular dermal matrix derived from porcine tissue intended for soft tissue applications. The proprietary LifeCell™ tissue processing is designed to maintain the biomechanical integrity of the tissue, which is critical to support tissue regeneration.

Indications

- Localized gingival augmentation to increase keratinized tissue (KT) around teeth and implants
- Alveolar ridge reconstruction for prosthetic treatment
- Guided tissue regeneration procedures in recession defects for root coverage

www.biohorizonscamlog.com

Product features

- Consistent thickness (1 mm)
- Pre-hydrated
- Controlled source

Before use, physicians should review all risk information, which can be found in the Instructions for Use attached to the packaging of each NovoMatrix™ Reconstructive Tissue Matrix graft. NovoMatrix™ is a trademark of LifeCell™ Corporation, an Allergan affiliate. ©BioHorizons. All rights reserved. Not all products are available in all countries.



MinerOss™ A The allograft for outstandingly fast bone remodeling [1]

The scientific evidence shows that allografts are the second best option to patient's own bone compared to other bone substitutes. [2]

Benefits of MinerOss™ A human bone substitute [1, 3–5]

- Optimal osteoconductivity
- Fast graft incorporation
- Complete remodeling potential

www.biohorizonscamlog.com



- [1] Wen et al. J. Periodont. 2019, 1, 734.
 [2] Schmitt et al. Clin Oral Implants Res. 2013, 24, 576.
 [3] Kloss et al. Clin Oral Implants Res. 2018, 29, 1163.
 [4] Solakoglu et al. Clin Implant Dent Relat Res. 2019, 21, 1002-1016.
 [5] Kloss et al. Clin Case Rep. 2020, 8, 5.
 References available at: www.biohorizonscamlog.com/references_mineross



MinerOss™ A is a trademark of BioHorizons®. BioHorizons® is a registered trademark of BioHorizons. ©BioHorizons. All rights reserved. Not all products are available in all countries.



Dental implants and bone marrow defects

Evaluation of bone quality by intra-oral ultrasonography

Dr Johann Lechner, Germany

Introduction

In ceramic implants—*international magazine of ceramic implant technology issue 2/2021*, I discussed

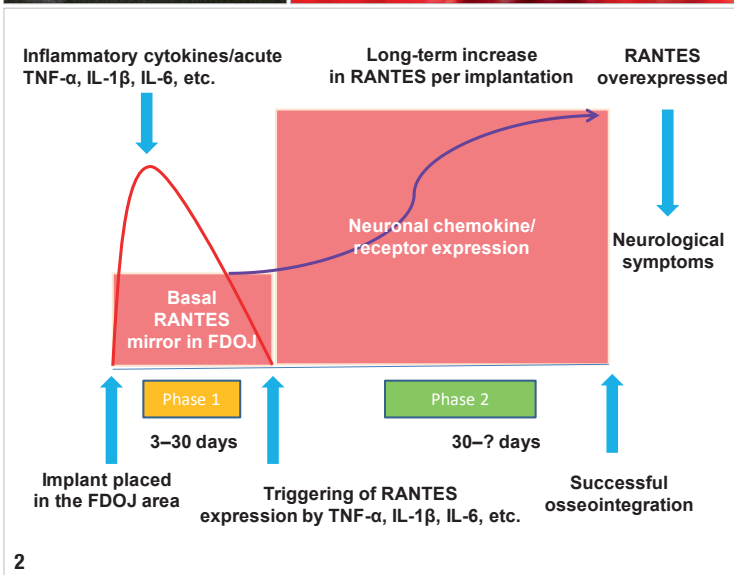
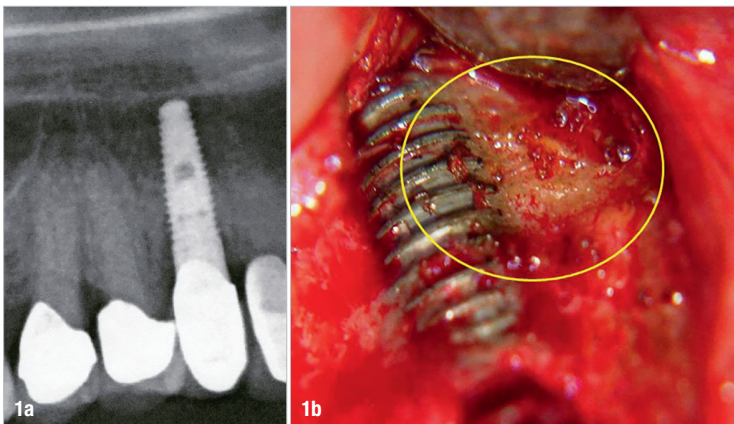
the objective validation of bone quality before implant placement in light of establishing whether the level of mineralisation in the jawbone is sufficient to osseointegrate an implant without any issues and to keep it secure in a stable bone bed for a long time or whether the implant is connected to a bone marrow defect.¹ In this current article, I would like to consider two questions relevant to the situation after implant insertion:

- Was the implant inserted into poorly healed bone?
- Is implant failure directly associated with incomplete wound healing of the implant site and a bone marrow defect around the implant?

How to forecast the success of dental implants

The measurement of the quantitative ultrasonic transmission velocity (UTV) has been established as an innovative, objective, valid and reliable method for repeated, non-invasive measurements of bone quality before dental implantation.⁵ The intra-individual correlation of the UTV values of the maxillary and mandibular lateral regions makes the data easy to interpret. The use of a small UTV device in this study enabled the recording of intra-oral UTV values in a large and heterogeneous patient population. Assessment of alveolar ridge UTV could provide a method for identifying critical bone quality before implant insertion or for monitoring bone healing (mineralisation) after augmentation procedures.⁶

The main advantages of ultrasonic measurement are that it is non-ionising, non-invasive, tolerable and available at relatively low costs. Furthermore, the examination is not a complicated process and can be easily performed by clinicians.^{7,8} The new technology of trans-alveolar ultrasonic (TAU) measurement by CaviTAU can reliably identify regions of low mineralisation density in bone marrow cavities with signs of bone marrow defects and collateral chronic ischaemic inflammation.^{9,10}



Figs. 1a & b: Radiograph of an implant. No sign of inflammation in the jawbone (a). Fatty degenerative osteolysis directly attached to the implant and thus not detectable by radiograph (b). **Fig. 2:** This figure shows schematically the sequence of cytokine expression after wound setting by insertion of an implant into a bone area that is already preloaded with chronic inflammation of fatty degenerative bone marrow.

Implant insertion and bone marrow defects

There is no doubt that dental implantology has achieved a very high reliability and success rate in recent years. Despite this, there is increasing evidence that, in addition to the success of long-term stability, other medical assessment criteria should also be part of the discussion. Further questions on implant insertion arise, such as:

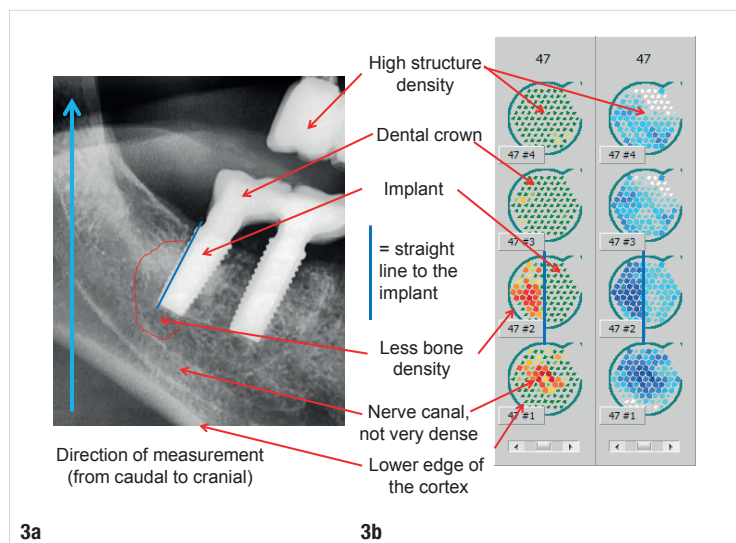
- Are good stability and loading capacity of an implant the only assessment criteria for implant success?
- Is there also undetected silent inflammation arising from fatty degenerative bone marrow defects (fatty degenerative osteonecrosis of the jawbone; FDOJ)?

A clinical case gives the answer to these questions: the panoramic radiograph showed that the implant had healed inconspicuously, hiding that it was directly attached to fatty degenerative morphology (Fig. 1). The overexpression of chemokine RANTES (CCL5) in regions of reduced bone density surrounding implants, as presented in the following case reports, has been described in detail. These FDOJ areas persist as silent or subclinical inflammation without the typical signs of acute inflammation.

In bone resorption in periodontitis and peri-implantitis, the acute cytokines tumour necrosis factor- α (TNF- α) and interleukin-6 (IL-6) are central to the destructive inflammatory process. A possible titanium intolerance provokes further expression of TNF- α and IL-1 β via released titanium particles and increased bone resorption.³

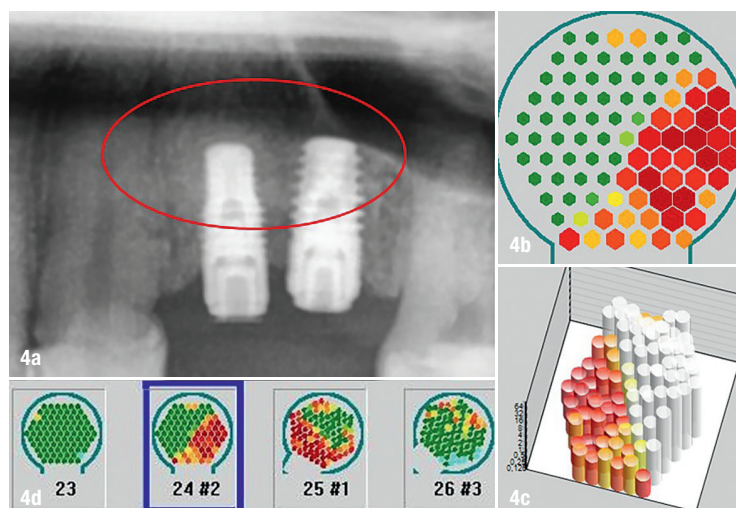
However, beyond this easily accessible therapeutic level, there are other bone resorption processes in the deeper layers of the bone marrow known as bone marrow defects or marrow oedema. This FDOJ morphologically shows bone softening, and TNF- α and IL-6 are far below the levels found in the healthy medullary cavity. In contrast, there is an up to 35-fold overexpression of RANTES.¹¹ With this chronic RANTES signal transduction, FDOJ appears to represent a unique pattern of inflammation with osteolysis in the body.

Local periodontal production of inflammatory cytokines such as TNF- α and IL-1 β or IL-6 dysregulates regulatory and compensatory mechanisms that prevent the formation of implant-related FDOJ in the bone marrow. Arising from an intramedullary overexpression of RANTES, this phenomenon seems to be more widespread than originally thought. However, surgical removal of FDOJ areas can stop the induction of RANTES signalling pathways and thus inhibit the progression of associated symptoms.¹¹

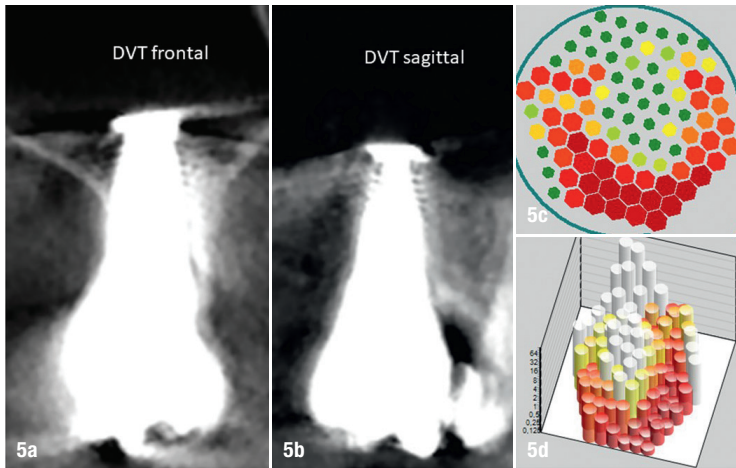


Figs. 3a & b: Two ceramic implants in areas #46 and 47 in an unremarkable radiograph (a). CaviTAU measurement in four vertical comparison steps (b).

An implant may be placed in an ischaemic area of subclinical FDOJ because of the radiographically inconspicuous FDOJ morphology and the lack of alternative methods for measuring bone density. Perala et al. demonstrated the induction of TNF- α *in vitro* after co-incubation of native implant material, which ensures that immunogenic particles are released from the materials.¹² With regard to cytokine expression in the context of an implant and the associated phases of healing, analysis during different stages of implantation reveals several new phases of cytokine-triggered signalling pathways. Acute wounding

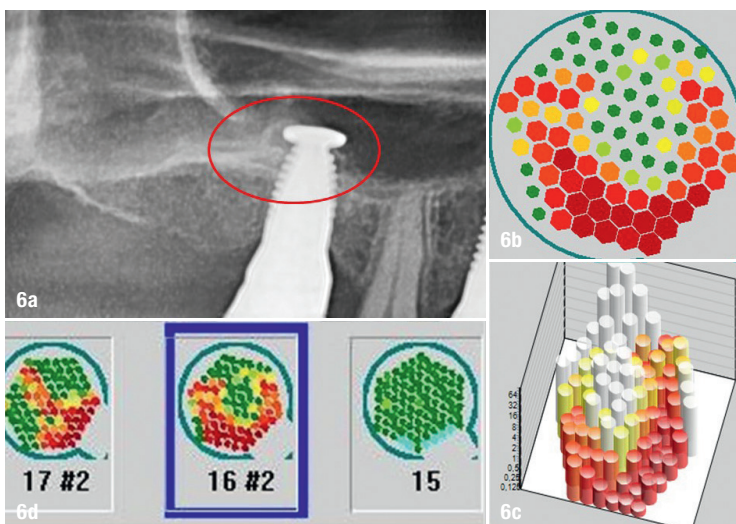


Figs. 4a-d: Radiograph showing implants in areas #24 and 25 and inconspicuous bone around the implants (a). CaviTAU image clearly displaying the straight line where the implant (in green) comes into contact with the obviously osteolytic jawbone in red (b). The white columns show the implant, and the red columns indicate the diminished bone density of the directly adjacent jawbone (c). In contrast to the radiograph, the measurement by CaviTAU of the bone density adjacent to the implants displays diminished bone density in red (d).



Figs. 5a–d: Frontal and sagittal CBCT images of implant #16. No conspicuous signs of inflammation (**a** & **b**). CaviTAU image of the apical part of the implant in green (green = hard substance), surrounded by suspected osteolytic or osteonecrotic areas in red (red = low bone density); **c**; CaviTAU image of the hard substance of the implant in white, surrounded by suspected osteolytic or osteonecrotic areas in red (**d**).

initiated by implant placement, which induces the release of acute cytokines through surgical trauma, provokes inflammatory cascades of TNF- α , IL-6 and IL-1 β expression. TNF- α expression provokes increased secretion of RANTES in the bone surrounding the implant in the medium to long term (Fig. 2).^{13–16} The apparent clinical stability of the implant and the radiographic inconspicuousness of the implant lead to the misdiagnosis of an apparently inflammation-free osseointegration.



Figs. 6a–d: Radiograph of the ceramic implant placed about nine months before. The radiograph did not give any indication of a possible cause of the atypical facial pain since insertion (**a**). CaviTAU image indicating a relatively high degree of bone loss around the implant in red (**b**). CaviTAU image of the implant in white and the surrounding diminished bone density in red (**c**). According to the CaviTAU measurement, the conspicuous areas with possible osteolysis indicated in red are towards the apical area of implant #16 with clear osteolysis (**d**).

CaviTAU detects focal inflammation areas around implants that cannot be identified by radiographs

CaviTAU solves the problem by providing reliable ultrasonic imaging of the circumscribed bone density. The measurement is divided into four vertical comparison steps, demonstrated here with reference to Figure 3:

- *Step 1:* The bottom right measurement shows caudal visualisation of the lower cortical margin of the lower jaw, as well as the less dense areas of the infra-alveolar nerve canal in red and dark blue.
- *Step 2:* The measurement shows the dense implant structure in green or light blue and white with a clearly straight delimitation of the distally located red or dark blue indicating reduced mineralisation density and suspected osteolysis.
- *Steps 3 & 4:* In a cranial and vertical direction, the scan shows dense structures in green or white and areas of suspected minor osteolysis or peri-implantitis in light blue.

Case reports on chronic inflammation around implants and their visualisation

In the following case reports, the reduced bone densities shown by CaviTAU—where the practice procedures allowed—were confirmed with the postoperative findings of RANTES/CCL5 expression measured by the multiplex procedure and light microscopy. Generally speaking, panoramic radiographs do not show findings of reduced bone density and are not sufficient for diagnosis of osteolysis.¹⁷ The focus of these case reports is the metrological evaluation of bone density with CaviTAU used from a diagnostic and a preventive perspective.

Case 1

The 35-year-old female patient came to our practice with complaints of pressure in areas #24 and 25, into which two titanium implants had been placed. Previously, after several root canal therapies and unsuccessful apicectomies, the teeth had finally been extracted and replaced with titanium implants. On the CBCT scan, the implanting dentist could not see any abnormalities at implants #24 and 25 that could explain the pressure complaints and pulling pain in the implant area. As the patient did not wish to retain the two implants owing to this chronic feeling of pain, she came to our clinic with the request for a more detailed ultrasonic diagnosis of her bone situation in the region of implants #24 and 25.

We performed a measurement of the bone density in the region of implants #24 and 25 with CaviTAU. The

“The use of a small UTV device in this study enabled the recording of intra-oral UTV values in a large and heterogeneous patient population.”

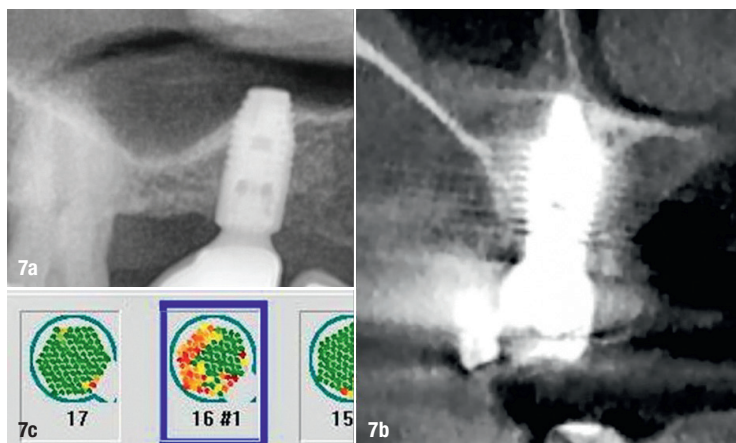
healthy neighbouring teeth, teeth #23 and 26, were also measured, as recommended for a lateral comparison measurement (Fig. 4). The measurement showed the teeth #23 and 26 in green, indicating dense structure. The extensive red area of osteolytic jawbone with clear demarcation of the hard implant proved the patient's complaint pattern. Both implants had been placed in a bone area that had not healed properly, and the remaining FDOJ had led to the patient's neuralgic complaint pattern after implantation.¹⁸ These FDOJ areas remain as silent or subclinical inflammation without the typical signs of an acute inflammation.¹⁹

This case demonstrates the importance of the question of whether the implants have been inserted into healthy bone. With modern digital radiographic technology, we have a means of digital determination of the bone quantity, that is, whether the bone volume is sufficient for implantation, but no means of digital determination of bone quality, that is, whether the bone is healthy enough for implantation.

The implanting dentist had already tried antibiotics for several weeks without success. Therefore, the only way out was to remove the implants, debride the osteolytic areas and build up healthy bone to enable further implantation in the patient. The financial expenditure for the preceding implantation was thus just as high as the preceding root canal therapies and apicectomies. A quick assessment of the bone density in areas #24 and 25 employing a low-cost ultrasonic measurement with CaviTAU would have led to a considerable cost-saving and a medically safe procedure.

Case 2

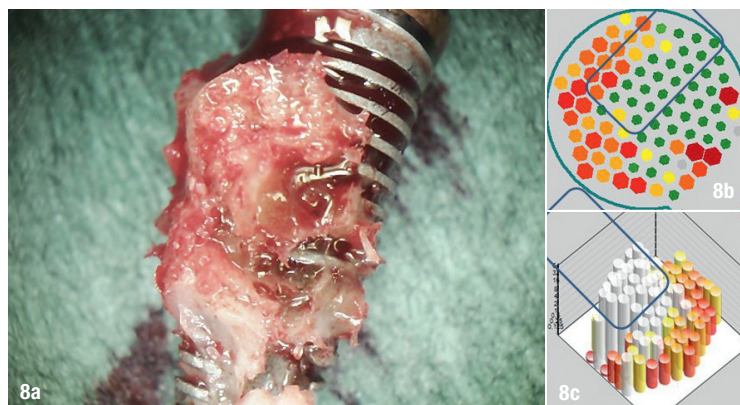
Nine months before, the 57-year-old female patient had received a ceramic implant simultaneously with a sinus lift immediately after extraction of her endodontically treated tooth #16. With the implant fixed, she was not sensitive to biting, but had suffered from chronic pain in the right upper jaw with no apparent cause for the last six months.



Figs. 7a–c: Radiograph showing inconspicuous bone tissue around implant #16 (a). The CBCT scan should show the degree of mineralisation of the peri-implant bone environment; however, the hardening artefacts caused by the implant prevented this visualisation (b). CaviTAU image clearly showing red around the implant, indicating an area of reduced mineralisation density (c).

The main problem in practice related to radiographic imaging in implantology is that typical hardening artefacts occur in CBCT scans, caused by ceramic implants in particular but also by titanium implants. The regions between the implants and the implant–bone interface cannot be visually reconstructed correctly for technical reasons (Figs. 5 & 6).⁴

Histology was performed of a 0.5 cm sample material of the apical tissue around implant #16 with an older scarring apical granuloma with foreign-body granulomas around partially birefringent foreign material. The sample material consisted predominantly of fibrous connective tissue with foreign-body giant cells partly around birefringent foreign material. Only minimal chronic inflammatory cell infiltration was found.



Figs. 8a–c: Post-op photograph of the bone situation around the implant clearly showing the FDOJ tissue attached to the implant (a). Corresponding to this is the 2D view of the hard implant shown in green in CaviTAU with a rectangular outline of the implant and a visualisation of the osteolytic dissolved tissue around the implant bed in red (b). 3D representation of the osteolytic dissolved tissue around the implant bed in red with clear borderlines to the implant, shown in white (c).