

DENTAL TRIBUNE

— The World's Dental Newspaper · Middle East & Africa Edition —

PUBLISHED IN DUBAI

APRIL, 2012

No. 3+4 Vol. 10




News
‘Healthy’ food gives you hay fever

Page 3



Media CME
Intraoral impression-taking

Page 6



Dental Cafe
Signs of Depression

Page 10

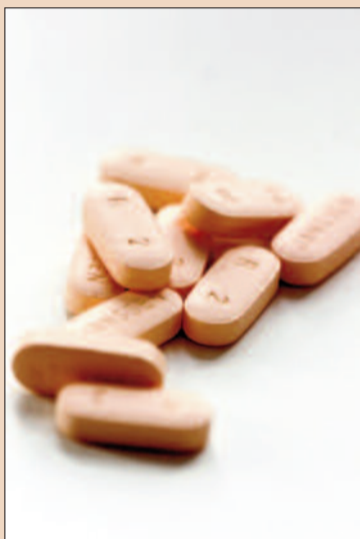J&J slapped with \$1.1bn fine for deceptive risperdal advertising

Johnson & Johnson has been hit with a \$1.1 billion fine after an Arkansas judge found the drugmaker guilty of deceptively marketing the antipsychotic Risperdal in the US State.

The ruling follows an earlier jury verdict that concluded the company and its Janssen unit had engaged in “false and deceptive acts” when it sent marketing letters to more than 6,000 Arkansas doctors in 2003 claiming Risperdal’s superior safety compared with competing drugs. The state also argued false statements were made about the drug’s risks and side effects and that J&J marketed the drug for “unapproved uses, including various symptoms in children and the elderly” despite authorities banning such actions.

According to Arkansas Attorney General Dustin McDaniel, the jury concluded that J&J had “lied to patients and doctors because they cared more about profits than people” and found the company had violated consumer-protection laws.

This is the third lawsuit that has hit J&J’s back pocket regarding claims the drugmaker



duped Medicaid programmes to overspend on the drug through misleading advertising and downplaying the drug’s risks. A South Carolina case fined J&J \$327 million, while the company was hit with a \$258 million penalty in Louisiana. The company has appealed both these rulings. Meanwhile, a settlement in Texas saw the company pay out \$158 million to resolve claims of illegal marketing. It is expected J&J will also appeal the Arkansas ruling.

A spokeswoman for J&J told Bloomberg: “It is our position that an individual state should not penalise a pharmaceutical company for using an FDA-approved package insert or decide for itself whether a company complies with FDA rules.”

The State will also seek damages over the misleading statements in the letter as well as penalties for almost 20,000 sales calls, which were allegedly deceptive as well. Sales of Risperdal peaked in 2007 at \$4.5 billion before losing patent protection, with the drug bringing in just \$527 million in 2010. **DT**

6th Group

1 - Year Program in Implant Dentistry

Oral Implantology

A series of advanced seminars leading to the European title as “CERTIFIED ORAL IMPLANTOLOGIST”
(European Association of Implantologists EDI and University of Cologne)

Program Chairman: Peter A. Ehrl Dr.med. Dr.med.dent. | Program Co-Chairman: Spyros Karatzas DDS, MS, DMD

INTERNATIONAL FACULTY:	GREEK FACULTY:	PERIOD 2012
Peter A. Ehrl Dr.med. Dr.med.dent. Dentist, Oral Surgeon, Specialist Implantology, Berlin, Germany Andrea Grandoch Dr. med. Ass. Prof. Anatomy University of Cologne, Germany Detlef Hildebrand Dr.med.dent. Dentist, Dental Technician, Specialist Implantology, Berlin, Germany Susanne Nahles Assistant Prof. at the Dept. of Oral and Maxillofacial Surgery, Charité, Berlin, Germany Uwe Sander Dr. med. Maxillofacial Surgeon, Berlin, Germany Istvan Urban DMD, MD Assistant Professor in Implant Dentistry Loma Linda University, School of Dentistry, USA Private Practice, Budapest, Hungary Dietmar Weng Dr.med.dent. Dentist, Dental Technician, Specialist Implantology, Starnberg, Germany	George Goumenos DDS, MS DrOdont, Periodontist, Athens, Greece Spyros Karatzas DDS, MS, DMD Periodontist, Patras, Greece Nick Krompas General Dentist, Athens, Greece Stratis Papazoglou DDS, MS, PhD Assistant Professor University of Athens, Greece Stavros Pelekanos Dr.Med. Dent Assistant Professor of Prosthodontics, University of Athens, Greece Nikos Raptis DDS Prosthodontist, Athens, Greece Iliia Roussou DDS, MS, Dr Dent Lecturer, Dept. of Prosthodontics, University of Athens, Greece Ioannis Fakitsas DDS DrOdont, Maxillofacial Surgeon, Athens, Greece	Location: Athens - Berlin Total duration of lessons: 16 days of clinical education. <ul style="list-style-type: none"> • Implantology from A - Z • Surgery to Prosthodontics • Soft and Hard Tissue • Treatment of Complex Cases • Systems for Everyday's Office • 4 Live Surgeries • 8 Hands-on & Workshops • 40 ECTS (Credit points according to the European Credit Transfer System)
		Session I May 3 - 6, 2012 Athens, Greece Session II July 12 - 15, 2012 Athens, Greece Session III October 18 - 21, 2012 Athens, Greece Session IV February 14 - 17, 2013 Berlin, Germany

Program Fee 8.100€
LIMITED NUMBER OF PARTICIPANTS

SPONSORS:

For Registration & More Information:
Tel: +30 210 21 32 084 Fax: +30 210 22 22 785 E-mail: middleeast@omnipress.gr
website: www.omnipress.gr, www.omnicongresses.gr

Visit us at
www.promedica.de

PROMEDICA

Highest quality made in Germany

- high quality glass ionomer cements
- first class composites
- innovative compomers
- modern bonding systems
- materials for long-term prophylaxis
- temporary solutions
- bleaching products ...

All our products convince by

- excellent physical properties
- perfect aesthetical results

Glass ionomer filling cement

- perfectly packable consistency
- excellent durable aesthetics
- also available as application capsules

Light-curing nano-ceram composite

- highly esthetic and biocompatible
- universal for all cavity classes
- comfortable handling, easy modellation
- also available as flowable version

Dental desensitising varnish

- treatment of hypersensitive dentine
- fast desensitisation
- fluoride release
- easy and fast application

PROMEDICA Dental Material GmbH
phone: +49 43 21/5 41 73 · fax +49 43 21/5 19 08 · Internet: www.promedica.de · eMail: info@promedica.de

Contemporary Endodontics and Complex Restorative Treatment Planning Course

Date: May 4-5, 2012
Fees: Dhs. 1500.00
10 DHA C.M.E.

Dr. Samira Al-Salehi

BDS, MFDS (UK), FDS (Rest. Dent) RCPS, PhD (Sheffield), FHEA (UK)

Dr. Samira Al-Salehi is Director of the Endodontic and AEGD programs at European University College (EUC), Dubai. She is

also a Consultant in Restorative Dentistry (Dubai Health Authority) since 1 May 2011. Endodontics at EUC is a three year higher specialty training program. The AEGD program provides advanced general dentistry training to improve the skill base of dentists who wish to work in primary care and/or specialize in one of the three year specialty programs offered at NAU.

Dr. Samira graduated from Manchester University, UK and practiced general dentistry for a number of years before becoming a Lecturer/Specialist Registrar in Restorative Dentistry at Sheffield University. In January 2007, Dr. Samira was awarded CCST (UK) in Restorative Dentistry. She is on the UK specialist lists in Prosthodontics, Endodontics, Periodontics and Restora-

tive Dentistry. Dr. Samira is a member of the British Endodontic Society, British Society of Restorative Dentistry and a Fellow of the Royal College of Physicians & Surgeons of Glasgow.

Dr. Samira is an expert in the field of Dental Bleaching and was awarded the degree of PhD from Sheffield University in September 2007. She has a number of publications in top ranked refereed journals. She also has a vast teaching experience gained from working at three leading UK dental schools; Sheffield, The

London and Manchester. In recognition of her teaching experience she was awarded FHEA (Fellow of the Higher Education Academy, UK) in 2008. From September 2008 until 30 April 2011 Dr. Samira worked as Associate Professor and Consultant in Restorative Dentistry at Manchester University Dental School, UK. Her main role was delivery of Endodontics to the three year MRD postgraduate students and as well as providing an Endodontic service for referred patients from general dental practitioners.

AD

EUROPEAN UNIVERSITY COLLEGE
(formerly NICOLAS & ASP UNIVERSITY COLLEGE)

الكلية الأوروبية الجامعية
(كلية نيقولا وآسب الجامعية سابقا)

FIRST INTERNATIONAL POSTGRADUATE DENTAL INSTITUTION IN THE REGION

"All programs accredited by UAE Ministry of Higher Education & Scientific Research"

3-YEAR MASTER DEGREE IN ENDODONTICS



Dr. Samira Kathryn Al-Salehi, BDS, FDS (Rest Dent), RCPS (Glasgow), PhD (Sheffield), FHEA (UK)

Program Director
Associate Professor of Endodontics
European University College

Overview

The overall Master degree Program goal is to provide the student with in-depth education and training in diagnosis, treatment planning and provision of comprehensive endodontic dental services. The Program outcome includes a critically thinking clinician who is ethical, socially aware and capable of delivering high quality endodontics services to a socio-economically diverse population of patients.

Program Length

The program consists of 3 years of full time study of which about 70% is dedicated to clinical activities. The Program is structured in four main categories: 1) theoretical training, 2) pre-clinical (laboratory) training, 3) clinical training, and 4) research. The research aspect of the Program provides the foundational knowledge to allow the student to do the following: 1) critically evaluate literature and conduct research, 2) become familiar with research design and statistical analysis, and 3) formulate a proposal, carry out a research project, analyze the results, and write the results in a publishable format.



3-YEAR MASTER DEGREE IN PEDIATRIC DENTISTRY

Mark M. Roseman, DDS, CAGS

Acting Director & Associate Professor of Pediatric Dentistry
European University College
Diplomate American Board of Pediatric Dentistry

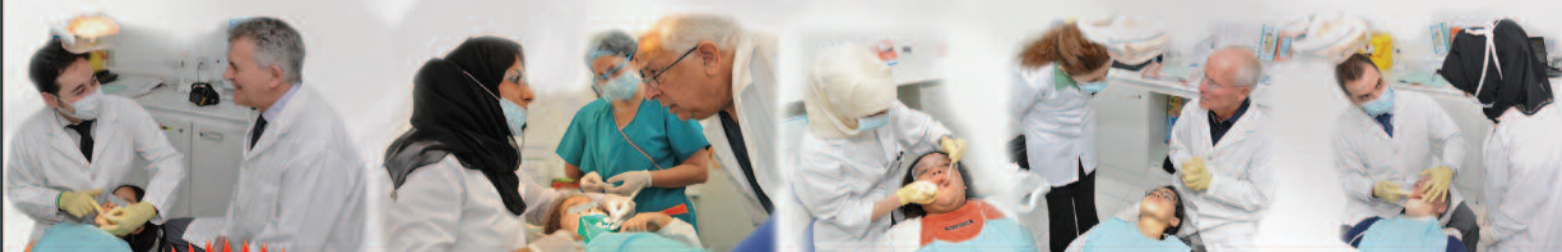

Overview

Pediatric Dentistry is an age dependent specialty and the Master degree in Pediatric Dentistry Program provides training in both primary and comprehensive preventive and therapeutic oral health care for infants and children through adolescence, including children with special health care needs. The program will provide the student with sufficient education and training for diagnosis, treatment planning and clinical dental care in younger and special needs patients. In addition, graduates will demonstrate critical thinking and decision making, and life-long learning skills.

Program Length

The program consists of 3 years of full time study of which about 70% is dedicated to clinical activities. The Program is structured in four main categories: 1) theoretical training, 2) pre-clinical (laboratory) training, 3) clinical training, and 4) research. The research aspect of the Program provides the foundational knowledge to allow the student to do the following: 1) critically evaluate literature and conduct research, 2) become familiar with research design and statistical analysis, and 3) formulate a proposal, carry out a research project, analyze the results, and write the results in a publishable format.



APPLY NOW

Highly Qualified Euro-American Faculty
Bringing World - Class Education To The Emirates

2012 Admissions Currently Open

+97143624784 • candidate@nicolasasp.ae • www.dubai-postgraduate.com



This course is designed for general dentist and those who wish to specialize in Endodontics as there is a focus on treatment planning of complex restorative cases and in depth coverage of many aspects of Endodontics.

The two day course covers the importance of accurate endodontic diagnosis and treatment planning of endodontic and complex restorative cases. A hands-on NiTi rotary session will be delivered as part of Day 1 as well as a complex Restorative treatment planning workshop on day 2.

- Systematic methods of case assessment
- Flare canals with NiTi rotaries
- Application of strategies to minimize the risks of rotary file separation
- Description and application of the principles of apical gauging
- Application of the principles of predictable ISO and tapered cone fit
- Understanding the importance of careful treatment planning in complex restorative cases
- Understanding the importance of controlling occlusion in full mouth rehabilitation cases

DENTAL TRIBUNE

The World's Dental Newspaper - Middle East & Africa Edition

Published by Education Zone

in licence of Dental Tribune International GmbH

© 2012, Dental Tribune International GmbH. All rights reserved.

Dental Tribune makes every effort to report clinical information and manufacturer's product news accurately, but cannot assume responsibility for the validity of product claims, or for typographical errors. The publishers also do not assume responsibility for product names or claims, or statements made by advertisers. Opinions expressed by authors are their own and may not reflect those of Dental Tribune International.

Editorial Board

Prof. Abdullah Al-Shammari, Restorative Dentistry, KSA
Prof. Hussain F. Al Huwaizi, Endodontics, Iraq
Prof. Samar Burgan, Oral Medicine, Jordan
Dr. Abdel Salam Al Askary, Implantology, Egypt
Dr. Talal Al-Harbi, Orthodontist, Qatar
Dr. Mohammed H. Al Jishi, Bahrain
Dr. Lara Bakaeen, Prosthodontist, Jordan
Dr. Aisha Sultan, Periodontist, UAE
Dr. Kamal Balaghi Mobin Aesthetics, Iran

President/CEO
Yasir Allawi y.allawi@dental-tribune.ae

Director mCME:
Dr. D. Mollova info@cappmea.com

Marketing manager
Khawla Najib khawla@dental-tribune.ae

Production manager
Hussain Alvi dentalme@dental-tribune.ae

PO Box 214592, Dubai, UAE,
Tel + 971 4 391 0257
Fax + 971 4 366 4512
www.dental-tribune.com

'Healthy' food gives you hay fever



Hay fever sufferers are more likely to have allergic reactions to fruit and veg, according to new research commissioned for National Allergy Week

It's not just airborne pollen that's set to make allergy sufferers' lives a misery this spring. If you experience hay fever, you're more likely to suffer from a similar, less well known, allergic reaction called Oral Allergy Syndrome. It's caused by your body mistaking proteins in your food for the same pollens that make you all sniffly, and reacting against them too.

As many as 40 per cent of hay fever sufferers are thought to be at risk of allergic reactions to foods with similar properties to tree and grass pollen. And surprisingly, the foods containing these are some of our healthiest diet choices. Fruit, vegetables, nuts and spices can all be culprits.

The good news, according to Lindsey McManus from Allergy UK, is that this allergic reaction is similar to most people's experience of hay fever - annoying but not particularly serious. It's not the same thing as food intoler-

ance and if you experience a serious allergic reaction to these foods, it's probably not Oral Allergy Syndrome. "It's worth being aware of the symptoms, but we definitely aren't suggesting anyone cuts some of these great food groups from their diet as there are plenty of ways you can reduce their effect so you still get all the benefits."

Symptoms and treatment

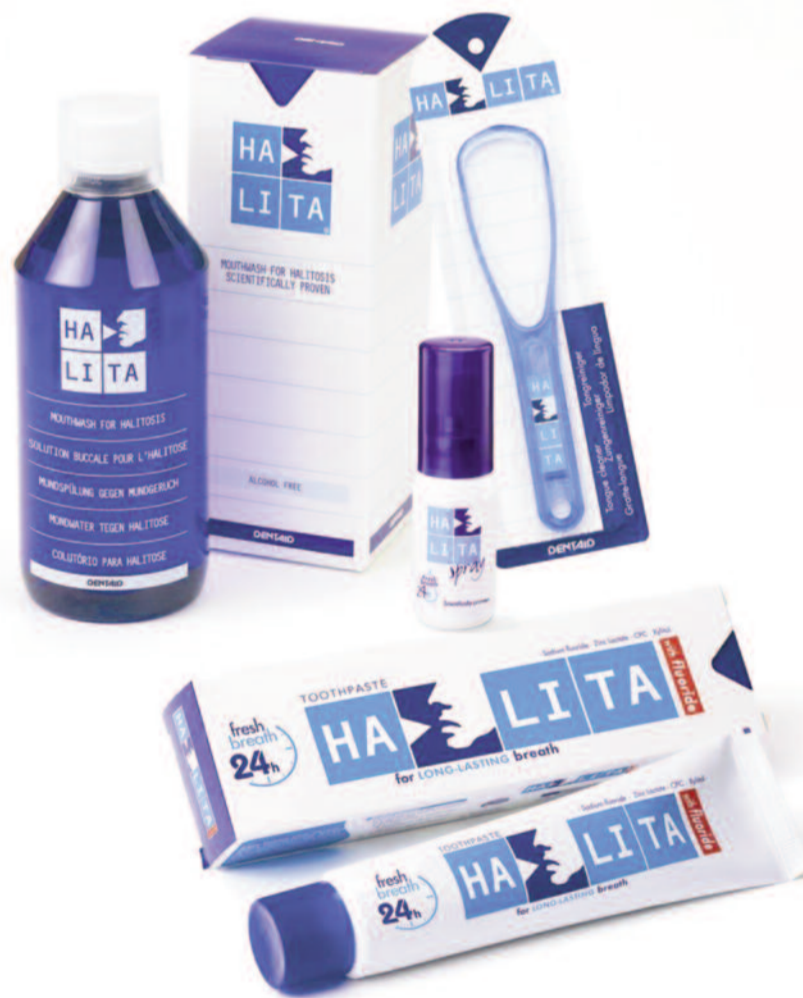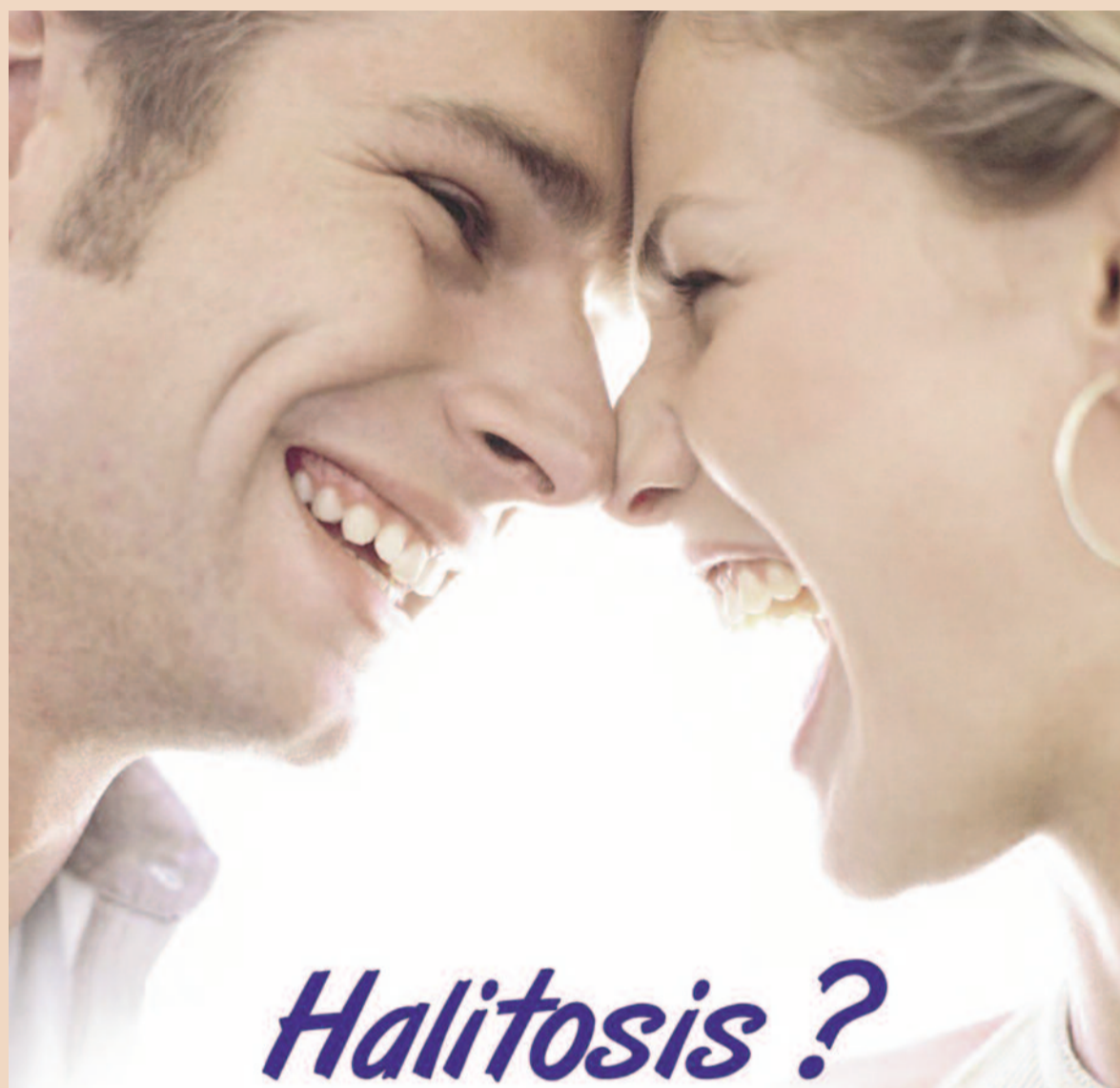Oral Allergy Syndrome usually manifests in your mouth, throat and sometimes lips, as a tingling, swelling or itching. Generally it will go away on its own in around half an hour and rinsing your mouth with cold water or drinking a warm drink often does the trick. If you're still feeling itchy, try an antihistamine. If you're very allergic, swelling can be more serious and if it affects your breathing, call an ambulance immediately. This is rare and suggests you have something more serious than Oral Allergy Syndrome. If you have an epi-pen, use it as necessary.

Foods

The worst offenders are apples, peaches, pears, cherries, carrots, raw tomatoes, melons, and celery. Nuts, particularly hazelnut, can also be the cause as can some spices such as coriander and cumin.

Prevention

You can reduce the chance of reacting to foods by cooking them so heat breaks down the proteins. Or try leaving the food for ten minutes after chopping it up. **DI**



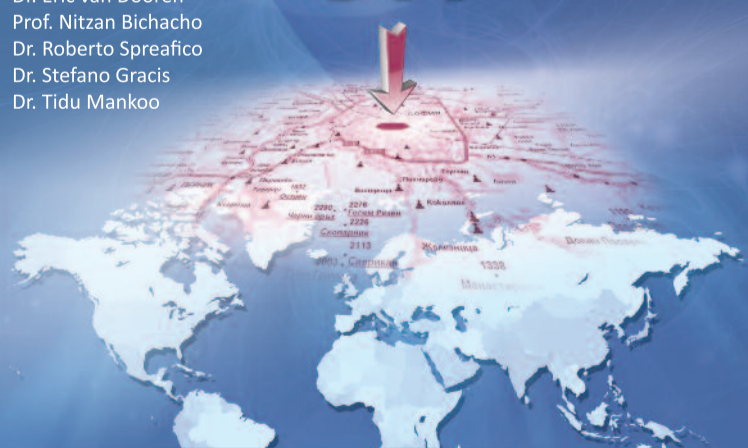Sofia Dental Meeting

27 September – 30 September 2012
Dedeman Princess Hotel, Sofia
BULGARIA

- 50 lectures
- 30 hands-on workshops
- 10 live demonstrations
- 5 discussion panels

Join the European

Esthetic Day
/September 27th/ with
Dr. Eric van Dooren
Prof. Nitzan Bichacho
Dr. Roberto Spreafico
Dr. Stefano Gracis
Dr. Tidu Mankoo



See our amazing **All - inclusive** offer and **register online** at
www.sofiadentalmeeting.com
For more details - sofiadentalmeeting@gmail.com

Exclusive Distributor : **Pharmapal Drug Store**
Tel +971 4 2675001, PO Box 37345 Dubai, United Arab Emirates www.pharmapaluae.com

Planmed Verity® selected as a finalist in the 2012 Medical Design Excellence Awards

The Planmed Verity® Extremity Scanner has been selected as a finalist in the Radiological and electromechanical devices category of the 2012 Medical Design Excellence Awards (MDEA) competition, the premier awards program for the medical technology community.

Planmed Verity® is designed to find subtle extremity fractures at the first visit to the clinic – fractures that have been the most commonly missed using only 2D radiographs. Planmed Verity Extremity Scanner is a unique solution to the problem with fast 3D imaging at the point of care. It is

intended for pre- and postoperative imaging with better resolution, patient adaptability, and significantly lower dose than full-body CTs. Unlike any other 3D imaging device, Planmed Verity also allows weight-bearing imaging of the extremities.

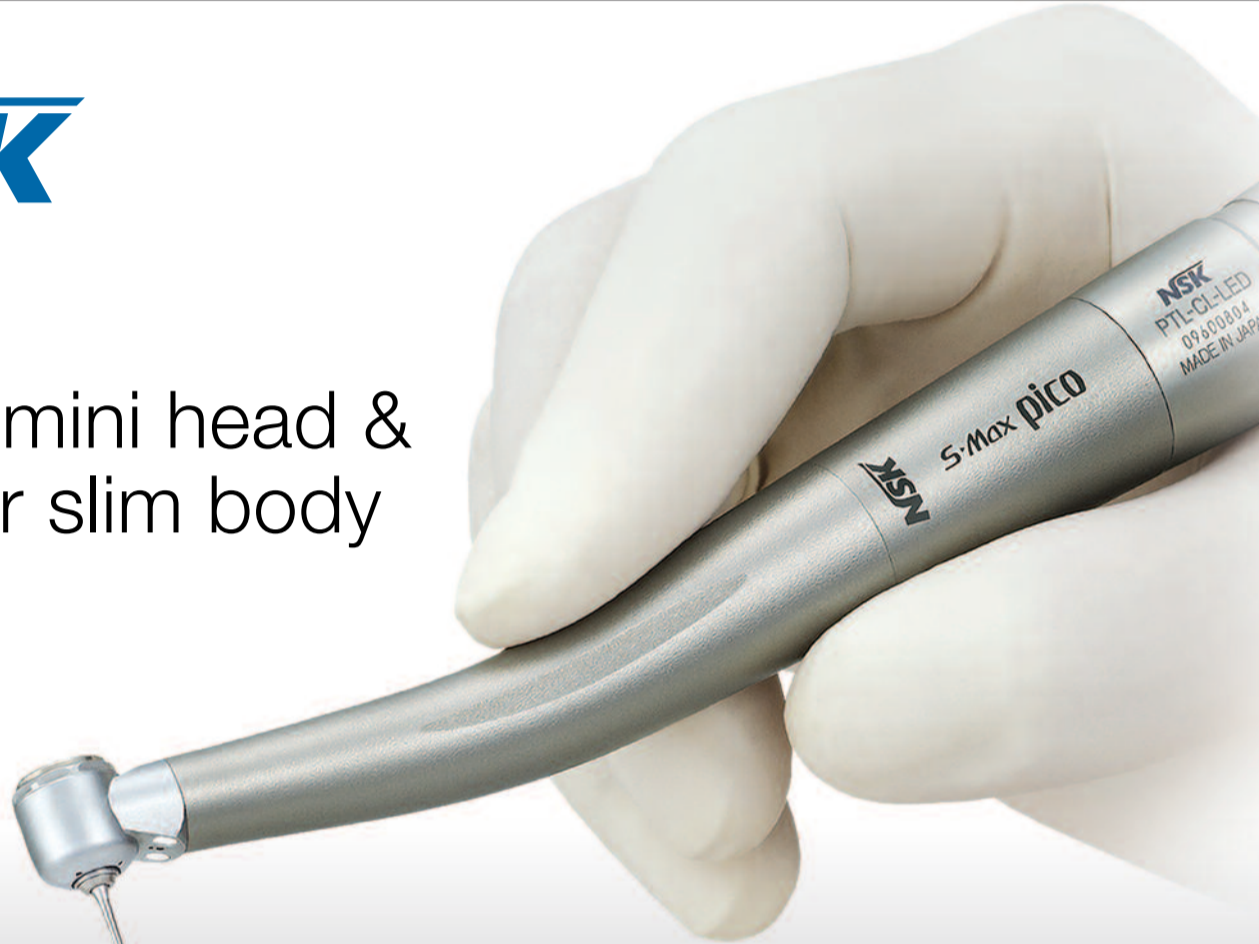As a dedicated extremity scanner, Planmed Verity adapts to the patient with anatomy-specific imaging programs, movements, and trays. Easily adjustable, soft surfaced gantry and motorized positioning trays help in finding a comfortable position for various examination proce-



AD




ultra mini head & super slim body



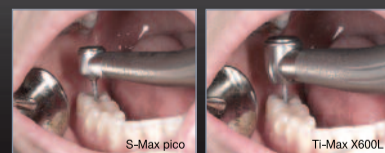new
S-Max pico

S-Max pico Series features ultra-mini head and super-slim body that has been developed specifically for delicate operations with high precision. With its greater visibility and accessibility to hard-to-treat oral areas, pico allows you to work more freely on pedodontics treatment, chamber opening, mirror-technique operation, and buccal and lingual axial reduction in the posterior areas. Pico is now a "must-have" handpiece for every practice and clinic which will be beneficial to both patients and clinicians. Use of NSK's original pico bur (or its equivalent bur) is strictly required.


The smallest head size in the world



The smallest head in dentistry allows for the biggest treatment area



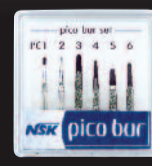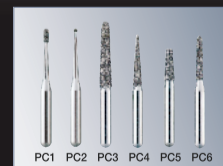
The slimmest neck in the world



Dedicated burs for S-Max pico series

Specifications of each bur

- PC1 for opening the Enamel and removing the Soft dentin
- PC2 for the preparation of small proximal caries
- PC3 for preparation of abutment tooth
- PC4 for the slice cut of proximal surface and feather-edge preparation
- PC5 for the preparation of molar occlusal surface and cavity
- PC6 for finish of the margin preparation



Standard accessory pico bur set PC1-6 (6pcs / pack)

dures. The adjustable user interfaces and efficient all-in-one workflow are also designed to maximize the operator's soothing presence for the patient.

"Its design is both welcoming and gentle with a strong personality. The look is enhanced with a tear-drop shaped imaging bore and "The Bite" in the outer rim that helps patient positioning", states Mr Tapio Laukkanen, Industrial Designer with Planmed Oy.

Judging of each year's MDEA competition is conducted by an impartial, independent, multi-disciplinary panel of jurors – comprised of a balance of clinicians, engineers, and designers – who carefully review all of the submissions and narrow them down to a select group of exceptional products in each of the 10 categories (41 finalists in total). Entries are evaluated on the basis of their design and engineering features, including innovative use of materials, user-related functions that improve healthcare delivery and change traditional medical attitudes or practices, features that provide enhanced benefits to the patient, and the ability of the product development team to overcome design and engineering challenges so that the product meets its clinical objectives.

Finalists are officially announced in the April issue of MD+DI (Medical Device and Diagnostic Industry) magazine. MDEA-winning products are honored with Bronze, Silver, or Gold-level awards in each category on May 23, 2012 in Philadelphia at a ceremony held in conjunction with the MD&M East event (www.MDMEast.com).

Additionally, Planmed Verity received the internationally renowned red dot 2012: product design award earlier this year.

Qualident Dental Laboratory

ADVANTAGES

- Metal to metal connection between screw and abutment, so superior fit of coping to the abutment
- custom designed for the individual patient
- have an anatomical shape
- reduction the number of impressions
- compatible with most implant systems
- ability to create duplicate abutment
- increase crown retention
- provide the ideal coronal preparation
- reduction of chair time

ESTHETIC ON THE TOP HYGIENIC BELOW

Computer-designed and -generated implant abutments will fundamentally change the present restorative protocols for implant dentistry. Standard implant prosthetic techniques rely on implant-level impressions and costly casting technology for component fabrication.

Implant abutments generated by computer-aided design and computer-aided manufacturing (CAD/Cam) are more precise than those created using traditional casting technology. This increased accuracy has specific application to implant dentistry,

THE CLINICAL CHALLENGE: LONG-TERM TISSUE STABILITY

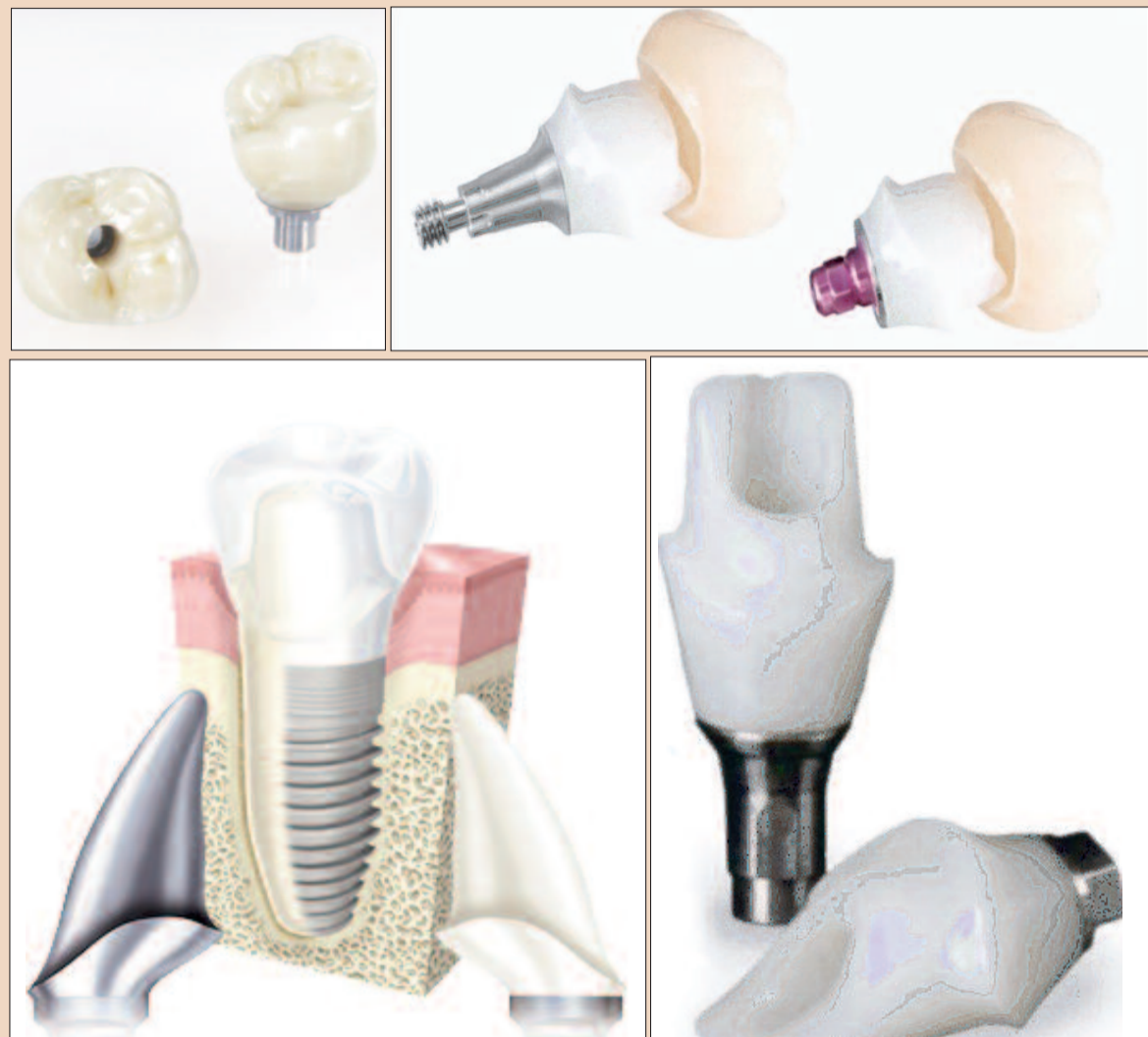When designing an abutment, the position of the implant in relation to the final crown contour, the thickness and biotype of the surrounding tissue, as well as the location within the arch must be taken into account. For ce-

ment-retained superstructures, it has been established that the location of the abutment-crown margin should always be located at, or slightly below, the gingival crest to allow for the complete removal of cement. If remnants of the cementation medium remain, potential risk of peri-implant inflammation and adverse tissue reactions increase significantly.

Research has been conducted and some products brought to market with concave transgingival sections.⁸ The concept behind this design is that creating a thicker band of gingival around the abutment will stabilize the soft tissue and mask the gray color of the titanium abutment at the gingival margin. A potential challenge with this design is that removing or replacing the abutment would likely necessitate anesthetizing of the patient. The narrow neck design could also lead to thin, potentially weak abutment wall

TITANIUM AND ZIRCONIA MATERIALS FOR CLINICAL USE.

Titanium abutments provide a biocompatible and clinically well-proven treatment option in areas where high strength is required or only limited space is available and is far superior to cast alloys. Today, zirconia is considered by many clinicians to be the material of choice for abutments. In addition to material properties that allow its application in any area of the mouth, the greatest advantage of ZrO₂ is its unrivalled support of adjacent tissue. Zirconia observably enhances tight adher-



ence of peri-implant tissues while minimizing bacterial and plaque adhesion at the same time. The key benefit of homoge-

neous materials such as titanium and zirconia is that their use eliminates material incompatibilities and corrosive phenom-

ena arising from dissimilar metal alloys and interfaces between cast and machined components. ^{DT}

QUALIDENT

Dental Laboratory

your esthetic partner




Century Plaza 101, Jumeirah 1 Beach Road, Dubai, U.A.E.,
 Tel.: +971 4 3427576, Fax: +971 4 3427016
 Muscat Tower Bldg.305. Near Qanat Al Qasba Next to Royal Crown Hotel
 Sharjah - U.A.E. P. O. Box : 24476 Tel : 06-5564322 Fax : 06-5563667
 info@qualident-online.com, www.qualident-online.com

Cyprus

28-29/09/12

INTERNATIONAL CONGRESS IN
IMPLANTOLOGY AND ESTHETIC
DENTISTRY

LECTURERS

OLIVER BRIX
Germany

DANIEL EDELHOFF
Germany

EGON EUWE
Italy

VASILIKAITASAS
Italy

ANGELO PUTIGNANO
Italy

ISTVAN URBAN
Hungary

PANOS BAZOS
Greece

GEORGE GOUMENOS
Greece

STAVROS PELEKANOS
Greece

ILIA ROUSSOU
Greece

Hilton Park Nicosia
Griva Dighenis Avenue,
Nicosia, Cyprus 1507
Web: nicosia.hilton.com

Information & Registration for Greece:
Omnipress
 Tel: +30 210 222 2637 +30 210 213 2084
 middleeast@omnipress.gr
 www.omnicongresses.gr www.omnipress.gr

ORGANIZED BY



SPONSORS







Intraoral impression-taking: Digital datasets soon to catch on everywhere

(mCME articles in Dental Tribune (always page 6) has been approved by HAAD as having educational content acceptable for (Category 1) CME credit hours. Term of approval covers issues published within one year from the distribution date (September, 2010). This (Volume/Issue) has been approved by HAAD for 2 CME credit hours.

The annual meeting of the German Society of Dentistry and Oral Medicine (DGZMK), held in conjunction with the Society for Dental Ceramics (AG Keramik), the DGZMK's professional society, is a major event that critically examines experiences with all-ceramics and CAD/CAM methods in clinics and practices. At this year's meeting, the 10th Annual Ceramic Symposium, Prof Bernd Wöstmann, Head of Prosthodontics at the University of Gießen in Germany, focused in his paper on the progress that has been made in the digitisation of intraoral impression-taking.

Naturally, perfectly fitting restorations that can be seated without further correction are every dentist's wish. This requires exact impressions of the preparation and dental arch. Quite some time ago, digitisation made inroads into this discipline, beginning in 1985 with the first digital impressions by Prof Werner Mörmann at the University of Zürich. Prof Wöstmann explained that en route to an exact restoration, creating an image of the intraoral situation either as a real or a virtual model is a very crucial step—it is only possible to produce the final restoration indirectly, whether it is an inlay or a multi-unit fixed dental prosthesis bridge (FDP).

Owing to material and haptic conditions, it is still impossible to produce a "flawless" conventional (stone) model from classical impressions with elastomeric impression material. Every virtual model produced on the basis of a classical impression is inexact, regardless of the accuracy of the scanning procedure itself. It thus makes sense to perform scanning directly in the oral cavity.

Now that producing all-ceramic restorations without CAD/CAM has become almost unthinkable, the next step has already been taken towards complete digitisation of the process from preparation to seating the prosthesis: optical scanning to create a digital, intraoral impression. In terms of clinical use, the devices—CEREC AC (Sirona), C.O.S. Lava (3M ESPE), iTero (Cadent-Straumann)—are similar, but they function according to different principles. Technically, the systems are similarly constructed, but the procedures for acquiring the 3-D datasets differ.

The acquisition unit of CEREC AC uses short-wave blue light and functions according to the principle of structured-light projection (Fig. 1). The scanning

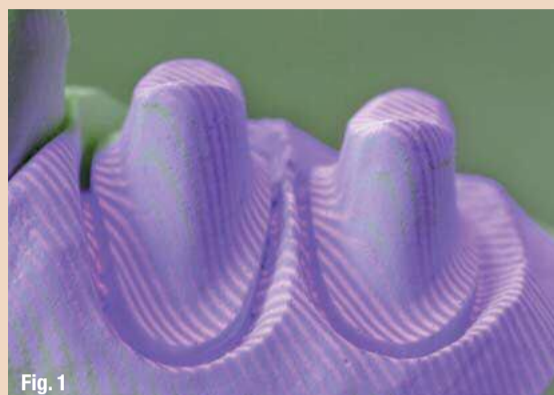


Fig. 1

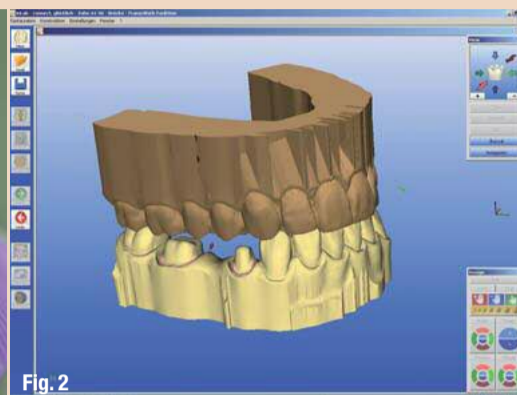


Fig. 2

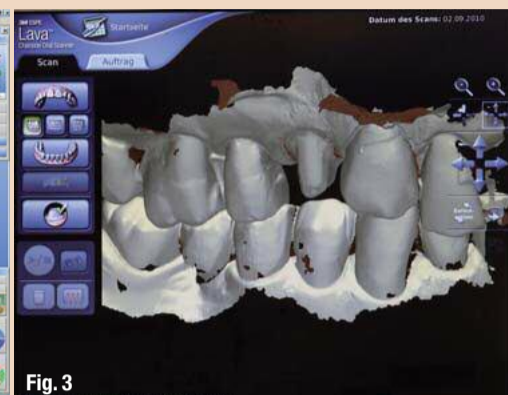

Fig. 3

procedure captures single images; the angled imaging function acquires tooth areas below the equator and thus increases accuracy. Through matching, several images are computed of a quadrant or whole arch (Fig. 2), as are the antagonist dentition and bite record.

The wavefront sampling of C.O.S. Lava captures the tooth shape by moving the video camera over the teeth. The distance to the camera can be calculated from the changing position of individual pixels during filming, giving rise to a 3-D image of the dental arch (Figs. 3 & 4).

The functioning of the iTero scanner is based on the principle of laser triangulation. The image captures the tooth and vertically scans 300 levels, each 50 µm deep (Figs. 5 & 6).

According to Prof Wöstmann, the scanning accuracy of CEREC AC and C.O.S. Lava corresponds to a conventional hydrocolloid or polyvinyl-siloxane impression. The differences were not significant.¹ Measurements of crown copings fabricated with C.O.S. Lava yielded an average of 33 µm (± 16 µm) for all

marginal gaps. Copings produced using the conventional impression-taking technique had a mean marginal gap of 69 µm (± 25 µm). Syrek et al. found comparable results in a clinical study.² The mean marginal gap of conventionally manufactured crowns was 71 µm, as compared with 49 µm for the C.O.S. Lava crowns. For CEREC 3D, the literature cites a tolerance of 40 µm (± 21 µm).

Another advantage of digital impressions is that the scanned preparation can be checked directly on the screen, where imperfections can also be immediately corrected (Figs. 7 & 8). For patients with an easily triggered gag reflex, these scanning methods greatly improve treatment comfort. Further benefits result from fewer working steps involved, especially in the practice. Choosing an impression tray, mixing the elastic impression compound, waiting during setting and disinfection, as well as producing a model are no longer necessary.

Fewer treatment and working steps also mean fewer sources of error and better standardisation, which in turn can

improve the predictability of treatment outcome. Prof Wöstmann cautioned that with crown margins that are clearly subgingival, the optical systems reach their limits; thus, conventional impression-taking techniques are still used in such cases.

Digital impressions are more accurate

At the 12th annual meeting of the International Society of Computerized Dentistry, Prof Gerwin Arnetzl, University of Graz, compared the accuracy of digitally generated impressions with that of conventional elastic impressions. When conventional impressions demonstrate an elastic recovery of 98.5% after deformation, a fitting accuracy of 35 to 75 µm for an inlay cavity can be expected. For cast pieces, additional tolerances of up to 46.5 µm accumulate,⁴ so that indirectly manufactured crowns can attain deviations of up to 114 µm.

Different elastomeric impression techniques can cause considerable deviations. For instance, in analogue impression-taking using different impression materials and trays, dimensional changes compared with

the reference (a cast metal control) varied between 0.32 and 1.17%. A deviation of 49 µm was found for standard and 122 µm for control impression-taking.⁶ As a rule, however, the studies on analogue impression-taking techniques were performed using 2-D measurements; the new studies on the imaging accuracy of optical methods were conducted with 3-D volume difference analyses.

Digitally or optically produced images by different operators exhibited a measurement accuracy of 11 µm.

With the analogue impression-taking technique, the deviations for a whole quadrant ranged from 72 to 101 µm, while the measurement error tolerance of digital images is only about 35 µm, thanks also to the enhanced accuracy made possible by angled images. Potential sources of error in the digital impression-taking technique are scanner adjustment, magnetic interference fields during image processing, image noise and the software. According to Prof Arnetzl, these results prove that given the correct use of a camera or scanner, digitally generated data exhibits fewer errors and greater

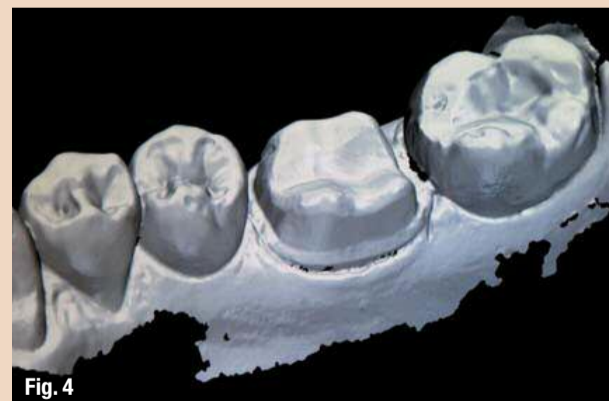

Fig. 4

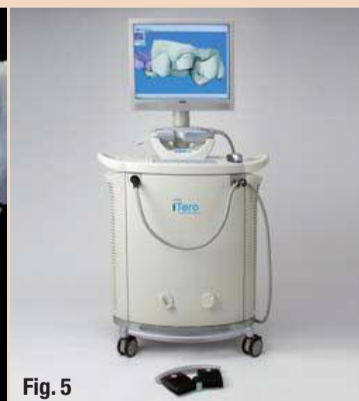

Fig. 5

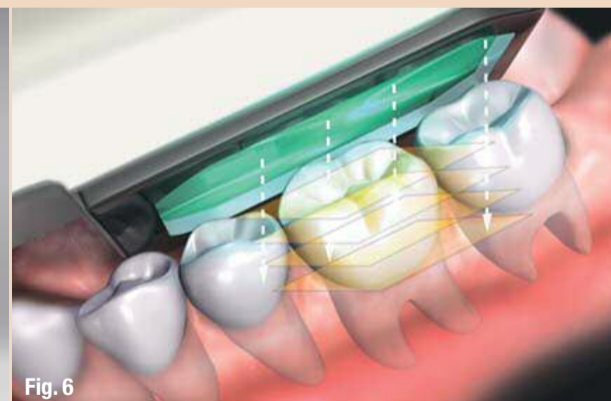


Fig. 6

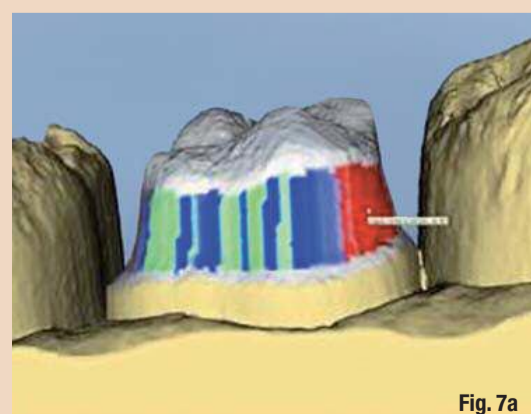


Fig. 7a

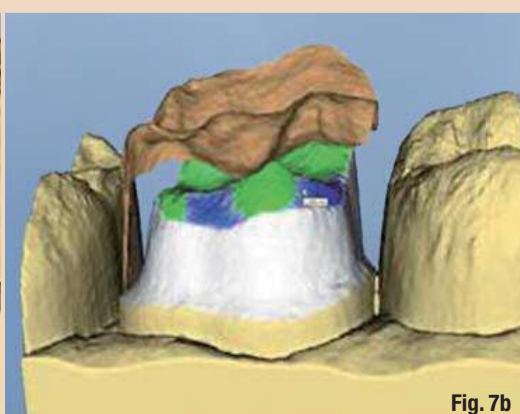


Fig. 7b

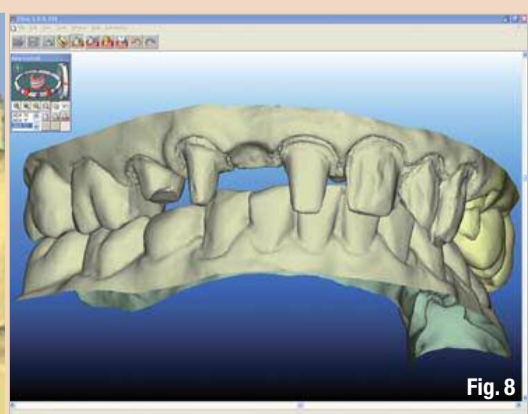


Fig. 8

Fig. 1_Short-wave blue light with structured light projection. (Photo courtesy of Ender)

Fig. 2_Single images are matched to create a digital full-arch model, basis for construction and milling of the framework. (Photo courtesy of Mehl)

Fig. 3_Optoelectronic intraoral scan using the C.O.S. Lava system. Crown preparation and preparation margin are portrayed exactly. In addition to framework manufacture, the dataset enables production of an SLA resin model including the antagonist teeth.

Fig. 4_Intraoral scan (C.O.S. Lava) of a molar with a cusp-supported preparation, for a ZrO2 crown framework. (Figs. 3 & 4 courtesy of Wöstmann)

Fig. 5_iTero is equipped with a laser camera. It is the third intraoral scanner on the European market.

Fig. 6_iTero scans the tooth at several levels using laser triangulation.

Figs. 7a & b_The virtual "prep-check" checks the preparation margins and the occlusal reduction against the antagonist tooth. (Photo courtesy of Lauer)

Fig. 8_The full-arch scan for an FDP construction using the iTero system. (Figs. 5, 6, 8 & 10 courtesy of Straumann)

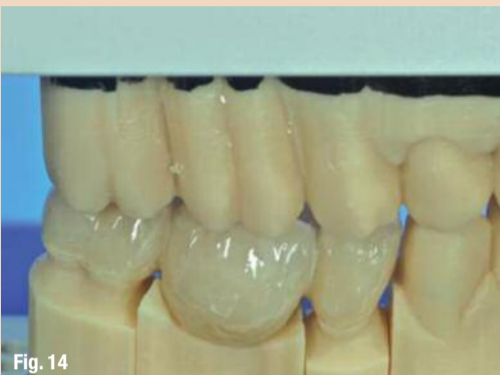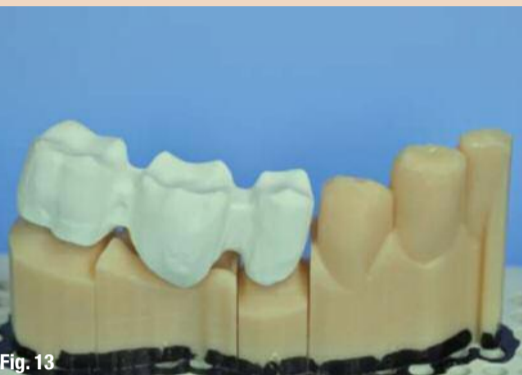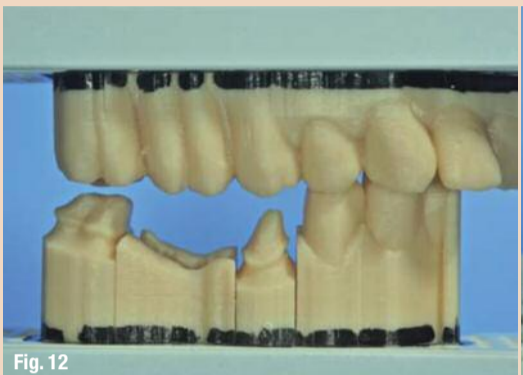
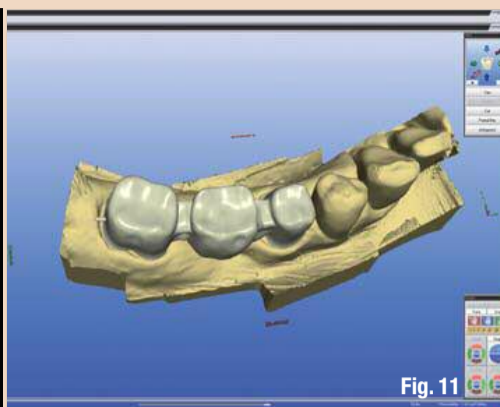
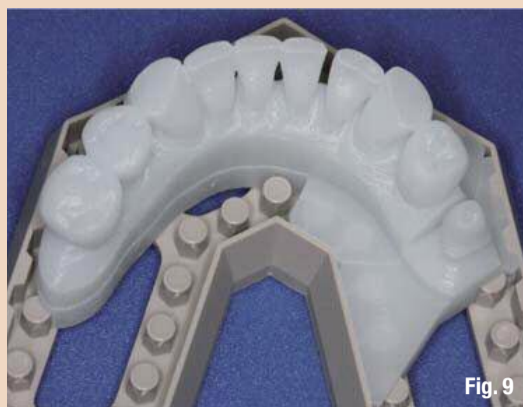Fig. 9_SLA resin model using the C.O.S. Lava system. (Photo courtesy of 3MESPE)

Fig. 10_Digitally milled resin model using the iTero system.

Fig. 11_Construction of an FDP.

Fig. 12_SLA model (acrylic) for trying in the framework.

Fig. 13_Trying in the ZrO2 framework. Fig. 14_Veneering and articulation. (Figs. 11-14 courtesy of Baltzer)



struction of the restoration, the dental technician can either mill the framework in his/her own laboratory or have it done at the milling centre. The resin model is needed to layer on the veneers and perform articulation. CEREC AC also computes a virtual model (Fig. 11).

Framework-free crowns and short-span FDPs can be milled immediately, directly from the dataset, in the practice's laboratory or in another dental laboratory with an online connection to the practice.

For veneered crowns and multi-unit bridges, a stereolithographically produced resin model (SLA) is necessary, which is provided by InfiniDent (Sirona) and makes veneering the framework and articulation possible (Figs. 12-14).

Optoelectronic impression-taking systems are extremely promising. Owing to the offered advantages in standardisation, quality assurance and patient-comfort, digital intraoral impression-taking systems have great potential for the future. In the

coming years, they will be seen in ever-increasing numbers in daily dental practice.

The datasets they create, thanks to the exchange of infor-

mation online, simplify communication between the dentist and the dental technician, regardless of distance. Supplemental facial photos, information on tooth colour, individualisation, mate-

rial, occlusal concept, etc. can also be attached. All of this happens without conventional impression-taking and the associated gag reflex, wax check-bite and stone model. **DT**

accuracy than the conventional impression-taking technique with elastomeric impression materials.

A virtual model of the maxilla/mandible is computed from the scans of the quadrants or complete dental arch with the antagonist dentition. Via the Internet, the dentist sends the datasets from C.O.S. Lava or iTero to the manufacturer, where they are checked before being used to produce a resin model (Figs. 9 & 10). After CAD con-

AD

FDI World Dental Federation

Leading the World to Optimal Oral Health

2012 Hong Kong FDI Annual World Dental Congress

29 August - 1 September 2012

10 reasons to join FDI in Hong Kong, World Oral Health Capital 2012

1. **Celebrate** the uniqueness of FDI at its 100th Annual World Dental Congress;
6. **Enjoy** exclusive face-to-face encounters with your peers worldwide;
2. **Learn** about the latest developments from international and regional experts;
7. **Develop** your knowledge and skills through a new and innovative programme;
3. **Discover** the newest technology, equipment, products and materials;
8. **Sample** some of the best cuisine in Asia: one restaurant for every 600 inhabitants!
4. **Interact** with renowned world specialists;
9. **Marvel** at the breathtaking views of Hong Kong and Macau;
5. **Empower** yourself through FDI sessions on policy and public and oral health;
10. **Uncover** the riches and mysteries of mainland China.

Leading the world into a new century of oral health

www.fdicongress.org congress@fdiworldental.org

ADA CERP® Continuing Education Recognition Program

MEDIA CME Self-Instruction Program

Dental Tribune Middle East & Africa in collaboration with CAPP introduce to the market the new project mCME - Self Instruction Program. mCME gives you the opportunity to have a quick and easy way to meet your continuing education needs. mCME offers you the flexibility to work at your own pace through the material from any location at any time. The content is international, drawn from the upper echelon of dental medicine, but also presents a regional outlook in terms of perspective and subject matter.

How can professionals enroll? They can either sign up for a one-year (10 exercises) by subscription for the magazine for one year (\$65) or pay (\$20) per article. After the payment, par-

ticipants will receive their membership number and will be able to attend to the program. **How to earn CME credits?** Once the reader attends the distance-learning program, he/she can earn credits in three easy steps:

1. Read the articles.
2. Take the exercises
3. Fill in the Questionnaire and Submit the answers by Fax (+971 4 3686885) or Email **:info@cappmea.com**

After submission of the answers, (name and membership number must be included for processing) they will receive the Certificate with unique ID Number within 48 to 72 hours. Articles and Questionnaires will be available in the website after the publication. **www.cappmea.com**

VITIS gingival
Gentle cleaning for delicate gums

- PREVENTS AND HELPS TREAT GINGIVITIS-RELATED BLEEDING AND INFLAMMATION.
- FIGHTS ORAL BIOFILM BUILD-UP*
- REDUCES GINGIVAL INFLAMMATION*

VITIS
because the difference is in your mouth

Exclusive Distributor :
Pharmapal Drug Store
Tel +971 4 2675001, PO Box 37345
Dubai, United Arab Emirates
www.pharmapaluae.com

DENTAID
The Oral Health Experts

Metal ceramic – well-proven and future oriented

We at Dentallabor Cera-Tech in Liestal/Switzerland, concentrate to a large extent on CAD/CAM technology and spend a lot of time advocating the cause of allceramics. Nevertheless, metal ceramic, comprises around 30% of our range of products and services, continues to remain an indispensable part of our programme. Gold accounts for 70% of this, and – trend increasing – non-precious metal alloys 30%.

The following article presents a corresponding case example.

Customer requirement and planning

The patient's tooth 11 was fractured and tooth 21 showed severe cracks (fig. 1). The requirements of the dentist were clearly defined, and communicated by oral agreement and an order form: the crowns were to be implemented as a standard restoration in metal ceramic, and at the same time blend harmoniously with the patient's oral situation.

For this reason, we decided to have the shade determination performed in the dental practice, and instead of using the casting technique, to fabricate the crown coping by milling a CAD/CAM restoration from a non-precious metal alloy. For the veneer we chose VITA VMK Master, a new metal ceramic for veneering in the classical style, and which promises brilliant shade reproduction.

The implementation

For shade determination we use – with growing enthusiasm – the VITA Linearguide 3D-Master, which is also finding increasing approval on the part of our dentist customers. We like the fact that it is based on the already known linear principle because it does not require any rethinking in terms of the concept. Also in the case described here, the dentist used this for determining the tooth shade. In addition to this, he documented the situation prior to treatment and the results of shade determination with regard to lightness and chroma by means of digital photographs which he sent us by e-mail. Further discussion of the case took place by telephone. This procedure usually enables us to achieve a remarkably high degree of accuracy, even without

the dental technician having come into contact with the patient in person.

The master model was scanned and used as a basis for the virtual framework design, and the latter was milled from a non-precious metal alloy. An important prerequisite for digitisation is that the dentist must be accurate in his preparation work, so that the preparation margin can be easily read by the scanner. The risk of cavities and porosities which could endanger the veneer, and in the event of late cracks result in work covered by guarantee, is no longer given in CAD/CAM manufacture, since the non-precious metal blanks are industrially fabricated ac-

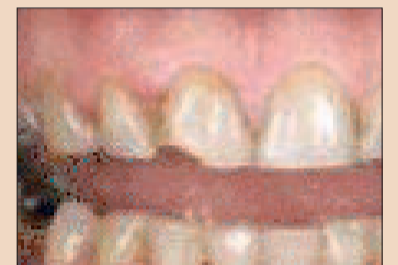

Fig. 1: Situation before treatment.



Fig. 2: Opaque application in the VITA SPRAY-ON procedure.

ording to unified quality standards. A further advantage of the milled non-precious metal copings is their high degree of marginal accuracy. The work required in the fitting of the copings is reduced to a minimum – only the mounting pins have to be removed, and the margin finished in such a way that it tapers thinly.

We used a silver and palladium-free alloy which has high strength values that enable it to withstand a high load capacity. This offers a high-quality, and, above all, a cost-effective alternative to all-ceramic and gold content solutions.

For the opaque application we use the SPRAY ON procedure (fig. 2), so that a thin and homogeneous layer thickness is achieved, which at the same time has good covering power. The




Fig. 3: Completing the build-up with enamel and effect porcelains.

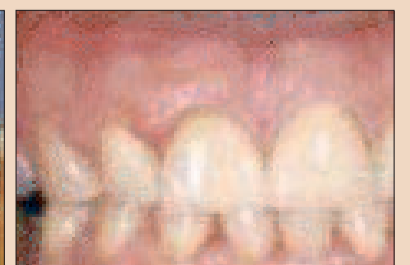


Fig. 4: End result directly after seating the restoration.



Fig. 5: VITA VMK Master

restoration was built up using the classical dentine/ enamel layering known, for instance, from VITA OMEGA 900. In this way, by using an efficient layering technique, I can quickly and easily obtain an aesthetic result.

I am impressed by the stability characteristics of the ceramics. This material property is an advantage especially in the case of larger restorations.

VITA VMK Master offers a comprehensive assortment for individualisation. In this case, however, because a standard solution was requested, I kept to just a few different materials, and modelled only the mamelons. I built up the incisal edge and the approximal areas by applying ENAMEL (EN1), and OPAL TRANSLUCENT (OT1) (fig. 3). The restoration was fired at 930°C, the approximal and palatal contacts adjusted, the latter in the articulator with lateral and protrusion movements under canine guidance before the finishing of the restoration.

I am very impressed by the very low degree of shrinkage, which I will be pleased to take into account when layering in fu-

ture. A generous application of porcelains at the approximal points in order to compensate for shrinkage is not necessary to this extent, as I am accustomed to doing with other ceramics. The final glaze firing achieves a shade brilliancy which awakens the tooth to life. There is a natural harmony between opalescent and translucent regions. As with every ceramic veneer, the actual success of the restoration can only be seen when the restoration is seated in the patient's mouth. Only then is it possible to assess whether the crowns – as desired by the patient – are harmoniously matched to the patient's oral situation. In our case, patient, dentist and dental technician alike were satisfied with the restoration (fig. 4).

Conclusion

Our aim is to provide an attractive solution with natural aesthetics in the VMK technique, even in cases which initially do not look very promising. If dentist and / or patient insist on a metal ceramic instead of a full ceramic highend solution, we can offer good, competitive results using our CAD/CAM system and VITA VMK Master, which is based on a combination of state-of-the-art equipment and highquality materials. Thanks to the use of a ceramic which is simple to process, pleasant to work with, and has a wide processing interval and accurate shade reproduction, which, in combination with the VITA Linearguide, enables the fabrication of crowns with natural aesthetics, time-consuming adjustments and corrections are usually unnecessary. **DI**

AD

Supported by:

وزارة الصحة
Ministry of Health

MEDEXPO
Saudi Arabia

الصحة العامة للغذاء والدواء
Saudi Food & Drug Authority

مجلس التأمين الصحي التعاوني
Council of Cooperative Health Insurance

ATTEND SAUDI ARABIA'S ONLY HEALTHCARE EXHIBITION

17 - 20 June 2012
4pm - 10pm
Jeddah Center for Forums and Events

Also presenting the inaugural MEDEXPO Forum

Register now for free entry to the exhibition www.medexposaudi.com

Organised by: dmg :: events

Organisers of: M.I.C.E Arabia

VITIS

orthodontic

the complete care your patients need

VITIS orthodontic mouthwash Mundspülung

VITIS orthodontic wax

VITIS orthodontic toothpaste

Apple-mint flavour

your daily oral hygiene

DENTAID
The Oral Health Experts
www.dentaid.com

Exclusive Distributor :
Pharmapal Drug Store
Tel +971 4 2675001, PO Box 37345 Dubai, United Arab Emirates
www.pharmapaluae.com