

DENTAL TRIBUNE

The World's Dental Newspaper · Middle East & Africa Edition

PRINTED IN DUBAI

www.dental-tribune.com

SEPTEMBER - OCTOBER 2013 | NO. 5, VOL. 2

ORAL HYGIENE
The Up-To-Date Series
Of Educational Events
Start In The Middle-East



MEDIA CME
Esthetic Long-Span
Bridge Using BruxZir



PRODUCT LAUNCH
New: Sensodyne
Complete Protection



SHOW EDITION
BIDM 2013 Beirut
Lebanon



> Page 22

> Page 6-7

> Page 14-15

> Insertion

NEW: 5th Dental Facial Cosmetic International Conference Hosts Inman Aligner Accreditation Course



By Inman Aligner

The 5th Dental Facial Cosmetic International Conference joint event with 2nd Global Conference of the American Academy of Implant Dentistry on 08-09 November at the Jumeirah Beach Hotel in Dubai will host the newest product in aesthetic orthodontic treatment provided by Inman Aligner.

The Inman Aligner is a revolutionary appliance described as the "missing-link" between cosmetic dentistry and orthodontics. It can move teeth in the anterior region quickly, safely and predictably using a single appliance. Whether it's a standalone treatment or prior to further cosmetic dentistry, patients and dentists love the speed of treatment. At last, conservative, no-compromise cosmetic dentistry has become a great option and is now available in the UAE.

the highly recommended hands-on course "The New Concept of Alignment, Bleaching and Bonding (ABB) (Inman Aligner Accreditation Course). Taking place on November 10 between 9am - 6pm attendees will be able to get started right away. Certified providers can access free online support, revision courses, marketing materials, downloads and the 'Space-wize' crowding calculator.

Inman Aligner will be launching

> see filling page 21

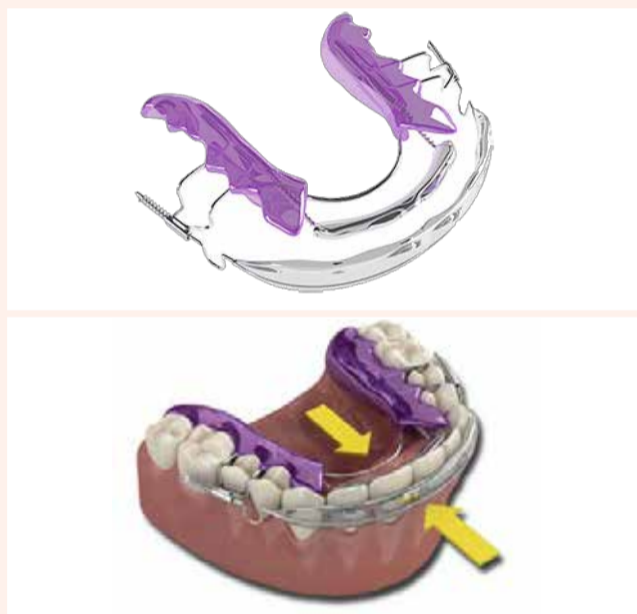


Fig. 1 The squeeze effect of the two aligner bows on the front teeth.

AGENDA	
08 November 2013	09 November 2013
08:00 - 09:00 / Breakfast with the Sponsors, Registration	08:00 - 09:00 / Breakfast with the Sponsors, Registration
09:00 - 09:45 Prof. George Anastassov, USA/AAID Facial Aesthetic Surgery- State of the Art	09:00 - 09:45 Dr. Andrew Saadoun, France/AAID Aesthetic Soft Tissue Management around Implants
09:45 - 10:30 Dr. Andreas Kurbad, Germany Smile Design as a key factor in the Esthetic treatment planning	09:45 - 10:30 Dr. Luca Cardaro, Italy/AAID Alveolar Augmentation in the Aesthetic Zone
10:30 - 10:45 / Meet the Sponsors, Coffee Break	10:30 - 11:15 Dr. Andreas Kurbad, Germany Ceramic in harmony with nature Ultraconservative restoration of enamel
10:45 - 11:30 Prof. Dr. Claus-Peter Ernst, Germany Tooth colored indirect restorations: Material selection, operative procedures, luting concepts.	11:15 - 11:30 / Meet the Sponsors, Coffee Break
11:30 - 12:15 Dr. Paul Weigl, Germany Sirona	11:15 - 11:30 Prof. Dr. Claus-Peter Ernst, Germany Directly placed anterior restorations today: Simplified concepts as the key to success
12:15 - 13:30 / Lunch, Prayer Time	12:15 - 13:00 Dr. Paul Weigl, Germany Sirona
13:30 - 14:15 Dr. James Russell, UK Progressive Smile Design: Truly Minimally Invasive Cosmetic Dentistry For Every Dentist	13:00 - 14:15 / Lunch, Prayer Time
14:15 - 15:00 Dr. Maria Hardman, Germany Carestream	14:15 - 15:00 Dr. Natalie Wong Canada/ AAID Digital Implant Dentistry - Has it Arrived?
15:00 - 15:45 Dr. James Russell, UK Ivoclar Vivadent	14:15 - 15:00 Dr. Nick Katsikeris, Canada/ AAID Possible Postulates of Peri-Implantitis Complications
15:45 - 16:30 Prof. Colin Murray, UK Oral B P&G	15:45 - 16:30 Dr. Shankar Iyer, USA/ AAID Controversies explored in Implant Dentistry
16:30 - 16:45 / Meet the Sponsors, Coffee Break	16:00 - 16:45 Dr. Samar Mashabi, KSA Oral B P&G
16:45 - 17:30 Dr. Gary Wadhwa, USA/ AAID "Better Value" Oro-Facial Healthcare	16:45 - 17:30 Dr. Tedie Lynn Hudson, KSA Restorative Treatment Planning with Orthodontics A New Approach
Hands on Workshops: 07-10 November	
AESTHETIC REHABILITATION (Minimum Invasive All-Ceramic Restorations for Better Aesthetic Results) Course Facilitator: Dr. Andreas Kurbad, Germany November 7, 2013, JSH, Dubai, UAE Estimated 8 CME Hours	INDIRECT VENEERS Course Facilitator: Dr. Murat Silekli, UAE November 7, 2013 3M Innovative Center, DIC, UAE Estimated 8 CME Hours
THE NEW CONCEPT OF ALIGNMENT, BLEACHING AND BONDING (ABB) (Inman Aligner Accreditation Course) Course Facilitator: Dr. James Russell, UK November 10, 2013, JSH, Dubai, UAE Estimated 8 CME Hours	SOFT TISSUE MANAGEMENT Around Teeth and Implants Course Director: Dr. Andre Saadoun, France Course Facilitator: Dr. Amit Vora, USA November 10, 2013 Jumeirah Beach Hotel, Dubai, UAE Estimated 8 CME Hours

Emirates Dental Society Attends Annual World Dental Congress On Dental Technology And Oral Health To Bring Back Key Learnings To The UAE

The Emirates Dental Society urges UAE residents to adopt a complete oral health regimen, of brushing flossing, dental visits and even chewing sugar-free gum, and announce intention to host a mega dental congress in Dubai next year



Dr. Aisha Sultan
President of EDS

By Emirates Dental Society

Dubai, UAE. According to recent research conducted by SEHA, (Abu Dhabi Health Services Company), 64% of school children in the Emirates show signs of tooth decay, largely due to poor dental hygiene. Furthermore, data shows tooth decay a largely preventable condition to be the most prevalent chronic health condition in the UAE affecting more

than 80 percent of the population. In an effort to combat these staggering statistics and further advance oral care in the UAE, a delegation from the Emirates Medical Association's Dental Society (EDS) headed by its President, Dr Aisha Sultan Alsuwaidi, attended the 2013 Annual World Dental Congress (FDI) in Istanbul, Turkey on 28th-31st August.

According to Dr Aisha Sultan and based on Emirates Dental Society surveys and data resources; "Four out of five people residing in UAE exhibit signs of tooth decay" commented Dr Aisha Sultan. This is particularly alarming given the fact that tooth decay is largely preventable through good oral hygiene habits such as brushing at least twice daily, flossing, chewing sugar-free gum and regular visits to dentists.

Dr Aisha Sultan continued, "Each year at FDI, we are able to bring back key advances to the Emirates that might help improve the oral health practices of our residents. For example, scientific evidence shows that something as simple as chewing sugar-free gum following meals has significant oral health benefits. It stimulates saliva,


which washes away food debris, and ultimately leads to healthier teeth and gums. This is one simple and perhaps underutilized and undervalued option that helps prevent tooth decay and begin to establish a good oral healthcare routine."

In an effort to promote oral health awareness and good oral hygiene practices in the UAE, the EDS is collaborating with the Asia Pacific Dental Federation, the UAE Ministry of Health and the Emirates Medical Association to host an international dental event in Dubai next year. The Asia Pacific Dental Congress (APDC) will be held at the Dubai World Trade Center from the 17th to the 19th of June 2014. The congress is expected to attract more than 3,000 dental industry experts from approximately 45 countries. As such, APDC Dubai 2014 is set to become the largest industry event in the region.

Dr Aisha Sultan, President of the Emirates Dental Society and Chairperson of APDC, commented, "Our aim is for the APDC to feature a broad scientific program that truly underlines pioneering research and technological developments which

have the potential to change the landscape of oral healthcare and hygiene. The global dental community recognizes the positive impact of good oral hygiene on the general wellbeing of the society. The theme for APDC 2014 is Improving Quality of Life through better Dental Care. APDC will not only provide an opportunity to uplift the dental profession in the

region, but will also showcase our commitment to improving the general health and the overall wellbeing of the natives and residents of the UAE and beyond."

To learn more about APDC Dubai 2014, please visit <http://apdentalcongress.org>. 

International Imprint

Licensing by Dental Tribune International Group

Editor	Daniel Zimmermann newsroom@dental-tribune.com +49 341 48 474 107
Clinical Editor	Magda Wojtkiewicz
Online Editors	Yvonne Bachmann Claudia Duschek
Copy Editors	Sabrina Raaff Hans Motschmann
Publisher/President/CEO	Torsten Oemus
Director of Finance & Controlling	Dan Wunderlich
Business Development Manager	Claudia Salwiczek
Media Sales Managers	Matthias Diessner (<i>Key Accounts</i>) Melissa Brown (<i>International</i>) Peter Witteczek (<i>Asia Pacific</i>) Maria Kaiser (<i>USA</i>) Weridiana Mageswki (<i>Latin America</i>) Hélène Carpentier (<i>Europe</i>)
Marketing & Sales Services	Esther Wodarski
Accounting	Karen Hamatschek
Executive Producer	Gernot Meyer

Dental Tribune International
Holbeinstr. 29, 04229 Leipzig, Germany
Tel: +49 341 4 84 74 302 |
Fax: +49 341 4 84 74 173
www.dental-tribune.com
info@dental-tribune.com

Regional Offices

Asia Pacific
Dental Tribune Asia Pacific Limited
Room A, 20/F, Harvard Commercial Building,
105-111 Thomson Road, Wanchai, Hong Kong
Tel: +852 3113 6177 | Fax: +852 3113 6199

The Americas
Tribune America, LLC
116 West 23rd Street, Ste. 500, New York,
N.Y. 10011, USA
Tel: +1 212 244 7181 | Fax: +1 212 244 7185

Dental Tribune Middle East & Africa

Edition Editorial Board

Dr. Aisha Sultan Alsuwaidi, *President Emirates Dental Society, UAE*
Dr. Nabeel Humood Alsabeeha, *Consultant Prosthodontist, Ministry of Health, UAE*
Dr. Dobrina Mollova, *MDS, UAE*
Dr. Munir Silwadi, *BDS, MRCDSO, DUSS, FADI, FICD, UAE*
Dr. Khaled Abouseada, *BDS, MS, orthod. cert. Consultant Orthodontist, KSA*
Dr. Rabih Abi Nader, *B.D.S, D.E.S, D.E.S.S, Oral Surgeon and Implantologist, UAE*
Rodny Abdallah, *Dental Technician, CDT, Lebanon*

Director of mCME
Dr. Dobrina Mollova
info@cappmea.com
+971 50 42 43072

Business Development Manager
Tzvetan Deyanov
deyanov@dental-tribune.com
+971 55 11 28 581

DID YOU KNOW

Almost **1 in 5** people find
stained teeth a turn off¹.
Beverly Hills Formula toothpaste
removes over **91%** of stains²
to give you **whiter** teeth
in **1 minute**



info@beverlyhillsformula.com



@BHF_Whitening



Beverly Hills Formula



+353 1842 6611

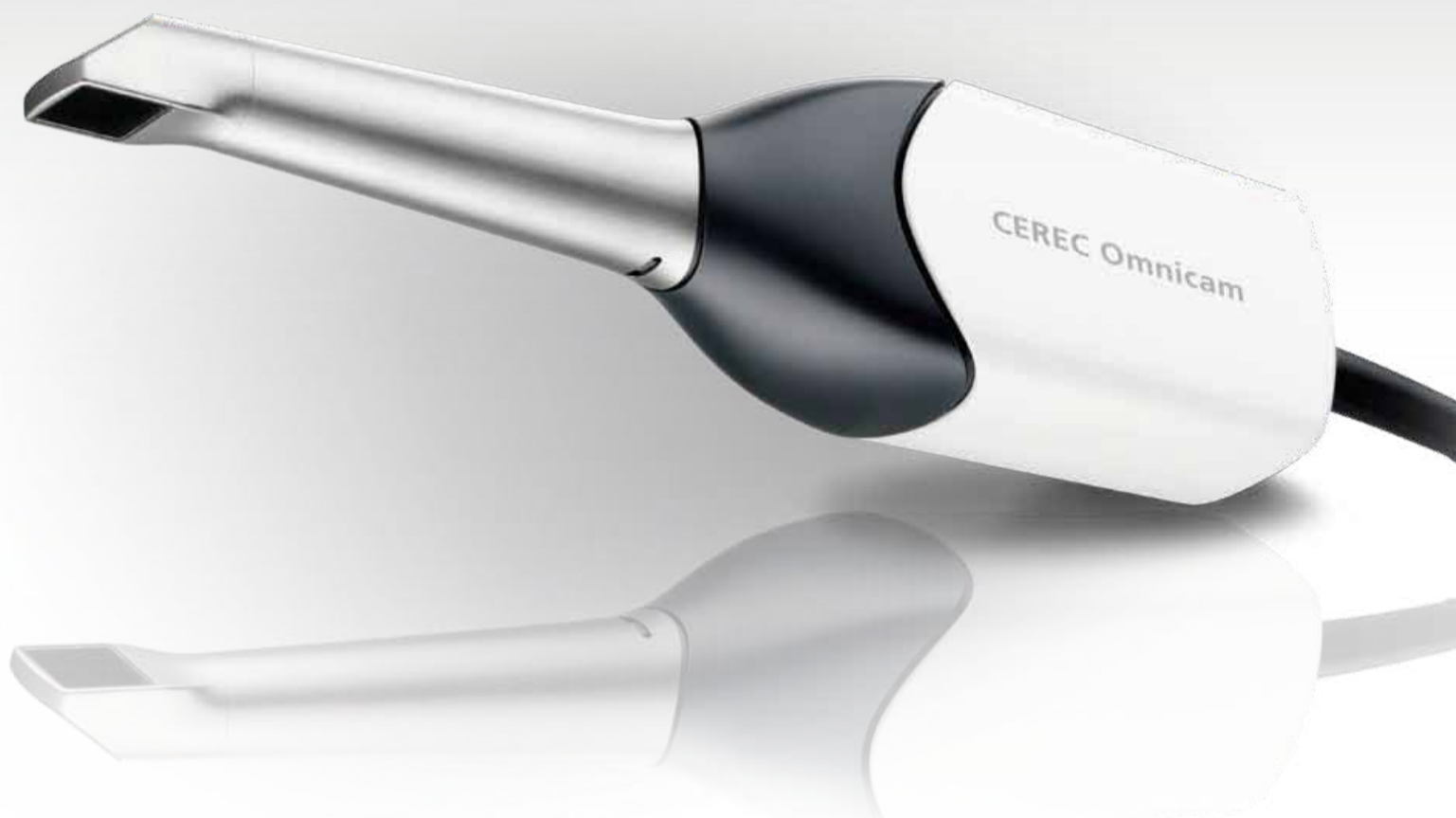www.beverlyhillsformula.com

Beverly Hills Formula toothpastes rank no.1 for stain removal when compared with other leading brands of whitening toothpastes and toothpolishes. (Stain Removal Data 2012) See the full range and results at www.beverlyhillsformula.com

Source: British Dental Health Foundation, January 2012. Source: Stain Removal Data 2012. Applies to Beverly Hills Formula Natural Whitening Expert toothpaste only.

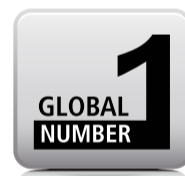

Elegant design and easy handling are a winning combination.



CEREC OMNICAM

THE EVOLUTION OF SIMPLICITY



The new CEREC Omnicam combines powder-free ease of handling and natural color reproduction to provide an inspiring treatment experience. Discover the new simplicity of digital dentistry – exemplified by Sirona's premium camera portfolio: CEREC Omnicam and CEREC Bluecam. **Enjoy every day. With Sirona.**

UNRIVALLED HANDLING ■ POWDER-FREE ■ SCANNING IN NATURAL COLOR

Contact: SIRONA Dental Systems Ltd · Dr Amro Adel · Building 49, Suite 304
Dubai Healthcare City · Telephone: + 971 4 375 2355 · E-Mail: amro.adel@sirona.com

sirona.com



The Dental Company

sirona.

Snoring And Sleep Apnoea – A Role For The Dentist

By Dr. Danielle Stephenson

Sleep apnoea has been known, and reasonably well understood, by the medical profession for a considerable time. Indeed, there are accurate descriptions of sufferers in some of Charles Dickens' work. However, the disease process was not understood during the Victorian period and it wasn't until the 1980s that technology was developed to help treat the problem. The last decade in particular has seen far greater understanding of the disorder and the introduction of simple, cost-effective solutions that deliver real benefits for patients.

Sleep-related breathing disorders are caused by varying degrees of collapsibility of the pharyngeal airway and range from simple palatal snoring to obstructive sleep apnoea. Simple snoring (affecting up to 45% of the adult population) is itself a health hazard. It has been shown to lead to poor memory, excessive daytime sleepiness, inability to concentrate, and reduction in overall performance due to the resultant sleep disturbances.

With Obstructive Sleep Apnoea (OSA) there is a much greater degree

of collapse of the pharyngeal airway, causing obstruction, which leads to pauses in breathing ('apnoea') or episodes of abnormally shallow breathing ('hypopnoea'). The hypoxia and hypercapnia resulting from these apnoeic and hypopnoeic events wakes the sufferer in order to re-establish patency and normal ventilation. Snoring is present in nearly all OSA patients and is classically very loud and intermittent. The snoring may be accompanied by gasping and some patients may wake with the feeling they are choking or gagging. Most problematic of all for sufferers is excessive daytime sleepiness as a result of the hypoxia and poor quality sleep arising from the multiple arousals from sleep. Left untreated, OSA is also thought to place patients at increased risk of hypertension, coronary artery disease, heart failure, cerebrovascular disease and sudden death.

Dr. Ama Johal, Consultant and Senior Lecturer at Barts and the London Queen Mary's School of Medicine and Dentistry and a leading expert in the field of sleep-related breathing disorders, said: "There is ever increasing awareness of sleep-related breathing disorders and the role mandibular advancement splints play in treating them. CPAP – continuous positive airway pressure – remains the gold standard treatment for severe cases of

OSA. However, mandibular advancement splints, provided by a patient's dentist, can offer a much simpler and more comfortable solution which can effectively treat many cases of mild and moderate OSA and eliminate snoring. There are a number of appliance designs on the market but not all have the same evidence base behind them."

With an increasing awareness of the problem there has been an increase in demand for the provision of mandibular advancement splints to treat these conditions, the demand coming both directly from patients attending dental practices and also on referral from medical colleagues.

Nicolas Bell, Managing Director of training company CPD Dubai agrees. "We are aware of the increasing demand from dentists to be able to provide mandibular advancement splints to treat a range of sleep-related breathing disorders. These disorders can have a profound effect on sufferers, their partners and those around them and we think this can be both a professionally and commercially satisfying area for dentists to get involved with. We have invited Dr. Ama Johal to come and speak on the topic to increase understanding amongst dentists in the regions and improve their ability to safely assess and treat

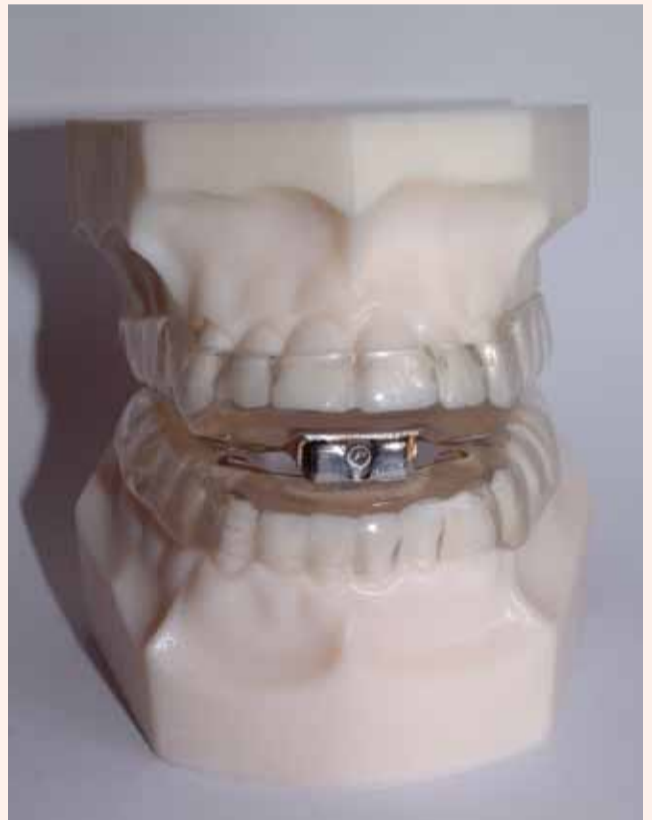
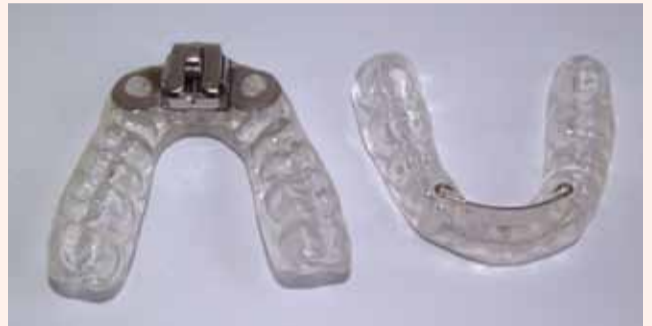
Fig.3, 4, 5: The 'Sleepwell' mandibular advancement splint.



Fig.1: CPAP machine

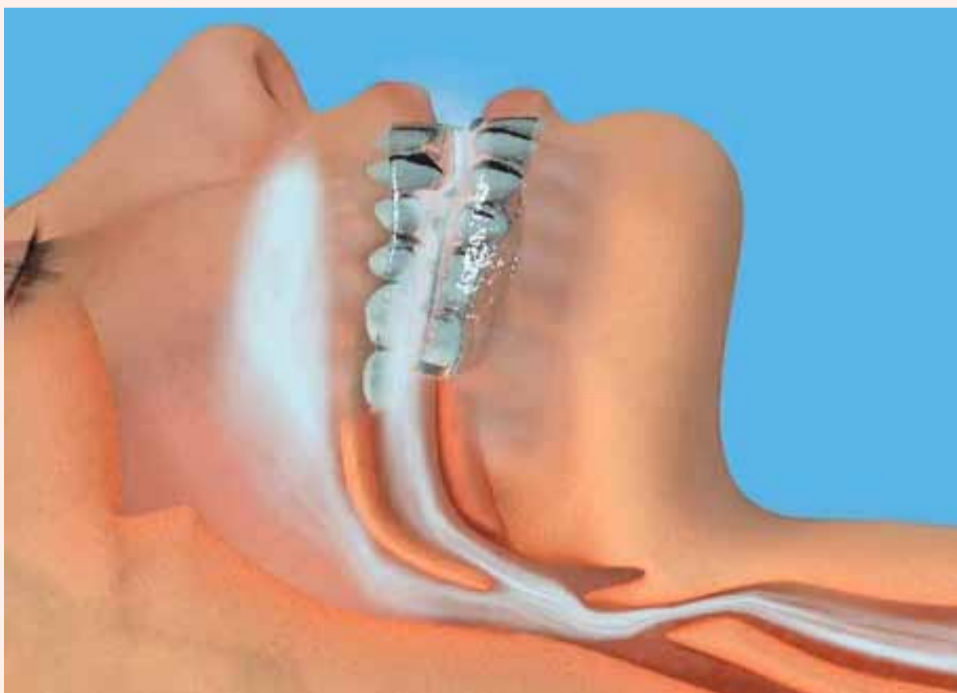


Fig.2: With appliance

patients using mandibular advancement splints."

The treatment of snoring and sleep apnoea using mandibular advancement splints is a rapidly expanding market both in Europe and North America, but despite large numbers of sufferers in the region, there are relatively few dental practitioners in the Middle East who can provide effective appliances. Samer Sabbagh, Managing Director of Qualident Dental Laboratory, said: "We view mandibular advancement splints as a core product we need to be able to provide to practices across the UAE and beyond. We have been working with a UK company called S4S to undertake the required training to fab-

ricate the Sleepwell appliance which is by far the most clinically proven and effective design. The Sleepwell is a soft, slim-line, two-piece appliance that unlike many similar appliances allows full lateral movement with the degree of advancement being fully adjustable. We are also looking to support local dentists with marketing and education materials for patients". DT

Contact Information

Information on CPD Dubai, licence renewal requirements and upcoming courses can be found at: www.cpd-dubai.com

'Snoring and Sleep Apnoea – A Role for the Dentist' will take place on **October 12th** at **The Address Hotel, Dubai Marina**.

Please visit www.cpd-dubai.com for more information and to make your booking.

EUROPEAN UNIVERSITY COLLEGE

(formerly NICOLAS & ASP UNIVERSITY COLLEGE)

FIRST INTERNATIONAL POSTGRADUATE DENTAL INSTITUTION IN THE REGION

MASTER DEGREE IN ORTHODONTICS

In cooperation with
Malmo University
in Sweden

Leads to Royal College
Membership (MOrth)

Accredited by:
MOHESR-UAE

MASTER DEGREE IN PEDIATRIC DENTISTRY

GA & OR Facilities &
Special Needs Care

Leads to Royal College
Membership (MPaed)

Accredited by:
MOHESR-UAE

MASTER DEGREE IN ENDODONTICS

Operating Microscope
Facilities, Computerized
Radiography

Leads to Royal College
Membership (MEndo)

Accredited by:
MOHESR-UAE

DIPLOMA IN ADVANCED EDUCATION IN GENERAL DENTISTRY

Operating Microscope
Facilities, Computerized
Radiography

Accredited by:
MOHESR-UAE

HIGH DIPLOMA IN ORAL IMPLANTOLOGY

Comprehensive Clinical
Training on Surgical &
Implant Restoration

CBCT Diagnosis and
Treatment Planning

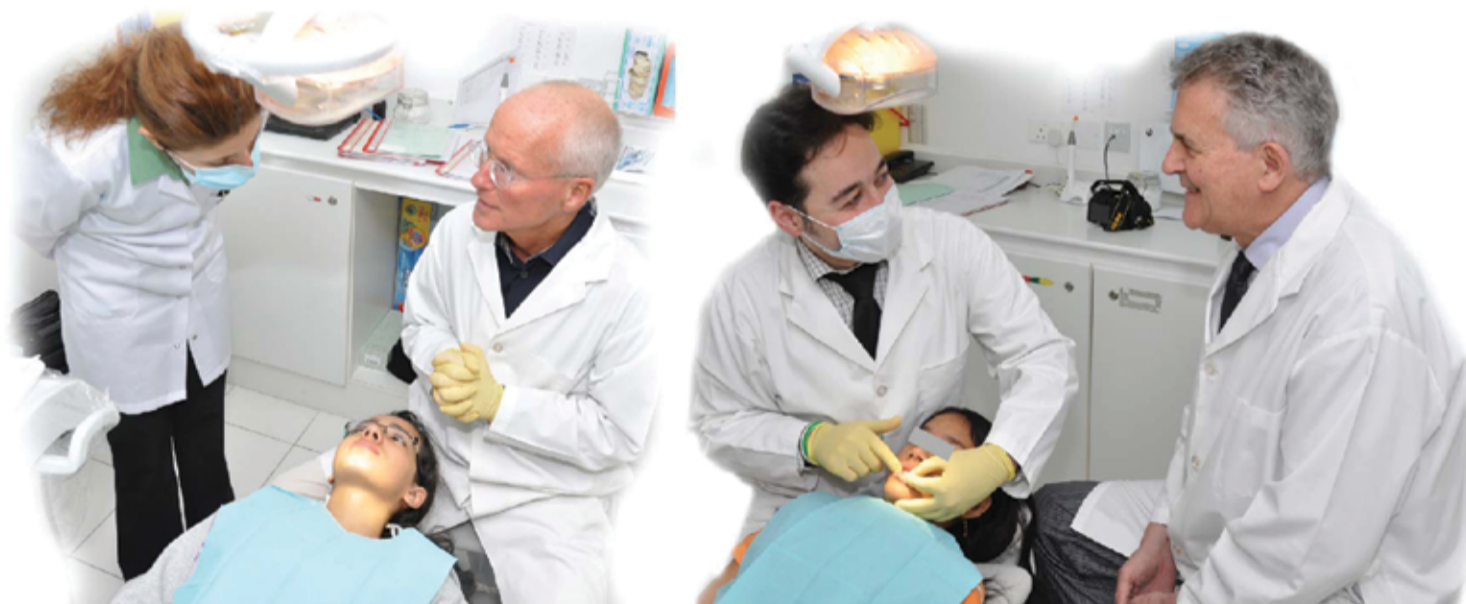Accredited by:
MOHESR-UAE

APPLY NOW

MASTER DEGREE IN
RESTORATIVE and
PROSTHODONTICS

ASSOCIATE DEGREE IN
DENTAL ASSISTING

- Accredited by The Ministry of Higher Education & Scientific Research (UAE)
- In Cooperation with Swedish Universities
- Accredited by the International Association of Universities (UNESCO)
- Teaching Faculty from reputed American & European Universities
- All programs include strong theoretical & clinical training
- Global pool of international students from Asia, Europe & the Middle East



CURRICULUM RECOGNIZED BY ROYAL COLLEGE OF EDINBURGH

EUC ORTHODONTIC GRADUATES EXEMPTED FROM THE WRITTEN EXAMINATION

ADMISSIONS FOR 2014 IS CURRENTLY OPEN



+97143624787

www.euc.ac.ae

info@dubaipostgraduate.com



Esthetic Long-Span Bridge Using BruxZir

mCME articles in Dental Tribune have been approved by HAAD as having educational content for CME credit hours. This article has been approved for 2 CME credit hours.

By Mark McOmie, DMD

One of the challenges that we face in dentistry today is how to build a long-span bridge with maximum esthetics in mind. In the age of implants, we can usually shorten the span by adding in a few implants or eliminate the need for a bridge all together by using implants to replace those missing teeth. However, what about those cases where we don't have the quality or quantity of bone that we need, a medical history that won't allow implant surgery such as free bleeding, a high-risk host such as a poorly controlled diabetic, smoker, etc.? Often times a patient doesn't desire to go through the complex surgery of a sinus lift or bone graft to make an acceptable site for implants. Patients should be given the options and risks associated with each approach and allowed to make an informed decision with the dentist's guidance. For a missing tooth there could be five or more options presented to the patient as ways to restore the space.

A case history

In 1998, a 39-year-old female presented with an abnormally loose tooth #12. Upon radiographic and clinical examination, it was noted there was little to no root left on teeth #10-13. Teeth #8 and #9 appeared normal as did tooth #14. Her gingival health was optimal and her medical history was unremarkable, and she was taking no medications at the time.

The patient recalled that when she was 14 years old she was hit in the face right above these teeth with a golf club during a friend's backswing, which probably lead to the resorption of the roots of the teeth in question. All options and risks were explained to the patient.

The sinus floor was 3 to 4 mm from the crestal bone. Implants with a sinus lift to allow room for placement were discussed. The patient did not like the idea of surgery and the healing time that would be required for a permanent restoration.

A partial was discussed; however, the young patient did not want to have a partial and was worried her esthetic demands would not be met. More options for less permanent treatment were offered, but the patient did not desire them.

The patient choose to do a long-span bridge, double abuting on teeth #8 and #9 with pontics to replace teeth #10-13 and using tooth #14 as a distal abutment. This would meet the patient's demands for esthetics and be a non-removable restoration. She would have the permanent restoration in less time than it would take to undergo implant therapy.

Porcelain-fused-to-metal was used on the original bridge work done in 1998. The highest noble metal content available that could span a four-pontic length was used. The porcelain work was done with a layered porcelain technique to provide a life-like appearance.

In January 2012, the patient, who was now 52 years old, presented with a broken tooth. She was eating a peppermint, incised it with the distal

of tooth #8 and fractured the porcelain in an incisal gingival direction. About 2 mm of porcelain came off toward the distal contact.

The metal substructure of the bridge was showing. The piece of porcelain was intact. She was on her way to a meeting she could not get out of and desired a temporary fix.

I tried the piece of porcelain in and found it to be adequate but not an exact match for fit. Some of the porcelain had chipped away and was lost. I rough-ened the surface of the bridge in her mouth in the area that needed the repair then placed K-etchant Gel by Kuraray to clean the area. I used Alloy Primer from Kuraray on the metal substructure.

On the porcelain, I placed Clearfil Ceramic Primer. Clearfil Majesty flowable composite was placed on the metal and on the piece of chipped porcelain. I refit the porcelain and light cured. All of these materials to do the repair are readily available in the Clearfil Repair Multi-Purpose kit from Kuraray.

It makes life simple to have ev-

erything you need in one place. The patient was able to get on with her day and made it on time to her meeting (Fig. 5). You can see the repair on the distal of #8.

Material selection

In the pre-op photo (Figs. 1,3, 5) you can see there is the telltale sign of a metal allergy to the metal that is in the bridge. The dreaded "black gum" look. In addition, there is a difference in height of the gingiva on teeth #8 and #9. The patient had already made the choice of a bridge, now we had to decide which material to use.

The patient reported that she has metal allergies to jewelry unless it is gold. So odds are high that any metal we use that is not 80 percent gold or more is going to cause a metal allergy and the dark gingiva. However, a metal that high in gold will bend on this long of a span, so we ruled out the use of metal. By eliminating the metal, the "black gum" look will go away (Figs. 5, 6).

BruxZir was the material of choice for

this case. BruxZir is a solid zirconia material that is sold to laboratories in a pre-sintered disk. CAD/CAM technology is then used to design and mill the restoration.

BruxZir Zirconia exceeds the flexural strength of typical zirconia (up to 1,465 MPa versus 1,200+ MPa for typical zirconia). BruxZir exhibits three to six times the fracture toughness (also known as the K1C value) of typical zirconia.

To better understand this concept, consider that a piece of steel or lead has high fracture toughness, whereas glass or brittle materials have a low K1C value. This property gives it high impact resistance. It also has excellent resistance to thermal shock. This low thermal expansion means the restorations will remain very stable in the mouth.

BruxZir is available in all the Vita Classic shades. Due to the esthetic demands of the patient, a monolithic colored restoration would not be acceptable. By performing a "cut back" on the facial of the bridge, we could achieve the desired esthetics and have the necessary strength. The advantage of BruxZir zirconia over other zirconia frameworks with overlay porcelain is that the lingual and occlusal surfaces do not have the opportunity to de-bond or chip.

The old bridge had metal lingual on #8 and #9 (Fig. 3) and a metal occlusal surface on tooth #14. This allowed minimal tooth reduction. Using BruxZir allows us to use the same minimal reduction, as low as 0.5 mm, thus conserving tooth structure. In addition, BruxZir allows us to have the esthetics desired with no additional reduction (Figs. 3, 4).

If using a zirconia framework system that required full-contour porcelain, we would need to reduce tooth #14 substantially. This theoretical reduction would give a clinical height on

the prep of around 1 mm.

This would be an insufficient abutment for a bridge of this length. Minimal preparation of the tooth structure, especially on #14, makes BruxZir an ideal material.

Additional considerations were given to try to balance this smile. The patient wanted to change the anatomy of #7 and add a little more length. A veneer was added to this case on tooth #7. IPS e.max lithium disilicate by Ivoclar Vivadent was chosen for the veneer material. IPS e.max lithium disilicate is an all-ceramic material that is available in a millable block or pressable ingot using the lost wax technique. IPS e.max CAD blocks have a flexural strength of 360 MPa versus 400 MPa for the IPS e.max press ingot.

Blocks and ingots are available in various shades and levels of opacity to achieve a final shade match. A stump shade is recommended for IPS e.max due to the level of translucency. IPS e.max press was used for the veneer and is indicated for anterior crowns and bridges with one pontic as well as posterior single units. A gingival recontouring procedure to match gingival heights was performed on teeth #8 and #9 using radiosurge electrocautery.

Lab portion

This case was sent to Oral Arts Dental Laboratories, a full-service lab located in Hunstville, Ala. I took a stick bite to establish the horizontal plane along with full upper and lower impressions and bite. Once the model work was completed, the models and dies required digital scanning. BruxZir is a CAD/CAM-fabricated material and thus must be digitally designed by a technician using a digital scanner and design software.

Once the final contours and design



Fig. 1: Full face with the old bridge. (Photos/Provided by Dr. Mark McOmie)



Fig. 2: Full face with the new BruxZir bridge and IPS e.max veneer on tooth #7.

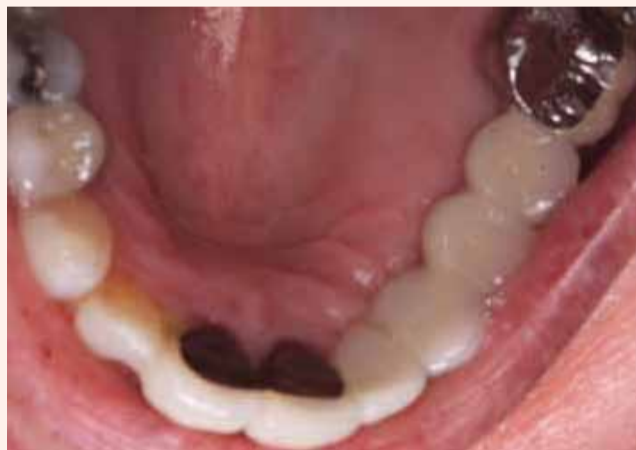

Fig. 3: Lingual of old bridge with metal lingual and occlusal surfaces on the abutments.

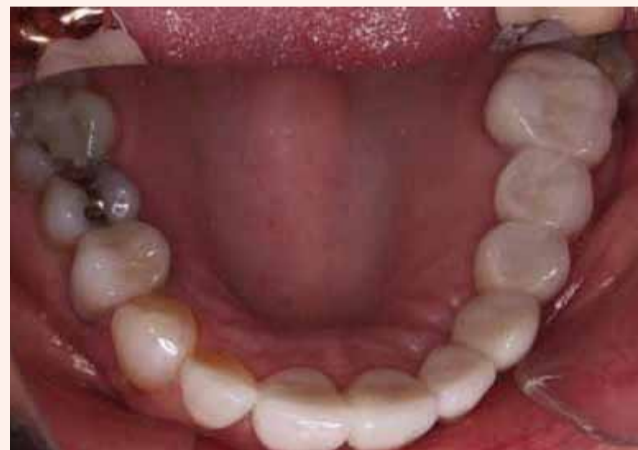

Fig. 4: Lingual of new bridge; the BruxZir material allows us to have full contour with the desired esthetics without having to reduce any more than would be required with metal.

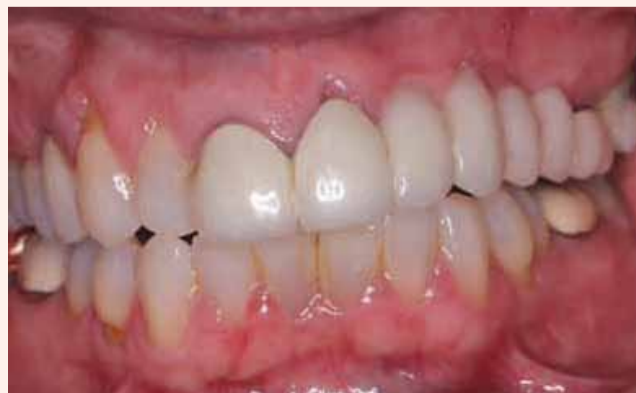

Fig. 5: Notice the porcelain repairs on the distal of tooth #8 on this old bridge.

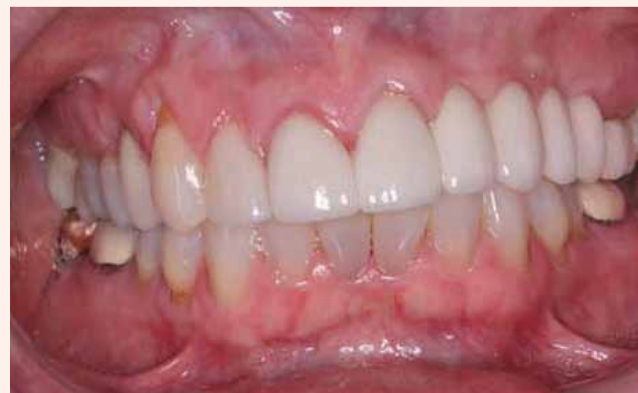

Fig. 6: Black at the gingiva is gone on this new bridge, and the gingival collar is more uniform.

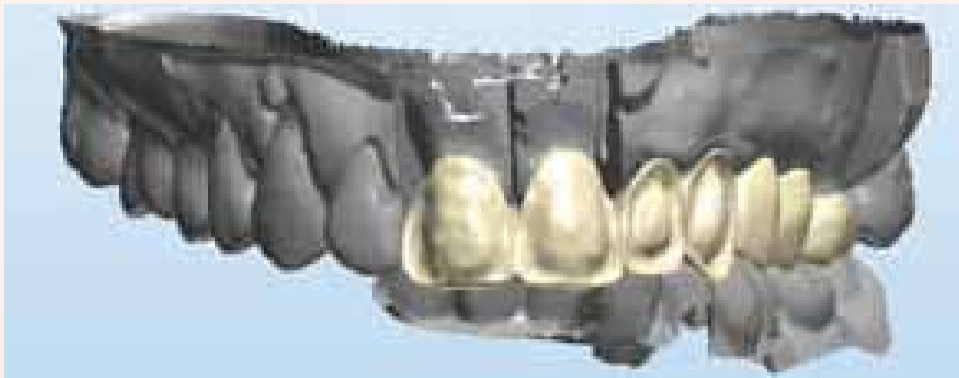

Fig.7: The screen shot of the design from Oral Arts Dental Lab in Huntsville, Ala.

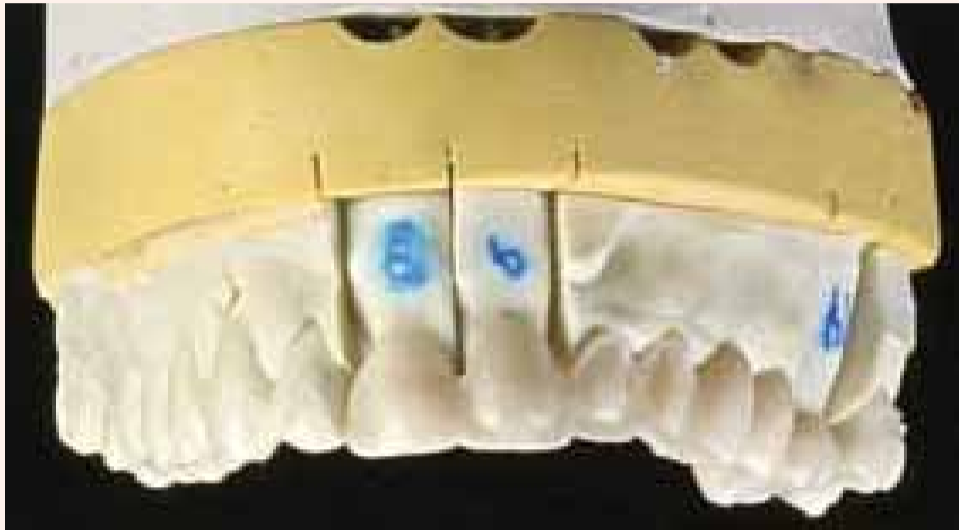

Fig.8: Full-contour zirconia cut-back to allow porcelain on the facial to increase esthetics.

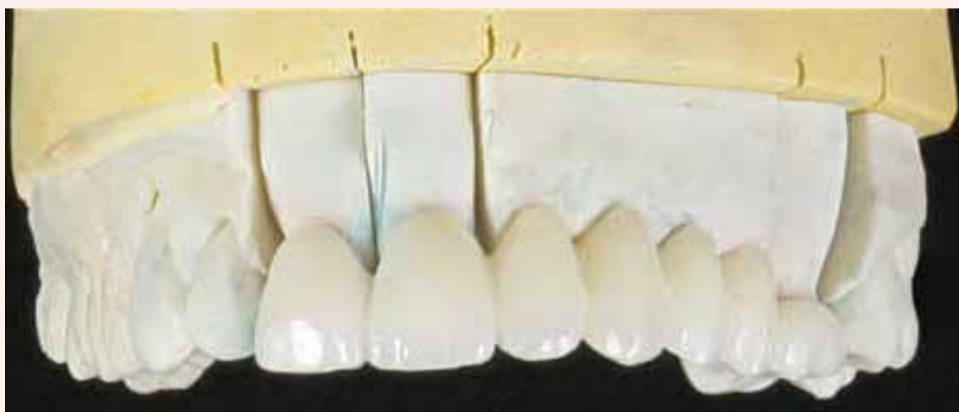

Fig.9: Porcelain facial applied to the BruxZir.

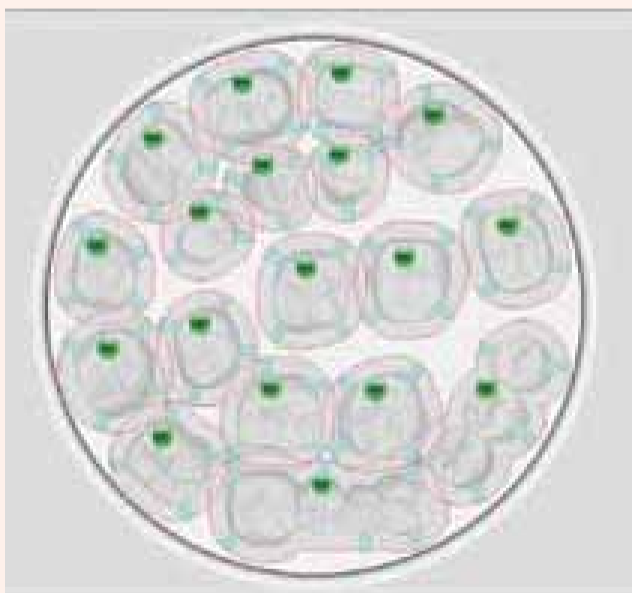


Fig.10: Layout of crowns on a design computer to be milled in BruxZir.



Fig.11: BruxZir disc with the crowns "nested" and fully milled.

are complete, the file is "nested" or positioned in the zirconia disk (Figs. 10, 11) and milled to a full contour approximately 30 percent larger than the final restoration. Once the restoration is milled and removed from the disk, it is dipped in the appropriate coloring solution and sintered in an oven for 6.5 hours at 1,530 degrees Celsius where it shrinks to its final size.

I requested that Oral Arts e-mail me the initial design for my approval before milling (Fig. 7). The case met my expectations on design and we proceeded with fabrication. On large complex cases, I enjoy the option of approving digital case design via e-mail before case completion. After the bridge framework was sintered and checked for accuracy of fit and margins (Fig. 8), IPS e.max Ceram was stacked and baked onto the facial surfaces for enhanced esthetics. IPS e.max Ceram is a stackable ceramic powder within the IPS e.max system. The veneering ceramic is the key to highly esthetic results, both on lithium disilicate and on zirconium oxide (Fig. 9).

The veneer was then waxed to a cut-back shape with mamelons, invested, burned out using the lost wax technique and pressed using IPS e.max Press lithium disilicate. Once the veneer was divested, it was layered using IPS e.max Ceram to further improve esthetics.

Final delivery and cementation

One of the challenges of cementing a case like this is the fact there are two dental materials side by side. Tooth #7

mCME SELF INSTRUCTION PROGRAM

CAPP with Dental Tribune with its mCME- Self Instruction Program gives you the opportunity to have a quick and easy way to meet your continuing education needs. mCME offers you the flexibility to work at your own pace through the material from any location at any time. The content is international, drawn from the upper echelon of dental medicine, but also presents a regional outlook in terms of perspective and subject matter.

Membership:

Take membership for one year by subscription for the newspaper: 600 AED
Take article with one newspaper subscription: 100 AED per issue.

After the payment, you will receive your membership number and will be able to start the program.

Completion of mCME

- mCME participants are required to read a continuing medical education (CME) article in each issue.
- Each article offers 2 CME Credit and followed by quiz questioner, which is available in <http://www.cappmea.com/mCME/questionnaires.html>.
- Each quiz has to be returned to events@cappmea.com or fax to: +97143686883 in three months from the publication date
- A minimum passing score of 80% must be achieved in order to claim credit
- Not more than two answered questions can be submitted in the same time
- Validity of the article – three months
- Validity of the subscription – one year
- Collection of Credit hours: you will receive the summary report with Certificate maximum one month after expire date of your membership. For single subscription Certificate and summary report will be sent one month after the publication of the article.

The answers and critiques published herein have been checked carefully and represent authoritative opinions about the questions concerned.

Articles are available in www.cappmea.com after the publication. For more information please contact events@cappmea.com or +971 4 3616174

FOR INTERACTION WITH THE WRITERS FIND THE CONTACT
DETAIL AT THE END OF EACH ARTICLE.

has an IPS e.max veneer and teeth #8 and #9 will be BruxZir with porcelain facials. IPS e.max is more translucent than the BruxZir, thus allowing more visibility of the cement and tooth that is prepped.

The cement chosen for the bridge was Panavia SA Cement, a self-adhesive resin. I choose a self-adhesive resin cement for the bridge because it has ease of use in that it can be light cured, but if the light doesn't penetrate the zirconia completely it will auto cure. This gives strength but also keeps the cementing process simple; it also would work on a full crown made of IPS e.max.

The cement for the veneer was Clearfil Esthetic Cement EX, a resin cement. Veneer preps do not have a retentive and resistant form. The veneer needs to have the maximum strength that resin bonding can give. I can get light through the veneer to fully cure the cement so an auto-cure option is unnecessary. Clearfil Esthetic Cement EX is one of the strongest bonds available and will work excellently on this veneer or a full crown made from IPS e.max.

Both restorations, the veneer and bridge, were tried in and contacts and occlusion checked. The colors were very close to exact between the two restorations. Clearfil Esthetic Cement EX comes with try-in paste, so we used the try-in paste and found that Universal colored try-in paste on both the bridge and veneer made a perfect match.

K-etchant gel was used to clean both restorations; the abutments were cleaned using a prophylactic cup and simple flour pumice with no fluoride. Panavia SA Cement was placed in the bridge abutments and the bridge was placed on the teeth. There is no need for a silinating agent on BruxZir because Panavia SA Cement will bond to the zirconia. Then it was light cured in place and the excess cement cleaned off.

An advantage to this type of cement is that it gives the benefits of resin bonding, and if you can't get the curing light to the cement through the material it will auto cure in five minutes on its own, thus giving the benefit of a resin cement but the ease of use of a glass ionomer. The veneer was treated with ceramic primer before resin bonding using Clearfil Esthetic cement in the Universal shade and light cured, then the excess cement was cleaned up.

The bottom line

In 2011, many labs reported the number of metal-free restorations surpassed the number of porcelain-fused-to-metal restorations for the first time. Most of these metal-free restorations are full-contour zirconia and lithium disilicate. Porcelain-fused-to-metal restorations have reigned as the predominant tooth-colored, indirect restorations for 50 years, so they have a long, successful history.

On the other hand, BruxZir has a much shorter history and most labs have only had it available for less than four years. The demand on the dentist to place esthetic restorations that are strong and will last has led to BruxZir's large market share. Learning new ways to employ this material is a must, and new innovative techniques can evolve to meet our patients' demands.

References is available from the author. markmcomie@gmail.com

Contact Information



Mark McOmie, DMD, attended the University of Utah. While attending the university he worked as a lab technician for several years. He then furthered his education at the University of Louisville School Of Dentistry, graduating and entering private practice in 1998. McOmie has presented research at the Kentucky Dental Association, International Association of Dental Research and American Association of Dental Research. He is a member of the Tennessee Valley Dental Study Group, Chattanooga Area Dental Society, Tennessee Dental Association, and the American Dental Association. McOmie also has hospital privileges at Memorial Hospital, where he routinely presents lectures on dentistry. You may contact him at markmcomie@gmail.com.

Oral Health Benefits Of Chewing Gum

By Michael WJ Dodds, BDS, PhD,
Wm. Wrigley Jr. Company
Excerpt from paper originally
published in the Journal of the Irish
Dental Association.

The use of sugar-free gum provides a proven anti-caries benefit, but other oral health effects are less clearly elucidated. Oral health, particularly caries-reducing, benefits of sugar-free chewing gums have been well documented in many studies and reviews.¹⁻⁶ In addition, chewing gum is increasingly being viewed as a delivery system for active agents that could potentially provide direct oral care benefits. Chewing sugar-free

chewing gum promotes a strong flow of stimulated saliva, which helps provide a number of dental benefits;

- the higher flow rate promotes more rapid oral clearance of sugars;
- the high pH and buffering capacity of the stimulated saliva help neutralise plaque pH after a sugar challenge;
- studies have shown enhanced remineralisation of early caries-like lesions and ultimately prospective clinical trials have shown reduced caries incidence in children chewing sugar-free gum.

Scientific evidence shows that chewing gum has a place as an additional mode of dental disease prevention to be used in conjunction with the more traditional preventive methods.

Benefits of chewing sugar-free gum

Oral clearance and saliva stimulation, plaque pH neutralisation

The major benefits of sugar-free chewing gum are mediated through oral physiology: stimulation of the salivary glands to produce a strong flow of saliva (a 10-12 fold increase over unstimulated saliva) is elicited by a combination of masticatory and gustatory stimuli.⁷ Although saliva flow rates are highest during the first five to seven minutes of chewing, when the sweeteners and flavour release is maximal, a two-fold increase in flow rate (over unstimulated flow) is maintained for as long as the gum continues to be chewed.⁸ One of the immediate short-term ef-



Michael WJ Dodds, BDS, PhD, Wm. Wrigley Jr. Company

VITA VMK Master® Innovation in the third generation!

The new VITA metal ceramic with the familiar layering you're accustomed to.



VITA shade, VITA made.

VITA

40 years. 3 letters. 1 original. For generations VMK has been the synonym for metal ceramics. With the power of the original, VITA VMK is the benchmark for easy, safe and cost-efficient handling. With VITA VMK Master this is more true than ever. Thanks to its firing temperature and chemical and physical characteristics,

VITA VMK Master is best suited for the veneering of non-precious metal alloy frameworks. Furthermore, the standard layering continues to provide the most simple handling. VITA VMK Master stands above all for one thing: quality without compromise.

www.vita-zahnfabrik.com facebook.com/vita.zahnfabrik

fects of this enhanced saliva flow is the increased clearance of sugars and food debris from the oral cavity.⁹ The higher flow rate, pH and buffer capacity of stimulated saliva further help neutralise acids found in the mouth, and in particular help raise the plaque pH.^{10,11} The short-term neutralisation of plaque pH out of the demineralisation danger zone can also be supplemented by medium-term benefits, as it has been shown that frequent chewing increases baseline (unstimulated) saliva flow rate and increases the resting plaque pH and subsequent ability of the plaque to form acid from sugar.^{12, 13} Some studies have suggested that chewing gum is better tolerated than artificial saliva for symptomatic relief of xerostomia.^{14, 15}

Remineralisation and clinical caries reductions

In addition to the pH neutralising effect, the increased rate of delivery of soluble calcium and phosphate ions from the stimulated saliva helps to remineralise surface enamel lesions, as shown in a number of in situ remineralisation studies.¹⁶⁻¹⁹ Clinical studies conducted in children who chewed gum at least three times daily for two or three years show that they have significantly lower rates of decay than children who do not chew gum.²⁰⁻²² Furthermore, these caries-reducing effects have been confirmed by systematic reviews.^{2, 5, 23} Indeed, the American Dental Association has recently provided clinical guidelines for the use of sucrose-free polyol chewing gums in high caries-risk children and adults.²³

Extrinsic stain reduction

Chewing gum can reduce extrinsic tooth stain, either by removing existing stain or inhibiting its formation,²⁴ whilst the addition of specific active agents (typically polyphosphates) may provide additional efficacy.^{25, 26} However, it should be noted that these types of claims are cosmetic and do not directly affect oral health, and the magnitude of the effect is small compared to bleaching therapies. On the other hand, accelerated oral clearance of staining agents such as tea or coffee, by chewing gum stimulated saliva could conceivably reduce the formation of extrinsic stain over time and help prolong the benefits of a dental prophylaxis. Interestingly, chewing gum has been found to counteract the short-term sensitivity associated with professionally-applied bleaching treatments,²⁷ although the mechanism of this effect is not clear.

Effects on plaque and gingivitis

There is evidence that regular use of chewing gum, in conjunction with normal oral hygiene procedures, provides a slight, but significant, reduction in plaque scores,²⁸⁻³⁰ although one other study did not show this effect.³¹ In addition, two of these stud-

ies showed effects on inflammatory parameters, such as bleeding score or gingival index.^{29, 30} A recent systematic review concluded that chewing sugar-free gum provides a small but significant reduction in plaque scores when used as an adjunct to normal plaque control measures.³² Therefore, any claims regarding effects of sugar-free gum without actives on plaque should be interpreted only as a potential adjunctive effect, not intended to substitute chewing gum as an alternative to regular brushing and flossing.

Active agents for remineralisation/caries

There have been many attempts to improve the inherent remineralising effect of chewing gum-stimulated saliva through the addition of specific active ingredients. See an overview of some of these actives below.

Specific polyol effects

Sugar-free gums are usually sweetened with polyol (sugar alcohol) sweeteners, such as sorbitol, mannitol, xylitol, or maltitol. These polyols have all been certified as safe for teeth by appropriate plaque pH testing; thus, while their inherent sweetness helps stimulate saliva, their rate of metabolism and acid production by the oral (plaque) bacteria is slow and does not cause an effective drop in the plaque pH, so the net effect is an increase in the plaque pH. There has been considerable research to test whether certain polyols show superior efficacy, but a recent systematic review²³ stated it was not possible to distinguish between benefits derived from chewing versus those associated with specific polyol effects.

Calcium and Phosphate salts

Other approaches to improving the inherent anti-caries effect of sugar free gums have focused on the use of suitable calcium or calcium phosphate salts to supplement the natural calcium and phosphate levels of saliva, raising the level of saturation of the immediate tooth environment with respect to these ions to aid remineralisation.^{33, 34} Calcium lactate added to chewing gum has also been shown to provide an enhanced remineralisation benefit.^{35, 36}

Potential negative effects of chewing gum

It is worth acknowledging that there are some concerns over chewing gum use, including its potential to be a choking hazard in young children, be subject to littering, and exert a laxative effect. Consumers should be reminded not to give gum to children younger than school age and to dispose of chewed gum responsibly. The laxative threshold of most polyol sweeteners used in gum is typically more than 15 g/day, which would require consumption of 10 or more sticks of chewing gum per day to achieve.

Conclusion

The scientific evidence supporting the non-specific benefits of chewing sugar-free gum has been reviewed and endorsed by key dental organizations across the globe including FDI (World Dental Federation), the ADA (American Dental Association) and the EFSA (European Food Safety Authority). Traditionally, preventive dentistry has focused on sugar restriction, plaque removal/oral hygiene, fluoride usage, fissure sealants and education. More recently, these approaches have been modified by improved diagnostic methods to allow early identification of disease, together with an accurate assessment of disease activity. There is an opportunity for chewing gum to be considered as another preventive modality to provide an additional layer of prevention by helping maintain the oral ecology in high and lower risk individuals and populations. Whilst it is not the intention of this article to

Oral care on-the-go.

A complete preventive oral care routine should include regular check-ups, brushing, flossing and chewing sugarfree gum when on-the-go.

Chewing Wrigley sugarfree gum for 20 minutes after meals and snacks on-the-go can help reduce tooth decay.

provide clinical guidelines for the use of sugar-free chewing gum, the aim is to inform practitioners so they can accurately answer his or her patients' questions regarding this topic and be able to provide appropriate guidance about chewing sugar-free gum and its oral health benefits when used as a complement to usual oral care regimens. While chewing gum may not be a treatment for oral diseases, by helping generate a healthy flow of saliva, it may help offset the perturbations in the oral ecology that lead to clinical disease states.

References

1. Burt BA. The use of sorbitol- and xylitol-sweetened chewing gum in caries control. *J Am Dent Assoc.* 2006 Feb;137(2):190-6.
2. Deshpande A, Jadad AR. The impact of polyol-containing chewing gums on dental caries: a systematic review of original randomized controlled trials and observational studies. *J Am Dent Assoc.* 2008 Dec;139(12):1602-14.

3. Edgar WM. Sugar substitutes, chewing gum and dental caries--a review. *Br Dent J.* 1998 Jan 10;184(1):29-32.

4. Imfeld T. Chewing gum--facts and fiction: a review of gum-chewing and oral health. *Crit Rev Oral Biol Med.* 1999;10(3):405-19.
5. Mickenautsch S, Leal SC, Yengopal V, Bezerra AC, Cruvinel V. Sugar-free chewing gum and dental caries: a systematic review. *J Appl Oral Sci.* 2007 Apr;15(2):83-8.
6. Twetman S. Consistent evidence to support the use of xylitol- and sorbitol-containing chewing gum to prevent dental caries. *Evid Based Dent.* 2009;10(1):10-1.
7. Dawes C, Macpherson LM. Effects of prolonged chewing-gums and lozenges on salivary flow rate and pH. *Caries Res.* 1992;26(3):176-82.
8. Dawes C, Kubieniec K. The effects of prolonged gum chewing on salivary flow rate and composition. *Arch Oral Biol.* 2004 Aug;49(8):665-9.
9. Fu Y, Li X, Ma H, Yin W, Que K, Hu D, Dodds MWJ, Tian M. Assess-

ment of chewing sugar-free gums for oral debris reduction: a randomized controlled crossover clinical trial. *Am J Dent.* 2012;25(2):118-22.

10. Manning RH, Edgar WM. pH changes in plaque after eating snacks and meals, and their modification by chewing sugared- or sugar-free gum. *Br Dent J.* 1993 Apr 10;174(7):241-4.
11. Park KK, Schemehorn BR, Bolton JW, Stookey GK. Effect of sorbitol gum chewing on plaque pH response after ingesting snacks containing predominantly sucrose or starch. *Am J Dent.* 1990 Oct;3(5):185-91.
12. Dodds MWJ, Hsieh SC, Johnson DA. The effect of increased mastication by daily gum-chewing on salivary gland output and dental plaque acidogenicity. *J Dent Res.* 1991 Dec;70(12):1474-8.
13. Jenkins GN, Edgar WM. The effect of daily gum-chewing on salivary flow rates in man. *J Dent Res.* 1989 May;68(5):786-90.
14. Bots CP, Brand HS, Veerman EC, Valentijn-Benz M, Van Amerongen

BM, Nieuw Amerongen AV, Valentijn RM, Vos PF, Bijlsma JA, Bezemer PD, ter Wee PM. The management of xerostomia in patients on haemodialysis: comparison of artificial saliva and chewing gum. *Palliat Med.* 2005 Apr;19(3):202-7.

15. Davies AN. A comparison of artificial saliva and chewing gum in the management of xerostomia in patients with advanced cancer. *Palliat Med.* 2000 May;14(3):197-203.
16. Creanor SL, Strang R, Gilmour WH, Foye RH, Brown J, Geddes DA, Hall AF. The effect of chewing gum use on in situ enamel lesion remineralization. *J Dent Res.* 1992 Dec;71(12):1895-900.

Full list of references is available from the author.

www.wrigleyoralcare.com