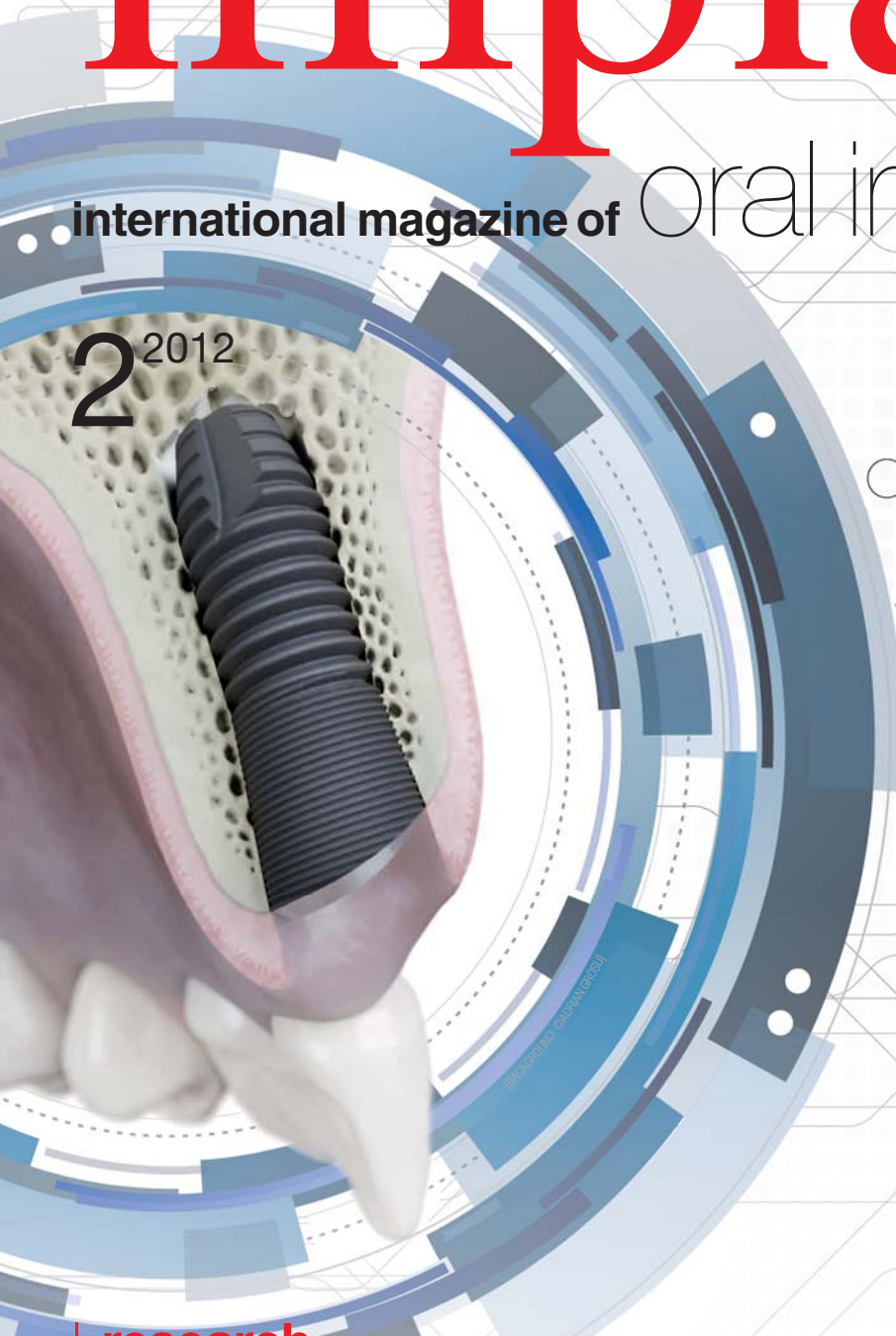

implants

international magazine of

oral implantology

2²⁰¹²



| **research**

The implant-retained bar overdenture

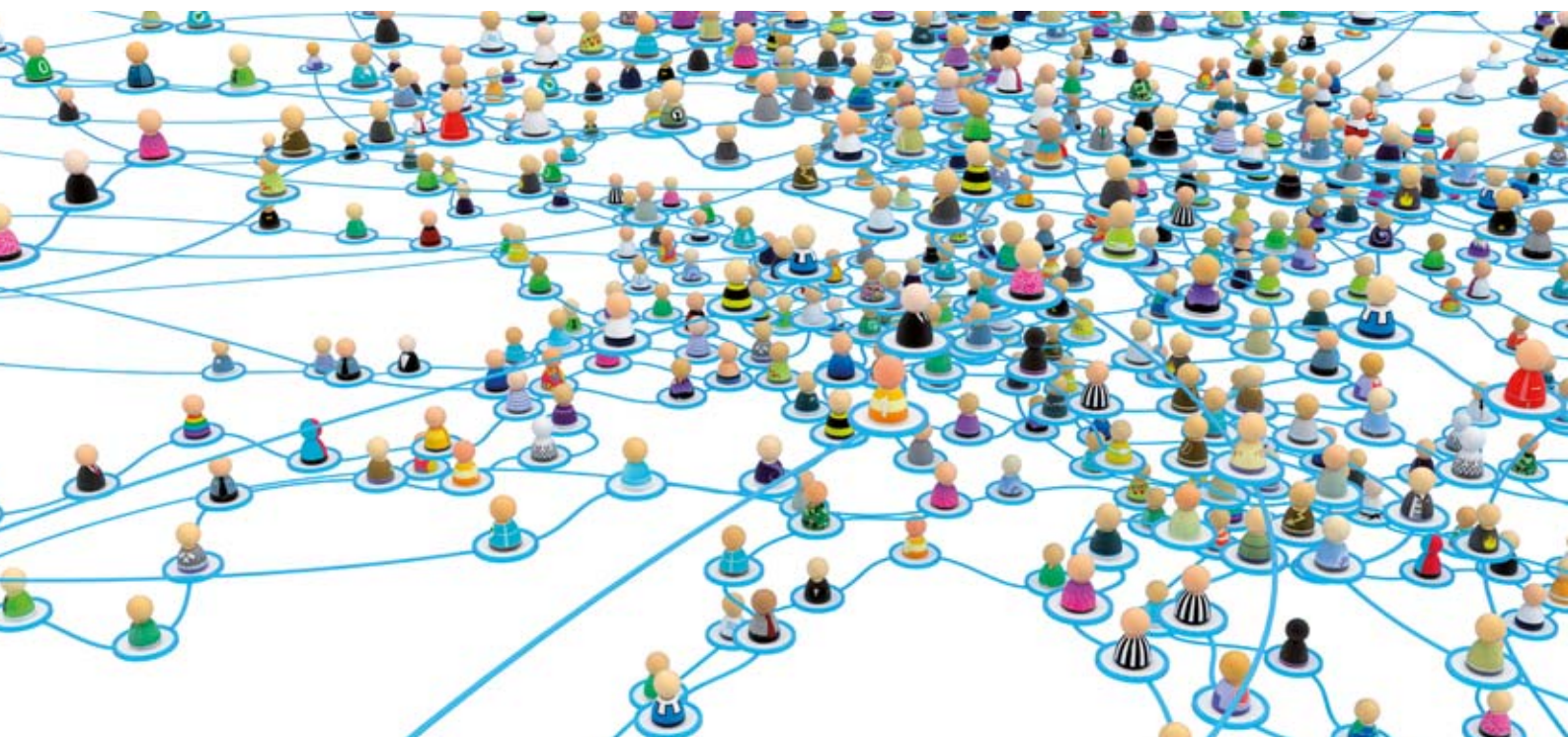| **case report**

Implantology in the atrophied alveolar ridge without augmentation

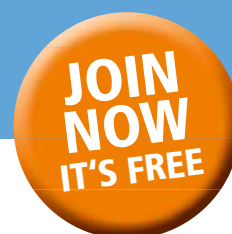| **meetings**

“Creating the future by going back to the roots”
New findings at AstraTech World Congress





CONNECTING THE CAMLOG COMMUNITY



**THE ONLINE PLATFORM FOR
CAMLOG USERS WORLDWIDE!**

CLINICAL CASES | VIDEOS | DISCUSSIONS | TUTORIALS | LEXICON



Dr. Peter Hunt,
Editor & Founder,
Camlog Connect

This site is for you. Its slogan is "By Camlog Users: For Camlog Users", and we mean it. We want you to use it, to talk about it with your colleagues, to let us know what you want more of, to ask questions and to share your own cases, problems and solutions.

TOGETHER WE CAN HELP EACH OTHER.



Laser (in)dispensable in implantology?



Dr Georg Bach

Have you been following the coverage of dental congresses in the past few weeks? If so, you might have felt just the same positive sensation as I have when I came across the fact that scientific contributions on laser applications in implantology have gained a high rank in the past congress season. By the way, the same holds true for scientific texts on implantology in dental specialist publications.

The growing impact of laser applications on both congresses and scientific literature does indeed pose a snapshot of the current status of laser in dental therapies and might even express a recent trend. This trend, in my view, bears various notable facets:

Many of the numerous implantological congresses and symposia intersecting with laser dentistry have included reports on the application of monochromatic light into their programs. Moreover, whole sessions are dedicated to laser in both implantological and periodontal congresses and symposia. On such occasions, the high value of atraumatic laser incisions with significantly reduced hemorrhage is highlighted, along with the lack of alternatives to laser surface decontamination in the treatment of periimplantitis.

As you can see, we are provided with a sufficient (and evidence-based) number of opportunities to pursue our passion for monochromatic light in implantology. It follows that our résumé be "No (more) implantology without laser"!_

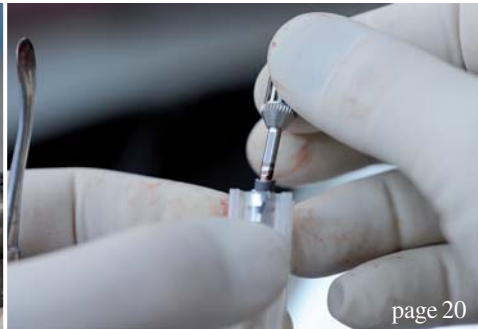With best regards,



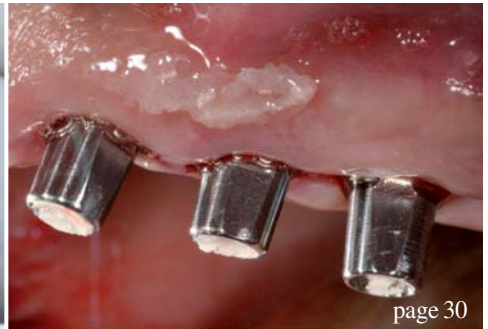Dr. Georg Bach



page 6



page 20



page 30

| editorial

03 **Laser (in)dispensable in implantology?**
| Dr Georg Bach

| research

06 **The implant-retained bar overdenture: The SFI-Bar**
| Dr Tussavir Tandra

16 **Restoration of implant supported crowns**
| Dr Igor Cemavin

| case report

20 **Implantology in the atrophied alveolar ridge without augmentation**
| Prof Dr Frank Liebaug *et al.*

26 **Bone expansion in one surgical step**
| Prof Sergio Alexandre Gehrke *et al.*

| industry report

30 **Screwed versus cemented immediately functionally loaded implants**
| Dr Luca Di Alberti *et al.*

34 **Immediate loading of the upper right lateral and central incisors**
| Prof Alessandro Pozzi

36 **One straight maxillary bridge prosthesis on three implants**
| Dr Eric Normand

| news

40 **Manufacturer News**

48 **News**

| education

43 **4th International CAMLOG Congress**
| CAMLOG Foundation

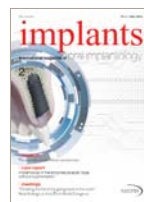44 **ITI Congresses in Switzerland and Spain make great debuts**
| ITI Center

| meetings

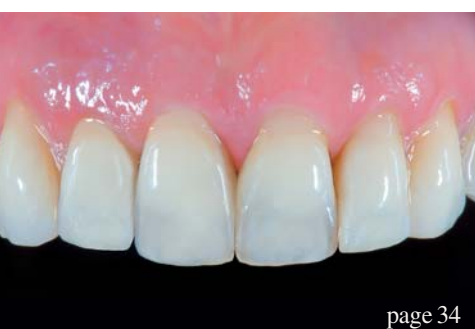46 **“Creating the future by going back to the roots”**
| Dental Tribune, AstraTech

| about the publisher

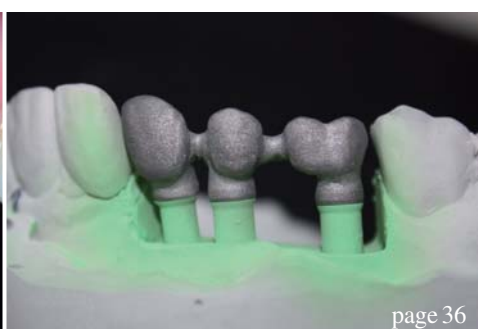50 | imprint



Cover image courtesy of Astra Tech GmbH, www.astratech.de.
Artwork by Sarah Fuhrmann, OEMUS MEDIA AG.



page 34



page 36



page 43



Behind every successful
implantologist is an Implantmed



Scan the QR code with
your mobile telephone
for more information on
Implantmed

With the new Implantmed you perform implant procedures with maximum precision. The unit is easy to operate and guarantees longer working without fatigue – thanks to the **lightweight**, yet **powerful motor** and the ergonomically-shaped contra-angle handpiece. And the integrated **thread cutter function** helps you with especially hard bone.

implantmed

The implant-retained bar overdenture: The SFI-Bar

Author_Dr Tussavir Tambra, United Kingdom

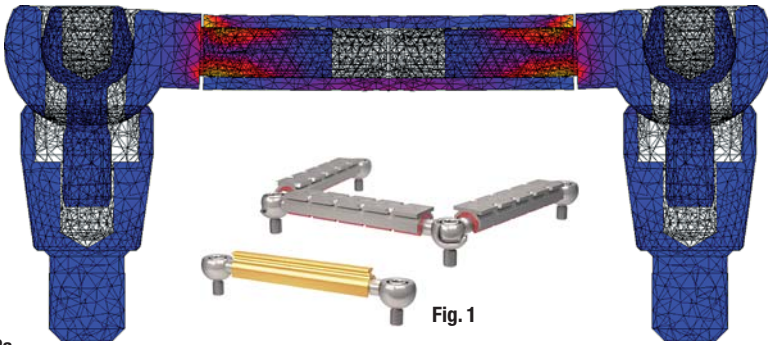


Fig. 2a

Fig. 1

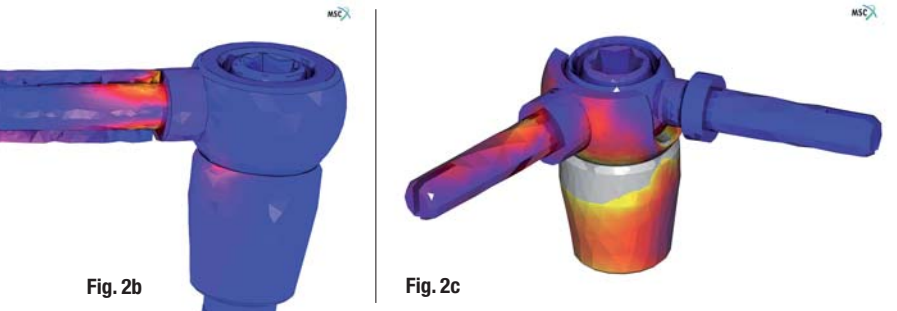


Fig. 2b

Fig. 2c

ous angulations (All-on-4, Nobel Biocare; Columbus Bridge, BIOMET 3i), has resulted in a significant uptake of treatment by edentulous patients and those with a failing dentition. This is mainly because a fixed bridge is provided and treatment times are reduced from months to hours, avoiding a conventional denture.

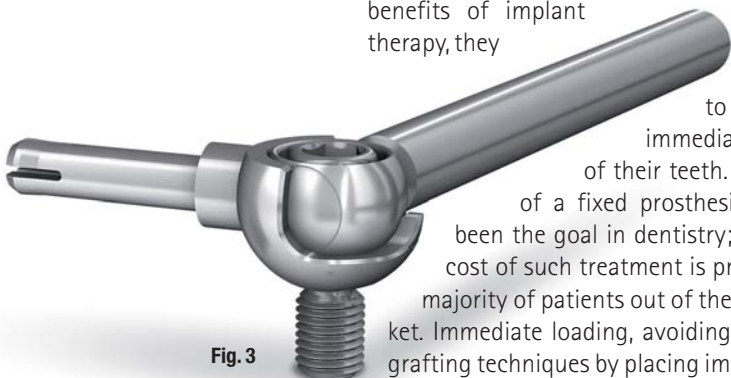
Most edentulous patients can tolerate a complete maxillary denture with few problems. The vast majority of problems arise in the mandible, where the underlying supporting tissues are not designed to function under this type of occlusal loading. Even a properly constructed complete lower denture can move as much as 10 mm in function. This continuous movement of the prosthesis results in loss of the supporting bone (or remodelling), further destabilising the denture. Poor ridge form increases denture instability and this produces more remodelling. Edentulism fulfils the WHO definition of a physical impairment.

Introduction

The advent of CAD/CAM technology and the more widespread utilisation of implants in modern dentistry have led to an explosion of treatment solutions designed to address any situation encountered by the general dentist. As patients have become more aware of the benefits of implant therapy, they

have begun to demand more immediate restoration of their teeth. The provision of a fixed prosthesis has always been the goal in dentistry; however, the cost of such treatment is pricing the vast majority of patients out of the implant market. Immediate loading, avoiding conventional grafting techniques by placing implants at vari-

Fig. 3



Treatment protocol

A simple treatment protocol was devised to treat this problem. According to this protocol, two dental implants are placed in the inter-foraminal area of the mandible, to which either a bar or stud attachments are connected to retain the lower



Fig. 4a

denture. This treatment greatly improves both masticatory efficiency and function in patients. Over the last two decades, attempts have been made to render the implant-retained overdenture the standard treatment for edentulism,¹ as demonstrated most recently by the McGill consensus.²

Prosthetic failure, usually loss of retention, and the technical difficulties encountered when relining or changing stud attachments proved to be major negative factors in dentists' attitudes towards this treatment modality. Several attempts were made to redesign and improve the attachments; however, owing to previous negative experiences, most dentists became reluctant to adopt implant-retained overdentures as a routine treatment option. The push to place more implants in an attempt to improve the situation led to the bar- and clip-retained overdenture scenario. This technique was more successful but still encountered similar issues to the stud-attachment overdentures.³

Poor stress transmission from the prosthesis to the supporting implants results in bone loss around the implants (especially the most distal implants in the multiple bar scenario), in addition to prosthetic and surgical complications.⁴ This resulted in implant companies and clinicians moving away from the two implant-retained overdenture treatment option in favour of fixed solutions, such as round-house bridges fixed on four or more implants. As a result, the vast majority of patients cannot access implant therapy owing to financial constraints. The McGill consensus brought the implant-retained overdenture back into the spotlight as a way of increasing access to implant dentistry and improving patients' quality of life. Improved component manufacturing techniques, and greater care and attention to both surgical and restorative treatment planning have significantly improved treatment outcomes using overdentures.⁵

Recently Cendres+Métaux introduced the Stress Free Implant Bar, or SFI-Bar, to the dental community. This unique, implant-platform-independent restorative bar overdenture solution allows the fabrication of a true passive-fit bar and clip system on two or more implants (Fig. 1). Finite element studies and clinical evaluation of the system have found minimal stress transmission from the prosthesis to the implants under loading (Figs. 2a-c), with most stresses being evenly distributed between the supporting implants. Vertical loads are transmitted effectively to the supporting implants, while undesirable lateral stresses are largely eliminated. More recent clinical studies have also shown it to be a viable immediate-loading treatment solution. The technique is in its infancy, so long-term (five years or more) data is not available. The SFI-Bar is a modular system that connects multiple dental implants with no soldered or laser-welded joints.

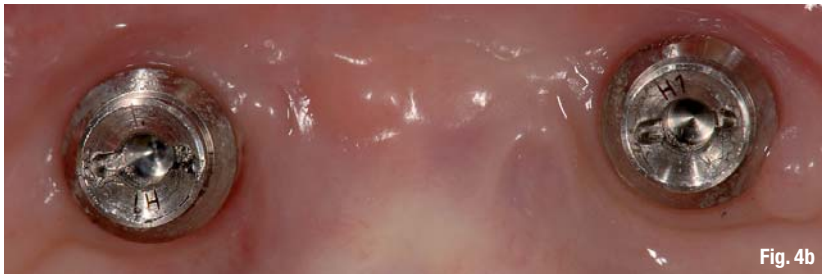

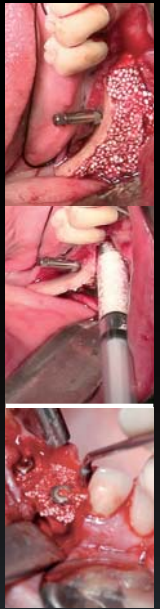Fig. 4b



Fig. 5

sticky granules

bionic



AD
easy-graft® CRYSTAL



easy-graft®
CRYSTAL

Ingenious: Simple handling and accelerated osteoconduction for long-term volume preservation.

SUNSTAR
GUIDOR®

Degradable Solutions AG
A Company of the Sunstar Group
Wagistrasse 23
CH-8952 Schlieren / Zurich
www.easy-graft.com

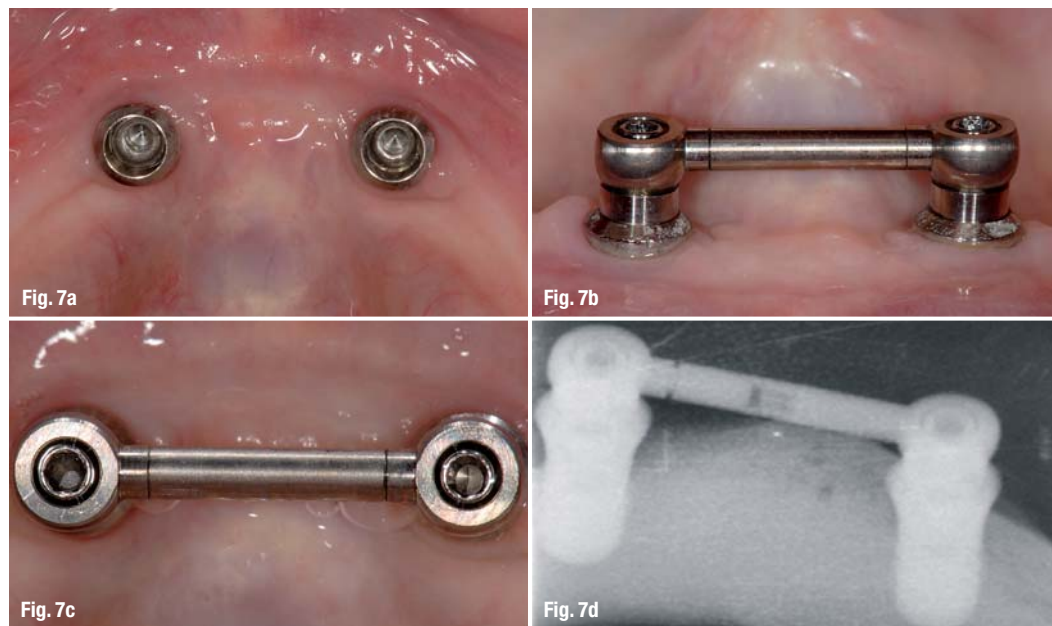


joint connection, ensuring a perfect section each time. The jig slides along the tube bar until it reaches the implant adapter, accurately sizing the bar. The tube bar is then locked in place and cut to size with a cutting disc (Fig. 6c). This process can be carried out either chair side (two-implant bar) or in the laboratory (four-implant bar or larger). An implant-level master cast will be required for cutting in the laboratory. The cutting of the tube bar must always be carried out extra-orally.

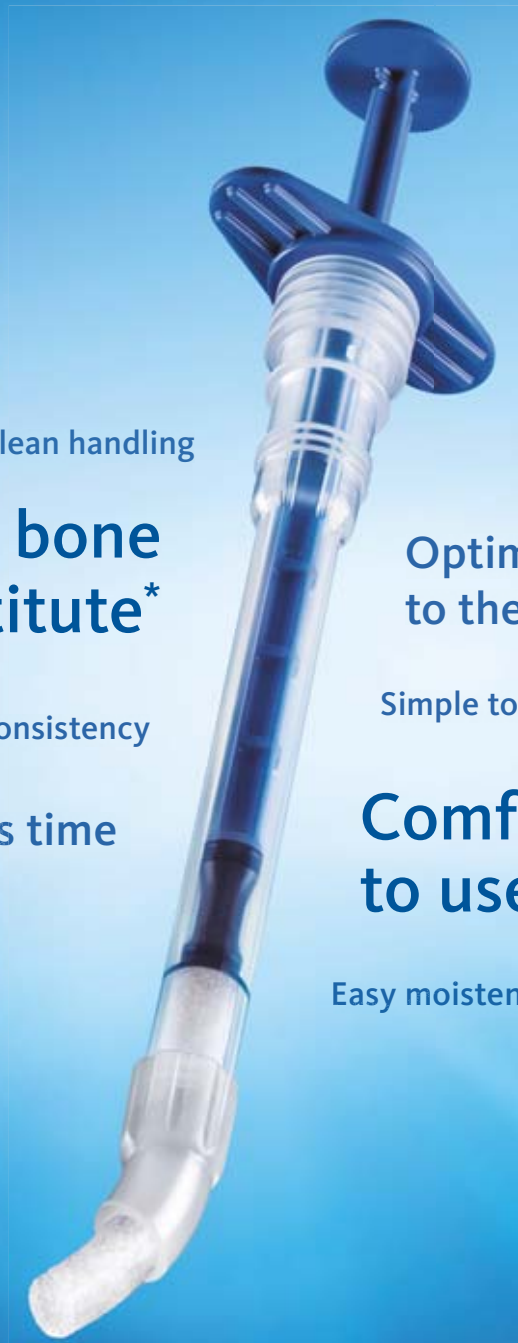Once the tube bar has been cut, the ball joints are inserted into each end of the tube bar prior to seating on the implant adapters (Figs. 7a–d) and torqued into place. The SFI-Bar is now complete and the patient is ready for the retentive element to be housed in the denture. The ball joints can accommodate non-parallel implant placement up to a maximum of 15° angulation correction. The absence of any soldered or welded joints means that a greater length of the bar can be engaged by the retentive clip. In conventional techniques, the presence of a weld increases the bar thickness, at that point preventing any retentive clip engaging that area. In the SFI-Bar, the clip engages the full length of the bar between the ball joints (Fig. 8). The bar assembly must be parallel with the occlusal plane; therefore, a selection of implant adapters of varying lengths should be available.

The minimum inter-implant distance is 8 mm and the maximum is 26 mm. This is an expandable bar system, in which add-on kits (Fig. 3) can be used to incorporate multiple implants to create a round-house bar. Implant adapter abutments are first torqued onto the implants (Figs. 4a & b). They form one half of a universal ball joint—the other half being incorporated into the bar element. The bar itself is formed by a hollow tube bar that fits onto the end of each ball joint (Fig. 5). This tube bar is cut to the correct length using a specialised jig and cutting disc (Figs. 6a–c). The jig is designed to mimic a ball

Most of the major implant companies offer CAD/CAM-fabricated bar and clip solutions. However, these bars are relatively expensive and are fabricated through a conventional impression and master cast technique. Studies have shown that 50% of all errors during impression making and cast fabrication result in non-passive fit of bars and



Nothing changed.
Just improved.



Clean handling

No. 1 bone substitute*

Optimal access to the defect

Very good consistency

Simple to use

Saves time

Comfortable to use

Easy moistening

New!

- ✓ Unwrap
- ✓ Moisten
- ✓ Use

* iData Research Inc., US Dental Bone Graft Substitutes and other Biomaterials Market, 2011.

iData Research Inc., European Dental Bone Graft Substitutes and other Biomaterials Market, 2010.

Please check for availability of this product with your country representative: www.geistlich-pharma.com

For more information visit:
www.bio-oss.com