



10 YEARS ANNIVERSARY

Ten years of successful continuing dental education: 2005 – 2015

>Page 1, 18

6TH DENTAL FACIAL

14-15 November 2014
Jumeirah Beach Hotel
DUBAI, UAE


>Insertion



MCME

Utilizing the Tempcap...
& Concepts, goals and techniques...

>Page 6-7, 10, 11, 37-38



Celebrate the 10th Anniversary at the Jumeirah Beach Hotel, DUBAI

Ten years of successful continuing dental education: 2005 – 2015

By Centre For Advanced Professional Practices

DUBAI, UAE: May 2015 will mark a significant milestone in the history of the Centre for Advanced Professional Practices (CAPP) in Dubai. CAPP will be celebrating its tenth anniversary of successful continuing dental education not only in the United Arab Emirates but also across the Middle East. Through the hard work of its colleagues, sponsors, partners and supporters, CAPP has been able to establish first-

class standards for continuing dental education programmes over the past decade. Participants and followers of CAPP programmes have also helped develop professional training according to the needs of the region with their open feedback.

CAPP is an ADA CERP-recognised provider that specialises in continuing medical and dental education programmes (conferences, hands-on courses,

> Page 18

Health authorities offer Ebola guidance for dentists

By Dental Tribune International

ATLANTA & CHICAGO, USA: In close collaboration with the Centers for

Disease Control and Prevention (CDC) and the Organization for Safety, Asepsis and Prevention, the American Dental Association (ADA) has released information for dental professionals on Ebola virus disease, which is epidemic in West Africa. Among other recommendations, it provides advice on the treatment of

patients recently returned from the region. CDC and its partners are currently working to help prevent

patients recently returned from the region.

CDC and its partners are currently working to help prevent

Ebola and other infectious diseases from being introduced into and spread in the U.S. As of

> Page 5

SOUTHERNIMPLANTS

12° 24° 36°

AVOIDING SINUS BONE GRAFTS WITH Co-AXIS SOUTHERN IMPLANTS

P.O. BOX 505190, Dubai, U.A.E.

Tel: + 971 (0)56 131 1574
Fax: + 971 (0)4 427 5011

info@southernimplants.net

www.southernimplants.com



Procter and Gamble Oral Care renews endorsement partnership with the Lebanese Dental Association in Beirut

By Crest & Oral-B

BEIRUT, Lebanon: During the 24th Beirut International Dental Meeting (BIDM 2014), held under the High Patronage of His Excellency the President of the Lebanese Parliament, Mr. Nabih Berry, a ceremony was organized to announce the renewal of the official partnership between P&G Oral Care and the Lebanese Dental Association, LDA at Biel Convention Center.

“Oral hygiene is a topic that quite often is overlooked”

Dr. Ashhad Kazi, Professional & Academic Relations Consultant – AP representing Crest and Oral B commented on the occasion: “The vision of Procter and Gamble Oral Care is to improve oral health of more people in more parts of the world more completely. This collaboration with the Lebanese Dental As-



Prof. Maalouf, President of the Lebanese Dental Association with Dr. Ashhad Kazi, Professional & Academic Relations Manager - AP for Crest & Oral-B

sociation is one of the initiatives that we are proud of and keen on sustaining.”

Professor Elie Azar Maalouf, President of Lebanese Dental Association (LDA), stressed on the advantages of such a part-

nership in benefiting the Oral Care segment in Lebanon. He added: “We are specifically thrilled about the unique benefits that this collaboration between the LDA and Crest and Oral B will provide to the retirement fund for dentists in Lebanon.”

The ceremony took place in the presence of the president and members of the Saudi Dental Syndicate, whereby Dr. Kazi presented Professor Maalouf with the newest innovation from Kormberg, Germany, a Bluetooth enabled Power Brush: The Oral-B White Pro 7000 that has just been released in the UK.

Dr. Kazi added, “Oral hygiene is a topic that quite often is overlooked and not given its due importance in our daily lives, with newer oral care technologies now at our disposal, it can be a game changer in the fight for maintaining good oral health. Crest and Oral B have a long history of high quality research as such, they offer a comprehensive line-up of toothpastes, mouthwashes, toothbrushes and flosses which provide consumers with innovative, targeted solutions designed to meet all general and specific oral care needs.”

With this collaboration for the second term, both Crest and Oral B and the Lebanese Dental Association will not only be establishing more awareness about the right routine for good oral hygiene and its maintenance, but also providing unique benefits to the retirement funds of dentists in Lebanon. ^{DT}

Contact Information

For more information contact:
Haneen Joudiyeh
PR Consultant
Impact Porter Novelli
h.joudiyeh@ipnbeirut.com.lb

DENTAL TRIBUNE

The World's Dental Newspaper - Middle East & Africa Edition

GROUP EDITOR

Daniel Zimmermann
newsroom@dental-tribune.com
+49 341 48 474 107

CLINICAL EDITOR

Magda Wojtkiewicz

ONLINE EDITORS

Yvonne Bachmann
Claudia Duschek

COPY EDITORS

Sabrina Raaff
Hans Motschmann

PUBLISHER/PRESIDENT/CEO

Torsten Oemus

CHIEF FINANCIAL OFFICER

Dan Wunderlich

BUSINESS DEVELOPMENT MANAGER

Claudia Salviczek

EVENT MANAGER

Lars Hoffmann

MARKETING SERVICES

Nadine Dehmel

SALES SERVICES

Nicole Andrá

EVENT SERVICES

Esther Wodarski

MEDIA SALES MANAGERS

Matthias Diessner (Key Accounts)
Melissa Brown (International)
Peter Witteczek (Asia Pacific)
Maria Kaiser (North America)
Veridiana Mageswki (Latin America)
Hélène Carpentier (Europe)

ACCOUNTING

Karen Hamatschek
Anja Maywald

EXECUTIVE PRODUCER

Gernot Meyer

DENTAL TRIBUNE INTERNATIONAL

Holbeinstr. 29, 04229 Leipzig, Germany
Tel.: +49 341 48 474 502
Fax: +49 341 48 474 175
info@dental-tribune.com
www.dental-tribune.com

REGIONAL OFFICES

ASIA PACIFIC
Dental Tribune Asia Pacific Ltd.
Room A, 20/F, Harvard Commercial Building,
105-111 Thomson Road, Wanchai, Hong Kong
Tel.: +852 5115 6177
Fax: +852 5115 6199

THE AMERICAS

Tribune America, LLC
116 West 25rd Street, Ste. 500, New York, N.Y. 10011, USA
Tel.: +1 212 244 7181
Fax: +1 212 244 7185

DENTAL TRIBUNE MIDDLE EAST & AFRICA

EDITION EDITORIAL BOARD

Dr. Aisha Sultan Alsuwaidi, UAE
Dr. Ninette Banday, UAE
Dr. Nabeel Humood Alsabeeha, UAE
Dr. Mohammad Al-Obaida, KSA
Dr. Meshari F. Alotaibi, KSA
Dr. Jasim M. Al-Saeedi, Oman
Dr. Mohammed Sultan Al-Darwish
Prof. Khaled Balto, KSA
Dr. Dobrina Mollova, UAE
Dr. Munir Silwadi, UAE
Dr. Khaled Abouseada, KSA
Aiham Farah, CDT
Dr. Rabih Abi Nader, UAE
Dr. George Sanoop, UAE
Retty M. Mathew, UAE
Rodny Abdallah, Lebanon
Victoria Wilson, UK

PARTNERS

Emirates Dental Society
Saudi Dental Society
Lebanese Dental Society
Qatar Dental Society
Oman Dental Society

DIRECTOR OF mCME

Dr. Dobrina Mollova
mollova@dental-tribune.me
+971 50 42 45072

DIRECTOR

Tzvetan Deyanov
deyanov@dental-tribune.me
+971 55 11 28 581

DESIGNER

Kinga Romik
k.romik@dental-tribune.me

KaVo QUATTROcare PLUS

Good care and maintenance pays-off.

NEW KaVo QUATTROcare PLUS

Efficient conservation of your handpieces' value.

- Optimum cleaning and care quality, with QUATTROcare PLUS spray
- Simple and comfortable handling and fast processing sequence
- Low initial purchase and consumables costs



KaVo. Dental Excellence.

KaVo Dental GmbH · Mobile +971 56 175 7141 · Phone +971 4 550 8600 · Fax +971 4 550 8781 · www.kavo.com/MEA

CEREC Omnicam

POWDER-FREE AND IN NATURAL COLOR.


Scanning with the new CEREC Omnicam combines powder-free ease of handling with natural color reproduction to provide an inspiring treatment experience for the patient. Discover the new simplicity of digital dentistry. **Enjoy every day. with Sirona.**



Dubai Contact: Sirona Dental Sytsems Ltd, Dr Amro Adel, Building 49, Suite 304
Dubai Healthcare City, Telephone: +971 4 375 2355, E-Mail: amro.adel@sirona.com

Kuwait Contact: Sirona Dental systems GmbH, Dr. Mostafa Al. Khouly
Office: +965 2 224 6063, Mobile: +965 9 800 2225

“CEREC Desert Fest 2014” in Dubai, UAE



Dr. Ninette Banday during the Chairside Indirect Veneers, Inlays, and Onlays: A – to – Z Table Clinic Presentation



Dr. Todd Ehrlich presenting Summer of CEREC Table Clinic Presentation



Dr. Todd Ehrlich presenting his Summer of CEREC in Dubai



Dr. Daniel Vasquez demonstrates the speed of the new CEREC Software

By Sirona

BENSHEIM, Germany: Sirona and the Centre for Advanced Professional Practices (CAPP) organized the first ever “CEREC Desert Fest”

connection between our know-how and the experiences of CEREC users in these spectacular surroundings. Professional exchanges are important for the advancement of digital dentistry. We wanted to provide a stage for

“We can proudly say that the event was a great success” - Dr. Amro Adel, Area Manager GCC, & Pakistan, Country Manager Saudi Arabia, Sirona Dental GmbH

with exciting discussions about the newest insight in digital dentistry, real-time demonstrations and an entertaining social program. The event held in Dubai from September 12–13 was aimed at both potential CAD/CAM users and experienced CEREC users.

creative discussions for dental professionals and the more than 200 guests took advantage of this opportunity. We can proudly say that the event was a great success for us and CEREC!”

The guests clearly enjoyed this new and signature networking event. Filled with entertainment, panel shows, real-time CEREC-demonstrations, desert safaris and table clinic presentations in a beautiful Arabian flavored ambience in the heart of Dubai.

Dr. Daniel Vasquez, San Diego “What a wonderful experience, we had a great time. When I started my presentation I asked how can I bring Dubai to San Diego or San Diego to Dubai; it is simple, I made many new friends and I hope I can stay in the heart of many of the attendees and of course in all of you.” **Dr.**

Volker Vellguth, Vice President Sales Russia, CIS, Middle East and Africa at Sirona: “With the CEREC Desert Fest we wanted to establish and strengthen the

Contact Information

Please visit the event’s website: <http://cerecfest.cappmea.com>.



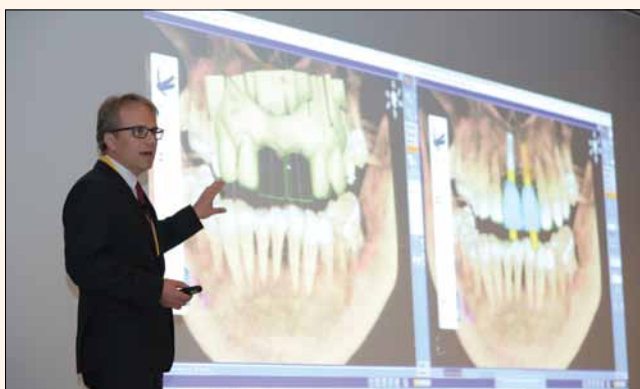The audience was well entertained at the CEREC Desert Fest in Dubai



Open Discussion between Dr. Bernd Reiss, Germany; Dr. Todd Ehrlich, USA; Dr. Daniel Vasquez, USA and Prof. Wael Att, Germany

“The guests clearly enjoyed this new signature networking event.”

“Professional exchanges are important for the advancement of digital dentistry.”



Dr. Josef Kunkela, CZ presenting CEREC meets SMILE DESIGN



The Panelists listening to questions from the audience



Exploring CEREC Omnicam with Dr. Daniel Vasquez - Table Clinic Presentation

< Page 1

Oct. 17, the ADA advises dental professionals of the following:

A person infected with Ebola is not considered contagious until symptoms appear. Owing to the virulent nature of the disease, it is highly unlikely that someone with Ebola symptoms will seek dental care when he or she is severely ill. However, according to CDC and the ADA Division of Science, dental professionals are advised to take a medical history, including a travel history, from their patients with symptoms in whom a viral infection is suspected.

As recommended by the ADA Division of Science, any person within 21 days of returning from the West African countries Liberia, Sierra Leone and Guinea may be at risk of having contacted persons infected with Ebola and may not exhibit symptoms. If this is the case, dental professionals are advised to delay routine dental care of the patient until 21 days have elapsed from their trip. Palliative care for serious oral health conditions, dental infections and dental pain can be provided if necessary after consulting with the patient's physician and conforming to standard precautions and physical barriers.

In general, providers of dental health care services should continue to follow standard infection control procedures in the clinical setting as described in CDC's 2005 Guidelines for Infection Control in Dental Health-Care Settings, the organization stated.

Signs and symptoms of Ebola include fever greater than 38.6 C or 101.5 F and severe headache, muscle pain, vomiting, diarrhea, stomach pain, or unexplained bleeding or bruising.

CDC emphasized, "The virus is spread through direct contact with blood and body fluids of an infected person, or with objects, like needles, that have been contaminated with the virus.

> Page 36

THE SEVENTH ANNUAL AMERICAN ACADEMY OF IMPLANT DENTISTRY MaxiCourse®- UAE 2015



A UNIQUE OPPORTUNITY DENTAL IMPLANTOLOGY

*In Fulfillment of the Educational Requirement for the Examination
for Associate Fellow Membership for the American Academy*

The Faculty are as follows:

Dr. Shankar Iyer, USA
Director, AAID Maxi Course@UAE
Diplomate, American Board of Oral Implantology
Clinical Assistant Professor, New York University,
College of Dentistry & UMDNJ

Dr. Ninette Banday, UAE
Manager of Dental Services, AHS-SEHA
Co-Director AAID Maxicourse- Abu Dhabi, UAE

Dr. Amit Vora, USA
Diplomate of the American Board of
Periodontology
Professor (parttime) JFK Hospital and the Veteran
Affairs (V.A.) Hospital

Dr. Jaime Lozada, USA
Director of the Graduate Program in Implant
Dentistry
Fellow, American Academy of Implant Dentistry

Dr. William Locante, USA
Diplomate of ABO/ID
Fellow of American Academy of Implant Dentistry

Dr. Frank LaMar, USA
Fellow, American Academy of Implant Dentistry
Diplomate, American Board of Oral Implantology

Dr. John Minichetti, USA
Diplomat, American Board of Oral Implantology
Honored Fellow, American Academy of Implant
Dentistry

Dr. Robert Schroering, USA
Board Certified by the American Board of Oral
Implantology
Fellow, American Academy of Implant Dentistry

Dr. James Rutkowski, USA
President – American Board of Oral
Implantology/Implant Dentistry
Acting Editor – Journal of Oral Implantology

Dr. Burnee Dunson, USA
Fellow, American Academy of Implant Dentistry
Diplomate ABOI

Dr. Stuart Orton-Jones, UK
Founder Member, The Pankey Association
Member, Alabama Implant Study Group
Director, The Stuart Orton-Jones Institute

Dr. Robert Miller, USA
Board Certified by the American Board of Oral
Implantology/Implant Dentistry
Honored Fellow American Academy of Implant
Dentistry

Dr. Hilt Tatum, France
Developer, Sinus Lift and Bone Expansion
Techniques
Diplomate, American Board of Oral Implantology
Fellow, American Academy of Implant Dentistry

Dr. Natalie Wong, Canada
Diplomate, American Board of Oral Implantology
Fellow, American Academy of Implant Dentistry

Dr. Kumar Vadivel, USA
Board Certified Periodontal Specialist

2009 Program Accredited by Health Authority-Abu Dhabi (HAAD) for 251 CME Hours
2010 Program Accredited by Health Authority Abu Dhabi (HAAD) for 258.25 CME Hours
2011 Program Accredited by Health Authority Abu Dhabi (HAAD) for 210 CME Hours
2012 Program Accredited by Health Authority Abu Dhabi (HAAD) for 224 CME Hours
2013 Program Accredited by Health Authority Abu Dhabi (HAAD) for 234 CME Hours
2014 Program Accredited by Health Authority Abu Dhabi (HAAD) for 279.25 CME Hours
2015 Program Accredited by Health Authority Abu Dhabi (HAAD) under process



Maxicourse ® Advantage	Venue & Dates
<ul style="list-style-type: none">300 hours of comprehensive lectures, live surgeries, demonstration and hands-on sessions.In depth review of surgical and prosthetic protocols.Sessions stretch across 10 months in 5 modules of 6 days. Each session is always inclusive of a weekend.Over 15 speakers from the International Community who are amongst the most distinguished names in implantology will teach the curriculum.Certificate of completion awarded by the American Academy of Implant Dentistry & HAAD.Non commercial, non sponsored course covering a wide spectrum of implant types and system.Hands-on patient treatment under direct AAID faculty supervision.	<p>SEHA- AHS Healthcare Centers Abu Dhabi University</p> <p>Module 1 25th- 30th January 2015 Module 2 30th March- 4th April, 2015 Module 3 22nd - 27th May, 2015 Module 4 2nd- 7th September, 2015 Module 5 3rd- 8th November, 2015</p>

Registration

Pre-Registration is Mandatory as it is a limited Participation Program.
For further information and registration details visit website: www.aaid-asia.org or e-mail
Dr. Ninette Banday, Dental Services Manager, Restorative Dentist & Implantologist, AHS-SEHA, Abu Dhabi
Coordinator AAID-MaxiCourse UAE at drnbanday@yahoo.com.



الخدمات العلاجية الخارجية
Ambulatory Healthcare Services

عائلة صحية. مجتمع صحي.
Healthy family. Healthy community.

www.ahs.ae



SOUTHERN IMPLANTS



7 mm
DIAMETER



8 mm
DIAMETER



9 mm
DIAMETER



ACADEMY
AWARD FOR
INNOVATION
2008



INTERNAL MORSE TAPER
EXTERNAL HEX
TRI-NEX
AVAILABLE
IN 3 DIFFERENT CONNECTIONS

IMMEDIATE MOLAR REPLACEMENT WITH MAX SOUTHERN IMPLANTS

P.O. BOX 505190, Dubai, U.A.E.

Tel: + 971 (0)56 131 1574
Fax: + 971 (0)4 427 5011

info@southernimplants.net
www.southernimplants.com



Utilizing the Tempcap abutment with CAD/CAM

Combination of Tempcap, in-office CAD/CAM and e.max allows for final restoration



mCME articles in Dental Tribune have been approved by:

HAAD as having educational content for 2 CME Credit Hours

DHA awarded this program for 2 CPD Credit Points

ADA CERP® | Continuing Education Recognition Program

Centre for Advanced Professional Practices (CAPP) is an ADA CERP Recognized Provider. ADA CERP is a service of the American Dental Association to assist dental professionals in identifying quality providers of continuing dental education. ADA CERP does not approve or endorse individual courses or instructors, nor does it imply acceptance of credit hours by boards of dentistry.

CAPP designates this activity for 2 CE credits.

By Dr. Les Kalman, USA

The E4D in-office CAD/CAM unit (Editorial note: Planmeca E4D Technologies) has been employed in an investigative laboratory study to design and mill an unconventional IPS e.max restoration that would be coupled with the Tempcap as a final implant-supported crown. The combination of the Tempcap, in-office CAD/CAM procedures and IPS e.max allows the clinician to create an immediate final restorative product with ideal characteristics.

The procedure is a simple, efficient and effective solution for the restoration of implants.

Introduction

The temporization of a dental implant following surgery, particularly in the anterior region, is a necessary procedure. The temporization allows for surgical healing, preservation of the gingival architecture and, most important, replacement of a tooth in the edentulous space for patient acceptance. Several techniques for the temporization exist, but the process has proved

to be time-consuming and frustrating. The Tempcap abutment and the process for temporization were created to provide a simple yet effective approach.¹ With the advent of CAD/CAM technology and e.max, the potential of the Tempcap to act as a final abutment seemed likely and suitable for investigation.

Background

Following the surgical placement of a dental implant, several requirements must be met to maximize healing and osseointegration of the implant body to bone:

- Minimal forces, if any, should be exerted on the implant body, permitting proper healing and preventing a non-osseous union.²
- The gingival architecture must be managed meticulously to prevent contamination, minimizing the risk of peri-implantitis and possible failure.³
- There must be sufficient time for the process of osseointegration.⁴
- Temporization and immediate restorations should not violate these factors.⁵

The Tempcap is a healing cap and restorative platform combined (Fig. 1). It has an all-metal construction, and it contains two to three retentive pin projections (Fig. 2). Tempcap is available in different widths and heights to accommodate different implant sizes (Fig. 3) and is compatible with existing instrumentation (Fig. 4).

The function of the Tempcap is:

- to allow for optimal gingival healing;
- prevent contamination of the surgical field;
- minimize forces and micro-vibrations on the implant;
- facilitate the simple yet successful restoration of the implant (Fig. 5).

CAD/CAM stands for computer-aided design and computer-aided manufacturing. CAD enables the individual to digitally capture an image of a prepared tooth or structure and then design an indirect (out of the mouth) restoration by using software.⁶

After the ideal restoration has been produced, the design is then fabricated out of a material by a milling machine. In-office

E4D units (Editorial note: Planmeca E4D Technologies) are currently available to allow for immediate chairside fabrication without the use of a commercial laboratory.

IPS e.max (Ivoclar Vivadent) is a relatively new metal-free dental material used in indirect restorations. It is an aesthetic material composed of lithium disilicate and has ideal physical and aesthetic properties, allowing it to be the first choice for CAD/CAM restorations. IPS e.max has strength second only to gold and has the ability of detailed CAM production.⁷

Methodology

The Tempcap was selected and placed on an Ankylos (DENTSPLY Implants) implant body (master cast with soft tissue) (Fig. 6). Digitization was achieved by using an E4D camera (Editorial note: Planmeca E4D Technologies) (Fig. 7), in which several images were captured to compile an accurate image (Figs. 8 & 9). CAD design was used with E4D software (Editorial note: Planmeca E4D Technologies) to determine and delineate margins (Fig. 10).

Tooth design was initiated incorporating several parameters:

- ideal aesthetics and emergence profile (Fig. 11);
- adequate proximal contacts;
- appropriate occlusal scheme;
- material thickness requirements;
- internal surface morphology to adapt to Tempcap;
- design that can be milled via CAM technology.

Numerous design iterations were required to achieve the desired design requirements (Figs. 12–14). IPS e.max was selected for milling (Fig. 15) and was executed by an E4D CAM unit (Editorial note: Planmeca E4D Technologies) (Fig. 16). Milling limitations, such as bur contact and prosthesis fracture, required CAD design modifications. Reiterations in CAD/CAM design were carried out until a successful restoration was achieved (Fig. 17).

The unfired IPS e.max crown was tried for fit and aesthetics and then subsequently fired (Fig. 18), resulting in its colour change. The crown was further stained, glazed and fired (Fig.




Fig. 1. Tempcap abutment.




Fig. 2. Retentive pins.




Fig. 3. Tempcap with Straumann implant.



Fig. 4. Use of existing instruments.




Fig. 5. Temporization form and function.

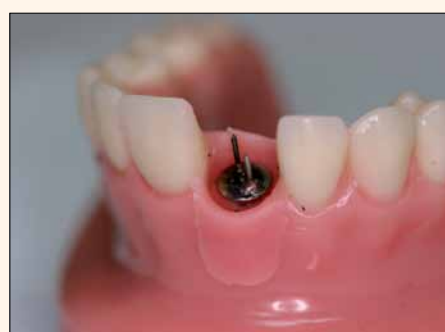

Fig. 6. Tempcap on soft-tissue model with Ankylos implant (DENTSPLY Implants).

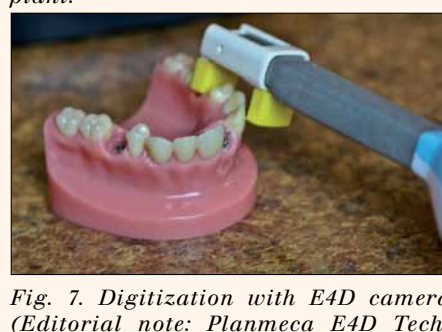


Fig. 7. Digitization with E4D camera (Editorial note: Planmeca E4D Technologies).

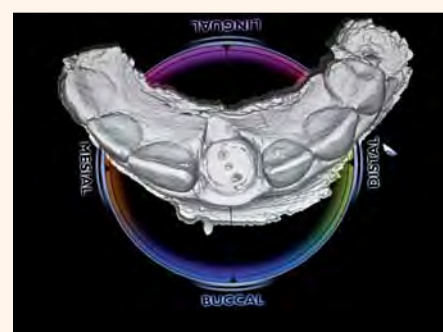

Fig. 8. Digitized images of arch.

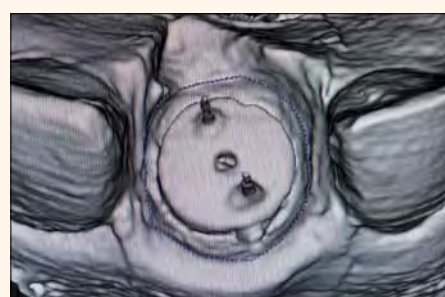


Fig. 9. Tempcap digitized.

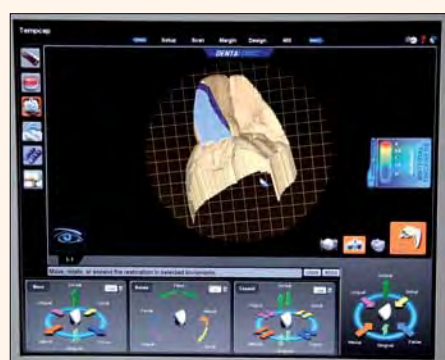


Fig. 10. Digitized delineation of Tempcap.

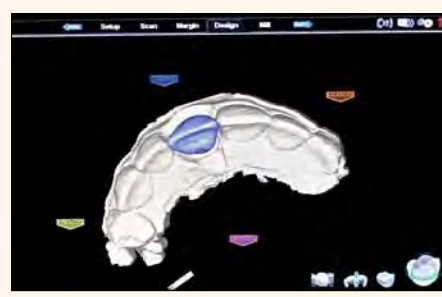

Fig. 11. Development of emergence profile.

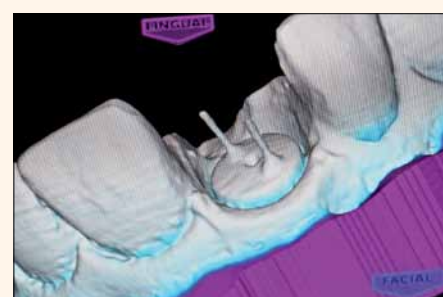


Fig. 12. Occlusal view of restoration.

< Page 6

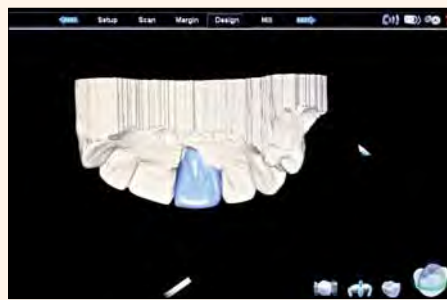


Fig. 13. Lingual view of restoration.

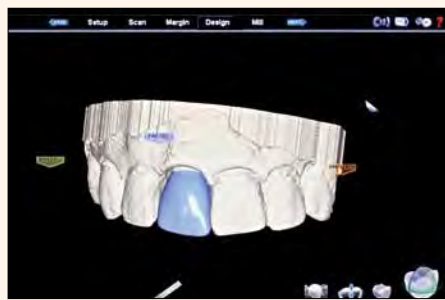

Fig. 14. Facial view of restoration.



Fig. 15. IPS e.max CAD/CAD block (Ivoclar Vivadent).




Fig. 16. E4D CAM unit (Editorial note: Planmeca E4D Technologies).

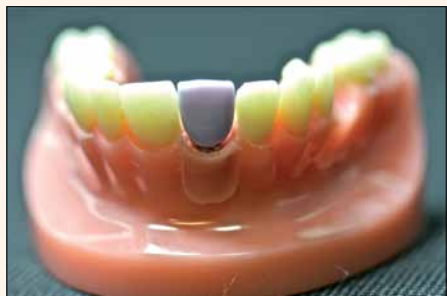

Fig. 17. Milled IPS e.max restoration.



Fig. 18. Ivoclar furnace.

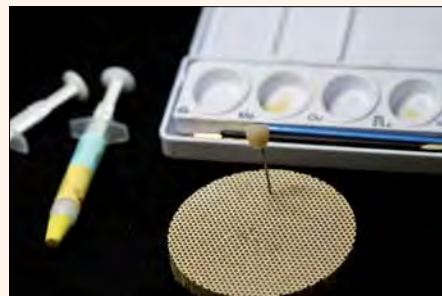

Fig. 19. Staining and glazing.

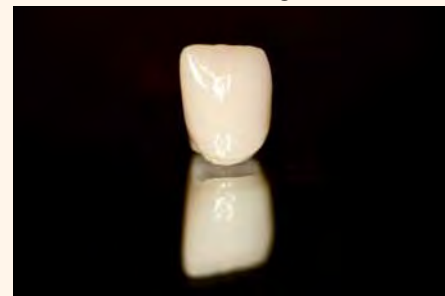

Fig. 20. Facial aspect of final restoration.

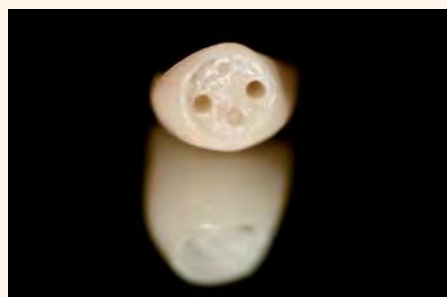

Fig. 21. Internal aspect of restoration.

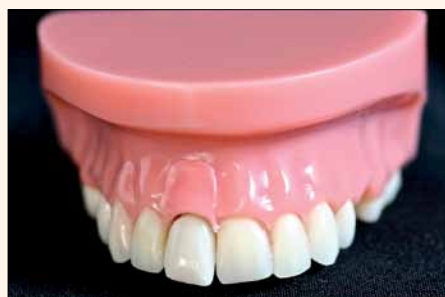

Fig. 22. Final CAD/CAM IPS e.max restoration.

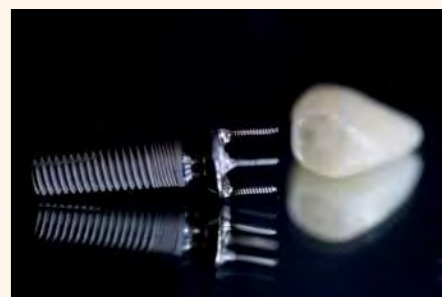

Fig. 23. Ankylos implant with complex Tempcap and milled IPS e.max crown.

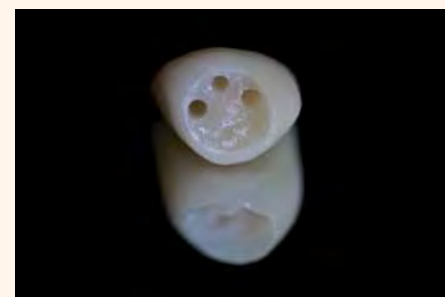

Fig. 24. Internal aspect of IPS e.max crown for three-pronged Tempcap.

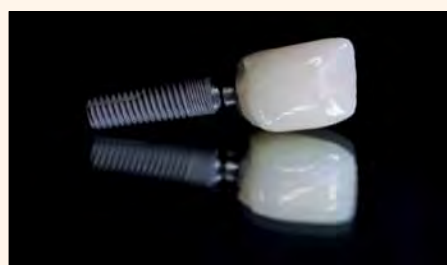

Fig. 25. Final implant-supported IPS e.max crown with Tempcap.

19), resulting in a highly aesthetic final restoration (Fig. 20). The restoration's internal aspect (Fig. 21) was assessed for path of insertion, retention and fit.

A secondary investigation utilized a more complex Tempcap to assess the limit of the CAD/CAM unit's capability. A stand-alone Ankylos (DENTSPLY Implants) implant body was coupled with a Temp-

The IPS e.max prosthetic crown was further assessed for fit, taking into account marginal fit, occlusion and proximal contacts (Fig. 22).

cap abutment with three retentive pin projections (Fig. 23). The abutment was digitized with the same methodology as described. An IPS e.max crown was executed and assessed (Figs. 24 & 25).

Discussion

This study has determined that the Tempcap can be successfully and accurately digitized and milled by in-office CAD/CAM technology (Editorial note: Planmeca E4D Technologies) to create an ideal prosthetic crown from IPS e.max within a laboratory setting. CAD software can be manipulated to generate forms beyond the scope of the unit.

Complex units, such as the three-pronged Tempcap may be successfully designed and milled. IPS e.max has the capability to be milled in complex patterns, while still maintaining its structural integrity.

However, further laboratory studies, quantitatively assessing stresses and strengths and utilizing a larger sample size, are required to validate the concept. Subsequent clinical investigations are required to assess the clinical significance and viability of the Tempcap with CAD/CAM technology. The potential to fabricate the Tempcap entirely from e.max should also be considered.

Conclusions

In-office CAD/CAM technology can be utilized and manipulated to generate digitized forms beyond the scope of the morphogenesis. CAM manufacturing has limiting factors that must be realized when producing modified prostheses. CAD modifications must account for these discrepancies. IPS e.max has the ability to be milled in extremely detailed designs.

The Tempcap can be optically scanned and digitized in order to

design and create a CAD/CAM IPS e.max restoration using E4D technology. The utilization of the Tempcap as a successful provisional abutment has been documented¹; the utility of the abutment as a simple, efficient and cost-effective component seems promising. These advances simplify the procedure and reduce the cost, ultimately allowing a greater accessibility for both patients and clinicians.

Editorial disclaimer: Dr Les Kalman is the co-owner of Research Driven and the inventor of the Tempcap.

This article was originally published in implants CE magazine 1/2013.

References

1. Kalman, L. Technique for the temporization of an anterior implant. *Dentistry Today*. 2011. Vol. 30, No.10: 128-130.
2. Mijiritsky, E., Mardinger, O., Mazor, Z. and Chaushu, G. Immediate provisionalization of single-tooth implants in fresh extraction sites at the maxillary esthetic zone: up to six years follow-up. *Implant Dentistry*. 2009. Vol. 18, No.4: 326-330.
3. Mijiritsky, E. Plastic temporary abutments with provisional restorations in immediate loading procedures: A clinical report. *Implant Dentistry*. 2006. Vol. 15, No. 3: 236-238.
4. Romanos, G. Bone quality and the immediate loading implants: critical aspects based on literature, research, and clinical experience. *Implant Dentistry*. 2009. Vol. 18, No. 3: 203-206.
5. Vela-Nebot, X., Rodriguez-Ciurana, X., Rodado-Alonso, C. and Segala-Torres, M. Benefits of an implant platform modification technique to reduce crestal bone resorption. *Implant Dentistry*. 2006. Vol. 15, No. 3: 313-318.
6. Berlin, M. Wowing the patient with chairside CAD/CAM. *Dental Economics*: 2008; 98(4): 92-96.
7. Ivoclar Vivadent: IPS e.max lithium disilicate: The Future of All-Ceramic Dentistry. 2009; 1-15. [DT](#)

> next mCME on page 10

About the Author

Dr Les Kalman, DDS, graduated from the University of Western Ontario with a doctor of dental surgery degree in 1999. He then completed a GPR at the London Health Sciences Centre. He has been involved in general dentistry within private practice since 2000. He has served as the chief of dentistry at the Strathroy-Middlesex General hospital. In 2011, he transitioned to full-time academics as an assistant professor at the Schulich School of Medicine and Dentistry. Kalman's research focuses on medical devices, including the Virtual Facebow and the Tempcap. Kalman is also the Director of the Dental Outreach Community Services (DOCS) program, which provides free dentistry within the community.

Dr Kalman has authored articles ranging from pediatric impression to immediate implant surgery in both Canadian and American journals. He has been a product evaluator for several companies, including GC America and Clinician's Choice. Dr Kalman is the co-owner of Research Driven, a company that deals with intellectual property development. He is a member of the American Society for Forensic Odontology, International Team for Implantology, Academy of Osseointegration, American Academy of Implant Dentistry and the International Congress of Oral Implantology. He has been recognized as an Academic Associate Fellow (AAID) and Diplomate (ICOI). In his spare time, Kalman enjoys photography as an accredited MotoGP photojournalist.

He can be contacted at: lkalman@uwo.ca.

mCME SELF INSTRUCTION PROGRAM

CAPP together with Dental Tribune provides the opportunity with its mCME- Self Instruction Program a quick and simple way to meet your continuing education needs. mCME offers you the flexibility to work at your own pace through the material from any location at any time. The content is international, drawn from the upper echelon of dental medicine, but also presents a regional outlook in terms of perspective and subject matter.

Membership:

Yearly membership subscription for mCME: 600 AED
One Time article newspaper subscription: 200 AED per issue.
After the payment, you will receive your membership number and Allowing you to start the program.

Completion of mCME

- mCME participants are required to read the continuing medical education (CME) articles published in each issue.
- Each article offers 2 CME Credit and are followed by a quiz Questionnaire online, which is available on <http://www.cappmea.com/mCME/questionnaires.html>.
- Each quiz has to be returned to events@cappmea.com or faxed to: +97143686883 in three months from the publication date.
- A minimum passing score of 80% must be achieved in order to claim credit.
- No more than two answered questions can be submitted at the same time
- Validity of the article - 3 months
- Validity of the subscription - 1 year
- Collection of Credit hours: You will receive the summary report with Certificate, maximum one month after the expiry date of your membership. For single subscription certificates and summary reports will be sent one month after the publication of the article.

The answers and critiques published herein have been checked carefully and represent authoritative opinions about the questions concerned.

Articles are available on www.cappmea.com after the publication. For more information please contact events@cappmea.com or +971 4 3616174

FOR INTERACTION WITH THE WRITERS FIND THE CONTACT DETAILS AT THE END OF EACH ARTICLE.

The aesthetic challenge

By Dr. Mohamed El Sayed Hassanien, Egypt

Patient's satisfaction has always been the main goal achievement of dental professionals particularly with esthetics. As the popularity of esthetic dentistry increases, a growing number of patients are seeking treatment for improvement of unaesthetic anterior dentition. Accordingly several treatment options have been proposed to restore the pleasant esthetic appearance that the patients are always seeking.

Based on the conservative approach and minimal invasive dentistry protocols, ceramic laminate veneers have been introduced to satisfy the patients growing esthetic demands.

Many construction techniques have been utilized in the dental market whether directly or in directly to fabricate ceramic laminate veneers.

CAD/CAM being state of the art dental technology offers lots of merits for both the clinician

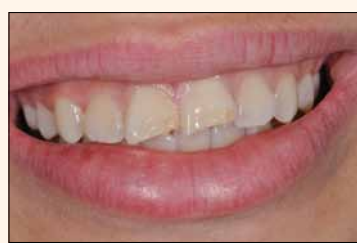

Figure 1

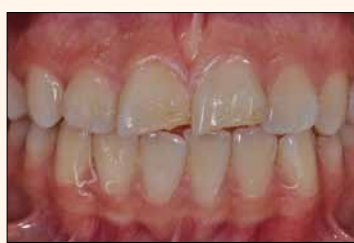

Figure 2

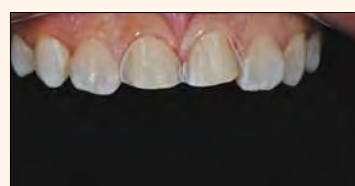


Figure 3

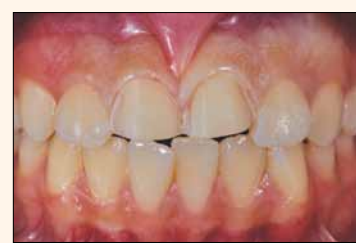

Figure 4

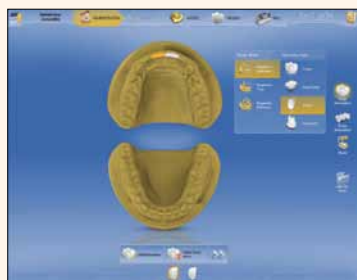

Figure 5

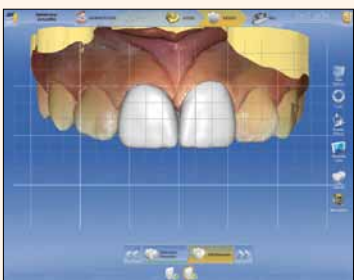


Figure 6

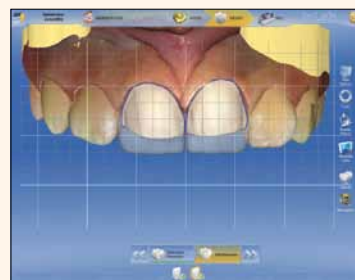


Figure 7

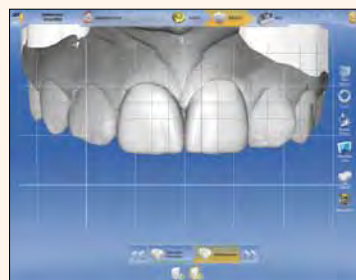

Figure 8

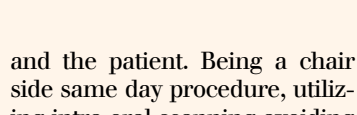


Figure 9

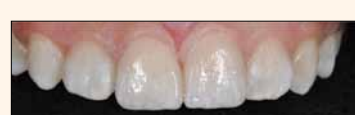

Figure 10

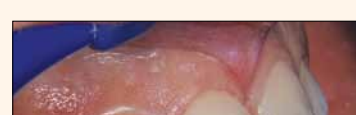

Figure 11

and the patient. Being a chair side same day procedure, utilizing intra oral scanning avoiding conventional physical impressions, and long-term provisional restorations thus producing an esthetic all-ceramic restoration with highest degrees of accuracy and precision.

Case presentation

A twelve year girl, medically healthy, denies taking any medi-

cations visited my clinic complaining of fractured upper two central incisors Fig. 1 & 2. After clinical and radiographic examination, which revealed complete root formation, two ceramic veneers for both central incisors were proposed as a treatment

option to solve her complaint.

Tooth preparation

Tooth preparations were made using the depth-guided diamond wheel no. 018 to indicate the facial reduction amount of 0.4 mm for both teeth. The labial diamond bur no. 016 was used to complete the preparation on the labial surface and precisely reproduce the cervical finish line located just below the free gingival margin Fig. 3.

Incisal preparations were made with type two-veneer preparation design ending with a butt joint on the Incisal edge and not involving the palatal wrap around.

Finally finishing bur no. 014 was used to finish and smooth all the preparation surfaces Fig. 4.

All teeth preparations were made with loupes of magnification 2.5 X for better precision.

CAD/CAM fabrication steps

In lab SW 4.2.5 was used to scan, design and mill these two veneers.

The case was administrated as two veneers on tooth number 8 and 9; with the bio-generic individual design technique, materials were selected from Ivoclar Vivadent Empress Cad Fig.5.

Intra oral scanning

Sirona Omnicam was used to scan the upper, lower and buccal catalogues to formulate the 3D virtual colored model. Margins were determined for each tooth separately and insertion axis were determined depending on their corresponding path of insertion.

Virtual design

The virtual design was proposed with the SW, both veneers were virtually linked as a group so they were both virtually active. The bio generic variation tool was used to give the best morphological proposal to match with the adjacent teeth. The Grid tool was used to show the veneers proportions to ensure

that the two veneers showed similar length to width relations Fig.6.

With the two veneers linked, restoration virtual translucency tool was used to check the amount of ceramic extension in relation to the underlying tooth preparation Fig.7.

SW 4.2 showed a new colored model tool, which enables the operator to see both veneers with the same color match for more valid size comparison Fig.8.

Shade matching

Visual shade matching was used for this case. Where the adjacent sound teeth showed A1 shade. Empress Cad blocks being a Lucite reinforced ceramic material was chosen for this case with a low translucency in order to mimic the adjacent shade of the teeth. Try in stage was done for the patient before glazing to check for proper seating and accuracy of the margins.

Glazing and characterization

Both veneers were seated properly with the object to fix putty material for better handling during glaze and stain process.

Empress Cad paste glaze was the material of choice for glazing the two veneers. In order to match the adjacent teeth, Empress Cad white stain was used on the middle and Incisal areas in a scattered pattern with a thin brush to give the natural white stain effect. Single cycle was used for staining and glazing together Fig.9

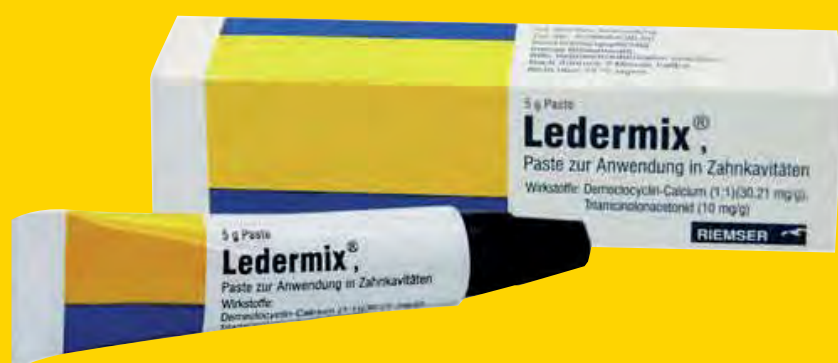Cementation procedures

• Ceramic veneer surface treatment:
HF 4 % Empress etching gel was

LEDERMIX®

RIEMSER

No more pain



Tried Tested Trusted



Dubai Medical Equipment L.L.C.

Tel : +971 6 5308055 www.dme-medical.com

KaVo MASTERsurg LUX Wireless: Redefining the best



MASTERsurg

By KaVo

With the successful launch of the EXPERTsurg LUX surgical unit and the SURGmatic instruments KaVo recently celebrated its comeback as a main player in the dental surgery field. As one of the world market leaders the dental company now presents another highlight: The MASTERsurg LUX wireless surgical unit. Thereby KaVo confirms its market position as a leading and innovative international dental player.

The new KaVo MASTERsurg now completes the attractive KaVo surgical portfolio and redefines surgical standards. Therewith all dentists and den-

tal surgeons, no matter what their different individual needs are, will find the perfect solution for their surgical work. The KaVo MASTERsurg surgical unit convinces through outstanding comfort. It is offering a wireless foot control, allowing the user a great freedom of movement. The data documentation function supports procedure by real time displaying of the torque and other important digital data and saving it concurrently.

KaVo MASTERsurg makes it

real: a customizable surgical unit that adapts to dentists' and dental surgeons' individual requirements. E.g. multiple programs, each with up to 10 treatment steps, maximum speed, maximum torque and even more parameters can individually be defined and saved.

The new INTRA LUX S600 LED, one of the lightest and smallest surgical motors in the world, enables to work with high power and precision.

When it comes to performance and comfort, KaVo continues to set the benchmark with the EXPERTsurg and the MASTERsurg controllers, the SURGmatic instruments (now available with hexagon clamping system with optimized head gearing) and the INTRA LUX S600 LED motor. All these components combine to a system for dental surgery that is not only easy to use but that provides save and highly precise tools for dentists and dental surgeons to face their daily challenges. ^{DT}



Scan & Discover

Contamct Information


KaVo Dental GmbH
Alexia Valera
9th Floor Rotana Arjaan Tower
Dubai Media City, UAE
Tel. +971 4 4332186
Mob. +971 56 1757141
E-Mail alexia.valera@kavo.com
www.kavo.com/MEA


Nobel Biocare to join Danaher dental business

By Dental Tribune International

ZURICH, Switzerland/
CHARLOTTE, N.C., USA:
Today, Danaher, a US health care conglomerate of brands from various industries, and Swiss dental manufacturer Nobel Biocare announced that the two companies have entered into a definitive transaction agreement. In order to further expand its global dental business, Danaher has offered to buy Nobel Biocare, which is the second-largest supplier of dental implants worldwide, for CHF2 billion (US\$2.1 billion).

As reported by Dental Tribune ONLINE earlier this year, Nobel Biocare confirmed that it had been approached at the end of July by third parties with a potential interest in acquiring the business. Now, the company's board of directors has unanimously decided to recommend that Nobel Biocare's shareholders accept the offer, which in-





INSTRUMENTARIUM

ORTHOPANTOMOGRAPH® OP300 Maxio

A new member of the legendary product family

- Precise positioning
- Automatic Dose Control (ADC)
- Five field-of-views (FOV)
- Low Dose Technology™ (LDT)
- Selectable resolution
- Upgradeable platform
- Professional software tools

www.instrumentariumdental.com

