

implants

international magazine of oral implantology

1 2015



| **case report**

Non-compromised aesthetics with multiple single implants in the anterior maxillae

Gingival recessions using a 3-D collagen matrix

| **research**

Aadva implant in private practice




The IMPLAnt

Clinical experience since 1963

Premium quality at a fair price

Part of the digital workflow



For more information, please visit
www.schuetz-dental.com



Schütz Dental GmbH • Dieselstr. 5-6 • 61191 Rosbach/Germany
Tel.: +49 (0) 6003 814-365 • Fax: +49 (0) 6003 814-907
www.schuetz-dental.com • export@schuetz-dental.de



Since 1963

IMPLA

The role of implantology in the upcoming years



Dr Rolf Vollmer

Dear colleagues,

"Has everything been seen before? Concepts in dental implantology"—this was the topic of the 44th annual meeting of the German Association of Dental Implantology in Düsseldorf last year. I have been active in the field of implantology since the early seventies, and I have seen many trends and designs come and go. The entire time, I was convinced that dental implantology would develop into a scientifically recognised dental discipline based on a large number of trial and error attempts. This vision was realised in 1982 when implantology was formally recognised as an advanced field in dentistry by the Deutsche Gesellschaft für Zahn-, Mund- und Kieferheilkunde (German Association of Oral and Maxillofacial Dentistry). Nowadays, implantology is formally recognised as a dental discipline.

Considering the current trends, particularly in geriatric dentistry, it becomes obvious that implantology will play an important role in the rehabilitation of older patients in the next 20 years. Furthermore, in view of the increasing number of edentulous patients, there is significant potential for treating many people who can benefit from implantology.

On the one hand, a trend towards simpler and cheaper implants and treatment concepts is evident in the industry; on the other hand, even the market leaders offer special types of implants with difficult implantation procedures at excessively high prices. As a logical consequence, treatment can be very expensive owing to high material costs. This is in contrast to treatment concepts like "All-on-4®", on which multicentre studies have been conducted, that are promoted to make implants and their benefits affordable for more patients on a social-based level.

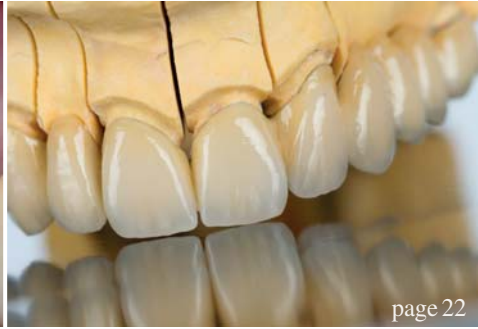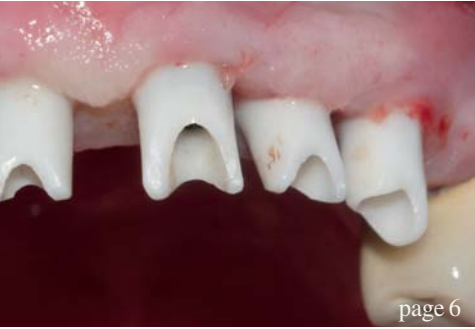In my opinion, the current development has both positive and negative aspects. I believe that it poses a particular problem for the newcomer in terms of deciding on standard, large or small, short, or mini implants, or implants of different materials, such as ceramic, as well computer-guided navigation systems. It is suggested that the smaller the implants the more easily they can be inserted into the jaw without problems, perhaps with navigation, maybe without requiring a flap procedure. Daily practice often shows us other results and veterans in our discipline will smile because they know about the problems and failures. Consider that the surgeon is not a robot and behind the implant there is a human being. Comparison here to the speed of vehicles seems fitting: exceeding the speed limit on the highway may result in a fine; exceeding the speed limit in implantology may lead to implant failure and court for the implantologist.

Let's see what the upcoming International Dental Show in Cologne will present to us.

With best regards,

Dr Rolf Vollmer

First Vice-President and Treasurer of the German Association of Dental Implantology



| editorial

03 **The role of implantology** in the upcoming years
| Dr Rolf Vollmer

| case report

06 **Non-compromised aesthetics** with multiple **single implants** in the anterior maxillae
| Dr Nikolaos Papagiannoulis *et al.*

12 **Gingival** recessions using a **3-D collagen matrix**
| Prof. Dr Gregor-Georg Zafiropoulos

| research

16 **Aadva implant** in private practice
| Dr Jean Pierre Brun *et al.*

| industry report

22 Use of a **full-arch bridge** in the **maxilla**—A case report
| Dr Dr Richard Marcelat

30 How a **modern implant** system is **developed**
| DENTSPLY Implants

32 **Straumann** provides **exclusive insights** into production site
| Claudia Duschek

| practice management

36 **Becoming Fred**—How to deliver **extraordinary results**
| Fred Heppner

| interview

38 “**DGZI** and its **training programme** is **internationally highly regarded**”
| Markus Brakel

| meetings

44 **IDS 2015** — Implantology with **innovation potential**

| obituary

46 **The man who made people smile**
| Frederic Love

| news

34 **Manufacturer News**

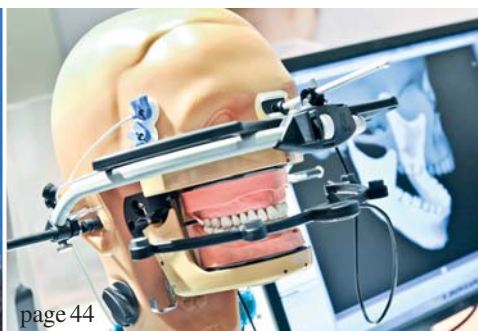48 **News**

| about the publisher

50 | imprint



Cover image courtesy of Schütz Dental GmbH
www.schuetz-dental.de
Original Background: ©style_TTT
Artwork by Sarah Fuhrmann, OEMUS MEDIA AG.





Welcome to GCTech.Europe . Gmbh
Aadva Implants & CAD/CAM Production Centre



Implants & CAD/CAM MUTUAL RESPECT



Visit us!
Hall 11.2
Stand P040

10. – 14.3.2015

GC Tech.Europe GmbH

Member of GC Group · Harkortstrasse 2, · D-58339 Breckerfeld · T: +49.2338.801980 · F: +49.2338.8019 · www.gctech.eu

Austrian Office · Tallak 124 · A-8103 Rein bei Graz · T: +43.3124.54020 · F: +43.3124.54020.40

France Office · 9 bis , avenue des Boutons d'Or BP 166 · F-94384 Bonneuil sur Marne · Tel :01.49.80.01.32 · Mail : gctech@france.gceurope.com

Non-compromised aesthetics with multiple single implants in the anterior maxillae

Authors Dr Nikolaos Papagiannoulis & Dr Marius Steigmann, Germany

_Tooth mobility is a clinical finding that indicates several difficulties regarding the treatment possibilities of the patients affected. Regardless of the mobility's cause, periodontal disease, occlusal trauma or a combination, the prosthetic rehabilitation of such patients is challenging. As this case report shows, conventional single-unit prostheses, such as full-ceramic crowns, may solve the aesthetic problems. The aesthetic outcome may be satisfactory at the beginning, but in the medium term the soft tissue will continue to retract. At the same time, the main problem will not have been resolved. Mobility, especially in cases of untreated periodontal disease, will proceed despite the prostheses, which will eventually lose functionality, and a new treatment plan will be needed.

Periodontal treatments have priority over every other treatment. Depending on the attachment loss, tooth mobility can persist, requiring a long-term stability solution. In this case report, the clinical examination found a tooth mobility of Grade II for teeth #12-23 as a result of an attachment loss that persisted even after successful conservative periodontal treatment. As mentioned, fixed prostheses are not an alternative, and fixing the teeth with a bridge would only accelerate further attachment loss, although it would reduce the occlusal load. A removable denture was not an option for the patient. An implant solution was thus deemed the only acceptable treatment. A re-

movable temporary denture was not an option for us and therefore we decided to replace each extracted tooth with an implant with immediate loading.

In such cases, surgeons have to deal with tooth loss, epithelial proliferation, bone resorption and loss of the periodontal ligament. In this case, we could clearly see in the pretreatment analysis that major bone resorption had occurred both horizontally and vertically. The bony defects affected more than one wall, but the bone resorption around the root was not infiltrated with soft tissue.

_Clinical and radiographic findings

The clinical examination found severe periodontal defects with a screening index of Grade IV, pocket depths up to 4mm and tooth mobility. The functionality was very limited and the aesthetic situation unsatisfactory. The radiographic findings confirmed that all four maxillary incisors and the left canine needed to be extracted (Figs. 1 & 2). The patient had a low scalloped gingiva with a middle thick gingival biotype, rectangular teeth and a bright smile.

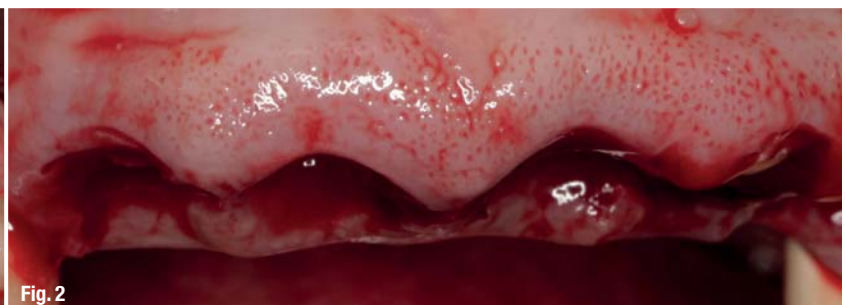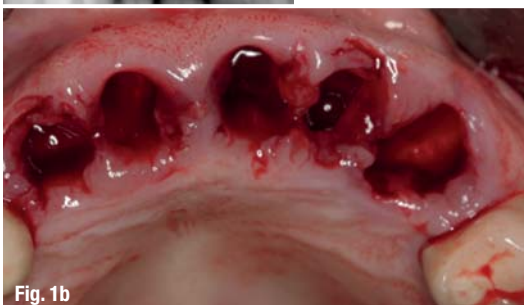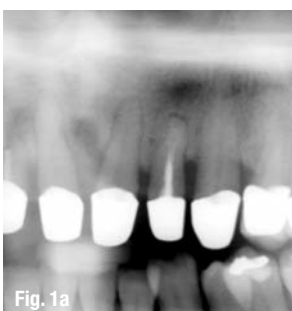
_Treatment plan

A removable denture was not acceptable, nor was a temporary or definitive denture. Although the ma-

Fig. 1a Initial situation before extraction.

Fig. 1b Extraction sockets immediately after extraction.

Fig. 2 Soft-tissue quality and anatomy after extraction.



Implant planning made easy

Planmeca PlanScan®

Planmeca ProMax® 3D

3^x
3D

Planmeca Romexis® software offers a completely integrated and digital workflow for modern implantology. From intraoral scanning to easy prosthetic design and realistic implant libraries, the most sophisticated implant planning tools are just a few clicks away.

- All the scanned and design data for prosthetic works is immediately available and can be mapped with the patient's CBCT data
- Use crown library or patient-specific crown from CAD system
- Verify the implant plan with verification tool
- Order surgical guide directly from the software
- Share data easily with partners through **Planmeca Romexis® Cloud** image transfer service



Find more info and your local dealer

www.planmeca.com



Planmeca Oy Asentajankatu 6, 00880 Helsinki, Finland
Tel. +358 20 7795 500, fax +358 20 7795 555, sales@planmeca.com

See you at **IDS 2015** in Cologne!
Hall 11.1, Stands G10/H11/H30

PLANMECA

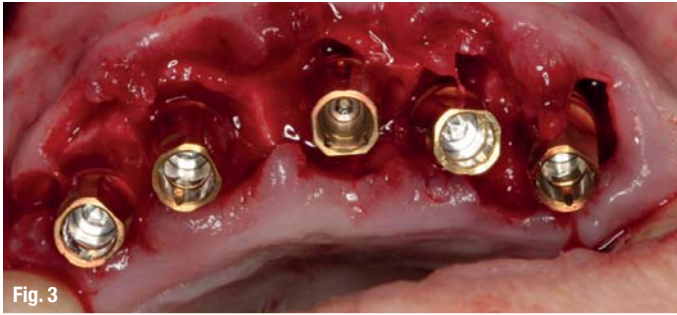


Fig. 3

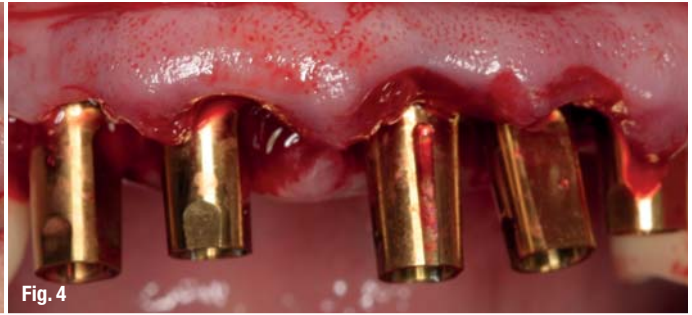

Fig. 4

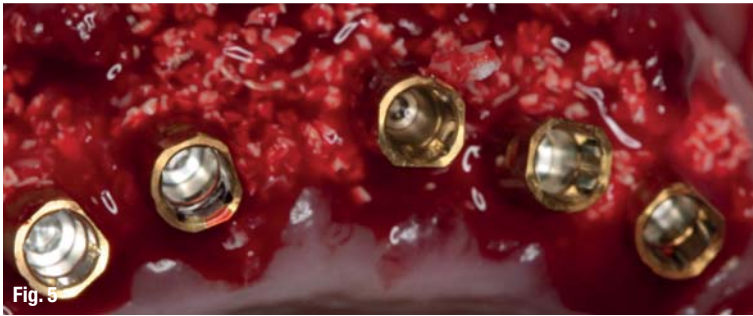


Fig. 5

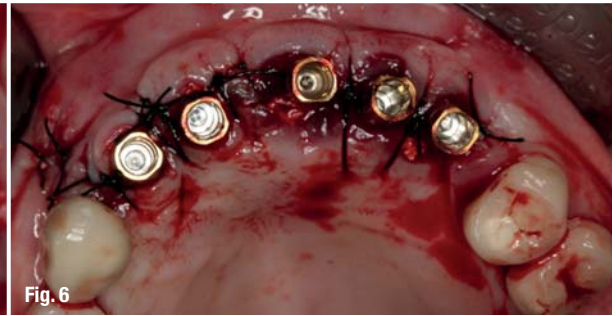

Fig. 6

Fig. 3_ Flap raising and implant insertion, showing the bone morphology after extraction.

Fig. 4_ Implant positioning, frontal view.

Fig. 5_ Guided bone regeneration: filling the gap to the buccal plate and the interproximal space.

Fig. 6_ Flap closure, coronal view.

major focus of treatment was on functional rehabilitation, aesthetics should not be underestimated in such cases. Once functionality has been obtained, the patient's attention turns to his or her appearance. The patient was to receive implants for teeth #12–23 in an immediate implantation with simultaneous guided bone regeneration. The implants were to be loaded immediately with a high-filler resin temporary bridge.

Surgery

With a wax-up on the situation model, an optimal form was created to support and manipulate soft tissue during the healing phase. At the same time, the temporary bridge functions as wound coverage if primary closure is not possible (Figs. 3–6).^{1–4}

In the next step, teeth #12–23 were extracted. The flap outline preserved the papillae of the adjacent teeth by an incision at the papilla base. Owing to the interproximal bone defects, papilla raising in this region would have led to severe recession. The vertical bone defects were obvious after raising a full-thickness flap. A releasing incision was made only mesiodistally at tooth #12 and only in attached gin-

giva to prevent scar formation through vertical cuts at the mucosa. The low vestibule made a split-thickness or periosteal pocket flap the less logical choice. Mobilising soft tissue from the lips too, through other flap designs, would have caused functional limitations, suture tension and a second gingival surgery to reposition the coronally transpositioned soft tissue. The wound margins were cut back to remove excess epithelium and the bone defects freed from soft-tissue ingrowth (Figs. 7–10).

The horizontal bone loss was moderate. The implants were placed slightly sub-crestally. Although the gap between the implants and buccal plate was due to the resorption of approximately 1–1.5 mm and the buccal plate thickness of less than 1 mm, we decided on 3.8 mm implants, leaving a 1.5 mm gap from the buccal plate.^{5–10}

The inter-implant space and the buccal plate were augmented with a combination of allograft and xenograft materials. Autologous bone obtained with a bone scraper was placed directly on the implant surface and covered with a mixture of allograft and xenograft materials. A pericardium membrane was used as barrier (Fig. 11).

Fig. 7_ Flap closure, frontal view.


Fig. 8_ Provisorium and temporary bridgework.

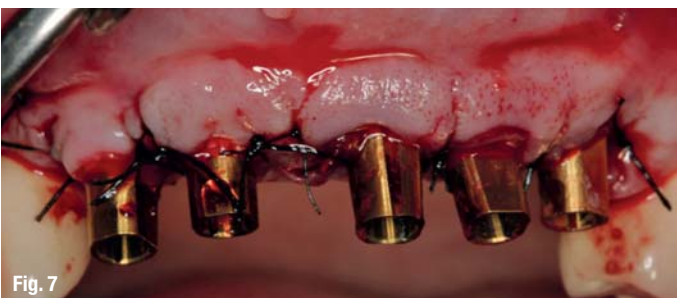

Fig. 7

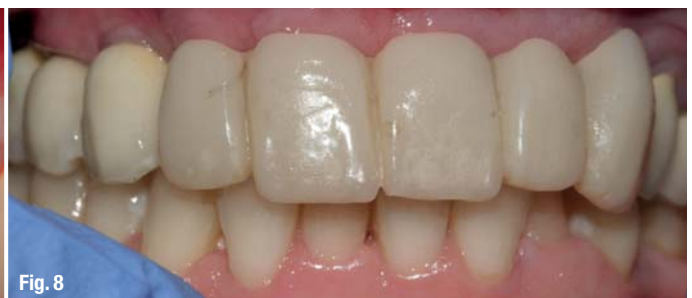

Fig. 8



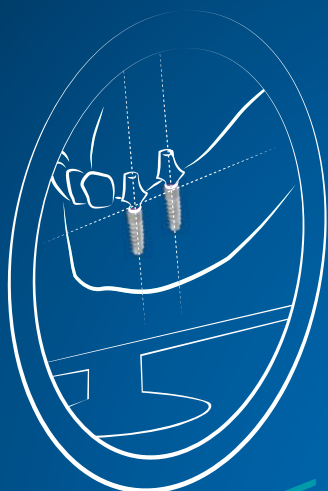
MGUIDE

Open wire-frame 3D printed surgical template allows irrigation + anesthesia from all angles. Surgical drills and tools eliminate the need for guidance keys, freeing-up hands & saving time.



MLAB

Precision CAD/CAM fabrication of customized abutments plus temporary crowns & bridges in a range of materials.



MISOFT

Highly accurate multi-level implant placement software, for more accurate surgical procedures & less chair-time.

MCENTER

**ON THE CUTTING EDGE
OF DIGITAL IMPLANT
DENTISTRY**
MAKE IT SIMPLE

MIS[®]
MCENTER

All MCENTER products and services, from the initial plan to temporary restoration, are available in one location. MISOFT, MGUIDE and MLAB systems provide doctors with optimum support for quicker, more accurate surgical procedures resulting in better esthetics, predictable outcomes and reduced chair-time. Learn more at: www.mis-implants.com

