



# DENTAL TRIBUNE

—The World's Dental Newspaper • Middle East & Africa Edition—

Printed in Dubai

[www.dental-tribune.me](http://www.dental-tribune.me)

July-August 2015 | No. 4, Vol. 4

## HYGIENE TRIBUNE

Infection control in dentistry has never been more essential



>Page 1B

## LAB TRIBUNE

Ceramill® Liquid Fx for accurate results



> Page 3C

## EVENT GALLERY

CAPP 10 years Anniversary  
10th CAD/CAM & Digital Dentistry Int'l Conference



>Insertion

## Excellence Awards in Digital Dentistry 2015

By Dental Tribune MEA/CAPPmea

On the eve of the 10th CAD/CAM & Digital Dentistry International Conference, CAPPmea celebrated its 10 year anniversary by awarding 28 dental professionals for their contributions to Digital Dentistry since the 1st event in 2005 as part of the Excellence Awards 2015. The celebrations took place under the majestic skyline of Burj Al Arab on the 'Arena' grounds of Jumeirah

Beach Hotel in Dubai. Thank you to all dentists, dental technicians and sponsors who supported us.

During the casual gala dinner party, Dr. Dobrina Mollova together with her business partner Mr. Tzvetan Deyanov showed their appreciation on behalf of CAPPmea for the support and contribution of the nominees during the last 10 years since the foundation of the company.



Winners of the Excellence Awards in Digital Dentistry 2015

The Excellence Awards in Digital Dentistry 2015 were handed out to all participants and included various prizes from the dental industry gifted by Sirona, Nikon, Philips Sonicare, Southern Implants, Dubai Medical Equipment and Oral-B.

Furthermore on behalf of CAPPmea, Dr. Dobrina Mollova awarded the pioneering companies who supported the CAD/CAM



View at Burj Al Arab during the Awards Dinner

### EXCELLENCE AWARD

Excellence Awards in Digital... 1-2

### MEDIA CME

Restoration of endodontic teeth 6-7

### ENDO TRIBUNE

Matching Gutta-percha cones 10-11

### ORAL HEALTH

Teeth and gum sensitivity effects 12

### PAEDIATRIC TRIBUNE

Paediatric Dentistry... 20-24

### IMPLANT TRIBUNE

Immediate implant placement ... 25-29

### REFERRAL CLINIC

Management of gingival recession 30-31

### PRACTICE MANAGEMENT

The seven essential habits ... 40

& Digital Dentistry International Conference since its first 2005 edition, Sirona, 3M ESPE, Zirkonzahn, Qualident and KaVo.

A full list of the winners of the Excellence Awards in Digital Dentistry 2015 can be found on [www.cappmea.com/awards2015](http://www.cappmea.com/awards2015)

> Page 2

## CAREERS

- Career Opportunities
- Job openings
- Dental Categories

[www.dental-tribune.com/careers](http://www.dental-tribune.com/careers)



## SOUTHERNIMPLANTS

### MAX Implants

### Co-Axis Implants

May Eliminate The Need For Grafting  
Shortens Treatment Time

Appropriate Emergence

Stable Enough For Immediate Restoration

## 5 Different Connections



EXTERNAL  
HEX

INTERNAL  
OCTAGON

TRI-NEX  
TRILOBE

DEEP  
CONICAL

INTERNAL  
HEX

P.O. BOX 505190, DUBAI, U.A.E.

Tel: +971 (0)56 131 1574

Fax: +971 (0)4 427 5011

[info@southernimplants.net](mailto:info@southernimplants.net) | [www.southernimplants.com](http://www.southernimplants.com)





## DENTAL TRIBUNE

—The World's Dental Newspaper— Middle East & Africa Edition —

**GROUP EDITOR**  
Daniel Zimmermann  
newsroom@dental-tribune.com  
Tel.: +49 541 48 474 107

**CLINICAL EDITOR**  
Magda Wojtkiewicz

**ONLINE EDITOR**  
**SOCIAL MEDIA MANAGER**  
Claudia Duschek

**EDITORIAL ASSISTANTS**  
Anne Faulmann  
Kristin Hübner

**COPY EDITORS**  
Sabrina Raaff  
Hans Motschmann

**PUBLISHER/PRESIDENT/CEO**  
Torsten Oemus

**CHIEF FINANCIAL OFFICER**  
Dan Wunderlich

**CHIEF TECHNOLOGY OFFICER**  
Serban Veres

**BUSINESS DEVELOPMENT MANAGER**  
Claudia Salwiczek

**JUNIOR MANAGER BUSINESS DEVELOPMENT**  
Sarah Schubert

**PROJECT MANAGER ONLINE**  
Martin Bauer

**EVENT MANAGER**  
Lars Hoffmann

**MARKETING & SALES SERVICES**  
Nicole Andrä

**EVENT SERVICES**  
Esther Wodarski

**ACCOUNTING SERVICES**  
Karen Hamatschek  
Anja Maywald  
Manuela Hunger

**MEDIA SALES MANAGERS**  
Matthias Diessner (Key Accounts)  
Melissa Brown (International)  
Antje Kahnt (International)  
Peter Witteczek (Asia Pacific)  
Weridiana Mageswki (Latin America)  
Maria Kaiser (USA)  
Hélène Carpentier (Europe)  
Barbora Solarova (Easten Europe)

**EXECUTIVE PRODUCER**  
Gernot Meyer

**ADVERTISING DISPOSITION**  
Marius Mezger

**DENTAL TRIBUNE INTERNATIONAL**  
Holbeinstr. 29, 04229 Leipzig, Germany  
Tel.: +49 541 48 474 502  
Fax: +49 541 48 474 175  
www.dental-tribune.com  
info@dental-tribune.com

**DENTAL TRIBUNE ASIA PACIFIC LTD.**  
Room A, 20/F  
Harvard Commercial Building  
105-111 Thomson Road, Wanchai, HK  
Tel.: +852 5115 6177  
Fax: +852 5115 6199

**THE AMERICA, LLC**  
116 West 23rd Street, Ste. 500, New York  
N.Y. 10011, USA  
Tel.: +1 212 244 7181  
Fax: +1 212 244 7185

**DENTAL TRIBUNE MEA EDITION EDITORIAL BOARD**  
Dr. Aisha Sultan Alsuwaidi, UAE  
Dr. Ninette Banday, UAE  
Dr. Nabeel Humood Alsabeeha, UAE  
Dr. Mohammad Al-Obaida, KSA  
Dr. Meshari F. Alotaibi, KSA  
Dr. Jasim M. Al-Saeedi, Oman  
Dr. Mohammed Sultan Al-Darwish  
Prof. Khaled Balto, KSA  
Dr. Dobrina Mollova, UAE  
Dr. Munir Silwadi, UAE  
Dr. Khaled Abouseada, KSA  
Dr. Rabih Abi Nader, UAE  
Dr. George Sanoop, UAE  
Aiham Farrah, CDT, UAE  
Retty M. Matthew, UAE

**PARTNERS**  
Emirates Dental Society  
Saudi Dental Society  
Lebanese Dental Association  
Qatar Dental Society  
Oman Dental Society

**DIRECTOR OF mCME**  
Dr. Dobrina Mollova  
mollova@dental-tribune.me  
Tel.: +971 50 42 43072

**DIRECTOR**  
Tzvetan Deyanov  
deyanov@dental-tribune.me  
Tel.: +971 55 11 28 581

**DESIGNER**  
Kinga Romik  
k.romik@dental-tribune.me

## The Winners

“The Best Educated in Digital Dentistry”  
2015 Excellence Awards

Dr. Munir Silwadi | Dr. Munir Silwadi Dental Center  
Dr. Andreas Stanke | Da Vinci Dental Clinic, Abu Dhabi  
Dr. Fadi Edward Daou | Daou Dental Clinic, Abu Dhabi  
Dr. Ghassan Mohamad Merhi | Merhi Dental And Orthodontic Center, Abu Dhabi  
Dr. Hisham Hassan Ahmed Ahmedien | Al Noor Hospital, Abu Dhabi  
Dr. K. M. Abdulsalam | Al Gharbia Hospital, Abu Dhabi  
Dr. Mohamad Iskandarani | Healthpoint Hospital, Abu Dhabi  
Dr. Omar Aloum | Al Hikma Medical Center, Abu Dhabi  
Dr. Reema Shawwa | Munir Silwadi Dental Center, Abu Dhabi  
Dr. Riad Manoir Emghaoech | Royal Specialist Medical Centre, Abu Dhabi  
Dr. Ziad Ramez Kassem | Victory Dental Clinic, Abu Dhabi  
Dr. Rabah Srouf | Al Srouf Dental Clinic, Al Ain  
Mr. Anchito Caruncho | Tawam Dental Centre, Al Ain  
Ms. Julia Gaudia Despabiladeras | Tawam Dental Centre, Al Ain  
Dr. Ammar Khanji | Netcare Clinic Center, Dubai  
Dr. Dominique Caron | Versailles Dental Clinic, Dubai  
Dr. Hussain Abdulrahman Saif Al Saleh | Ministry of Health, Dubai  
Dr. Hussein Labib | Dr. Hussein Labib Dental Clinic, Dubai  
Dr. Iyad Estoiny | GMC Clinics, Dubai  
Dr. Najia Ayoob Hassan | Al Badaa Health Clinic, Dubai  
Dr. Thomas Varghese | Belhoul Speciality Hospital, Dubai  
Mr. Houssam Faour | Ministry of Health, Dubai  
Mr. Rachwan Koutoby | Dubai Health Authority, Dubai  
Mr. Bruno Czylewicz | Drs. Nicolas & Asp Dental Clinic, Dubai  
Mr. Nestor O. Dator | American Dental Center, Dubai  
Dr. Hazza A. Alhobeira | The University Hail, Hail  
Mr. Amjad Hassan Arroub | Amjad Dental Factory, Riyadh  
Dr. Mohd Wassim Kabbani | Kabbani Specialist Medical Center, Shajah

## The Sponsors

**sirona**  
The Dental Company

**PHILIPS**  
**sonicare**  
the sonic toothbrush

**S**  
**SOUTHERNIMPLANTS**

**دبي للمعدات الطبية**  
Dubai Medical Equipment

**Crest**  
**Oral-B**

**Nikon**





# SMALL CHANGE. BIG DIFFERENCE.

The new imaging plate scanner XIOS Scan completes the intraoral family from Sirona. Whether you're taking the first steps into the digital world or establishing or updating a fully digital practice, XIOS Scan and XIOS XG Sensors offer perfectly synchronized solutions for every-workflow. **Enjoy every day. With Sirona.**



THE NEW  
IMAGING PLATE  
SCANNER:  
**XIOS Scan**

SIRONA.COM

The Dental Company

**sirona.**

# “3M ESPE innovative solutions for dental professionals”

By Dental Tribune MEA/CAPPmea

**Dental Tribune MEA/CAPPmea: 3M ESPE is based with its regional hub in Dubai. What does 3M ESPE offer dentists and dental technicians in the MEA region?**

**Elena Golubeva:** In MEA region 3M is offering wide range of dental products and solutions for direct and indirect restorations, pediatric dentistry, preventive treatment. In addition, we integrate advanced digital technology and materials science through CAD/CAM dentistry and digital impressions.

Dentists can choose from the broad portfolio of restorative materials including one of the most advanced composites on the market - Filtek™ Z350XT Universal Restorative. With over 400 million restorations globally (using Filtek™ Supreme Restorative line), Filtek™ Z350XT Universal Restorative is the one composite that can do it all. It's ideal for aesthetic anterior restorations but also strong enough for posterior restorations thanks to the true nanotechnology introduced by 3M ESPE in 2002.

In the impression category 3M ESPE offers polyether impression materials widely used by dentists all over the world and repeatedly winning various awards. Having unique product characteristics such as outstanding hydrophilicity and “snap-set” behavior the polyether materials help achieving outstanding clinical results. In combination with Pentamix™ Automatic Mixing Unit dentists can benefit from a very well-tuned system designed to provide high quality void-free mixtures and make procedure faster and more convenient.

RelyX™ Unicem resin cement family is one of the most trusted solutions in self-adhesive cementation. In 2015 Dental Advisor published results of the 5-year clinical study stating that ‘RelyX™ Unicem has proven to be an excellent and reliable self-adhesive resin cement in the five years since its introduction’. In 2015 RelyX Unicem 2 Automix Self-Adhesive Resin

Cement became Product Award Winner in the ‘Top Long Term Performer – Cement’ Category. It was evaluated by 35 consultants in 1170 uses and received a 96% rating.

These are only several examples of 3M ESPE innovative technologies for the dental industry. New products are being continually introduced by 3M ESPE to provide dentists with state-of-the-art materials for various clinical situations and dental procedures.

**How do you see the presence of 3M ESPE in the GCC market? Would you say you cover a big percentage of the market and is there room for improvement?**

3M has regional offices in UAE, Kuwait, Oman, Qatar, Saudi Arabia, and our products can be accessed via a network of approved distribution partners in most of the GCC countries. We are actively cooperating with governmental and private clinics of the region, as well as with leading dental universities and educational organizations. In different countries of the region we are having strong presence in various product categories depending on the market specific landscape and development level. Our legacy brands such as Filtek™, Ketac™, RelyX™, Impregum™, Protemp™ are very well perceived by the dental professionals and widely used across the region.

Of course, there are always untapped growth opportunities on the market. This year, for example, we are launching new products for the direct procedure making it faster and easier to create natural and beautiful looking restoration. We presented innovative solutions for the digital dentistry such as 3M™ True Definition Scanner to complement high-end Lava™ consumables for CAD/CAM dentistry.

**Do you see the Dental scene changing much in the Middle East? What are the main trends in the dental market in MEA region?**

In fact, MEA region is quite a

dynamic area open to the new technologies and solutions. Dentists are actively participating in the regional conferences and exhibitions, exchange information. Every year our Innovation Centers receive dentists from various countries of the region interested in new products and technologies.

Having done several surveys among dental professionals we saw the trend that majority highly value their time and are willing to make treatment process faster and more efficient with no compromise to the quality. Clinics move into direction of treatment standardization and seek for the cost efficient sustainable solutions.

Online communication is becoming more and more commonly used. Electronic platforms for socializing, sharing information, education are very relevant especially for a region with extensive geography. We are working on development of the modern instruments to make our on-line communication with dentists more convenient, efficient and interactive.

**3M ESPE is known for the cutting edge products constantly being developed and brought into the market. Can you list some of the strategies used to successfully market several products at a time?**

3M ESPE is constantly investing into innovation and development of the new technologies and products. Every year we introduce new solutions for the dental professionals to make their work more efficient and to help achieving predictable results.

In 2015 the Anaheim Group, distributor of Dental Fax Weekly, has recognized the 3M Company for an unprecedented tenth consecutive year as the most innovative company in the worldwide dental industry, sharing this place with Colgate-Palmolive, with 97 innovations each for 2014.

3M ESPE Dental continued its consistent performance by introducing new composite for posterior restorations using trusted nanofiller technology – Filtek™

Bulk Fill Posterior - one-step placement bulk fill material that delivers stress relief, excellent wear resistance and the ability to place up to 5 mm in one increment. By eliminating expensive dispensing devices, additional layers and multiple steps, Filtek Bulk Fill posterior restorative provides a fast and easy option for direct restorations.

And to make dental professionals more confident in the restoration results 3M ESPE introduced new Elipar™ Deep-Cure LED Curing Lights (stainless steel and plastic version with identical performance). New lights have optimized optics which creates a more even distribution of energy throughout the restoration, resulting in a complete and uniform cure from center to rim and from top to bottom.

In March 2015 at IDS, Cologne 3M ESPE also presented new glassionomer material Ketac™ Universal Glass Inonomer Restorative which provides faster and easier procedure by eliminating the need for conditioning, coating or light-curing steps. The product has extended indications versus the predecessors – restricted stress bearing Class I and Class II restorations – which makes it universal glass ionomer solution for the dental practice.

**How does 3M ESPE educate its clients in the region? Do you feel you spend enough resources to educate the clients, given the fast pace in which technology is developing?**

Customer education has always been and remains a fundamental part of 3M ESPE business model, and to help dentists stay ahead of the continual changes being made in materials and techniques, we actively carry out 3M<sup>sm</sup> Health Care Academy educational programs under Expertise™ brand. 3M Health Care Academy is providing access to high quality educational content delivered in flexible formats to suit dentist's learning style including hands-on training, live seminars and online self-study and webinars.

During such programs we cre-



Elena Golubeva, 3M ESPE Marketing Manager MEA

ate environment for a two-way exchange of knowledge and information between clinical researchers, material scientists and dental professionals. Our goal is to provide independent, objective information on the most recent innovations and trends in dentistry, the latest material developments and scientific research results.

3M ESPE is also working closely with opinion leaders from MEA region as well as with leading international speakers from various countries to provide dentists with the most recent information about new dental products and technologies. In 3M Customer Innovation Centers in UAE, Saudi, South Africa and other countries of the region we carry out a variety of dental programs for the dentists of different specializations. We have highly equipped educational areas where dentists can take part in smaller hands-on sessions or bigger educational events. Every year we conduct over 500 educational activities in MEA region. On annual basis we participate in the regional dental events such as AEEDC, SDS Conference, SADA Congress, CAD/CAM & Digital Dentistry International Conference etc. presenting new 3M ESPE products both at our booth and within the scientific program.

We are also actively cooperating with the Dental Schools providing an opportunity for younger generation of dental professionals to learn and to work with the newest 3M ESPE solutions and technologies.<sup>DT</sup>

## Glass Ionomers Get Stronger and Faster with 3M™ ESPE™ Ketac™ Universal Glass Ionomer Restorative

By 3M ESPE

Dentists know that many times caries-prone patients can be the most restless, so speed is important when treating them. Whether working with children, teens or geriatric patients, dentists need effective restorative options that can be placed quickly. Now, new 3M™ ESPE™ Ketac™ Universal Glass Ionomer Restorative gives dentists a solution with easy handling and reduced chair time, so they can get patients on their way fast with a fluoride-re-

leasing restoration that is strong enough for long-term use.

Ketac Universal Glass Ionomer Restorative is self-adhesive and self-curing, so it eliminates the need for conditioning, coating or light-curing steps, enabling an efficient procedure – just place, sculpt, and you're done. The material's low stickiness adds to its easy handling, and it can now be used for restricted stress-bearing Class I and II restorations<sup>1</sup>, thanks to its compressive strength and surface hardness. It can also be placed in bulk, elimi-

nating the need for layering, and giving dentists an economical option for a general bulk restorative material.

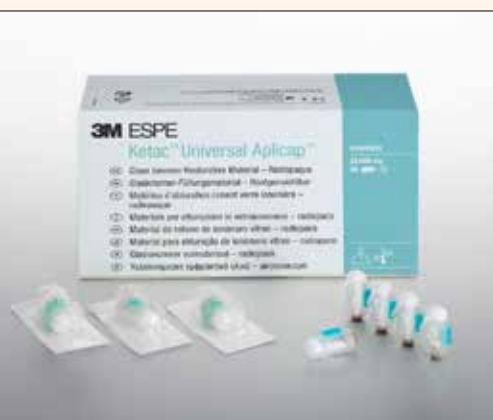The restorative is available in both Aplicap™ and handmix deliveries, as well as six shades for simple color matching. The new nozzle design of the Aplicap delivery system gives dentists better access to deep cavities, while the handmix powder is formulated to resist air humidity, making it safe to store even in high-humidity climates.

With its timesaving capabilities and easy product handling, Ketac Universal Glass Ionomer Restorative gives dentists a fluoride-releasing solution for pediatric patients, geriatric patients, and everyone in between.

For more information, visit [www.3MGulf.com/espe](http://www.3MGulf.com/espe).

### References

1. Please refer to Instructions for Use for more information. <sup>DT</sup>



Ketac™ Universal Glass Ionomer Restorative





# Finish faster. Finish strong.

## Now, get them out of the chair faster!

Pediatric. Geriatric. And busy teens in between. Treating patients who can't sit still long feels like a race against the clock—and every second counts. That's why 3M ESPE Dental developed Ketac™ Universal Aplicap™ Glass Ionomer Restorative.

- **One-step placement**—no conditioning, coating or light-curing steps to slow the procedure down
- **Stress-bearing properties** enable extended indications
- **Continuous fluoride release** over 12 months

**Ketac Universal restorative ... because the most caries-prone patients are also the most restless.**

For more information please visit:

[www.3MGulf.com/espe](http://www.3MGulf.com/espe)



**Ketac™  
Universal  
Aplicap™**

Glass Ionomer Restorative

**3M**



# Restoration of endodontic teeth: An engineering perspective



*mCME articles in Dental Tribune have been approved by:*

*HAAD as having educational content for 2 CME Credit Hours*

*DHA awarded this program for 2 CPD Credit Points*

**ADA C-E-R-P**® Continuing Education Recognition Program

Centre for Advanced Professional Practices (CAPPP) is an ADA C-E-R-P Recognized Provider. ADA C-E-R-P is a service of the American Dental Association to assist dental professionals in identifying quality providers of continuing dental education. ADA C-E-R-P does not approve or endorse individual courses or instructors, nor does it imply acceptance of credit hours by boards of dentistry.

*CAPPmea designates this activity for 2 continuing education credits.*

By Gregori M. Kurtzman, USA

## Introduction

Identifying the canals and negotiating them to be able to instrument and obturate the tooth is necessary to clinical success. But restoration of the endodontically treated tooth is critical to long-term success. It does not matter if we can complete the endodontic portion of treatment if the tooth cannot be restored. With this in mind, we need to look at the restoration phase from an engineering perspective. What is needed to reinforce the remaining tooth so that it can manage the repetitive loading that occurs during mastication? This article will discuss the importance of ferrule in adhesive dentistry as well as when to use posts and what materials are best.

## Ferrule: How important is it today?

Ferrule has long been an important concept in dentistry but has been de-emphasized with the bonding evolution. Yet this concept is as important today as it was prior to dental bonding. But what is a ferrule? A ferrule is a band that encircles the external dimension of residual tooth structure, not unlike the metal bands that exist around a barrel to hold the slats together. Sufficient vertical height of tooth structure that will be grasped by the future crown is necessary to allow for a ferrule effect of the future prosthetic crown; it has been shown to significantly reduce the incidence of fracture in the endodontically treated tooth.<sup>1,2</sup>

Important to this concept is the margin design of the crown preparation, which may include a chamfer or a shoulder preparation. Because a chamfer margin has a beveled area that is not parallel to the vertical axis of the tooth, it does not properly contribute to ferrule height. Therefore, when a chamfer is utilized it would require an additional 1 mm of height between the edge of the margin and the top aspect of the coronal portion of remaining tooth structure.

Thus, use of a chamfer may not be the best margin design when restoring endodontically treated teeth or those teeth with significant portions of missing tooth structure. With today's movement toward scanning and milling for fixed prosthetics, whether done in the practitioner's office or at the laboratory, it should be noted that it is difficult to scan the internal aspect of a shoulder preparation, and it has been uniformly recommended that a rounded shoulder be used. The rounded shoulder preparation provides the maximum vertical wall at the margin, with the internal aspect being slightly rounded versus at a 90-degree angle. This ensures better rep-

lication of the margins when scanned and milled.

Some studies suggest that while ferrule is certainly desirable, it should not be provided at the expense of the remaining tooth/root structure.<sup>5</sup> Alternatively, it has also been shown that the difference between an effective, long-term restoration and restorative failure can be as small as 1.0 mm of additional tooth structure that, when encased by a ferrule, provides greater protection.

When such a long-lasting, functional restoration cannot be predictably created, osseous crown lengthening should be considered to increase what tooth structure is available to achieve a ferrule, but this is also dependent on the periodontal status of the tooth, and when ferrule cannot be achieved then extraction should be considered.<sup>4</sup> Ichim, et al, stated succinctly, "The study confirms that a ferrule increases the mechanical resistance of a post/core/ crown restoration."<sup>5</sup>

## How much ferrule is required?

When rebuilding an endodontically treated tooth, it is best to maintain all dentin that is available, even thin slivers. These thin slivers of dentin provide a strong connecting link between the core and tooth's root and between the crown and root.<sup>6</sup>

It is important to attempt to retain as much tooth structure as possible, and this aids in achieving ferrule as well as maintaining cervical strength of the tooth where loading concentrates. Under masticatory loading, strain concentrates at the cervical portion of teeth; thus it is important to avoid over-preparation of this portion of the tooth during endodontic treatment and preserve this area during restoration of the tooth (Fig. 1).

Multiple studies discussing how much ferrule is required have found that teeth with at least 2.0 mm of ferrule have significantly greater long-term prognosis from a restorative standpoint than those with less or no ferrule. Libman, et al, reported, "Fatigue loading of cast post and cores with complete crowns of different ferrule designs provide evidence to support the need for at least a 1.5- to 2.0-mm ferrule length of a crown preparation. Crown preparation with a 0.5-mm and 1.0-mm ferrule failed at a significantly lower number of cycles than the 1.5-mm and 2.0-mm ferrules and control teeth."<sup>7</sup> Libman further demonstrated when loading at an off-axis direction, which occurs in the maxillary anterior, at the restoration's margin, the side where the load is originating is under tension, whereas the opposing side is under compression (Fig. 2). This repetitive loading and micro strain due to tension at the lingual margin leads to the margin opening, which may lead to

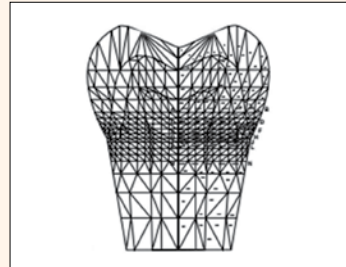


Fig. 1. Strain analysis of a posterior tooth demonstrating concentration of strain on loading at the cervical. (Image/Provided by Dr. Gene McCoy)

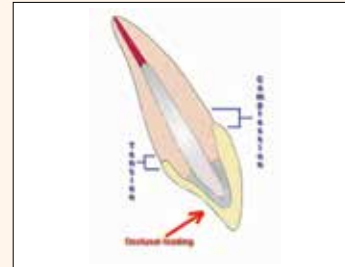


Fig. 2. As a maxillary anterior tooth is loaded during mastication, tension and compression occur at the crown's margins. (Images/Provided by Dr. Gregori M. Kurtzman)

recurrent decay and/or failure of the endodontic seal or restoration (Fig. 3).

Additionally, if we look at strain studies by Libman and others comparing ferrule of different heights, we observe that in a ferrule of 0.5 mm there is greater strain at the margin under tension and concentrates at mid tooth where the core or post is situated. Teeth with 2.0 mm of ferrule demonstrated significantly less strain loading at the margins or center of the cervical aspect of the tooth. The lower the strain at the cervical midpoint, the less chance of overload and failure restoratively (Fig. 4).

## Detecting failure at the coronal seal

It is not unusual to have a patient present for a routine recall appointment and the clinician or hygienist note recurrent decay at a crown margin with the patient unaware of the issue. This becomes more complicated with teeth that have previously undergone endodontic treatment, as there is no pulp present that could warn the patient an issue is present until often extensive decay occurs or the crown dislodges from the remaining tooth. Freeman, et al, in their published study, stated, "Fatigue loading of three different post and core designs with the presence of a full cast crown leads to preliminary failure of leakage between the restoration and tooth that is clinically undetectable."<sup>8</sup>

The literature supports that coronal leakage may be a major factor in failure of endodontic treatment.<sup>9-11</sup> As previously discussed, when loaded during mastication, margins with inadequate ferrule may demonstrate micro opening on the tension side, leading to leakage over time.

This initially may be observed as recurrent decay, but as it deepens and exposure of the obturation material results, failure of the endodontics may result due to apical migration of oral bacteria. This is minimized when a bonded core or post/core is present, but given sufficient time when a ferrule of sufficient height is not present the endodontics or the restoration will fail.

## Do all posts function the same?

Teeth function differently, depending on the material that

the post is fabricated from, with loads distributed within the root relative to the modulus of elasticity of the post compared to the dentin of the root (Fig. 5).

When a tooth restored with a fiber post does fail due to overload, the mode of failure is coronal, protecting remaining root and tooth structure.<sup>12</sup> This mode of failure with fiber-post-restored teeth typically allows the tooth to be restored, as vertical root fracture is a rare occurrence.

Bitter reported, "Compared to metal posts, FRC posts revealed reduced fracture resistance in vitro, along with a usually restorable failure mode"<sup>15</sup> (Fig. 6). Whereas, with metal posts either prefabricated or cast, failure was at a higher value for cast post and core: 91 percent of the specimens had fractured roots (none of the specimens with a fiber post demonstrated root fracture); and the post and core usually fractured at the tooth composite core interface.<sup>14</sup>

As stress concentrates at the apical tip of the metal post due to its higher modulus of elasticity than the surrounding root, vertical root fracture is a frequent occurrence (Fig. 7). This may result also from breakdown of the cement luting the post to the root, allowing slippage microscopically of the post in the tooth under load, leading to torque at the cervical area and the resulting vertical root fracture.

Because metal posts are stiffer (higher modulus of elasticity) than the dentin of the root, stress concentrates at the post's apical tip, leading to vertical root fracture and catastrophic loss of the tooth. Ansari reported, "The risk of failure was greater with metal-cast posts (nine out of 98 metal posts failed) than with carbon fiber posts (using which, none out of 97 failed) risk ratio."<sup>15</sup> But with fiber posts having a flexibility equal to or greater than the root (lower modulus of elasticity), stress concentrated at the cervical region, leading to horizontal fracture of the post and core; and typically the tooth can be salvaged.

The elastic modulus refers to the relative rigidity of the material. The stiffer the material, the higher its relative modulus. When two different materials are placed together, such as when a post is placed into a tooth's root, the elastic modulus is influenced

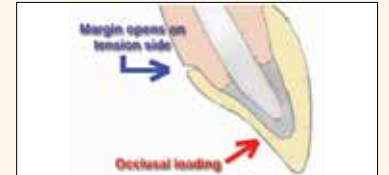

Fig. 3. Opening of the margin on the tension side may lead in time to recurrent decay or restoration and endodontic failure.

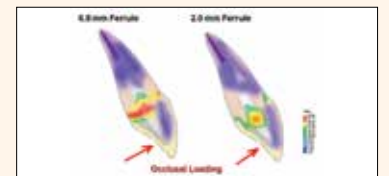


Fig. 4. Difference of intensity of strain and location related to ferrule height during occlusal loading (Libman).

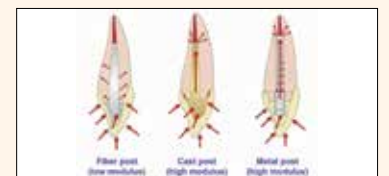


Fig. 5. Comparison of load distribution of fiber post, cast metal post and prefabricated metal post.

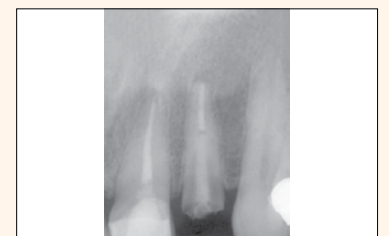

Fig. 6. Tooth restored with a fiber post demonstrating coronal horizontal fracture supracrestally; typically seen with teeth restored with fiber posts when overloaded.

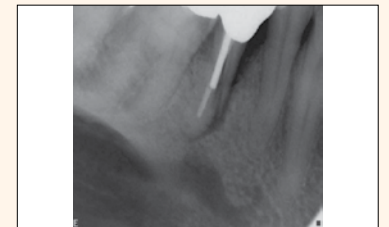


Fig. 7. Vertical root fracture of a tooth restored with a metal post.

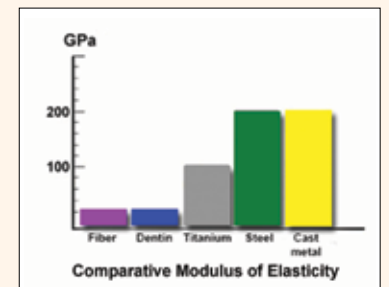


Fig. 8. Comparative modulus of elasticity of different post materials

by whichever of the materials is stiffest. Dentin averages a modulus of elasticity of 17.5 (+/- 3.8) GPa, with glass fiber posts at 24.4 (+/- 5.4) GPa, titanium prefabricated posts at 66.1 (+/- 9.6) GPa, prefabricated stainless steel at 108.6 (+/- 10.7) GPa and cast high noble gold posts at 53.4 (+/- 4.5) GPa.

Cast posts fabricated from noble or base metals have higher modulus than high noble alloys and approach stainless-steel prefabricated posts in their relative stiffness. Fiber posts have





&lt; Page 6

an elastic modulus that more closely approaches that of dentin (Fig. 8). The flexural strength of fiber and metal posts was respectively four and seven times higher than root dentin, and there is still debate on whether a post strengthens the tooth.<sup>16,17</sup> The basic purpose of a post is to aid in retention of the core.

The absence of a cervical ferrule has been found to be a determining negative factor, giving rise to considerably higher stress levels within the root. When no ferrule was present, the prefabricated metal post/composite combination generated greater cervical stress than cast post and cores. Yet, the ferrule seemed to cancel the mechanical effect of the reconstruction material on the intensity of the stresses.

With a ferrule, the choice of reconstruction material had no impact on the level of cervical stress. The root canal post, the purpose of which is to protect the cervical region, was also shown to be beneficial even with sufficient residual coronal dentin. In the presence of a root canal post, cervical stress levels were lower than when no root canal post was present. Pierrisnard concluded that the higher the elasticity modulus, the lower the stress levels.<sup>18</sup>

The material the post is fabricated from should have the same modulus of elasticity as the root dentin to distribute the applied forces along the length of the post and the root and not concentrate them at the apical tip of the post. Studies have shown that when components of different rigidity are loaded, the more rigid component is capable of resisting forces without distortion. This stress is concentrated when the post is the stiffer material at the post's apical tip. The less-rigid component fails invariably when a post is used that is stiffer than the root's dentin.<sup>19</sup>

Posts with modulus of elasticity significantly greater than that of dentin create stresses at the tooth/cement/post interface, with the possibility of post separation and failure. As repetitive loading occurs on the endodontically restored tooth, the cement eventually fails at the interface between the metal post and root dentin, allowing microslippage of the post. This allows higher stresses to be exerted on the root, leading to vertical root fracture and catastrophic loss of the tooth. The higher modulus (rigidity) of the metallic posts makes it stiff and unable to absorb stresses. In addition, transmission of occlusal and lateral forces through a metallic core and post can concentrate stresses, resulting in the possibility of unfavorable fracture of the root.<sup>20</sup> Dentin's modulus of elasticity is approximately 14 to 18 GPa. Fiber posts have modulus that is approximately 9 to 50 GPa, depending on the manufacturer of the post.

This provides a similarity in elasticity between the fiber post and dentin of the root, allowing post flexion to mimic tooth flexion. The fiber post absorbs and distributes the stresses and thus shows reduced stress transmission to the root.<sup>21</sup> The longitudinal arrangement of fibers in the fiber post and the modulus of elasticity of a post that is less

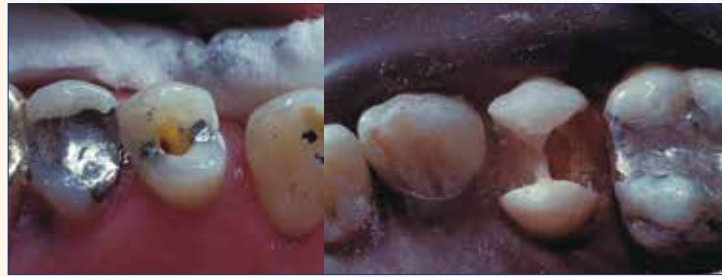

Fig. 9. Minimal tooth missing or previously restored following endodontic treatment.

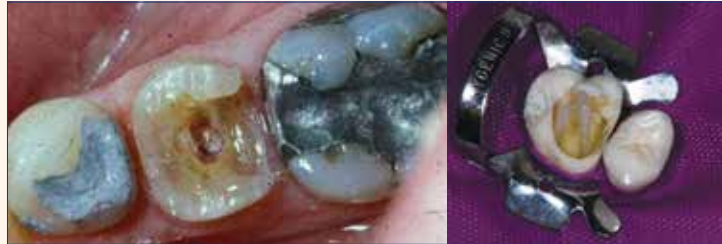

Fig. 10. Moderate tooth missing or previously restored following endodontic treatment.

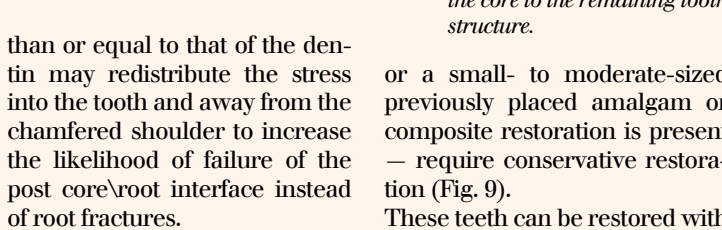


Fig. 11. Significant tooth missing or previously restored following endodontic treatment.

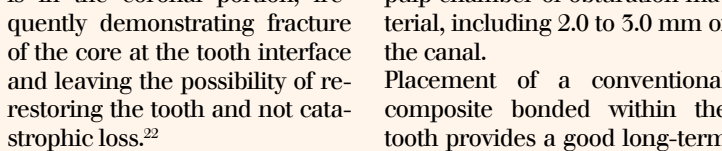

Fig. 12. Multiple fiber posts placed into a molar to lock the core to the remaining tooth structure.

than or equal to that of the dentin may redistribute the stress into the tooth and away from the chamfered shoulder to increase the likelihood of failure of the post core/root interface instead of root fractures.

When failure does occur due to overloading, failure typically is in the coronal portion, frequently demonstrating fracture of the core at the tooth interface and leaving the possibility of re-restoring the tooth and not catastrophic loss.<sup>22</sup>

The flexural properties of fiber posts were higher than the metal post and similar to dentin.<sup>23</sup>

Whereas prefabricated, stainless-steel post exhibited a significantly higher fracture resistance at failure when compared with the fiber posts, the mode of failure of the carbon fiber post was more favorable to the remaining tooth structure when compared with the prefabricated, stainless-steel post and the ceramic post.<sup>24</sup> Ceramic posts were introduced prior to fiber posts as a more esthetic alternative to prefabricated metal posts, and, although not widely used today, they are still available. Modulus of elasticity of ceramic posts is 170-215 GPa, which is approximately 15 times that of dentin. Because these ceramic posts are too rigid and transmit more stress to the root canal than the fiber posts, which lead to irreversible root damage via vertical root fracture seen with metal posts, their use is not recommended in restoring endodontically treated teeth today.<sup>25</sup>

#### Decision making for restoration of teeth treated endodontically

Restoration of endodontically treated teeth needs to take an engineering view of how best to reconstruct the remaining tooth for the best long-term survival. With this in mind, the practitioner needs to categorize the tooth based on how much native tooth structure is present following endodontic treatment and how much existing restorative material is currently present in the tooth.

#### Minimal tooth missing or previously restored

Posterior teeth gain strength when the marginal ridge area and proximal surface is natural tooth structure and has not been restored. Teeth that have undergone endodontic treatment — when either occlusal decay was present in the pits and fissures leading to pulpal involvement,

or a small- to moderate-sized previously placed amalgam or composite restoration is present — require conservative restoration (Fig. 9).

These teeth can be restored with removal of the existing restorative material and cleaning the pulp chamber of obturation material, including 2.0 to 3.0 mm of the canal.

Placement of a conventional composite bonded within the tooth provides a good long-term restorative solution to these teeth, and a crown typically is not needed. The access or existing restoration should leave most of the cuspal width present. When the preparation following removal of decay and existing restorative materials invades the width of the cusp leaving half of this tooth structure missing, more extensive restoration is indicated.

#### Moderate tooth structure missing or previously restored

When the tooth to be restored is missing one or both marginal ridges and these areas have been previously restored or will be restored, placement of a bonded composite will not suffice as the final restoration (Fig. 10). The marginal ridges provide resistance to cuspal flexure of the tooth, improving its strength. When these are missing, functional loading of the tooth will allow greater cuspal flexure and consequently a higher chance of fracture under masticatory function. Restoration of these teeth will require a core buildup with optional pins or other retentive elements for the core followed by a full coverage crown. Posts are often not needed, as the remaining tooth structure at the cusps after crown preparation is sufficient to retain the core, and a ferrule can be achieved.

A post may be considered in those patients who are bruxers or clenchers or whose occlusion may place higher forces on the restored tooth due to the tooth's position relative to the occlusal plane. When a ferrule cannot be achieved, the practitioner should consider osseous crown lengthening or forced eruption to improve the ferrule.

Inlay restorations should be avoided in endodontically treated teeth because the access created to perform the endodontic treatment weakens the tooth from a cuspal flexure standpoint and the inlay even when bonded may act as a wedge forcing the cusps apart and leading to frac-

ture of the tooth. An onlay restoration may be utilized, and its design should include shoeing of the cusps to limit cuspal flexure.

#### Significant tooth structure missing or previously restored

These teeth are a challenge to restore when removal of the old restorative material and decay leaves significant portions of the tooth needing replacement (Fig. 11). These teeth will require placement of posts to retain the core of the remaining tooth structure.

Because the purpose of posts is to retain the core, it is recommended that in multi-canal teeth a post be placed into each canal to cross-pin the core to the remaining tooth structure (Fig. 12). Projection of the posts in posterior teeth due to the angulation of the canals leads to convergence of the posts in the coronal portion of the tooth. This locks the core in place and assists in preventing fracture of the post or dislodgement under function that is observed when only a single post is placed.

Use of pins may also be considered to assist in retaining the core portion when cusps are missing and as an augment to posts being placed. These teeth require a full coverage crown to limit cuspal flexure under load. As with teeth with moderate missing tooth structure, use of inlays should be avoided because they do not restrict cuspal flexure. An onlay may be used if desired in some cases but should include shoeing the cusps as part of the preparation design to limit cuspal flexure. Again, when ferrule is not achievable, consider osseous crown lengthening or forced eruption to improve the ferrule.

#### Conclusion

For restoration of endodontically treated teeth, an engineering view is needed to ensure long-term survival. Ferrule is often overlooked in today's age of adhesive dentistry, but it is as critical today as it was in the past. Lack of ferrule has been shown to affect survival of the tooth, and the literature supports use of 2.0 mm of ferrule, which is more critical in maxillary anterior teeth due to the direction of loading during mastication.

Additionally, how we restore the remaining tooth plays a role in potential issues in the long term. Metal posts are being used less frequently due to vertical root fractures that can occur when the tooth is overloaded, and the direction has increasingly moved to the use of fiber posts, which mimic the roots modulus of elasticity. When teeth restored with a fiber post are overloaded, fracture typically occurs in the coronal (supragingival) portion, leaving sufficient tooth remaining to re-restore the tooth. Teeth rarely fail when they are over-engineered, but many fail due to under-engineering.

#### References

1. Barkhodar RA, Radke R, Abbasi J: Effect of metal collars on resistance of endodontically treated teeth to root fracture. *J Prosthet Dent* 61:676, 1989.

#### Editorial note:

The full list of references is available from the publisher.<sup>DT</sup>

#### About the Author

Dr. Gregori M. Kurtzman  
He can be reached at [dr\\_kurtzman@maryland-implants.com](mailto:dr_kurtzman@maryland-implants.com).

#### mCME SELF INSTRUCTION PROGRAM

CAPPmea together with Dental Tribune provides the opportunity with its mCME - Self Instruction Program a quick and simple way to meet your continuing education needs. mCME offers you the flexibility to work at your own pace through the material from any location at any time. The content is international, drawn from the upper echelon of dental medicine, but also presents a regional outlook in terms of perspective and subject matter.

#### Membership:

Yearly membership subscription for mCME: 900 AED  
One Time article newspaper subscription: 250 AED per issue.  
After the payment, you will receive your membership number and allowing you to start the program.

#### Completion of mCME

- mCME participants are required to read the continuing medical education (CME) articles published in each issue.
- Each article offers 2 CME Credit and are followed by a quiz Questionnaire online, which is available on <http://www.cappmea.com/mCME/questionnaires.html>.
- Each quiz has to be returned to [events@cappmea.com](mailto:events@cappmea.com) or faxed to: +97143686885 in three months from the publication date.
- A minimum passing score of 80% must be achieved in order to claim credit.
- No more than two answered questions can be submitted at the same time
- Validity of the article – 5 months
- Validity of the subscription – 1 year
- Collection of Credit hours: You will receive the summary report with Certificate, maximum one month after the expiry date of your membership. For single subscription certificates and summary reports will be sent one month after the publication of the article.

The answers and critiques published herein have been checked carefully and represent authoritative opinions about the questions concerned.

Articles are available on [www.cappmea.com](http://www.cappmea.com) after the publication. For more information please contact [events@cappmea.com](mailto:events@cappmea.com) or +971 4 3616174

FOR INTERACTION WITH THE AUTHORS FIND THE CONTACT DETAILS AT THE END OF EACH ARTICLE.



# The role of the dental team in the management of the patient with sleep apnea



*mCME articles in Dental Tribune have been approved by:  
HAAD as having educational content for 2 CME Credit Hours  
DHA awarded this program for 2 CPD Credit Points*

**ADA CERP®** Continuing Education Recognition Program

Centre for Advanced Professional Practices (CAPPP) is an ADA CERP Recognized Provider. ADA CERP is a service of the American Dental Association to assist dental professionals in identifying quality providers of continuing dental education. ADA CERP does not approve or endorse individual courses or instructors, nor does it imply acceptance of credit hours by individuals/dentistry.

*CAPPmea designates this activity for 2 continuing education credits.*

By Nancy M. Costa-Larson, USA

The evolution of the dental hygienist's role in the assessment of a client's oral health from a singular approach to a collaborative multidisciplinary approach is evident in the treatment of clients with sleep disorders. Knowledge of the variations in sleep disorders, medications, treatment needed, as well as the various appliances will be vital to the dental health-care providers. Pagel (2012) says that by 2015, 40 percent of the U.S. population will have some form of sleep disorder; 18 million Americans have sleep apnea, which affects all ages, both sexes and may be genetic. The most prevalent form occurs in 4 percent of middle-aged men and 2 percent of middle-aged women.<sup>1</sup>

As with all medical conditions, early detection and baseline data will aid in monitoring changes in the patient's health and providing useful information in treatment planning and implementation. Sleep apnea in the past has been viewed as most typically related to snoring; however, there are different types of sleep apnea disorder. The most prevalent and known is obstructive sleep apnea syndrome. Another type, central sleep apnea, is less common. A third type, complex sleep apnea, combines both the obstructive and central types.

## What is obstructive sleep apnea syndrome?

Obstructive sleep apnea syndrome (OSAS) is a common, but underdiagnosed disorder that is potentially fatal.<sup>5</sup> According to de Almeida et al. (2006), "It happens most frequently during REM sleep, and breathing stops for 10 to 30 seconds, which results in reduced levels of oxygen dissolved in the blood."<sup>4</sup> The patient with the OSAS does not know this is happening. A person's quality and quantity of sleep is often inadequate. These interruptions of sleep can affect a person's mental and physical state — and lead to additional problems in the oral cavity.

## What is central sleep apnea?

Central sleep apnea is caused by the brain failing to signal the breathing-control muscles to work. With central sleep apnea, snoring is infrequent to rare because there is no airway obstruction. Though this disorder is less common than obstructive sleep apnea, it is important to address for the overall health of the sleeper. Oral appliances do not work in this situation. Central sleep apnea is diagnosed by

sleep studies and typically treated with medications.

## What is complex sleep apnea?

Complex sleep apnea is a combination of obstructive sleep apnea and central sleep apnea. Some patients with obstructive sleep apnea develop central sleep apnea while on treatment with continuous positive airway pressure (CPAP).<sup>2</sup>

This article focuses on obstructive sleep apnea and how it relates to the oral cavity.

## Cause of obstructive sleep apnea syndrome

Tongue muscles, soft palate and uvula relax and/or sag (Fig. 2), causing snoring, difficulty breathing and breathing cessation. Obesity, alcohol consumption and sleep medications can exacerbate the condition. Snoring and gasping for air causes the person to wake several times a night, preventing the person from getting the proper sleep needed to function.

Sleep apnea is often present in people who are overweight, have physical abnormalities such as a deviated septum or have other abnormalities of the nose or throat. The sleeper tries to breathe, creating a tighter seal, which decreases oxygen flow to the brain. The sleeper awakens gasping for air.

## Effects and oral effects

Studies on sleep apnea are fairly new, and diagnostic evidence is evolving. Snoring is one of the symptoms of obstructive sleep apnea syndrome; however, not all individuals who snore necessarily have OSAS. Friedlander says, "Even when the airway is partially open, obstruction occurs frequently and results in a loud irregular snoring sound caused by air rushing through the narrow passage and stimulating the soft palate, uvula, throat walls and tongue to vibrate."<sup>5</sup> If an OSAS patient is left untreated, the condition can worsen over time. Risk can increase for hypertension, stroke, myocardial infarction, anoxic seizures and sudden death while asleep.<sup>5</sup> Sleep apnea can be alleviated with oral devices and/or surgical procedures, however some complications have arisen in the oral cavity because of some of the devices used to correct or minimize obstructive sleep apnea.

## Signs and symptoms

Dental professionals may be the first health-care providers to suspect possible OSAS in a patient<sup>5</sup> because of signs and symptoms exhibited within the oral cavity. These include: "macroglossia (Fig. 3) and enlarged

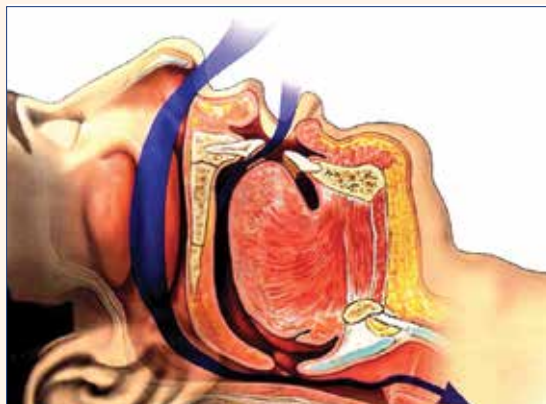


Fig. 1. The position of the tongue and mandible with normal and open airway while sleeping. (Photos/Provided by Sleep Group Solutions)

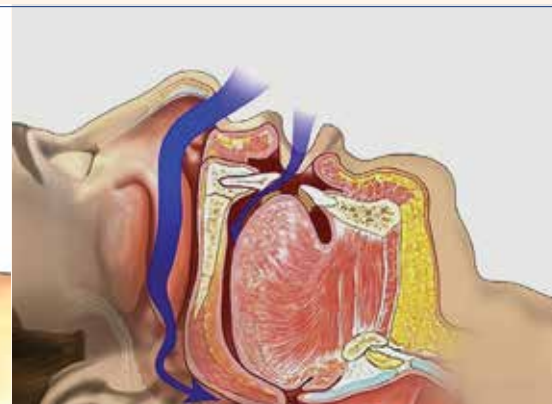


Fig. 2. The position of the tongue and mandible showing blocked airway that occurs with obstructive sleep apnea.

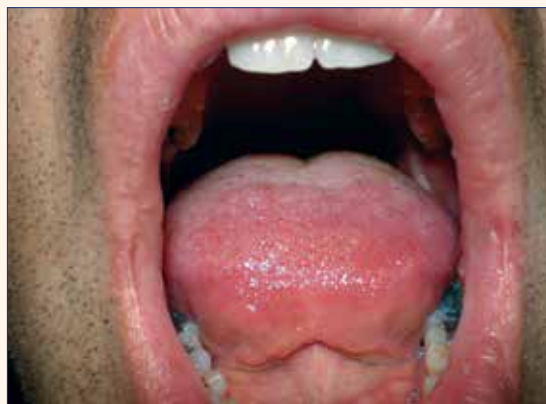

Fig. 3. Macroglossia (enlarged tongue).

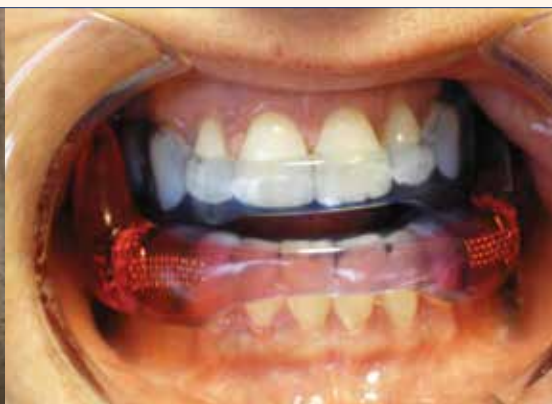

Fig. 4. One of many oral devices used to relieve sleep apnea. The appliance keeps the mandible in a static position to not fall back when the individual is sleeping in a supine position. (Photo/Provided by Respire Medical/The Respire Blue Series)

pharynx, narrowed posterior airway space resulting from a long soft palate by the uvula lying below the base of the tongue; the tongue lying above the mandibular plane of occlusion and small mandible."<sup>5</sup>

Signs and symptoms of OSAS while sleeping can include drooling, xerostomia, restlessness, bruxism, choking or gasping, snoring, breathing pauses and diaphoresis. But an individual's symptoms associated with OSAS are not limited to sleeping problems. During waking hours the patient may experience depression, difficulty concentrating, fatigue and insomnia. Other signs can include gastroesophageal reflux disease (GERD), irritability and sleepiness throughout the day. Coughlin says, "If OSAS continues to be untreated or it is never diagnosed, the sleeping disorder may elevate blood pressure and the potential for mortality increases."<sup>6</sup>

## What to look for

Maglioca says, "The population with OSAS is a heterogeneous group, and have a wide range of physical attributes. Not all patients with OSAS have all of these physical features."<sup>7</sup> The most common orofacial characteristics encountered include a retrognathic mandible, narrow palate, large neck circumference, long soft palate (which leads to dentists being unable to visualize the entire length of the uvula when the patient's mouth is open wide), tonsillar hypertro-

phy, deviated nasal septum and relative macroglossia.

## Potential outcomes of non-treatment

Patients with OSAS have interrupted sleep patterns because the obstruction of airflow causes prolonged interruptions in their breathing while they sleep (up to 40 seconds). Because the condition can lead to a reduction of oxygen in the blood stream, a host of medical complications can occur. Individuals with obstructive sleep apnea can experience worsening snoring, which is caused by vibration of the partially collapsed soft palate as air passes. Respiratory events, which deplete certain stages of non-REM and REM sleep, contribute to sleep fragmentation and unrefreshing sleep.<sup>7</sup> Because of the lack of sleep, an OSAS sufferer may have difficulty concentrating and staying awake during the day. When sufferers sleep on their back, gravity pulls the jaw and tongue down and back. This causes the mouth to open and the tongue to drop back into the airway, narrowing the air passage.

## Treatments

Oral devices and surgical intervention are the procedures used to treat OSAS. An oral appliance (Fig. 4) is a small acrylic device that fits over the upper and lower teeth or tongue (similar to an

orthodontic retainer or mouth guard). This device slightly advances the lower jaw or tongue, which moves the base of the tongue forward and opens the airway. This improves breathing and reduces snoring and apnea. The appliance is fabricated and customized for each patient by a dentist experienced in the treatment of snoring and sleep apnea. The appliances are comfortable and well tolerated by patients. Appliances are easy to place and remove, easy to clean and are convenient for travel.

## Non-surgical treatments are available, including positional therapy

The two main categories of oral appliances currently in use are the mandibular advancement devices (MAD) and the tongue retaining devices (TRD). The mandibular advancement devices, made of acrylic materials, are custom fabricated for each patient. The impression for the acrylic devices can be made in the dental office for lab fabrication. The devices fit comfortably over the upper and lower teeth, positioning the lower jaw slightly forward, advancing the tongue and soft tissues of the throat to open the airway. Some of the "repositioners" are designed to hold the mandible





&lt; Page 8

anteriorly, constructed to position the mandible at 75 percent of the maximal mandibular advancement and within a 7 mm opening between upper and lower incisors<sup>78</sup> with no adverse effects to the temporal mandibular joint.

The MADs have an adjustment mechanism built into the device, enabling users to gradually change the position of the bottom jaw under dental supervision to improve the effectiveness of the device.

Oral appliances used for OSAS patients cause a “mandibular advancement, including development of posterior open bite, altered inclination of incisors and decreased anterior open bite.”<sup>78</sup> Through the use of various imaging techniques, research on appliances used for OSAS has identified various dental/skeletal changes that occur.

One of the most common effects, referenced in many studies, is the degree of vertical and horizontal overlap of the teeth (overjet and overbite, respectively).<sup>9</sup> The adjustment mechanism makes it possible to position the device to best address a patient's particular needs.

The tongue-retaining device is custom-made using a softer, pliable material with a compartment that fits around the tongue to hold it forward by means of suction. This device is used most for patients with dentures or patients who cannot adequately advance their lower jaw. Such patients must be able to breathe well through their nose, or they may have difficulty tolerating this appliance.

There are other recommended treatments, some involving behavioral therapy, that patients may be less likely to comply with, such as “non-supine sleep, [avoiding] late evening [food] consumption, weight loss, abstaining from drinking alcoholic beverages and a lifetime of required nightly use of continuous compressed air delivered by a CPAP (continuous positive air-way pressure) machine via a nasal mask”<sup>75</sup> (Fig. 5).

The CPAP machines work when there is a compliant patient. If the patient is not compliant, there are other oral-appliance therapies that may be used, but CPAP remains the “gold standard” treatment for sleep apnea [and] the objective success rate of any other treatment must be judged against it.”<sup>10</sup> If a patient chooses oral devices over a CPAP machine, the dental team may be responsible for the fabrication of the oral devices.

#### Surgical treatments

Surgery is usually done in severe cases of OSAS or as an alternate or last-resort procedure. The main surgical treatments offered for OSAS often target the anatomical areas of the posterior airway where collapse is suspected to occur. Treatment is designed to enlarge the posterior airway space, reduce airway collapsibility and, ideally, stabilize the airway for the long term. Surgery has the advantage of correcting any craniofacial abnormalities that may be the cause of the OSAS and of removing the variable of patient compliance that is required with

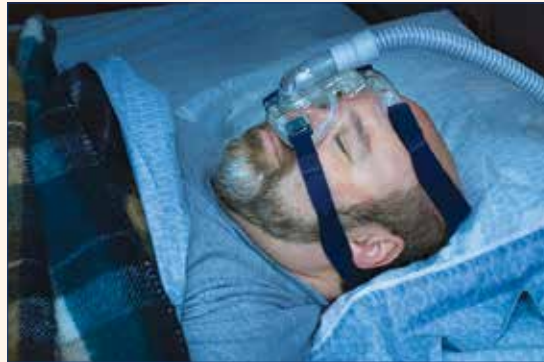

Fig. 5. CPAP machine nosepiece. Adjustments need to be made to the CPAP nosepiece and mouthpiece. Mouthpiece can cause pressure and create lesions in the upper anterior gingival tissues.

other long-term treatment strategies.

Obstructive sleep apnea syndrome sometimes occurs in patients with a retrognathic positioning of the mandible (Fig. 6). People who have a receding chin related to a small lower jaw are more likely to snore because there is less room in the back of the throat for the soft tissues and tongue. This reduction in space decreases the size of the air passage and causes increased snoring.

Some patients undergo “maxilla-mandibular advancement surgery.”<sup>73</sup> Oral and maxillofacial surgeons engaging in corrective surgery communicate with the general dentist, because whenever an OSAS patient undergoes surgery, treatment plans need to be suspended in anticipation of changes to the patient's occlusion. Hoffstein says, “Maxilla-mandibular advancement (MMA) surgery, which is based on traditional orthognathic surgery techniques, has been proven effective for a range of OSAS disease.”<sup>10</sup> Surgery allows the repositioning of the tongue. Additionally, de Almeida says, “These bone movements pull the base of the tongue forward and upward, thereby enlarging the posterior airway space, creating more anterior space for the tongue. The bony segments are fixed rigidly with screws and plates to assist in healing and to resist the pull of soft tissue that may cause skeletal relapse.”<sup>4</sup>

#### Dental team's role in identifying sleep apnea

Obstructive sleep apnea requires appropriate diagnosis and treatment. Interdisciplinary communication is paramount when cases are handled by a team methodology. The dentist should work closely with other health-care professionals. Referral of patients to a physician indicates the dentist's desire to make certain that the patient receives the best care possible. Dental professionals are crucial advocates involved in the management of OSAS and should be aware of the complications that can be caused by the disorder.

Asking questions about patients' sleep habits can stimulate awareness for the general dentists and hygienist, enabling them to refer a patient to a physician who specializes in sleep disorders. Use of a standardized questionnaire similar to a medical history will ensure that every patient is screened for OSAS (see example in appendix). Identifying the underlying causes of OSAS and recommending an appropriate course of treatment

can help patients maintain quality of life and reduce morbidity rates. Prinsell says, “This should be a working relationship between the medical community.”<sup>75</sup>

#### Teamwork between dental and medical professions

Patients with OSAS have a higher risk for hypertension, which can lead to other physical complications. Dental professionals working with physicians should be familiar with the medications and appliances used for sleep apnea and the oral complications that can result from the different treatments. Treatment for sleep apnea and snoring can help patients get the rest they need to reduce the medical complications and improve their function during the day. The dental team will be involved in monitoring any occlusal changes that result from mouth devices used in the sleep-disorder therapy.

When working with patients who have been prescribed an oral appliance, the dental hygienist needs to recommend mandatory dental visits as part of the treatment plan to keep a record of changes that might occur in the occlusal bite or to stay ahead of other dental problems that can occur because of use of the appliance. Magliocca and Helman say, “In addition to the patient's medical history, the dentist's clinical examination findings influence treatment planning.”

It is also important to be aware that patients may be taking medication that creates xerostomic effects.<sup>7</sup> Kalan and Kenyon say, “There are, also, certain types of CPAP delivery that may add to the patient's complaints of xerostomia.”<sup>11</sup> Medications may sometimes be used to treat depression experienced by some patients with OSAS. These medications may contribute to causing the oral cavity to be dry. Patients also might begin to neglect daily oral hygiene. Dentists and hygienists should recommend and prescribe artificial saliva products and regular fluoride applications for patients with xerostomia who are using the CPAP devices. While the incidence of caries has not been reviewed in the OSAS population, it would seem especially prudent to educate patients with xerostomia about avoiding cariogenic foods and beverages.<sup>7</sup> Dental professionals need to be aware of the impact certain surgery procedures within the oral cavity can have on patients who are using a CPAP machine. For example, Kapur says, “Reflecting a mucoperiosteal flap to accomplish surgical extractions or

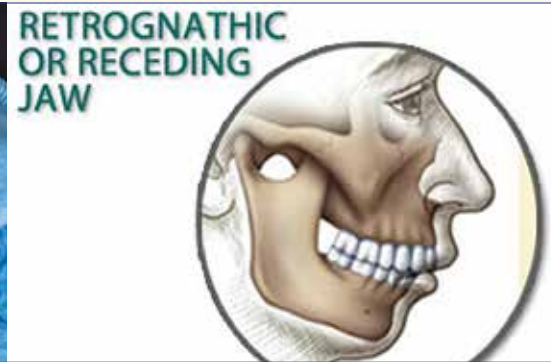


Fig. 6. Retrognathic or receding jaw. (Photo/Provided by Oral Facial Reconstruction and Implant Center of Florida, www.orafacial.com/ doctors-luis-cardenas.php)

other procedures may preclude the patient from using CPAP for one to two evenings to avoid the possible risk of developing subcutaneous emphysema.”<sup>12</sup> Because occlusal changes can occur with OSAS therapy, communication between the patient, dentist, hygienist and the physician who prescribed the oral appliance is essential. Some patients may not notice or may not be affected by changes in their occlusion while using an oral appliance, but problems may still exist. Robertson et al. suggest “keeping the patient's bite opening to a minimum when fabricating an appliance to reduce the impact on the occlusion.”<sup>15</sup> When restorative work is done on OSAS patients, such as crowns or fillings, adjustments to the existing appliance — or fitting of a new appliance — may be needed. The process of adjusting or creating a new appliance needs to be done with the oral surgeon or physician who prescribed the oral device. The prevalence of OSAS may be higher than estimated, and medical and dental health-care professionals can “offer these

patients the full range of available treatment options to defeat this often fatal illness.”<sup>76</sup> Adding sleep-related questions to the written or oral medical history and consideration of both orofacial and physical findings may result in the detection of a sleep disorder.<sup>8,14,15</sup> Dental hygienists can ask questions, such as: “How many pillows do you sleep with? Does your spouse complain that you snore? Are you grinding or clenching? Do you wake up with headaches in the morning? Do you wake up with a dry mouth?” The routine oral assessment that hygienists provide can aid in recognizing conditions pertaining to OSAS. Hygienists can facilitate the management of the patient with sleep apnea by recommending oral care products to reduce xerostomia and to reduce inflammation of gingiva for sleep apnea patients who snore. Dental health-care professionals should refer patients to physicians who manage OSAS patients on a regular basis. Dental hygienists see patients frequently and often on a routine basis, so they are often the first to observe variations in the oral cavity. Cooperation between hygienists and dentists and medical health-care professionals who treat patients with OSAS creates an advantage to the patient for overall health care. Treatment plans for patients with sleep apnea and sleep disorders, along with the associated medications being used by such patients, should be included in the medical history in the patient's charts. This will ensure the dental team is aware of any changes in the oral cavity and is

&gt; Page 10

#### mCME SELF INSTRUCTION PROGRAM

CAPPmea together with Dental Tribune provides the opportunity with its mCME - Self Instruction Program a quick and simple way to meet your continuing education needs. mCME offers you the flexibility to work at your own pace through the material from any location at any time. The content is international, drawn from the upper echelon of dental medicine, but also presents a regional outlook in terms of perspective and subject matter.

#### Membership:

Yearly membership subscription for mCME: 900 AED  
One Time article newspaper subscription: 250 AED per issue.  
After the payment, you will receive your membership number and  
Allowing you to start the program.

#### Completion of mCME

- mCME participants are required to read the continuing medical education (CME) articles published in each issue.
- Each article offers 2 CME Credit and are followed by a quiz Questionnaire online, which is available on <http://www.cappmea.com/mCME/questionnaires.html>.
- Each quiz has to be returned to [events@cappmea.com](mailto:events@cappmea.com) or faxed to: +97145686885 in three months from the publication date.
- A minimum passing score of 80% must be achieved in order to claim credit.
- No more than two answered questions can be submitted at the same time
- Validity of the article – 5 months
- Validity of the subscription – 1 year
- Collection of Credit hours: You will receive the summary report with Certificate, maximum one month after the expiry date of your membership. For single subscription certificates and summary reports will be sent one month after the publication of the article.

The answers and critiques published herein have been checked carefully and represent authoritative opinions about the questions concerned.

Articles are available on [www.cappmea.com](http://www.cappmea.com) after the publication. For more information please contact [events@cappmea.com](mailto:events@cappmea.com) or +971 4 5616174

FOR INTERACTION WITH THE AUTHORS FIND THE CONTACT DETAILS AT THE END OF EACH ARTICLE.