

# DENTAL TRIBUNE

—The World's Dental Newspaper · Middle East & Africa Edition—

PRINTED IN DUBAI

www.dental-tribune.me

MARCH-APRIL 2014 | NO. 2, VOL. 5

## EVENT

9<sup>th</sup> CAD/CAM & Digital Dentistry International Conference  
Jumeirah Beach Hotel, Dubai  
09-10 May 2014

>Cover Page



## WORLD ORAL HEALTH DAY



>Page 29

## DENTAL HYGIENE TRIBUNE

Message from the Editor



>Page 29



Fig. 1

By Lee Culp, USA

The concept of digital dentistry is one that started out small and has progressively increased in momentum until its boundaries appear to have become endless. New technologies in dentistry will only be successful if they are combined with a complete understanding of basic comprehensive dentistry.

While new technology and computerization can make procedures more efficient, less labor-intensive and more consistent, it will not replace education, practical experience and clinical/technical judgment.

The most exciting factor surrounding these technologies is not, however, only in the potential applications of the technology that are being hypothesized by dental professionals. The excitement truly lies in the fact that

## CAD/CAM dentistry and the laboratory technician: Partners in success

these “hypothetical” applications are currently being developed today, and some are even in the final stages.

In a relatively short time period, distal technology will revolutionize the quality of dental care that is being delivered in modern practice. Implants are now well documented for fulfilling the functional requirements in prosthetic tooth replacement. These new technologies, along with the evolution of surgical and prosthetic techniques, allow the

dental team predictable, consistent results in implant rehabilitation. MicroDental is involved as a beta test area for many of these emerging technologies.

As dentistry evolves into the digital world, the successful incorporation of computerization and new technology will continue to provide more efficient methods of communication and fabrication, while at the same time retaining the individual creativity and artistry of the skilled dentist and dental technician. The utilization of new technology will be

enhanced by a close cooperation and working relationship of the dentist/technician team.

The evolution from hand waxing to “digital waxing” using the diagnostic wax-up and provisional restorations, as well as their digital replicas to guide us in the creation of CAD/CAM restorations, will be presented. The utilization of these new technologies, along with the evolution from “hand” design to “digital”

> Page 37

## Leading dental companies form KaVo Kerr Group

By Dental Tribune International

CHICAGO & WASHINGTON, USA: Yesterday, Henk van Duynhoven, senior vice president of Danaher Corp., a U.S. umbrella corporation encompassing brands from various industries, announced the formation of KaVo Kerr Group.

The group strategically unites leading dental consumable, equipment, high-tech and specialty brands under one platform.

“The formation of KaVo Kerr Group enables us to better serve dental professionals and healthcare providers who purchase

> Page 39

## Handing over ceremony



Officers at the meeting: from left, Imtiaz Turkistani, Cedric Haddad, Riad Bacho, President Ali Alehaideb, Ibrahim Nasseh and Nadim AbouJaoude.

By International College of Dentists

This was a historic moment for Section X with the handing over of the presidency taking place for the first time outside Lebanon. The meeting took place in Dubai at the Fairmont Hotel on February 4<sup>th</sup> in the presence of fellows from both districts and guests. The event was sponsored by CARE and Planning

> Page 34

## mCME

### Page 6

Clinical and diagnostic advantages of PreXion 3-D imaging system

### Page 8

Clinical digital photography. Part 1: Equipment and basic documentation

## ORTHO TRIBUNE

### Page 26

Invisalign®: clear benefits for your patients

By Vicki Vlaskalic BDS; MDS.

## ENDO TRIBUNE

### Page 40

Biological and conservative root canal instrumentation with BT-Race file system

By Drs Gilberto Debelian & Martin Trope

## CLINICAL

### Page 17

Case presentation: Opti-Bond™ XTR

### Page 18

Two phase treatment of a Class II division 1 patient complicated by traumatic upper incisor intrusion: A Case Report

## LAB TRIBUNE

### Page 12

Mr. Kaufmann explains the advantages of KaVo's new ARCTICA CAD/CAM system

### Page 14

The Inman Aligner: A progressive approach to smile design - Part 2

# Brilliant technology for diagnostics: KaVo DIAGNOcam: A new look at caries

By KAVO

With the introduction of the caries diagnosis device DIAGNOdent 15 years ago and more than 60,000 devices sold, KaVo has set a new standard in caries detection. We are now combining this great success with the new DIAGNOcam and is thereby setting new standards in caries diagnostics. The new KaVo DIAGNOcam is

the first camera system that uses the tooth's structure to verify caries diagnosis. To do this, the tooth is transilluminated utilizing light of a specific wavelength and used like a light conductor. A digital video camera records the image and displays it live on a computer screen. Carious lesions are displayed as dark shadows. The images recorded by the KaVo DIAGNOcam can be stored, thus significantly sim-

plifying monitoring and patient communication.

With its DIFOTI technology (Digital Imaging Fiberoptic Transillumination), DIAGNOcam offers high diagnostic safety which is comparable or superior to X-ray diagnosis in many cases, in particular with regard to approximal and occlusal caries. Furthermore, it is possible to show certain kinds of secondary caries and cracks. The X-ray free device thereby allows early

and very gentle caries detection. Compared to other methods, the clinical significance is not distorted through plaque deposits.

Because of its easy handling, the device can quickly be integrated in existing routines, thereby resulting in a distinct added value in terms of patient motivation and information.

Experience the next generation of caries detection with the KaVo DIAGNOcam. [DT](#)



DIAGNOcam

## DENTAL TRIBUNE

—The World's Dental Newspaper— Middle East & Africa Edition —

### GROUP EDITOR

Daniel Zimmermann  
newsroom@dental-tribune.com  
+49 541 48 474 107

### CLINICAL EDITOR

Magda Wojtkiewicz

### ONLINE EDITORS

Yvonne Bachmann  
Claudia Duschek

### COPY EDITORS

Sabrina Raaff  
Hans Motschmann

### PUBLISHER/PRESIDENT/CEO

Torsten Oemus

### DIRECTOR OF FINANCE & CONTROLLING

Dan Wunderlich

### BUSINESS DEVELOPMENT MANAGER

Claudia Salwiczek

### MEDIA SALES MANAGERS

Matthias Diessner (Key Accounts)  
Melissa Brown (International)  
Peter Witteczek (Asia Pacific)  
Maria Kaiser (USA)  
Weridiana Mageswki (Latin America)  
Hélène Carpentier (Europe)

### MARKETING & SALES SERVICES

Esther Wodarski  
Nicole Andra

### ACCOUNTING

Karen Hamatschek

### EXECUTIVE PRODUCER

Gernot Meyer

### DENTAL TRIBUNE INTERNATIONAL

Holbeinstr. 29, 04229 Leipzig, Germany  
Tel.: +49 541 48 474 502  
Fax: +49 541 48 474 175  
www.dental-tribune.com  
info@dental-tribune.com

### REGIONAL OFFICES

**ASIA PACIFIC**  
Dental Tribune Asia Pacific Limited  
Room A, 20/F, Harvard Commercial Building,  
105-111 Thomson Road, Wanchai, Hong Kong  
Tel.: +852 5115 6177  
Fax: +852 5115 6199

### THE AMERICAS

Tribune America, LLC  
116 West 25rd Street, Ste. 500, New York, N.Y. 10011, USA  
Tel.: +1 212 244 7181  
Fax: +1 212 244 7185

### DENTAL TRIBUNE MIDDLE EAST & AFRICA

### EDITION EDITORIAL BOARD

Dr. Aisha Sultan Alsuwaidi, UAE  
Dr. Nabeel Humood Alsabeeha, UAE  
Dr. Mohammad Al-Obaida, KSA  
Dr. Meshari F. Alotaibi, KSA  
Dr. Jasim M. Al-Saeedi, Oman  
Dr. Mohammed Sultan Al-Darwish  
Prof. Khaled Balto, KSA  
Dr. Dobrina Mollova, UAE  
Dr. Munir Silvadi, UAE  
Dr. Khaled Abouseada, KSA  
Dr. Rabih Abi Nader, UAE  
Rodny Abdallah, Lebanon  
Victoria Wilson, UK

### PARTNERS

Emirates Dental Society  
Saudi Dental Society  
Lebanese Dental Society  
Qatar Dental Society  
Oman Dental Society

### DIRECTOR OF mCME

Dr. Dobrina Mollova  
mollova@dental-tribune.me  
+971 50 42 45072

### BUSINESS DEVELOPMENT MANAGER

Tzvetan Deyanov  
deyanov@dental-tribune.me  
+971 55 11 28 581

## KaVo MASTERtorque™ turbine with Direct Stop Technology

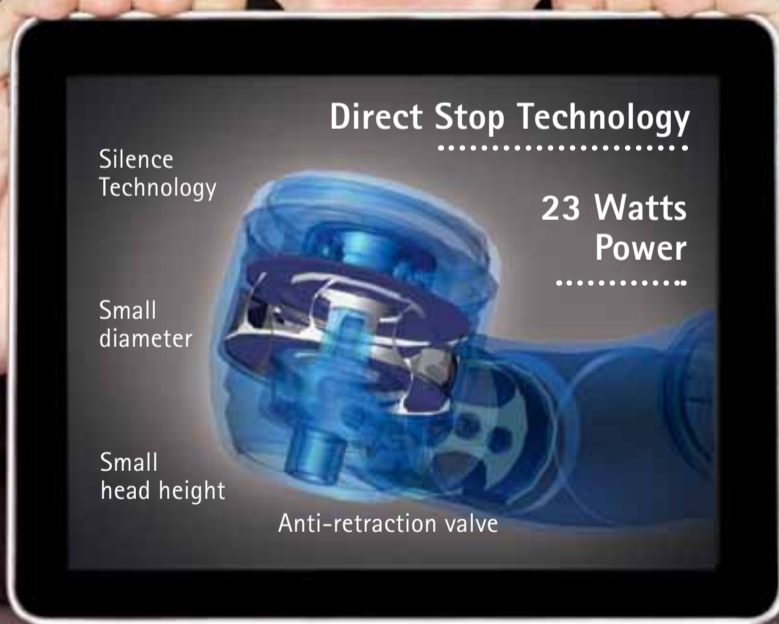Superiority is at hand – all day, every day.  
Maximum Power. Whisper Quiet. Optimal Comfort.

### NEW KaVo MASTERtorque™ with Direct Stop Technology

- DST, Direct Stop Technology:
  - Safe, dental bur stops within one second
  - Hygienic, no retractive suction
- Powerful, 20 % more power, 23 watts
- Extremely low-noise, 57 dB(A)

KaVo *Master Series*

A true master knows no compromise.



KaVo. Dental Excellence.

Elegant design and easy handling are a winning combination.



## CEREC OMNICAM

### THE EVOLUTION OF SIMPLICITY



The new CEREC Omnicam combines powder-free ease of handling and natural color reproduction to provide an inspiring treatment experience. Discover the new simplicity of digital dentistry – exemplified by Sirona's premium camera portfolio: CEREC Omnicam and CEREC Bluecam. **Enjoy every day. With Sirona.**

**UNRIVALLED HANDLING ■ POWDER-FREE ■ SCANNING IN NATURAL COLOR**

Dubai Contact: SIRONA Dental Systems Ltd · Dr Amro Adel · Building 49, Suite 304  
Dubai Healthcare City · Telephone: + 971 4 375 2355 · E-Mail: amro.adel@sirona.com

Kuwait Contact: SIRONA Dental Systems GmbH · Dr. Mostafa Al.Khouly  
Office: + 965 2 224 6063 · Mobile: + 965 9 800 2225

**sirona.com**



The Dental Company

**sirona.**

# Saliva and Oral Health

By Michael Edgar, Colin Dawes & Denis O'Mullane and contributed to by C. Dawes

*Excerpt from Saliva and Oral Health - An Essential Overview for the Healthcare Professional, 2012*

The presence of saliva is vital to the maintenance of healthy hard (teeth) and soft (mucosa) oral tissues. Severe reduction of salivary output not only results in a rapid de-

terioration of oral health but also has a detrimental impact on the quality of life for the sufferer.

An understanding of saliva and its role in oral health helps to promote awareness among oral health care professionals of the problems arising when the quantity or quality of saliva is decreased; this awareness and understanding is important to the prevention, early diagnosis and treatment of the condition. There is an extensive

body of research on saliva as a diagnostic fluid. It has been used to indicate an individual's susceptibility to developing caries; it has also been used to reflect systemic physiological and pathological changes which are mirrored in saliva. One of the major benefits of saliva as a diagnostic fluid is that it is easily available for non-invasive collection and analysis. It can be used to monitor the presence and levels of hormones, drugs, antibodies, microorganisms and ions.

## Factors Influencing Salivary Flow Rate and Composition

The following article provides an overview of the differences in flow rate and composition between unstimulated saliva (secreted continuously in the absence of exogenous stimulation) and stimulated saliva (secreted usually in response to masticatory or gustatory stimulation), the factors influencing salivary flow rate and composition, and their physiological importance.

## Unstimulated saliva

Unstimulated whole saliva is the mixture of secretions found in the mouth in the absence of exogenous stimuli such as tastants or chewing. It is composed of secretions from the parotid, submandibular, sublingual, and minor mucous glands but it also contains gingival crevicular fluid, desquamated epithelial cells, bacteria, leucocytes (mainly from the gingival crevice), and possibly food residues, blood, and viruses.

Several large studies of unstimulated salivary flow rates in healthy individuals have found the average value for whole saliva to be about 0.5-0.4 ml/minute, but the normal range is very large and includes individuals with very low flow rates who do not complain of a dry mouth. Such a broad normal range makes it difficult to say whether or not a particular individual has an abnormally low flow rate. Unless saliva is almost completely absent, patients can be said to have a dry mouth (xerostomia) only on the basis of their subjective symptoms. However, a flow rate of <0.1 ml/min is considered objective evidence of hyposalivation.

Whether the flow rate is high or low is much less important than whether it has changed adversely in a particular individual. Physicians will often take a patient's blood pressure as a yardstick for future measurements. Dentists, however, do not routinely measure the salivary flow rate, so that when a patient complains of having a dry mouth, it is impossible to judge whether or not a genuine reduction in flow has taken place. It would therefore be very advantageous if dentists included measurement of salivary flow as part of their regular examination. Just as there are individuals with very little saliva but without discomfort, so there are others with flow rates within the normal range who feel that their mouth is drowning in saliva. This problem is often due to difficulty in swallowing, rather than to a genuinely high flow rate.

## Factors affecting the unstimulated salivary flow rate

- **Degree of hydration** – This is potentially the most important factor. When body water content is reduced by 8%, the salivary flow rate decreases to virtually zero.
- **Body posture** – Flow rate varies with position and a person when standing or lying will have a higher or lower flow rate, respectively, than when seated.

**Extra**  
Oral Healthcare Program

**CHEW** FOR A HEALTHY MOUTH

Research shows, chewing Sugarfree gum for 20 minutes after meals and snacks, can help reduce tooth decay.

Graph showing Salivary Flow Rate (ml/min) vs Time (min) for before gum, during gum, and after gum. The flow rate increases significantly during gum chewing and remains elevated after gum.

**Eat Chew Drink!**  
Extra

&lt; Page 4

• **Biological rhythms** – Circadian rhythms are rhythms with a period of about 24 hours and include the rhythms in body temperature and in salivary flow<sup>2</sup>. The body temperature and the flow rate of saliva peak during the late afternoon but the flow rate drops to almost zero during sleep. This circadian rhythm also has important clinical implications for the timing of oral hygiene. The most important time to clean the teeth is probably at night before going to sleep, since the presence of plaque and food debris and a greatly reduced salivary flow during sleep provide optimum conditions for progression of dental caries.

• **Functional stimulation** – Further studies are needed to clarify whether regular stimulation of salivary flow, as by use of chewing gum, leads to an increase in the unstimulated flow rate, although there is evidence that it increases the stimulated flow rate

#### Stimulated saliva

This type of saliva is secreted in response to masticatory or gustatory stimulation; Several studies of stimulated salivary flow rates have been done in healthy populations and show a wide variation among individuals. Many factors influence the stimulated salivary flow rate which, for whole saliva, has an average maximum value of about 7 ml/minute.

#### Factors affecting the stimulated salivary flow rate

• **Chewing gum** – Research shows the flow rate is high initially but after about ten minutes, as the flavour and sweeteners leach out and only the gum-base remains, it falls to the rate obtained by chewing gum-base alone, namely to two to three times the unstimulated rate. This increase in salivary flow during gum chewing can be maintained for as long as two hours and this may be very beneficial to those with a dry mouth. Even after two hours of gum chewing, the salivary glands do not become 'exhausted' and introduction of a fresh piece of gum causes a secretory response similar to that initially.

• **Mechanical stimuli** – The action of chewing, in the absence of any taste, will itself stimulate salivation but to a lesser degree than maximum gustatory stimulation with citric acid.

• **Gender, gland size and unilateral stimulation** – Most studies have found that females have lower salivary flow rates than males and a recent study<sup>3</sup> showed that in females, the sizes of the major salivary glands are smaller than in males. Additionally, if one habitually chews on one side of the mouth (for instance with chewing gum), most of the saliva will be produced by the glands on that side after the initial tastants in the gum have been leached out.

• **Age** – Many elderly people receive medication and the greater the number of drugs taken, the greater is the tendency for reduction in salivary flow.

#### Salivary flow rate and oral health

The unstimulated flow rate is more important than the stimulated flow for oral comfort, since only a small fraction of the day (54 minutes in a group of dental students) is spent eating<sup>4</sup>. However, stimulation of the glands through mastication is beneficial in terms of promoting clearance of food from the mouth and may help by causing an increase in the unstimulated flow rate, although further

studies of this are needed. A study has shown that two sugar-free chewing gums, one containing chlorhexidine, used by a group of 'frail, elderly', dentate subjects over a one-year period, led to improved oral health and a statistically significant 55-100% increase in their stimulated flow rate<sup>5</sup>. This suggests that if the glands are stimulated regularly, their secretory ability may increase. Unfortunately, unstimulated flow rates were not measured in that study.

#### Carbohydrate clearance from the oral cavity

One major role of saliva is the clearance of carbohydrate from the mouth. The more

rapid the flow, the faster the carbohydrate is cleared. This is true whether the saliva is unstimulated or stimulated, for example by chewing gum. If the gum contains sweeteners such as xylitol or sorbitol, which are minimally metabolised by plaque bacteria, then the increased salivary flow will be very effective in clearance of cariogenic carbohydrates remaining from previously consumed food.

#### The composition of saliva

The composition of saliva is affected by many factors, such as the type of salivary gland producing the saliva. For example, most of the amylase in saliva is produced by the parotid glands while

blood-group substances are derived mainly from the minor mucous glands.

#### Factors affecting salivary composition

• **Flow rate** – The main factor affecting the composition of saliva is the flow rate. As the flow rate increases, the pH and concentrations of some constituents rise (e.g. protein, sodium, chloride, bicarbonate), while those of others fall (e.g. magnesium and phosphate).

• **Duration of stimulation** – When the salivary flow rate is held constant, the composition of the saliva depends on the duration of stimulation<sup>6</sup>.

&gt; Page 39

# The One

**"THE TRUE IMAGING EXPERTS"**  
**GO FOR INSTRUMENTARIUM DENTAL**

ORTHOPANTOMOGRAPH® is a registered trademark of Instrumentarium Dental, Palo Alto, CA, USA.



This is the one that started it all. This is the one, that set the benchmark for everyone to follow. This is the one with a long legacy of innovation. This is the one which became synonymous with quality – **This is Instrumentarium Dental's ORTHOPANTOMOGRAPH®. The OP1.**

**With a legacy of innovation and experience spanning over 50 years,** we've mastered the clinical excellence valued by true dental professionals. We're ready for the next 50 years. As a true professional yourself, are you ready to join us for this journey?



1961 | ORTHOPANTOMOGRAPH® OP1      2011 | ORTHOPANTOMOGRAPH® OP300      2013 | The journey continues

[www.instrumentariumdental.com](http://www.instrumentariumdental.com)



**INSTRUMENTARIUM**

# Clinical and diagnostic advantages of PreXion 3-D imaging system



*mCME articles in Dental Tribune have been approved by:*

*HAAD as having educational content for 2 CME Credit Hours*

*DHA awarded this program for 2 CPD Credit Points*

**ADA CERP®** | Continuing Education Recognition Program

Centre for Advanced Professional Practices (CAPP) is an ADA CERP Recognized Provider. ADA CERP is a service of the American Dental Association to assist dental professionals in identifying quality providers of continuing dental education. ADA CERP does not approve or endorse individual courses or instructors, nor does it imply acceptance of credit hours by boards of dentistry.

*CAPP designates this activity for 2 CE credits.*

By Dan McEowen, DDS

For nearly 100 years, dentists have relied on 2-D radiographic imaging for diagnosis and treatment planning. With the 1999 introduction of cone-beam computed tomography (CBCT), all dentists now have tools available for more accurate diagnosis and treatment.<sup>1</sup>

The ability to look at a tooth in any direction and orientation, as well as in 3-D, eliminates much of the guesswork commonly experienced with 2-D radiographs.

We have been limited in most cases to only a buccal-lingual view provided by periapicals, bitewings and panoramic radiographs with the occasion-

al axial view of an occlusal film. Medical CT scans and images began in the early 1970s and were sometimes used by dentists, offering our first multiplaner views.<sup>2</sup>

The adoption of 3-D cone-beam imaging is appropriate and has important advantages for all modalities of dentistry. From every specialist to the general dentist, the increased amount of radiographic information as well as increased accuracy will aid in the most sound diagnosis possible.

## CBCT description

CBCT is a single or partial rotation of an X-ray source around the head, capturing X-rays on various flat panel arrays and sensors. The information is converted to a series of axial slices by computed tomography and stored as virtual anatomy in the computer.

With the use of sophisticated software, the dentist is able to view information in several different views, including: axial slices (head-to-toe orientation), coronal slices (front-to-back orientation), sagittal slices (side-to-side orientation) all known as multiplaner reconstructions (MPR). The thickness of each slice can be varied to include more or less information.

Because the voxels (volumetric pixels 3-D) are isotropic, other MPR images can be generated by slices drawn at any angle, curve or thickness through the scan to view areas critical to the final diagnosis.<sup>5,8</sup>

The final view offered by CBCT is a 3-D view that can be rotated and viewed in any direction.

Once again through software manipulation, 3-D images

can be viewed as conventional radiographs, maximum intensity projections (MIP), soft-tissue projections and a variety other views.

This nearly endless ability to manipulate the data aids in the diagnosis and identification of disease, nerve canals, sinus morphology, dental caries, bone density, fractures, endodontic pathology, implant placement criteria, periodontal defects, bone pathology, fractured teeth, iatrogenic trauma, TMJ morphology and disease, third-molar position and many more healthy or diseased conditions.

## Early CBCT adoption with implants

The first and primary use of CBCT for early adopters was implant placement. As the scope and the value of the information became better known, dentists of all branches began to see the value of MPRs and 3-D renderings including periodontics, endodontics, oral surgery, treatment of TMJ, orthodontics, implantology and general dentistry.<sup>1,7,8</sup>

Clinical periapical and panoramic radiographs for the placement of implants can be misleading with elongation, foreshortening, superimposition and geometrically incorrect data.<sup>7,8</sup> A look at the implant in the periapical shows no obvious disease to an existing integrated implant. Clinically, a buccal fistula was present with exudate and slight pain. The CBCT scan (Fig. 1) reveals a more accurate view showing a buccal defect on a sagittal MPR. A surgical flap revealed a dehiscence of the coating of the implant. Removal of the foreign body resulted in an asymptomatic and healthy patient.

The evaluation of the available bone for the initial implant placement can be crucial for the long-term success of the case. If there is inadequate bone available, grafting may be a necessity. CBCT studies render the most accurate information available at a low radiation dose. The periapical shows an obvious lack of bone height, but does not show the buccolingual dimensions or an accurate view of the sinus morphology (Fig. 2).

The MPR view of the CBCT shows all necessary measurements to perform the sinus lift and grafting with the immediate placement of the implant fixture (Fig. 5). Three-dimensional views show the floor of the sinus and any soft-tissue pathology (Fig. 4). Having accurate measurements in all dimensions is an advantage of CBCT scanning.

## CBCT and endodontics

Endodontics is a field that is rapidly adopting the use of CBCT and for good reason. The inherent geometric deficiencies of 2-D radiographs make the CBCT scan a valuable adjunct to investigate the root morphology in both 3-D and MPR. The typical periapical will show superimposed canals in the anteriors, bicuspid and molars as well as unwanted bone densities both buccal and lingual to the affected tooth making the image quality poor.

The ability to view MPR slices in cross-section, long axis and oblique directions gives the ability to follow all canals in any direction and show their relationship and measurements from other known structures. This virtual tour of the root morphology is a great benefit to the final treatment outcome (Fig. 5).<sup>5,4</sup>

Post root-canal infection can be difficult to diagnose with the standard periapical. The endodontic fills may appear to be normal even though other clinical findings and symptoms are abnormal. The patient presents several months post root-canal treatment with

pain on palpation and pressure and avoids this side of the mouth.

A periapical radiograph shows minimal pathology (Fig. 6). The roots appear to be filled and a small puff of sealer extends through the apex of the mesial roots. The distal root structure and fill appear normal. There is little indication of periapical radiolucency only a widening of the periodontal ligaments of the mesial roots.

A CBCT scan reveals a completely different picture. The coronal MPR reveals a short fill near the apex of the mesial lingual root and a large radiolucency (Figs. 7, 8) not visible on the periapical radiograph (Fig. 6).

Missed canals are difficult to see in a buccolingual projection of the periapical radiograph as one canal is superimposed on the other (Fig. 9). Often, as viewed in this radiograph, we see periapical pathology with an apparent normally filled canal. CBCT scans allow dentists to look for pathology in MPR planes to identify the actual problem before invasive procedures are performed on the patient. The axial view shows a lingual canal exists and is untreated. The coronal view confirms the diagnosis and treatment can be completed (Fig. 10).

Today's endodontists, as well as general dentists, are benefiting from the diagnostic capabilities of the high-resolution CBCT scanners available over conventional 2-D periapical.<sup>5,6</sup>

## Oral surgery

Oral surgery, with its inherent invasive nature, can be better served using CBCT with MPR as well as 3-D images. The ability to perform virtual surgery is a benefit to both the doctor and the patient. Doctors have the advantage of seeing morphology and landmarks in real time and space with accurate measurements, and patients will gain a better understanding of the problems and the solutions their doctors are offering them.

Third-molar extractions can be risky based on 2-D and panoramic radiographs.

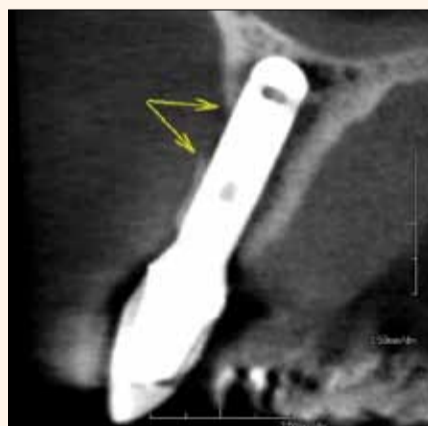

Fig. 1: Sagittal CBCT MPR showing bone defect at point of dehiscence of the implant coating.

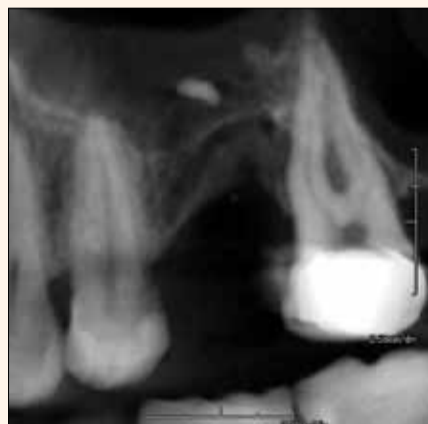

Fig. 2: Periapical does not show the sinus anatomy or the width of the bone.

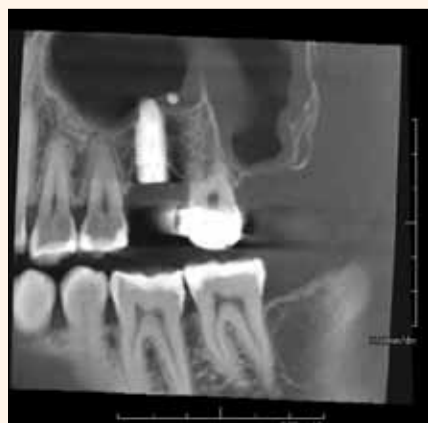

Fig. 3: MPR showing post op of sinus graft and implant placement.

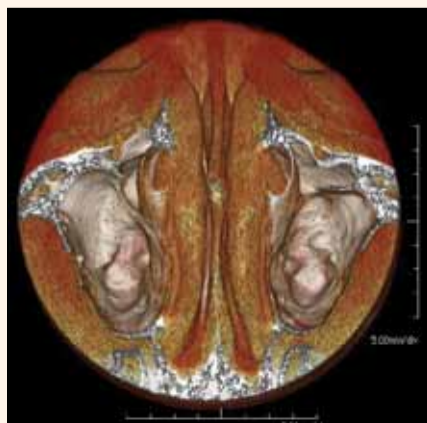

Fig. 4: The 3-D CBCT showing anatomy of the maxillary sinuses.

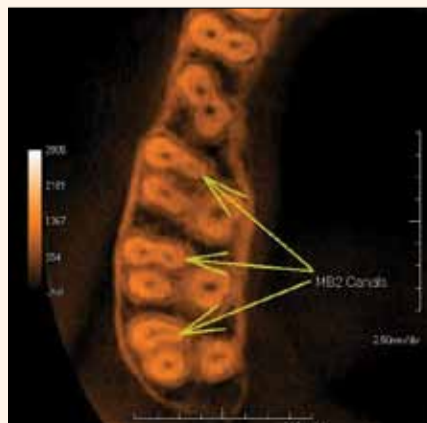


Fig. 5: Axial MPR showing mesial buccal roots in first, second and third molars.

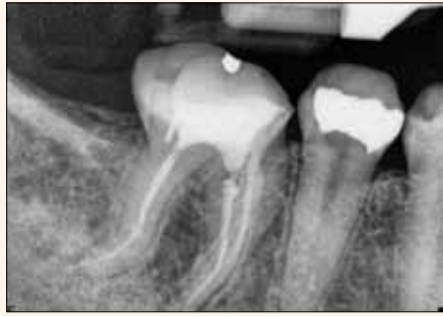

Fig. 6: Periapical showing minimal pathology with no radiolucency.

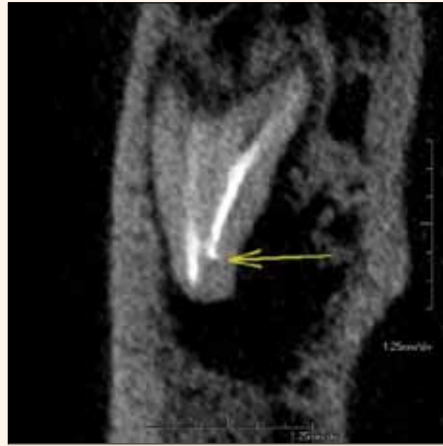

Fig. 7: Coronal MPR showing a short fill on the mesial lingual and radiolucency.

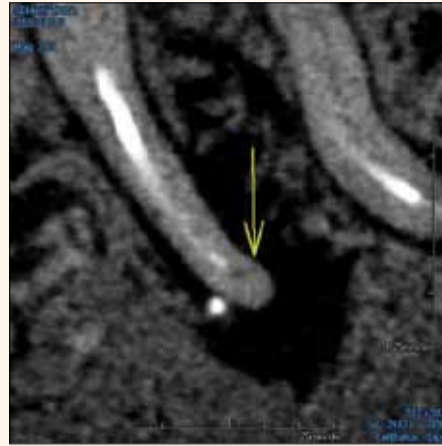


Fig. 8: Saggital MPR showing unfilled canal and radiolucency.

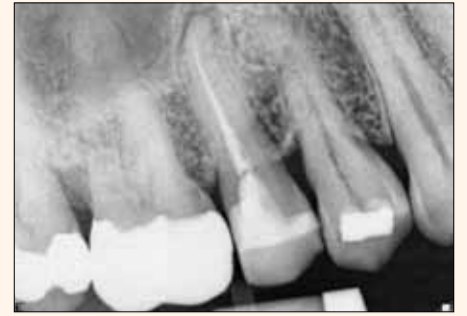

Fig. 9: Periapical showing a normal fill with a radiolucency.

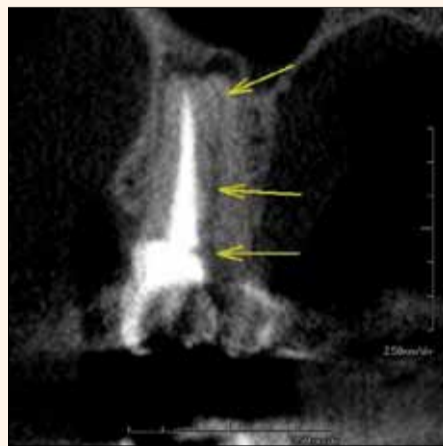

Fig. 10: Coronal MPR showing the superimposed lingual root unfilled.

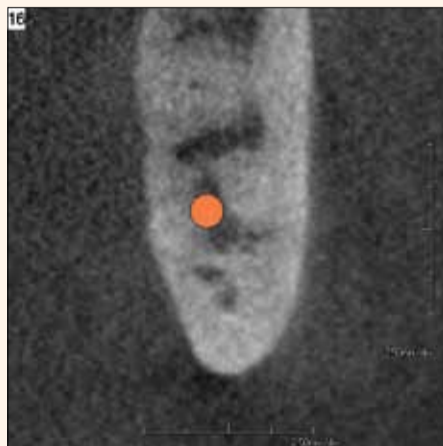


Fig. 11: Coronal MPR showing nerve between roots of the third molar.

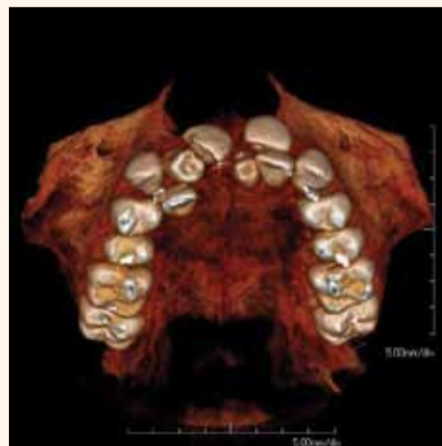


Fig. 12: The 3-D rendering showing supernumerary teeth and positions.

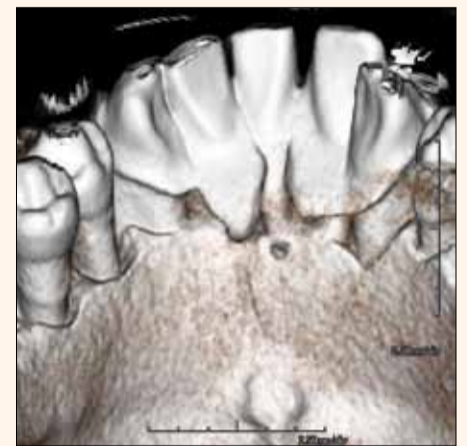


Fig. 13: The 3-D Rendering with periodontal defects and calculus bridge.

These radiographs can often superimpose nerves and sinuses over root structures. Dentists using 2-D radiographs must often rely on experience to assess the risks of iatrogenic trauma. The use of CBCT with MPRs and 3-D images reduces any guessing as well as the chance for any permanent damage to the patient. With the adoption of CBCT, the judgment is based

on solid evidence and the risk will decrease.

A panorex of the superimposed third molars gave no solid evidence the canal lies between the roots. It is only with the use of CBCT and the MPRs that the nerve can accurately be seen traversing between the mesial buccal and mesial lingual root (Fig. 11).<sup>4,5</sup>

Other surgical advantages include the identification and the position of supernumerary or impacted teeth. The images show accurate positions and show definitive morphology that will aid in removal of the proper teeth (Fig. 12). Knowing the exact position of many of these teeth is a benefit to both the doctor and patient. It will lead to the most precise surgical path and the least invasive procedure.

#### Periodontics

The explanation of periodontal problems are often misunderstood by the patient. As doctors we talk about pockets, point to X-rays and propose treatment only to have patients refuse treatment because they do not understand what we are clinically describing. Using the 3-D portion of the CBCT scan can improve the understanding and acceptance of treatment plans. The images are a picture of the problem that is owned by that patient and much easier to understand by the layperson. Illustrating periodontal defects and pockets allows the patient to better participate in the process (Fig. 13).

The MPRs and the 3-D projections aid in surgical planning for periodontists, allowing for accurate measurements and bone analysis prior to osseous surgery that doctors cannot get using the periapicals or panoramics. Studies have shown that CBCT images are more accurate than panoramic radiographs. For the periodontist placing implants, the ability to measure bone density and avoid important anatomy is important.<sup>4,5</sup>

#### Orthodontics

Orthodontists are beginning to adopt large field-of-view CBCT. Recent studies show that linear measurements of bony structures are more accurate using CBCT and have less distortion than currently used methods of measurement: lateral cephalometric, posteroanterior (PA) and submentovertex (SMVT).<sup>5</sup> Accurate measurements of tooth volume and tooth position can aid in accelerated treatment times and more precise treatment.

Along with tooth position, density of bone and size of arches, the orthodontist also has an accurate evaluation of the temporomandibular joint and position of the condyles. Impacted teeth are easily identified and position either buccal or lingual can be confirmed prior to movement or removal. Both MPRs and 3-D projections give the clinician a complete picture of the problems and the treatment course.

With a single CBCT scan, orthodontists can produce all of the information they need: panoramic, cephalometric, PA, SMVT, tooth size and volume, crowding evaluation in any plane, TMJ evaluation and airway analysis, all with both soft-tissue and skeletal information.<sup>5,7</sup>

#### Conclusion

We treat our patients in 3-D, and now, with conebeam computed tomography, we are changing the way we diagnose from 2-D to 3-D. The addition of this technology will increase your diagnostic skills with better and more complete information at your disposal. As with any type of invasive diagnostic tool,

clinicians should weigh the risk to benefit in using CBCT scans.

Judicious use of CBCT and knowledge of patient's lifetime doses should always be a consideration as well as the availability of other diagnostic tests appropriate for the problems of the patient. When adopting new technology, training is paramount. Along with training comes the responsibility of the doctor to read and diagnose information from CBCT scans. Do not avoid CBCT from lack of knowledge; instead, take this opportunity to become a better diagnostician and radiologist. As you review radiology and pathology, your use of CBCT will aid in making the most accurate diagnosis and the most complete treatment plans.

*Editorial note:*

*References are available from the author.*<sup>DT</sup>

#### About the author

Dan McEowen, DDS, is a 1982 graduate of Loma Linda School of Dentistry and has been in private practice for 26 years. He is a founding member of the World Clinical Laser Institute, achieving a mastership level of proficiency. He has been active in FDA approval of oral surgery techniques using Erbium lasers. McEowen has lectured and trained internationally in techniques using lasers in general and specialty dental fields. He is a member of the ICOI and is active in implantology. McEowen has been involved in cone-beam technology for more than five years and owns 3D Imaging Center in Maryland.

#### mCME SELF INSTRUCTION PROGRAM

CAPP together with Dental Tribune provides the opportunity with its mCME- Self Instruction Program a quick and simple way to meet your continuing education needs. mCME offers you the flexibility to work at your own pace through the material from any location at any time. The content is international, drawn from the upper echelon of dental medicine, but also presents a regional outlook in terms of perspective and subject matter.

#### Membership:

Yearly membership subscription for mCME: 600 AED  
One Time article newspaper subscription: 100 AED per issue.  
After the payment, you will receive your membership number and allowing you to start the program.

#### Completion of mCME

- mCME participants are required to read the continuing medical education (CME) articles published in each issue.
- Each article offers 2 CME Credit and are followed by a quiz Questionnaire online, which is available on <http://www.cappmea.com/mCME/questionnaires.html>.
- Each quiz has to be returned to [events@cappmea.com](mailto:events@cappmea.com) or faxed to: +971436868883 in three months from the publication date.
- A minimum passing score of 80% must be achieved in order to claim credit.
- No more than two answered questions can be submitted at the same time
- Validity of the article - 3 months
- Validity of the subscription - 1 year
- Collection of Credit hours: You will receive the summary report with Certificate, maximum one month after the expiry date of your membership. For single subscription certificates and summary reports will be sent one month after the publication of the article.

The answers and critiques published herein have been checked carefully and represent authoritative opinions about the questions concerned.

Articles are available on [www.cappmea.com](http://www.cappmea.com) after the publication. For more information please contact [events@cappmea.com](mailto:events@cappmea.com) or +971 4 3616174

**FOR INTERACTION WITH THE WRITERS FIND THE CONTACT DETAILS AT THE END OF EACH ARTICLE.**

# Clinical digital photography. Part 1: Equipment and basic documentation



*mCME articles in Dental Tribune have been approved by: HAAD as having educational content for 2 CME Credit Hours DHA awarded this program for 2 CPD Credit Points*



Centre for Advanced Professional Practices (CAPP) is an ADA CERP Recognized Provider. ADA CERP is a service of the American Dental Association to assist dental professionals in identifying quality providers of continuing dental education. ADA CERP does not approve or endorse individual courses or instructors, nor does it imply acceptance of credit hours by boards of dentistry.

*CAPP designates this activity for 2 CE credits.*

**By Dr. Eduardo Mahn, DDS, DMD, PhD**  
**Universidad de los Andes**  
**Clinica CIPO Santiago-Chile**

**A**bstract: The use of photography is becoming a standard in modern dental practice. The sharing of pictures is not only essential for communication between dentist, laboratory technician and patients, but also for communication between professionals, undergraduate and postgraduate students with their teachers

and for documenting of clinical procedures in cases you want to show to both patients and work colleagues at scientific meetings. This article will describe the necessary equipment for clinical photography, explain its uses and deliver the foundation for basic documentation and structure for clinical cases. The second part will discuss the step by step documentation and show practical examples to improve your results.

**Introduction**

The first process of photogra-

phy was presented to the world by Louis J. M. Daguerre at the Paris Academy of Sciences on January 7, 1839. In that same year, Alexander S. Wolcott, a manufacturer of dental instruments, designed and patented the first camera producing images on a silver-coated copper plate.<sup>2</sup> Thanks to the graphic documentation that this allowed, it created the first dental journal, the American Journal of Dental Science.<sup>5</sup>

Due to the advancement in technology, we now have the privilege of having digital photography that allows an immediate view of the results and not having to wait for the processing of films as was the case of old movies, utilising silver halide ions in a gelatine emulsion on a strip of celluloid film to capture latent images. The advantage of digital images is that in addition to instantly seeing them through a viewfinder, there is less cost of developing film negatives and their storage is easy and fast. The power of viewing and saving images in computers also saves space and access to a database is almost immediate. By developing different virtual media files and almost universal use of email, information sharing is almost instantaneous anywhere in the world.

Because many of the procedures performed in dentistry represent established protocols that should be read, learned and then practiced, it becomes clear that photography aids us in teaching or explaining to our patients what we think are common, but to them are complex and mysterious procedures.

**Digital Cameras**

There are currently hundreds of cameras on the market. If we compare their features and capabilities, we can divide them into 3 groups:

Compact cameras (point and shoot), interchangeable lens cameras (mirrorless system cameras) and reflex cameras, SLRs DSLR (Digital Single Lens Reflex).

Initially, compact cameras (Figure 2) may seem appealing, but they have many limitations. They do not have a consistent image control, the position of the flash is not suitable for intraoral photography, distorted images from utilization of an insufficient macro lens in the wide-angle position, lack of manual exposure and focus problems. One of the biggest problems is the inability to change the lens, which gives its




Figure 11, 12 and 13: Different types of intraoral mirrors.

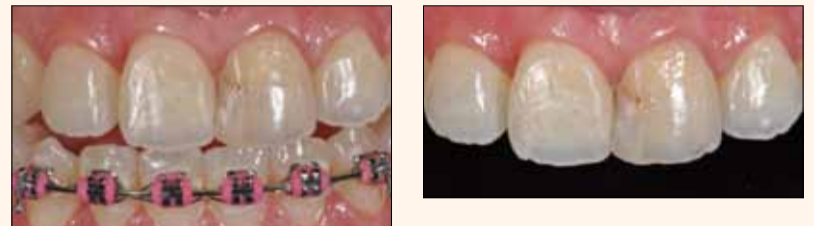

Figure 14 and 15: Photo without and with a contrastor. Notice how other structures distract the viewer from what is to be displayed effectively. When using a black background, all the attention goes to what the desired clinician wishes display.

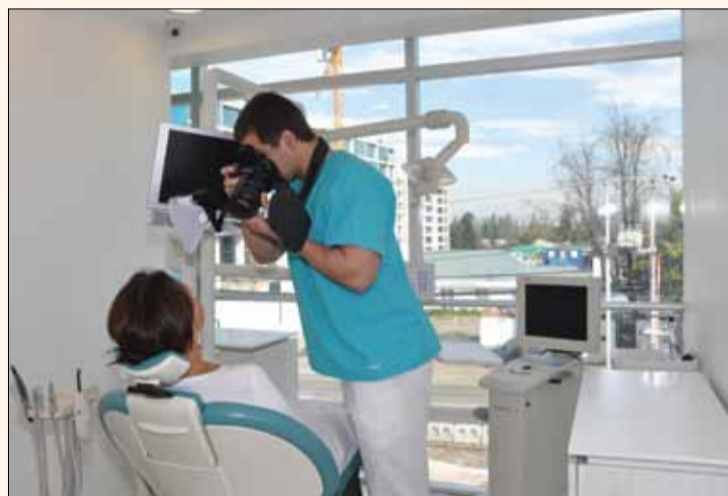

Figure 1: Clinical photography can be helpful, provided that we understand the basic principles and have the right equipment.



Figure 16 and 17: Examples of a portrait with distracting factors and a clearer one.

design for a wide angle or middle distance, causes distortion of perspective, as the clinician would have to stand close to the patient. This has another negative effect of poor lighting.<sup>4,5</sup>

The second group seems promising, but is still in development, and the third group, DSLR cameras (Figure 3), are those with greater advantages for clinical use, thanks to the sensor size and the many options in manual mode, lenses and flashes.

These cameras use a lens for both image composition and image capture<sup>6</sup>. This design, which allows direct viewing and focusing without parallax error, is ideal for dental photography.<sup>6, 7, 8</sup> One of the biggest advantages is the ability to exchange lenses. For example, you can take pictures of landscapes, portraits, and all dental treatments with the same camera, by just changing the lens. The same applies with changing the flash. All professional cameras more than meet the requirements. Semiprofessional cameras (with a more affordable price) that meet these requirements are for example Nikon D7000, D90, D5100, D3200, Canon EOS 7d, 60d, 550d or other similar brands.

**Flash**

The discussion with which

flash, macro lateral or twin flash light (Figure 4) or ring flash (Figure 5), is most suitable for intraoral photography, and has been a quite discussed topic for many years<sup>9</sup>.

The ring flash light is the favourite amongst inexperienced dental photographers and it is considered the universal flash system for general macro photography.<sup>10, 11</sup> On the one hand, it is true that the greater the distance between the ring flash and the subject, the flatter, less textured and refined the photos are, while a twin flash generates pictures with more texture, contrast and that look more alive<sup>12</sup>

The macro lateral flash shows more variability in light direction, allowing certain details to be highlighted. The overall hue of colour, cracks and also transitions are best captured with the macro lateral flash.<sup>15</sup> Probably the only drawback, besides its higher cost, is when photographing posterior regions, where access and space is limited. In these cases, the homogeneous light and easy handling of the ring flash has an advantage. In the author's experience, when a clinician decides to begin clinical photography, a ring flash is more



Figure 2 and 3: Compact and SLR camera (DSLR).



Figure 4 and 5: Macro lateral flash and ring flash.



Figure 6 and 7: Different types of lenses, Sigma 105mm f/2.8 EX DG macro and micro Nikkor AF-S 105mm f: 2.8 ED, NC, VR.



Figure 8, 9 and 10: Mirahold, Spandex and OptraGate retractors.



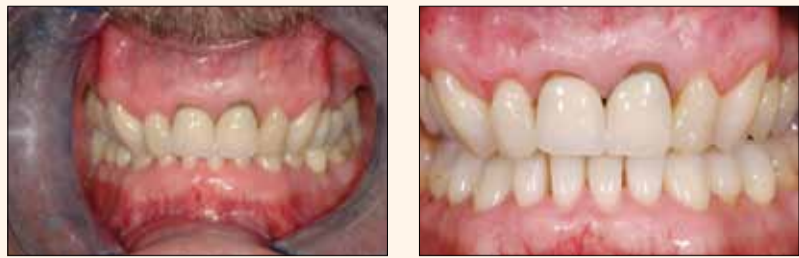

Figure 18 and 19: Examples of a general anterior photo. Ideally, lips, corners, mustaches and retractors should not appear in the photo.

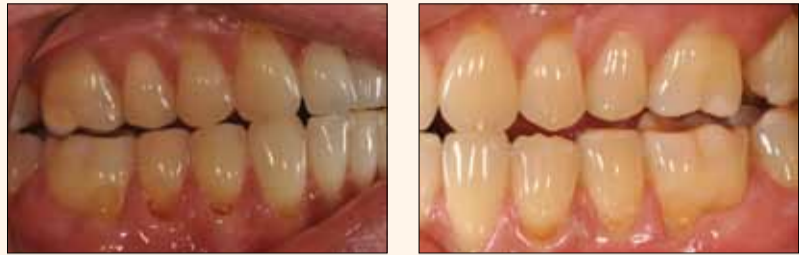

Figure 20 and 21: Example of a lateral view. Note the difference between the two pictures both in lighting and in the presence or absence of distracting factors.

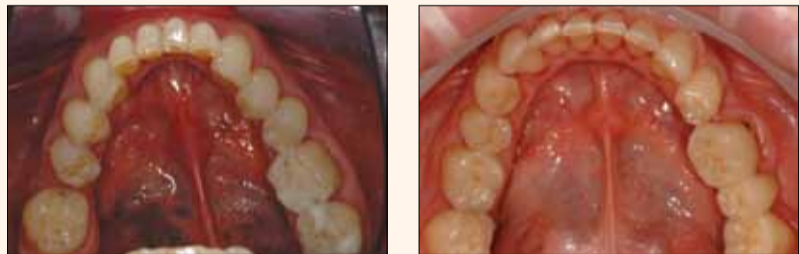

Figure 22 and 23: Mandibular occlusal view. This kind of picture may be difficult to achieve with the presence of the tongue. Examples of a poor and well taken picture.

than adequate; the extra cost of the macro lateral flash is not justifiable, since differences in the early stages of the learning curve will not be substantial. Then once they handle certain techniques, the macro lateral flash is a great contribution.

#### Lenses

Basically, macro lenses from 50 to 200mm in focal length are used for clinical photography. In the author's experience, macro lenses of about 100 mm in focal length provide the ideal combination of magnification ability and convenience working distance for dental purposes. Teleconverters or zoom lenses can be used, but not recommended. The same goes for lenses with autofocus mode. If this is the case, the automatic mode must be switched off and put on manual. Focusing is done manually and moving the ring lens near a sharp image, and with small

movements to and fro, achieves perfect focus. A high quality lens is paramount to capturing crisp and bright photos.<sup>14</sup> This aspect should not be compromised. It is ideal to have a magnification ratio of 1:1. In the author's experience a good lens to start off with at a reasonable cost is the Sigma 105mm f/2.8 EX DG macro (Figure 6), which is compatible with different brands of cameras. On the other hand, for the seasoned and professional photographer, who does not want to compromise quality, a Nikkor micro lens and the AF-S 105mm f: 2.8 ED, NC, VR (Fig. 7), would be recommended, though costing more than doubled compared with the aforementioned Sigma.

#### Accessories Retractors

To gain better access to the buccal cavity, better visualization of the structures of interest and

that they are sufficiently illuminated, it is essential to have good lip retractors. They should neither be very uncomfortable for patients, should avoid reflections and ideally possess a certain capacity to stay in place and avoid having the dental assistant hold them, as is the case with Mirahold type retractors (Figure 8). In the case of a Span-dex type (Figure 9) or soft latex retractors from Ivoclar Vivadent OptraGate (Figure 10), this does not happen and the picture can be taken without external help. Ideally, always choose the largest possible retractor for improved exposure of the structures of interest. The clinician can make the process less cumbersome by using petroleum jelly or cream on the patient's lips before starting.

#### Mirrors

When taking pictures in posterior regions, mirrors are invaluable, since the angle of the buccal area doesn't allow taking of direct photos. To avoid double images and to enhance the sharpness, quality mirrors are needed, ideally hodium. It is useful to have mirrors with long firm handles (Figures 11-15), in order to position your hands away from the objects of interest and avoid unwanted shadows. This is of particular importance in documenting steps when showing the use of materials or objects near to the teeth. To prevent the mirror misting up, they must be at a temperature similar to that of the oral cavity. For this effect you can use hot water or any type of air heater. You should also ask the patient to breathe through their nose. Another option is that the dental assistant gives a gentle stream of air with the triple syringe. It is noteworthy that these mirrors are very sensitive to fractures, bites, abrasions or scratches, so they must be treated with great care by the staff.

#### Black background or contrastors

In the previous section, where the aim is to show the upper and lower teeth separately, the rest of the structures in the back-

**DR. EDUARDO MAHN HANDS-ON COURSES**  
**VENEERS/CROWNS: 12 NOV. 2014**  
**DIRECT VENEERS: 15 NOV. 2014**  
**FACE AND SMILE ANALYSIS: 15 NOV. 2014**  
 JBH, Dubai, UAE

ground can distract from what you want to highlight. To avoid this, we recommend the use of opaque black plates called contrastors, positioned behind the teeth you want to photograph. When used correctly, the quality of the picture is improved and the viewer can focus on the subject (Figures 14 and 15). Besides commercial products from brands like Anaxdent, Doctors-eyes and Photomed, different types of black plastic can also be used as long as they do not generate unwanted reflections. If you do use material other than contrastors, it is important to use your preference consistently when photographing a series of photos. If you decide to cut the edges of the picture by using software such as Photoshop, it not only will not produce the same results, because cropping will increase the relative size of the pixels due to the magnification of the desired area, but will increase the time invested by the clinician producing good quality clinical photos.

#### Examples

In order to compliment intra-oral photography, it is recommended to show pictures of patients before and after treatment. These types of photos, although may seem simple and easy to execute, can present difficulties. In Figure 16 and 17, you can see a badly taken picture, distracted by multiple flaws such as inadequate background, shadowing on the right side, and an unfavourable facial expression, etc. In contrast, Figure 16 shows clearer picture, a neutral background, no unwanted shadows, good lighting and a positive facial expression.

The second aspect to show in most of the treatments is a buccal overview of the oral cavity, starting from the anterior teeth. In the Figure 18 and 19, you can see two examples of a photo, the first badly taken and second well taken. In this case, interest should focus on the anterior teeth that need treatment. Therefore, there is no point taking a picture showing lips, facial hair such as moustache's, lip retractors and excessively showing gingiva. These structures only distract from what is really important.

It is also easy to make errors in lateral photos, an example of this is Figure 20, which shows that, in addition to an underexposed sensor (insufficient light, the picture is dark, the angle is not right, you see the lips and the tip of the mirror). On the contrary Figure 21 is a better photo, having the proper exposure, no distracting elements and the correct angle was taken.

In the occlusal view, both mandibular and maxillary, one must keep several aspects in mind. A good mandibular occlusal photo is far more difficult than the maxilla by several factors: Firstly, the tongue needs to be retracted, secondly, the rapid accumulation of saliva of the patient makes the clinician act quickly and without hesitation, and thirdly, the angle of the photo.

In Figure 22 you notice, in addition to being inadequately illuminated, the axis of the arch is not centered with the photo, we can see the jaws and teeth as well as the edges of the mirror. In contrast, Figure 23 shows an image best achieved where the picture is centered, well lit, and no presence of other distracting structures.

#### Case report

One of the main objectives of the documentation process, is to explain to our colleagues or students what steps were performed to reach certain results. It is also beneficial to graphically present and compare new and already established techniques. The following is simple a case of two composite restorations with sectional matrices and a centripetal layering technique as an example of the detailed documentation and standardization that images should demonstrate.

Another objective of a systematic and structured documentation is to have graphic material, either for patients to understand or to show treatment results objectively, so they have no obscured treatment expectations. These types of aesthetically documented treatments will be discussed and presented with documented cases in a step by step manner in the next chapter of this series, in addition to discussing common mistakes and how to solve them.

*Editorial note:*  
References are available from the author. <sup>[17]</sup>

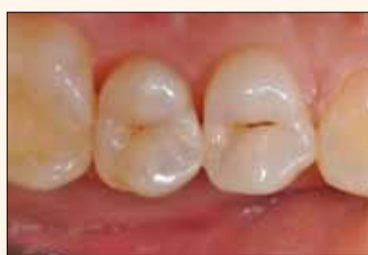

Figure 24



Figure 25

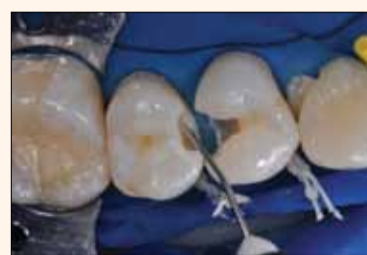

Figure 26

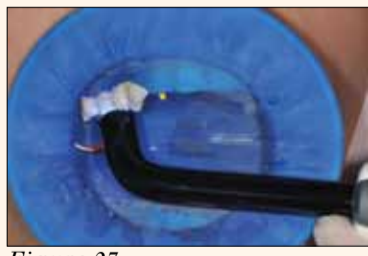

Figure 27

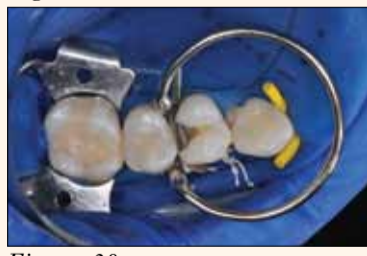

Figure 28

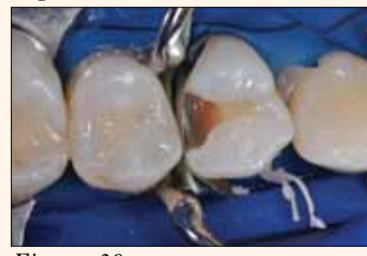

Figure 29

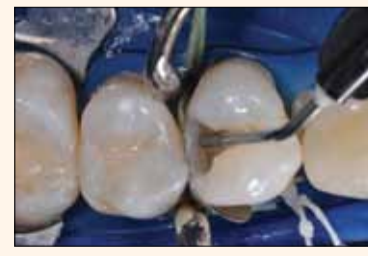

Figure 30

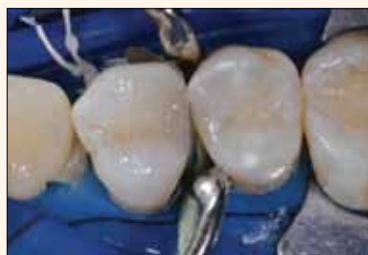

Figure 31

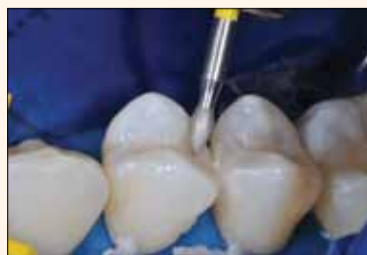

Figure 32

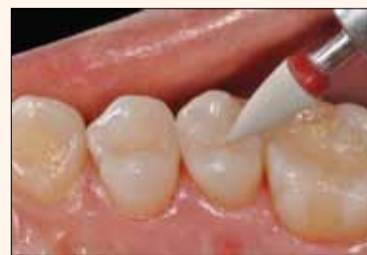

Figure 33

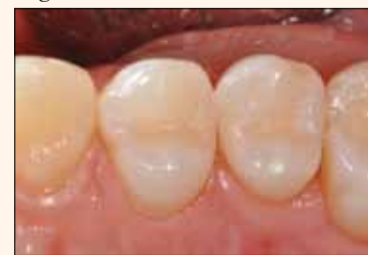

Figure 34

Figure 24-34. Example of standardized documented photographs to show a step by step procedure.

#### About the author

Dr. Mahn is a graduate from the University of Chile, School of Dentistry. He received the German DDS in Munster, Westfalen Lippe one year later. The New York University College of Dentistry certified him as Implantologist in 2007. In 2008, he published his doctorate thesis in 2008 titled "Osseointegration of zirconia implants, an in vivo study" and got his doctorate degree in 2010.