

# implants

international magazine of oral implantology

4<sup>2016</sup>



**research**

Survival of allogenic corticocancellous bone blocks

**case report**

Straightforward advanced complex in dental implantology

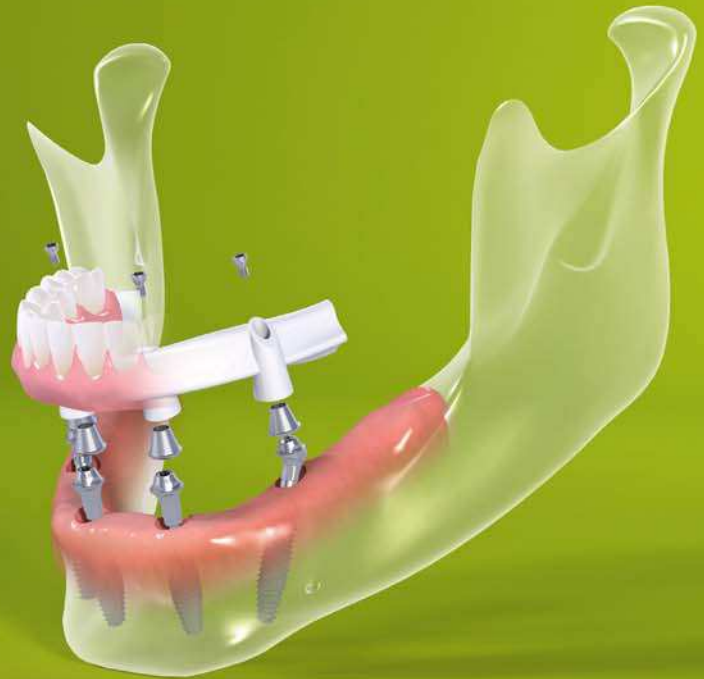**industry**

Vestibular cortical stabilisation with bone graft





More than a  
fixed rehabilitation.  
A reason to smile.



With Straumann® Pro Arch patients are sure to receive a high-end solution that will instantly bring a new quality of life. And a perfect smile:

- Reduced complexity by addressing the individual anatomical situation and leveraging the unique Roxolid® material
- Predictability even in challenging cases thanks to the SLActive® surface
- Time-saving treatment with the option for immediate temporization
- Increased efficiency with new prosthetic portfolio

In combination with:



# Munich extraordinaire!



Dr Georg Bach

Dear colleagues,

Anything but ordinary—Our DGZI family has only recently experienced eventful days in Munich during our 46<sup>th</sup> International Annual Congress. Extraordinary, no doubt, was the choice of Munich as event location, which certainly is always worth a trip. Moreover, the two congress days were packed with knowledge and expertise of renowned speakers from Germany and abroad, organised by congress makers Prof. Dr Herbert Deppe and Prof. (CAI) Dr Roland Hille. We also experienced an exceptional cooperation among colleagues, within the lecture halls as well as during the evening event on the Oktoberfest Wiesn at the Löwenbräu brewery, which has proven to be an unforgettable event especially for our international guests. Furthermore, we have seen an exceptional congress organisation, which is why I would like to especially thank our headquarters and their leader Dr Torsten Hartmann as well as the OEMUS MEDIA AG team.

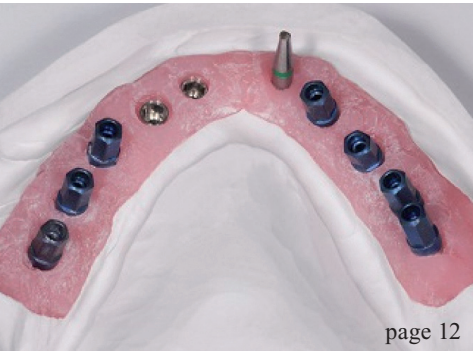
Memorable were the key messages of the congress, which were dedicated to the ambitious topic "Implantology and Aesthetics". While the options for aesthetically oriented implantology have increased, pre-implantological problems of implant planning or implantological education still form the centre of the discussion. If these parameters are not well adjusted, we are prone to reach a high-risk zone of complications and possible failure. That's when "total damage" might be a consequence, both a fact and warning that were highlighted throughout the congress.

Another success parameter formed a key aspect of the scientific contributions and discussions: the contemplation of biological principles. Therefore, the congress posted the provocative question, 'Does biology still play a permanent role implantology?' It does! Which is why I now would like to shed some light on the 2017 DGZI Congress.

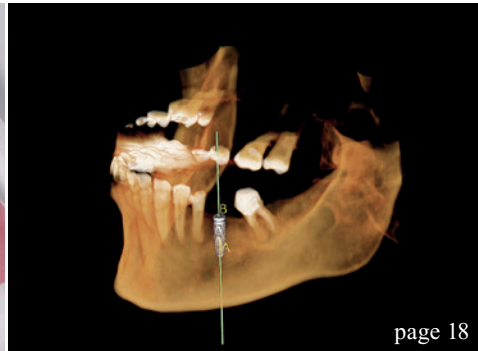
The 47<sup>th</sup> DGZI Congress is going to take place on the last weekend of September 2017 in Germany's capital Berlin. We hope that this event will help us to decide upon this pressing problem of the relevance of biological aspects in implantology. We are looking forward to it!

With warm collegial regards,

Dr Georg Bach



page 12



page 18



page 40

| **editorial**

- 03 Munich **extraordinaire!**  
Dr Georg Bach

| **research**

- 06 **Survival** of allogenic corticocancellous **bone blocks**  
Dr Dadi Hrafnkelsson

| **case report**

- 12 Straightforward **advanced** complex in dental **implantology**  
Dr Rolf Vollmer, Dr Patricia Wieschollek and the laboratory team of Michael Anger

| **industry**

- 18 The **atrophic** crest  
Dr Paolo Borelli & Dr Massimiliano Favetti
- 24 The use of **narrow** implants  
Dr Huub van't Veld
- 30 **Comparison** of bone-graft **substitutes**  
Dr Robert J. Miller, MA, DDS, FACD, DABOI

| **interview**

- 33 “**Powerful**, but remarkably gentle to the bone”
- 34 “The **surface** that the **bone** was waiting for”

| **events**

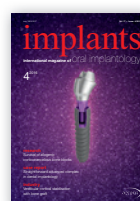- 40 46<sup>th</sup> **International** Annual **DGZI** Congress in **Munich**  
Dr Georg Bach
- 44 **SOIA** **symposium** **Sudan**  
Dr Rolf Vollmer
- 45 Millions of **happy** **smiles**  
Dr Rolf Vollmer
- 46 1<sup>st</sup> **Joint** Congress of **GLIPD** and **DGZI** in **Georgia**  
Dr Rolf Vollmer
- 47 **25<sup>th</sup>** Annual **EAO** Congress

| **news**

- 36 manufacturer **news**
- 49 **news**

| **about the publisher**

- 50 imprint



Cover image courtesy of Klockner Implant System  
www.klocknerimplantsystem.com  
Original Background: © Christos Siatos/Shutterstock.com



neo

THE NEXT SENSATION

by Alpha-Bio Tec.

 | [www.alpha-bio.net/neo](http://www.alpha-bio.net/neo)



# Survival of allogenic corticocancellous bone blocks

## Horizontal alveolar process augmentation for implant placement

**Author:** Dr Dadi Hrafnkelsson, M.Sc., Denmark

### Introduction

Loss of mastication or aesthetics that is to be restored by dental implants requires sufficient volume and quality of alveolar bone.<sup>1-3</sup> It is important for the primary stability and the long term success of any dental implant treatment. The famous golden standard remains to be the autologous bone block<sup>4,5</sup> as it is not involved in any immunological concerns, and contains vital cells. However, the vitality of the graft is highly dependent on the perioperative storage of

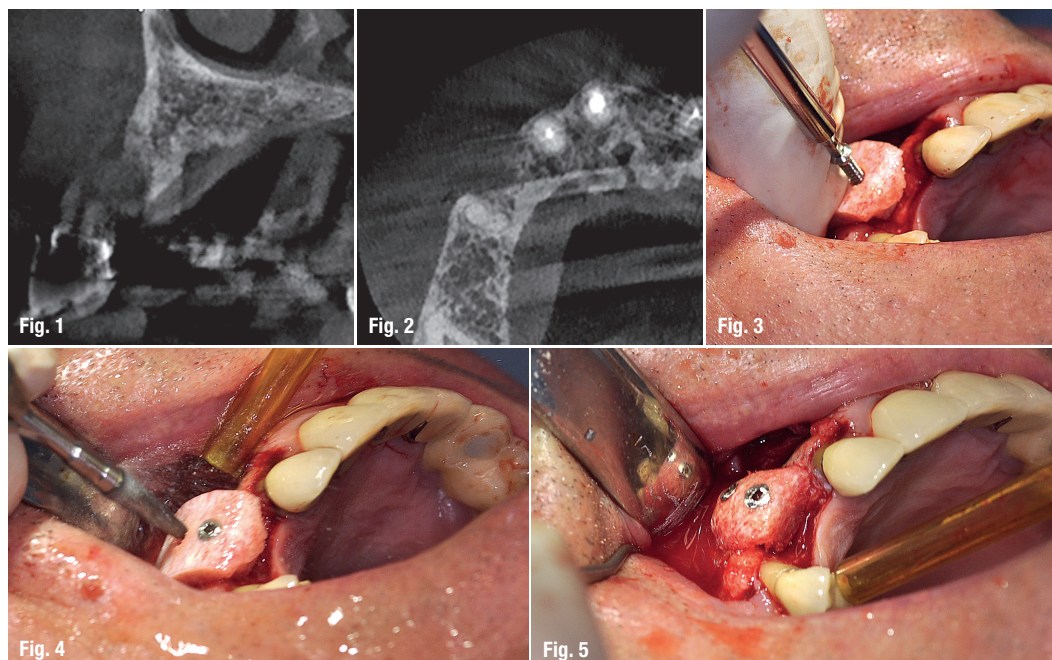
the graft.<sup>6</sup> It is generally accepted that class IV and V, according to the Cawood and Howell classification,<sup>7</sup> need block augmentation before implant placement. The use of osseous allograft blocks for alveolar process augmentation is not very well documented in the literature.

Antonio Barone et al.<sup>8</sup> published his study in 2009 and showed a good success with the osseous allogenic block, 24 blocks were used to augment the maxilla in 13 patients. Five blocks were used for ver-

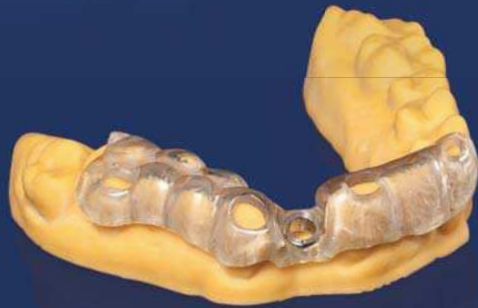
**Figs. 1 & 2:** Case 1: Horizontal atrophy of the alveolar process in the maxilla.

**Figs. 3 & 4:** Allogenic bone block is fixed with two osteosynthesis screws.

**Fig. 5:** All sharp edges are removed intraorally.



# The complete implant workflow – easiness with **one** software



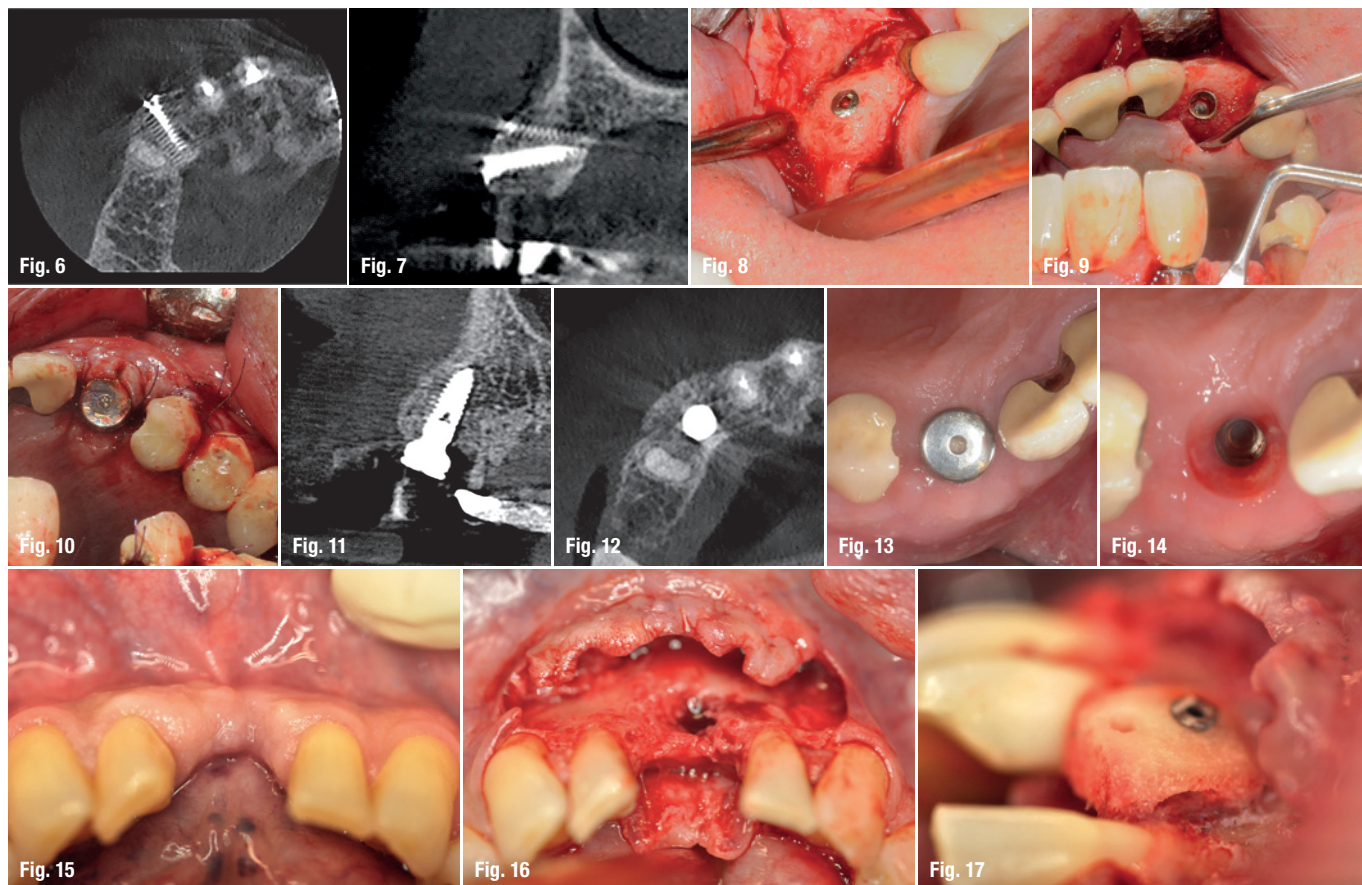
Taking an implant plan to actual surgery is now easier than ever! From imaging to implant planning and guide designing, all workflow steps can be controlled and completed in the **Planmeca Romexis®** software. Lastly, the guide can be easily and accurately created with **Planmeca Creo™** 3D printer.

[www.planmeca.com](http://www.planmeca.com)



**PLANMECA**





**Figs. 6–8:** Six months after bone augmentation.  
**Figs. 9 & 10:** Implant placement.  
**Figs. 11–14:** Healing six weeks after implant placement.  
**Figs. 15 & 16:** Case 2: Preoperative situation.  
**Fig. 17:** Allogenic bone block stabilised with a single osteosynthesis screw. Lateral view, much of the spongy part was removed so there was a gap between residual bone and graft.

tical augmentation. Out of these 24 blocks, two were a failure due to soft tissue exposure and thus completely removed. The remaining blocks were loaded with 38 implants at later stages and all implants achieved good primary stability. Contar et al.<sup>9</sup> also published their paper in 2009. A total of 34 osseous allogenic blocks were used in 15 patients, one block had an early exposure. A number of 51 implants were placed into the grafted area with sufficient primary stability. None of the implants were lost within an observation period between 24 to 35 months. Carinci et al.<sup>10</sup> published a paper in 2010 where implants placed in the resorbed maxilla, which had been grafted with osseous allogenic blocks and reported a survival rate of 98.3% over a mean follow-up of 26 months. This study showed results comparable to same areas augmented with autologous iliac crest bone.<sup>11</sup> In 2015, Krasny et al.<sup>12</sup> published an article in which 21 patients were treated with 26 grafts. In two grafts, there were complications with soft tissue, and one augmentation had to be redone because of iatrogenic causes. After three to six months of healing, 33 implants were placed. Within an average observation time of 36 months (28–50), no implant had been lost. Araujo et al.<sup>13</sup> published a systematic review on the same matter in 2013, in which a total of 253 osseous allogenic blocks were placed in 194 patients with a mean follow-up of twelve months (3–66). All studies showed good success from 95% to 100%.

## Materials and methods

A total of 15 Patients were treated by the same surgeon in Godt Smil Odense from November 2013 to March 2015. Nine Patients were male, six were female. The youngest patient is 26 and oldest patient is 78-years-old. These 15 patients received 19 allogenic bone blocks to horizontally augment the atrophic alveolar process both in the mandible and in the maxilla prior to implant placement. All patients were in good general health, one was a smoker. All patients underwent periodontal therapy, if needed, before surgical intervention.

## Surgical procedure

Premedication is 2,000 mg Imdrax (Amoxicillin), 1,000 mg Pinex (Paracetamol) and 400 mg Ibuprofen (Ibuprofen) 60 minutes before treatment. All Patients were instructed to rinse their mouth with 0.05% Chlorhexidine solution twice for one minute. The same strength of chlorhexidine solution was used for the perioral skin using a chlorhexidine-impregnated gauze. Local anaesthesia was administered as infiltration buccally and palatally/lingually (Xyloplyin® dental adrenalin 20 mg/ml + 12.5 microgram/ml lidocain hydrochlorid + adrenalin, DENTSPLY). Venous blood was sampled with a so-called butterfly (Vacuette® Greiner bio-one). The blood was collected in 10 ml



in a place that has no borders,  
creativity goes unbound...



Bone



Tissue

VCONCEPT<sup>®</sup> By  
mis<sup>®</sup>  
SET THE VOLUME

Albert Einstein once said "look deep into nature and then you will understand everything better". We are proud to introduce you to our VCONCEPT, based on natural design. Ingenuity that leaves more bone volume, more soft tissue volume, more room for nature. Because in a place that has no borders, creativity goes unbound... To learn more about VCONCEPT visit: [www.vconcept.com](http://www.vconcept.com)